

# CHEST<sup>®</sup>

Official publication of the American College of Chest Physicians



## Bronchopleural Fistulas<sup>\*</sup>

Manuel Lois and Marc Noppen

*Chest* 2005;128:3955-3965  
DOI 10.1378/chest.128.6.3955

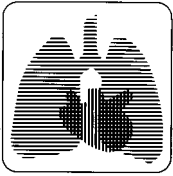
The online version of this article, along with updated information and services can be found online on the World Wide Web at:  
<http://www.chestjournal.org/content/128/6/3955.full.html>

CHEST is the official journal of the American College of Chest Physicians. It has been published monthly since 1935. Copyright 2007 by the American College of Chest Physicians, 3300 Dundee Road, Northbrook IL 60062. All rights reserved. No part of this article or PDF may be reproduced or distributed without the prior written permission of the copyright holder.  
(<http://www.chestjournal.org/site/misc/reprints.xhtml>) ISSN:0012-3692

A M E R I C A N C O L L E G E O F



P H Y S I C I A N S<sup>®</sup>



## reviews

# Bronchopleural Fistulas\*

## An Overview of the Problem With Special Focus on Endoscopic Management

Manuel Lois, MD, FCCP; and Marc Noppen, MD, PhD

A bronchopleural fistula (BPF) is a communication between the pleural space and the bronchial tree. Although rare, BPFs represent a challenging management problem and are associated with high morbidity and mortality. By far, the postoperative complication of pulmonary resection is the most common cause, followed by lung necrosis complicating infection, persistent spontaneous pneumothorax, chemotherapy or radiotherapy (for lung cancer), and tuberculosis. The treatment of BPF includes various surgical and medical procedures, and of particular interest is the use of bronchoscopy and different glues, coils, and sealants. Localization of the fistula and size may indicate potential benefits of surgical vs endoscopic procedures. In high-risk surgical patients, endoscopic procedures may serve as a temporary bridge until the patient's clinical status is improved, while in other patients endoscopic procedures may be the only option. Therapeutic success has been variable, and the lack of consensus suggests that no optimal therapy is available; rather, the current therapeutic options seem to be complementary, and the treatment should be individualized.

(*CHEST* 2005; 128:3955–3965)

**Key words:** bronchopleural fistula; bronchoscopy; empyema; stents

**Abbreviations:** BPF = bronchopleural fistula; HFV = high-frequency ventilation; PEEP = positive end-expiratory pressure

**B**ronchopleural fistula (BPF) is a relatively rare but feared complication of several pulmonary conditions. BPF carries a high morbidity and mortality and is associated with prolonged hospital stay and high resource utilization. Pulmonary physicians are often consulted to assist in the management of these patients for which treatment remains a challenging and frustrating problem. Unfortunately, scientific evidence for the management of BPF is lacking, with several therapeutic options that range from conservative therapies to aggressive surgical procedures, which can be quite disabling. Most of

these interventions are described in isolated case series and personal experiences or retrospective studies, but no guidelines or consensus have been established. This report has the following objectives: (1) to review the etiologies and predisposing conditions for the development of BPF; (2) to review the different therapeutic options with special emphasis on bronchoscopic techniques; and (3) to provide a framework for future directions in research and guideline management.

### DEFINITION AND INCIDENCE

BPFs are communications between the pleural space and the bronchial tree. Although rare, they represent a challenging management problem and are associated with an important morbidity. After pulmonary resection, BPFs can be a life-threatening condition.

The incidence has been reported from 1.5 to 28% after pulmonary resection.<sup>1–4</sup> This variability apparently depends on the etiology, surgical technique,

\*From the Department of Pulmonary Medicine (Dr. Noppen), University Hospital AZ-VUB, Brussels, Belgium; and the John Peter Smith Hospital Intensive Care Unit (Dr. Lois), Fort Worth, TX.

Manuscript received April 19, 2005; revision accepted May 2, 2005.

Reproduction of this article is prohibited without written permission from the American College of Chest Physicians ([www.chestjournal.org/misc/reprints.shtml](http://www.chestjournal.org/misc/reprints.shtml)).

Correspondence to: Marc Noppen, MD, Department of Pulmonary Medicine, University Hospital AZ-VUB, 101, Laarbeeklaan, B 1090 Brussels, Belgium; e-mail: [marc.noppen@az.vub.ac.be](mailto:marc.noppen@az.vub.ac.be)

and experience of the surgeon.<sup>5-7</sup> It seems that the incidence is lower for benign conditions compared to malignancy. Most recently, Cerfolio<sup>2</sup> reported an incidence of 4.5 to 20% after pneumonectomy and 0.5% after lobectomy. Sirbu et al<sup>3</sup> reported their experience with 490 patients with lung resection for non-small cell lung cancer. The incidence of BPF was 4.4% (22 of 490 patients). Twenty-one patients (95%) were men, and 1 patient (4.5%) was a woman. Mean age was 57.8 years. BPF after pneumonectomy occurred in 12 patients (54.6%), in 9 patients (40.9%) after lobectomy, and in 1 patient (4.5%) after sleeve resection.<sup>3</sup>

## ETIOLOGIES

The etiologies are varied (Table 1).<sup>8-13</sup> By far, postoperative complication for pulmonary resection is the most common cause, followed by necrotic lung complicating infection, chemotherapy or radiotherapy (for lung cancer), persistent spontaneous pneumothorax, and tuberculosis (less common).<sup>1,14-16</sup> Most recently, Sato and colleagues<sup>17</sup> reported their experience with postoperative BPF; they found BPF in 5 of 64 cases (7.8%) of inflammatory diseases and 19 of 481 cases (4%) of lung cancer.

In lung cancer patients, BPFs are associated with advanced cases, residual tumor on the stump, and

intrathoracic use of chemotherapy. The incidence is highest in patients who undergo right pneumonectomy and right lower lobectomy. Most of the fistulas are seen on the stump besides the residual lobe.

Preoperative risk factors for the development of BPF are as follows: fever, steroid use, *H influenzae* in sputum, elevated erythrocyte sedimentation rate, and anemia. Postoperative risk factors that have been implicated are fever, steroid use, leukocytosis, tracheostomy, and bronchoscopy for sputum suction/mucus plugging.<sup>17</sup>

In addition, residual tumor in the resection margins, long bronchial stump, tightness of the individual sutures, excessive peribronchial, and paratracheal dissection have been associated with increased incidence of fistulization. All of them increase the risk of ischemic necrosis or pooling of secretions with subsequent colonization and bacterial overgrowth.

In the study by Sirbu et al,<sup>3</sup> right-sided pneumonectomy and postoperative mechanical ventilation were identified as risk factors for BPF. In another study,<sup>18</sup> 557 consecutive cases were reviewed according to nine variables; stumps that made dehiscence were compared with stumps that did not dehiscence. BPF was seen in 1.8% of the cases (10 patients). The main bronchus and intermediate bronchus had a higher risk compared to lobar bronchus. Previous ipsilateral thoracotomy and preoperative chemotherapy and/or radiation increased the risk.<sup>18</sup> When considering the incidence of BPF according to the type of closure, Sonobe et al<sup>18</sup> found an incidence of 1.8% with a manual suture, 5.0% with a stapling device, 1.9% with a stapling device and reinforcement suture at the distal side of staplers, and 1.0% when the reinforcement suture was done at the proximal side of staplers. Other patients at risk for the development of BPF include patients with ARDS (especially if requiring high pressures); chest trauma, invasive chest procedures (including central line placements); debilitated patients, including those with diabetes and malnutrition; patients with pneumonia, lung abscess; or other infectious processes; COPD; and patients with bullous lung disease, spontaneous pneumothorax, or other parenchymal abnormalities.

Because surgical and nonsurgical etiologies have different prognoses and approaches, an alternate classification is included in Table 2. This classification may be more useful to the clinician and may guide the selection of optimal approach or approaches to the problem. In general, surgical procedures (particularly related with cancer or necrotic lung) have a higher incidence and may have worst prognosis.

The postoperative BPF can also be classified as acute, subacute, and chronic. The acute form is

**Table 1—Etiologies Associated With the Appearance of BPFs**

Infectious	
	<i>Haemophilus influenzae</i>
	<i>Streptococcus viridans</i>
	<i>Staphylococcus aureus</i>
	<i>Pseudomona aeruginosa</i>
	<i>Klebsiella pneumoniae</i>
	Pneumococcus
	Nonhemolytic streptococcus
	Aspergillus
	<i>Histoplasma capsulatum</i>
GI	
	Gastroesophageal reflux disease with Barrett esophagus
	Boerhaave syndrome
	Broncholithiasis
Malignancy	
	Lung cancer
	Thyroid cancer
	Esophageal cancer
	Lymphomas
Other	
	Persistent spontaneous pneumothorax.
	Thoracic trauma
	Necrotizing lung disease associated with radiation or chemotherapy
	ARDS
	Idiopathic

**Table 2—Classification of BPFs**

Postoperative
Associated with resection
Malignancy
Trauma
Infectious ( <i>ie</i> , removal of pneumatocele, tuberculosis, abscess, fungus ball)
Associated with pleuroparenchymal disease
Empyema
Thoracic trauma
Other infections ( <i>ie</i> , <i>Pneumocystis carinii</i> , liver abscess opening into the chest)
Others
Tracheal or esophageal perforation repairs
Gastroesophageal reflux disease
Boerhaave syndrome
Nonpostoperative
After procedures ( <i>ie</i> , line placement, pleural biopsy, bronchoscopy, lung biopsy)
Idiopathic
Infections
Persistent spontaneous pneumothorax.
Thoracic trauma
Necrotizing lung disease associated with radiation or chemotherapy
ARDS

usually related to dehiscence or technical problems and requires early reoperation. The subacute and chronic forms are mostly related to infection, and immunocompromised or debilitated patients with comorbidities.

### CLINICAL PRESENTATION

The clinical presentation is variable and is divided into acute, subacute, and delayed or chronic forms. When acute, BPF can be a life-threatening condition due to tension pneumothorax or asphyxiation from pulmonary flooding. The presentation is characterized by the sudden appearance of dyspnea, hypotension, subcutaneous emphysema, cough with expectoration of purulent material or fluid, shifting of the trachea and mediastinum, persistence of air leak in the absence of a technical problem, or decrease or disappearance of pleural effusion on the chest radiograph (postoperative cases).

The subacute presentation is more insidious and is characterized by wasting, malaise, fever, and minimally productive cough. In the chronic form (which is usually associated with an infectious process), there is fibrosis of the pleural space and mediastinum preventing the mediastinal shift

Usually, after a pulmonary resection, air is seen in the pleural space from small air leaks in the cut surface of the lung. Small amounts of fluid also may be present. Air is usually reabsorbed gradually and

continuously, followed by a reabsorption of fluid, and both may be completely gone within the first 24 to 48 h. Prolonged persistence of air and fluid may require drainage. Residual spaces may remain indefinitely without untoward effects and do not necessarily suggest BPF.

Air and fluid are always apparent in the basilar zone of the hemithorax after a pneumonectomy and may be loculated in some cases. The rate of fluid accumulation is variable, but the space left by a pneumonectomy is usually completely obliterated within 3 weeks to 7 months. If the fluid level decreases rather than increases, one must differentiate between a benign decrease in fluid and a BPF with loss of the fluid through the tracheobronchial tree.

A BPF displaces the mediastinum to the opposite side because of an increase in the amount of air on the operated side. Benign descent in fluid level without a fistula shows no associated mediastinal shift. Total clearing of fluid from the space and coughing up of fluid and blood suggest a BPF. Sudden reappearance of air in an obliterated space suggests either a BPF or a gas-forming infectious process.

A BPF can occur any time during the postoperative period but more often occurs within 8 to 12 days after surgery. If seen within the first 4 postoperative days, the BPF is probably secondary to a mechanical failure of closure of the stump and requires re-exploration and reclosure. A BPF also may occur after a suppurative pneumonia or massive pulmonary infarction, or even spontaneously.

Extremely rapid filling of a space with fluid suggests infection, hemorrhage, or malignant effusion. If secondary to infection, the rapid increase in height of the fluid level is usually associated with fever and leukocytosis. Empyema may occur alone or may be associated with a BPF. However, a BPF can occur without associated empyema, and the fluid in the pleural space in these cases is sterile.

When the fistula appears in nonsurgical cases or in the delayed postoperative period, the diagnosis should be suspected when fever, productive cough, and new or increasing air fluid levels are seen on the chest radiograph in the pleural space. In cases of esophagotracheal fistulas, the presentation is typical and straightforward. Coughing and shortness of breath are associated with drinking and eating. Non-resolving pneumonias in the dependent lobes are typical and should be evaluated endoscopically.

### DIAGNOSIS

Several methods have been used to diagnose BPFs, including the instillation of methylene blue into the pleural space<sup>19</sup> and bronchography.<sup>19,20</sup> Although <sup>133</sup>Xe often is no longer used, Zelefsky et

al<sup>21</sup> demonstrated small leaks using <sup>133</sup>Xe in a gaseous state in a ventilation study. In the presence of a fistula, <sup>133</sup>Xe activity accumulates in the pleural space and remained trapped within the pleural space on the washout study. Other gases have been used such as <sup>81m</sup>Kr and <sup>99m</sup>Tc diethylenetriamine pentaacetic acid ventilation scintigraphy.<sup>22,23</sup>

Persistent air leak after pulmonary injury may represent either disruption of a bronchus or rupture of an overdistended alveolus. In general, the former are seen early after injury and the latter in a delayed fashion after a complication such as ARDS.

In a retrospective study of 33 patients, Ricci et al<sup>24</sup> reported their experience using the CT scan as guiding tool for the management of peripheral BPF. They found that the CT was useful in guiding surgery by identifying and localizing the cause in 55% of patients who required surgery. The BPF or its cause was identified in 91% of the cases. The etiologies were bullae in 12 patients, lung abscess/necrotizing pneumonia in 11 patients, peripheral bronchiectasis in 5 patients, malignancy in 1 patient, and posttraumatic pneumatocele in 1 patient. The BPF was right sided in 24 patients, left sided in 9 patients, and visible on CT in 12 patients. In the patients with bullae, 58% required surgery, but the BPF was visible in only 8% (1 of 12 patients). Of the 21 patients without bullae, the BPF was visible in 52%; and in this subgroup, 73% required surgery compared with 30% in whom the BPF was not seen. Ricci et al<sup>24</sup> concluded that the CT scan is useful in detecting the etiology of BPF and select potential candidates for surgery.

Other techniques used for the diagnosis of BPF include the instillation of methylene blue through the stump and its detection in the chest tube, small metallic probes introduced through the working channel of the bronchoscope, and changes in gas concentration in the pneumonectomy cavity after inhaling different concentrations of oxygen and N<sub>2</sub>O.<sup>25</sup> Bronchoscopic exploration is important as a diagnostic and therapeutic intervention. It allows proper evaluation of the stump, attempts to localize the fistula, as well as to exclude tuberculosis or other infectious etiologies and if possible allows the introduction of sealants into the fistulous tract. Of interest is that among a panel of experts for the management of pneumothorax, the use of CT was an acceptable aide in secondary spontaneous pneumothorax during management of an air leak (some consensus) and for planning a surgical intervention (some consensus).<sup>26</sup>

#### PROGNOSIS

BPF, or bronchopleural air leak, is regarded as an ominous complication of ventilator management in

acute respiratory failure. Mortality reports have been variable as stated earlier, but data on its natural course and prognosis are lacking. Pierson et al<sup>15</sup> reported their experience with all cases of mechanical ventilation at a major trauma center during a 4-year period. They found that 39 of the 1,700 patients receiving mechanical ventilation had BPFs lasting at least 24 h. Overall mortality in these 39 patients was 67%, and Pierson et al<sup>15</sup> found that mortality was higher when BPF developed late rather than early in the illness (94% vs 45%). Large air leaks also had significant mortality compared to smaller leaks. Pierson et al<sup>15</sup> concluded that the occurrence of BPF during mechanical ventilation identifies patients with high mortality but that unmanageable respiratory acidosis from this complication is rare.

Others<sup>14</sup> have reported mortality as high as 50%. However, reports<sup>27,28</sup> using omental and thoracic flaps have shown decreased mortality. In the study by Sirbu et al,<sup>3</sup> the mortality rate was 27.2% (6 of 22 patients).

#### TREATMENT

Treatment options of BPF include surgical procedures as well as medical therapy, and in particular the use of bronchoscopy and different glues, coils, and sealants. Success has been variable, and the lack of consensus suggests that no optimal therapy is available; rather, the current interventions seem to be complementary and that treatment should be individualized.

Bronchoscopy is indicated to exclude injury to the proximal airways. Initial nonoperative management focuses on decreasing the gradient between airway pressures and the pleural space. Mean airway pressure should be minimized, and if the lung remains fully inflated, suction on pleural tubes should be minimized.

Cooper and Miller<sup>29</sup> recommended a logical stepwise evaluation and management of these patients. The initial treatment is aimed to control any life-threatening condition. If there is a tension pneumothorax, emergent drainage is required. In the case of pulmonary flooding, airway control and postural drainage positioning the affected lung down are required. If a major bronchial stump dehiscence is suspected, immediate resuture and reinforcement are necessary.<sup>16,20,30</sup> Furthermore, these patients are often debilitated due to the underlying process, and therefore aggressive management of the underlying comorbidities and conditions that led to the BPF is mandatory. When infectious etiologies are present or empyema is suspected, adequate drainage of the

pleural space is mandatory along with proper antimicrobial coverage. Proper nutrition is required, frequently requiring enteral and/or parenteral feeding. Successful treatment of chronic BPF requires aggressive control of infection, adequate drainage of the chest cavity, closure of the fistula with vascularized tissue, and obliteration of the chest cavity.

### *Chest Tubes*

The use of chest tubes in the management of BPF has its potential benefits and complications. The negative effects of the chest tube (especially when mechanical ventilation is used) include the loss of tidal volume, abnormal gas exchange, and the appearance of ventilator cycling. In addition, the use of negative pressure to the chest tube potentially can increase the flow through the fistulous tract and interfere with closure and healing. Finally, the chest tube itself can function as a foreign body and predispose infection both at the insertion site and in the pleural space.<sup>31</sup>

The chest tube is indicated in patients with high-flow BPF and drainage of empyema. In addition, in patients receiving mechanical ventilation, the chest tube can be used to add positive intrapleural pressure during the expiratory phase or occlusion during the inspiratory phase. The goal of these interventions is to decrease the air leak during expiration in order to maintain positive end-expiratory pressure (PEEP) [with the former] and to decrease BPF flow during inspiration with the latter. These maneuvers have also been used in combination, and they may be particularly important in patients in which PEEP is required to maintain oxygenation (ARDS).<sup>32–34</sup>

The chest tube should be of sufficient diameter to allow drainage of the air leak. In this respect, a large diameter is necessary since flow varies exponentially to the fifth power of the radius of the tube (Fanning equation).<sup>35</sup> In addition, the chest tube can be used to apply sclerosing agents to promote pleurodesis (talc, bleomycin).

### *Mechanical Ventilation*

Mechanical ventilation may be required in patients and, as stated before, is an independent risk factor for the development of BPF in postsurgical patients or in patients with certain conditions (ARDS, COPD). The air escaping through the BPF not only delays healing of the fistulous tract, but because this is an area of low resistance, it accounts for a significant loss of tidal volume, jeopardizing the minute ventilation and oxygenation. The goal in promoting healing of the BPF has been the limitation of flow through the tract; this can be accomplished by limiting the amount of PEEP used during

ventilation, limiting the effective tidal volume, shortening the inspiratory time, and reducing the respiratory rate.<sup>32,36–38</sup> All of these maneuvers have as a goal reducing the airway pressure and therefore reducing fistula flow and loss of tidal volume. In addition, the use of selective intubation of the unaffected lung, the use of double-lumen intubation with differential lung ventilation, or the use of independent lung ventilation and patient positioning have been tried.<sup>32,36–39</sup> Carvalho et al<sup>40</sup> suggested that independent lung ventilation with two ventilators could sometimes be used in the management of BPF. They described a patient in whom gas flow through a large BPF was initially reduced, and subsequently eliminated, during differential lung ventilation using a single ventilator and a variable-resistance valve attached to one lumen of a bifurcated endotracheal tube.

The use of high-frequency ventilation (HFV) has been tried to overcome the limitations of conventional ventilation; however, reports have been conflicting. In general, HFV seems to be useful in patients with normal lung parenchyma and proximal BPF, while it is of limited value in patients with distal disease and parenchymal disease.<sup>39</sup> The reason for the failure in the latter group seems to be related to the disease process itself, rather than to actual failure of the HFV.<sup>41</sup> One study<sup>42</sup> reported the successful application of high-frequency oscillatory ventilation in a patient with tension pneumatocele. They proposed that a check-valve mechanism is responsible for the development of pneumatoceles and predicts that positive-pressure ventilation could lead to distension of these airspaces and formation of a tension pneumatocele. They suggest that HFV could be more applicable in conditions such as massive air leak due to BPF, which are difficult to manage by conventional ventilator modes.<sup>42</sup> Adjunctive interventions combining mechanical ventilation and chest tube manipulation have been described earlier.

### *Surgery*

The success rate of surgical closure of BPF has been reported between 80% and 95%<sup>27,28,43</sup> but is associated with the risk of open thoracotomy, although reported mortality has been as low as 0%.<sup>27,28,43</sup> Surgical closure includes chronic open drainage, direct stump closure with intercostal muscle reinforcement, omental flap, transsternal bronchial closure, and thoracoplasty with or without extrathoracic chest wall muscle transposition. Since the appearance of video-assisted thoracoscopy, this technique has been also used in attempts to treat BPF.

Turk et al<sup>4</sup> recommended a staged closure of

complicated BPF. In the first stage, the patients undergo an Eloesser procedure for chest cavity drainage consisting of a muscle flap operation with minimal morbidity in chronically ill patients. After this, the patients undergo aggressive nutritional and physical rehabilitation until they are able to tolerate the second procedure for chest cavity obliteration with an omental flap.<sup>4</sup>

In the series by Sirbu et al,<sup>3</sup> initial chest reexploration was performed in 91% of the cases. After debridement, the bronchial stump was reclosed by hand suture in 45%. All patients with a postlobectomy and sleeve resection BPF necessitated additional surgery: the BPF was additionally covered with a vascularized flap in 91% of the cases. In two patients (9%) because of poor overall condition, the initial treatment was endoscopic. In both cases, the fistula persisted and the stump had to be surgically resutured.<sup>3</sup> A description of the most common flaps and indications can be found in the articles by Stamatis et al<sup>27</sup> and Cooper and Miller.<sup>29</sup>

### Bronchoscopy

Initially used only for evaluation of the stump and for the exclusion of tuberculosis, flexible bronchoscopy has been gaining acceptance as a diagnostic and therapeutic modality in patients with BPF. The fiberoptic bronchoscope has been successfully used percutaneously to visualize the track of a bronchopleurocutaneous fistula.<sup>44</sup> BPF associated with pneumonectomy or lobectomy can be directly visualized, while distal BPF require the use of balloons to systematically occlude the bronchial segments to locate the one leading to the fistula.<sup>45-48</sup> Once the site is located, the application of sealant substances into the fistula have been tried. Regel et al<sup>47</sup> reported the use of the Swan-Ganz catheter (Edwards Laboratories; Santa Ana, CA) in the management of patients with distal fistulas. The balloon is used to localize the fistula, and with the balloon inflated the sealant material is passed through the distal port into the tract.<sup>47</sup> In order to successfully manage a BPF with bronchoscopic techniques, the fistula must be directly visualized or prove that occlusion significantly decreases or stops the air leak.

Multiple sealing compounds have been applied directly to the fistula through the bronchoscope. The potential success of this approach is that most of the leaks are peripheral or alveolar, rather than at the large airways. In addition, this offers an alternative to patients who are otherwise poor surgical candidates unable to tolerate a major thoracic procedure. All these studies are anecdotal or limited to a few patients, and there have been no controlled studies to determine which is the most effective or safest.

In 1977, Hartmann and Rausch<sup>49</sup> and Ratliff et al<sup>50</sup> reported the first successful endobronchial management of BPF using tissue glue and a lead shot, respectively. Since then, many reports using different devices have appeared. These include ethanol silver nitrate, cyanoacrylate compounds, coils, lead plugs, balloons, fibrin or tissue glue, antibiotics, gel foam, spigots, and autologous blood patch.

*Lead Shots:* As mentioned earlier, Ratliff et al<sup>50</sup> pioneered the endoscopic management of BPF by using a lead shot. He use a guidewire passed into the affected bronchus after its location with a balloon catheter. A sterilized fishing weight attached to a suture was passed over the guidewire and advanced with the bronchoscope until the leak stopped. The suture was used to retrieve the lead shot at a later session.

*Ethanol:* Five consecutive BPFs were successfully treated by Takaoka et al<sup>51</sup> by injecting absolute ethanol directly into the submucosal layer of a fistula under flexible bronchoscopy. No complications were found, and Takaoka et al<sup>51</sup> recommended it as a first-line therapy for patients with a postoperative central BPF with an orifice < 3 mm in diameter.

*Polyethylene Glycol:* FocalSeal-L (Focal; Lexington, MA), a water-soluble polyethylene glycol-based gel, comes as a polymer and sealant activated by a xenon-generated light in the spectrum of 440 to 550 nm. The light probe is to be held for 45 s approximately 2 cm from the area in which the sealant and polymer has been applied. Cross-linking of the compounds then occurs. Hoffberger et al<sup>52</sup> reported a case of a 72-year-old woman who acquired BPF after undergoing left-upper lobectomy for squamous cell carcinoma. Fiberoptic bronchoscopy revealed the presence of a 4-mm dehiscence in the bronchial closure representing a BPF. They instilled FocalSeal under direct visualization through the bronchoscope, and activated it using a helium cadmium laser (LIFE system; Xillix Technologies; Richmond, BC, Canada), which emits blue light at a wavelength of 442 nm with 150 mW of output.<sup>52</sup>

*Cyanoacrylate Glue:* Cyanoacrylate glues are one of the most common sealant compounds along with fibrin. They initially seal by acting as a plug, and later by inducing an inflammatory response that leads to fibrosis and mucosal proliferation, permanently sealing the defect. A catheter is introduced through the working channel and positioned near the fistula; the acrylate glue is then injected through the catheter into the fistula. The procedure can be repeated if

incomplete seal occurs. The cyanoacrylate glues polymerize into solid material on contact with body fluids or tissue. Iodized oils are used to delay polymerization. Usually, 0.5 to 1 mL are injected.<sup>49,53-57</sup>

**Fibrin Glue:** The diagnosis and closure of small postresection BPFs can be accomplished with selective bronchography and placement of fibrin sealant through the flexible fiberoptic bronchoscope. This technique has been reported to be successful in small BPFs and patients with multiple postresection bronchial stumps.<sup>58-63</sup> The fibrin glue is passed through a catheter located close to the BPF, and 1 mL of concentrated fibrinogen is injected followed immediately by 1 mL of topical thrombin (1,000 UI/mL). A fibrin clot forms over the fistula, sealing the leak. It is believed that the fibrin glue is eventually reabsorbed, preventing foreign body reaction.<sup>64</sup> Kinoshita et al<sup>62</sup> used fibrin glue that was diluted fourfold with saline solution and/or contrast medium, and performed pleurodesis with a large amount of the diluted fibrin glue in 40 high-risk patients with intractable pneumothorax and in 13 postthoracotomy patients with persistent air leakage associated with an intrapleural dead space. The air leaks were stopped by administration of the glue in all patients of both groups. During the follow-up period, a recurrence rate of 12.5% was observed in the former group. These recurrent pneumothoraces also were successfully treated by glue administration with no further recurrence. In the 13 postthoracotomy patients, there was no recurrence after the initial treatment. Pyrexia (12.5%) and chest discomfort (4.1%) were observed as side effects, but there were no findings of severe chest pain or thoracic empyema.<sup>62</sup> The fibrin glue can be instilled directly into the tract or injected directly into the submucosa.<sup>65</sup>

**Blood Clot:** Blood clot is based on a principle similar to that above.

**Antibiotics:** Martin et al<sup>66</sup> reported a patient with fulminant *S aureus* pneumonia complicated by chronic BPF formation, which prevented weaning from mechanical ventilation due to severe air leak. Successful fistula closure was obtained by endoscopic instillation of tetracycline into the fistula using a balloon catheter and blood clot occlusion technique.

Lan et al<sup>48</sup> reported a patient with BPF who was successfully treated by selective intrabronchial injection of doxycycline and blood under fiberoptic bronchoscopic guidance; they used 20 mg of doxycycline followed immediately by 15 mL of blood. Whether the success is due to the antibiotic or the blood patch

is unclear. In one report, Heffner et al<sup>67</sup> used 500 to 1,000 mg of doxycycline instilled through a chest tube in four patients with BPF. All four patients with persistent BPF had resolution of their air leaks; one patient had recurrence with a partial pneumothorax.

**Albumin-Glutaraldehyde Tissue Adhesive:** Potaris et al<sup>68</sup> reported the performance of an albumin-glutaraldehyde tissue adhesive (BioGlue; Cryolife; Kennesaw, GA) in the sealing of air leaks from pulmonary parenchyma and BPFs. They applied the BioGlue in 38 randomly selected patients who underwent 39 operations. A median of 5 mL of BioGlue was used per patient (range, 5 to 20 mL). The operations included thoracotomy (n = 36), video-assisted thoracoscopy (n = 2), and rigid bronchoscopy (n = 1). The duration of air leak ranged from 0 to 2 days (median, 1 day). The duration of total (air and fluid) chest tube drainage ranged from 1 to 12 days (median, 3 days). Complications were observed in three patients (8%): atelectasis (n = 1) and residual space (n = 2). Three patients died because of preexisting respiratory failure unrelated to BioGlue application. Hospitalization ranged from 4 to 16 days (median, 6 days) and was prolonged in some patients because of their primary disease (empyema, BPF). They concluded that the use of BioGlue proved to be safe and effective in the sealing of lung lacerations and in preventing air leakage from suture or staple lines in emphysematous lungs. It was also successful in sealing BPFs when applied either intrabronchially through the rigid bronchoscope or during thoracotomy.<sup>68</sup> Similar reports have been made by Iannetoni.<sup>69</sup>

**Cellulose:** There is at least one report<sup>70</sup> of successful use of oxidized regenerated cellulose (Surgicel; Ethicon; Piscataway, NJ) in the management of BPF.

**Gel Foam:** Gel foam has been used due to the theoretical advantages of availability and being totally reabsorbed. It is cut in small strips, moistened with normal saline solution, and flushed through the working channel of the bronchoscope into the affected area (or instilled directly through the rigid scope).<sup>71</sup>

**Coils:** Coils have been used alone or in conjunction with other sealants to treat BPF.<sup>42,72-74</sup> Angiographic occlusion coils placed endobronchially under fluoroscopic guidance succeeded in controlling a large parenchymal BPF after failure of surgical treatment and transbronchoscopic fibrin glue application as reported by Salmon et al.<sup>73</sup> Ponn et al<sup>74</sup> reported the use of Gianturco vascular occlusion



coils in five patients with complete or significant control of the leak without complications.

*Balloon Catheter Occlusion:* As mentioned earlier, balloon catheter occlusion is the method of choice to detect the site of air leak and place the sealant substance. However, the use of the balloon itself for the management of the BPF has been described.<sup>45</sup> In this report,<sup>45</sup> a 15-year-old boy acquired BPF as a complication of necrotizing pneumonia. A 5F atrial septostomy catheter was passed through the endobronchial tube under fluoroscopic guidance into the right and left segmental bronchi until the air leak stopped. The balloon was inflated with the smallest amount of diluted contrast media required to stop the air leak. After 1 month, the patient became stable and underwent surgery with three thoracotomies over a period of 6 weeks in which multiple BPFs were oversewn. However, the BPF recurred and the patient eventually died.

*Silver Nitrate:* Silver nitrate has been used through the rigid scope to seal stump leaks.<sup>75</sup>

*Calf Bone:* There is at least one report<sup>76</sup> in which calf bone was used along with fibrin glue to seal a BPF. In this case, the bone is shaped to the form of the fistula and sprayed with fibrin after insertion.

*Others:* There have been reports<sup>77,78</sup> on the use of surgical sponges and specially built endobronchial silicon spigots.

*Stents:* Stents have been extensively used mostly for the management of esophageal-to-airway fistulas, with malignancy being more common than the congenital or other acquired forms.<sup>76,79–83</sup> They are also indicated for the sealing of stump fistulas after pneumonectomy and dehiscence after bronchoplastic operations. The goal of the stent is to provide as tight seal in the airway as possible to prevent aspiration and pneumonias. Since there are many types of stents with different properties, the selection of a stent requires considering the type of lesion, its location, the physical characteristics of the stent, and its potential short-term and long-term complications.

## DISCUSSION

There are no controlled studies comparing the different sealants or comparing surgical and endoscopic therapy. In general, the endoscopic procedure is preferred in high-risk surgical candidates to avoid the risk of anesthesia and surgery. The only study<sup>65</sup> found to specifically address the value of broncho-

scopic sealing of BPFs was a retrospective study in which cases of 45 patients seen over a 13-year period with BPF after pneumonectomy (40 patients) or lobectomy (5 patients) were reviewed. In all of these cases, closure of the stump was performed with a mechanical stapler, and no routine mechanical ventilation was used. Outcomes studied included cure, death, chronic empyema with closed fistula, or chronic empyema with open fistula. All procedures were performed with rigid bronchoscopy under general anesthesia with jet ventilation. The fistula channel was de-epithelialized via laser, brushing, or diathermy prior to treatment. Visible leaks < 3 mm were treated with fibrin sealant. Fistulas > 3 mm were treated with fibrin and spongy calf bone. Fistulas > 8 mm were not considered suitable for endoscopic treatment, and those patients were excluded from the analysis. If successful, rinsing of the pleural cavity was performed with an antibiotic solution as dictated by the culture sensitivity. Bronchoscopic follow-up was performed on a weekly basis. If the occluding material was expectorated, immediate bronchoscopy was performed to reclose the fistula. Surgical intervention was considered when fistula size increased during endoscopic treatment, empyema developed, or there was progression to systemic sepsis. The surgical therapy was open window drainage or thoracoplasty (when the former was not possible). The overall rate of fistula closure was 35.6% (16 patients), and recurrence occurred in 2 patients (12.2%).

The average number of endoscopic interventions was 2.47 regardless of the outcome.<sup>1–7</sup> Size, interval, and number of therapeutic interventions showed no significant differences between the surgical and endoscopic groups. Although there was a marked tendency for more frequent cure of small and early fistulas compared to bigger and later ones, size and interval show no difference on the course of therapy.

Hospital mortality was 17.8%, and most of the patients died in the group treated only endoscopically.<sup>65</sup> The patients were in poor physical condition when first seen and were not surgical candidates. The authors<sup>65</sup> concluded that bronchoscopic treatment of BPF was an efficient alternative, especially when surgical intervention cannot be done because of the physical condition of the patient.

Baumann and Strange<sup>83</sup> investigated the practice habits among clinicians treating spontaneous pneumothorax and BPF using a randomized postal survey of 3,000 American College of Chest Physicians members. They found that significant differences exist between thoracic surgeons and pulmonologists approach to these problems, including the management of BPF.<sup>66</sup>

The current recommendations of the American

College of Chest Physicians expert panel<sup>26</sup> for the management of spontaneous pneumothorax states that for patients with persistent air leak:

Continue observation for 4 days to assess for spontaneous closure of bronchopleural fistula. If an air leak persists longer than 4 days, evaluate the patient for surgery to close the air leak and perform a pleurodesis procedure to prevent pneumothorax recurrence (Very Good Consensus). Thoracoscopy is the preferred management procedure (Very Good Consensus). Use of an additional chest tube or bronchoscopy in an attempt to seal endobronchial sites of air leakage is not indicated (Very Good Consensus). Except in special circumstances where surgery is contraindicated or a patient refuses surgery, chemical pleurodesis should not be used in the management of most patients (Very Good Consensus). If chemical pleurodesis is performed, doxycycline or talc slurry are the preferred sclerosing agents (Good Consensus).

In patients with secondary spontaneous pneumothorax and persistent air leaks, the same panel<sup>26</sup> stated:

For a patient with persistent air leaks and prolonged chest tube drainage who initially refuses surgery, continue observation for 5 days. After 5 days of observation, the patient should be urged to accept surgical intervention. More prolonged delay may limit the effectiveness of thoracoscopy. Instillation of sclerosing agents through a chest tube to produce a pleural symphysis in managing persistent air leaks is acceptable for patients who are not surgical candidates (Good Consensus).

## CONCLUSIONS

Clearly, further studies are required to establish the role of techniques and patient selection for endoscopic procedures, as well as which technique or combination will be most valuable. There are no established guidelines in the proper management of patients with BPF or even a consensus on how to approach the problem. Further research in these areas may shed light into the best therapy for this difficult problem.

### *A Possible Recommended Approach*

Use of manual sutures rather than mechanical stapling or a combination of the two seem to reduce the risk of BPF appearance. For unclear reasons, right-sided procedures are more prone to BPF. Detection of high-risk patients and possible delayed or alternative procedures until their condition is improved may reduce the risk. Once the BPF has developed, early recognition, drainage of the empyema, and management of the infectious process are critical. Prevention of complications (*ie*, aspiration and sepsis) and aggressive nutritional and rehabilitative support are needed. Diagnostic tools that may

be useful include nuclear scans and CT scans; bronchoscopic evaluation is beneficial as a diagnostic and therapeutic intervention in selected cases.

As noticed, all reported interventions consist of retrospective studies, individual cases, or personal experience with a few patients. Localization of the fistula and apparently size may indicate potential benefits of surgical vs endoscopic procedures. In high-risk surgical patients, endoscopic procedure may serve as a temporary bridge until the patient clinical status is improved. In other patients deemed nonsurgical candidates, the procedure may be the only option.

Based on the results of the above-mentioned studies, it is apparent that BPF size appears to be an important factor in predicting bronchoscopic outcome. BPFs > 8 mm are not suitable for endoscopic management, while those 1 mm in size have the highest success rate. Also, it seems that the time of appearance of the BPF plays a prognostic factor in further morbidity and mortality.

Distal small BPFs are more suitable for bronchoscopic therapy, while large or central BPFs are best managed with surgery or stent placement. If the BPF appears early after surgery, then reclosure is mandatory.

Apparently, a two-stage intervention may be the best approach for debilitated high-risk patients. In the first stage, an attempt to close or decrease the BPF via endoscopy is performed and the patient receives aggressive nutritional and rehabilitative support. Once the patient's clinical condition stabilizes, a definite surgical intervention may be accomplished. It seems that double stenting is the best approach for the management of esophagotracheal fistulas. This approach achieves the highest sealing effect, survival time, and quality of life.<sup>82</sup> If mechanical ventilation is required, HFV seems to be indicated in patients with otherwise normal lung parenchyma and proximal BPF; however, a trial of HFV should be tried in any patient not responding to conventional ventilation.

Finally, in terms of the "best sealant," there is no evidence to support one vs another compound or combination, and therefore the experience of the endoscopist with different compounds may dictate the choice. In selected cases, the use of stents may be all that is required.

## REFERENCES

- 1 McManigle JE, Fletcher GL, Tenholder MF. Bronchoscopy in the management of bronchopleural fistula. *Chest* 1990; 97:1235-1238
- 2 Cerfolio RJ. The incidence, etiology and prevention of post-resectional bronchopleural fistula. *Semin Thorac Cardiovasc Surg* 2001; 13:3-7

- 3 Sirbu H, Busch T, Aleksic I, et al. Bronchopleural fistula in the surgery of non-small cell lung cancer: incidence, risk factors and management. *Ann Thorac Cardiovasc Surg* 2001; 7:330–336
- 4 Turk AE, Karanas YL, Cannon W, et al. Stage closure of complicated bronchopleural fistulas. *Ann Plastic Surg* 2000; 45:560–564
- 5 al-Kattan K, Cattelani L, Goldstraw P. Bronchopleural fistula after pneumonectomy for lung cancer. *Eur J Cardiothorac Surg* 1995; 9:479–482
- 6 Conlan AA, Lukanich JM, Shutz J, et al. Elective pneumonectomy for benign lung disease: modern day mortality and morbidity. *J Thorac Cardiovasc Surg* 1995; 110:1118–1124
- 7 Sato M, Saito Y, Nagamoto N, et al. An improved method of bronchial stump closure for prevention of bronchopleural fistula in pulmonary resection. *Tohoku J Exp Med* 1992; 168:507–513
- 8 Williams NS, Lewis CT. Bronchopleural fistula: a review of 86 cases. *Br J Surg* 1976; 63:520–522
- 9 Abouasaleh R, Halaweh O, Pichurko B. Barrett's esophagitis-related bronchoesophageal fistula: the diagnostic value of persistent air leak in the ventilated setting [abstract]. *Chest* 2003; 124(suppl):265S
- 10 Ford MA, Mueller PS, Morgenthaler TI. Bronchoesophageal fistulae secondary to broncholithiasis: a case series. *Chest* 2003; 124(suppl):146S–147S
- 11 Richardson JV, George RB. Bronchopleural fistula and lymphocytic empyema due to *Histoplasma capsulatum*. *Chest* 1997; 112:1130–1132
- 12 Jenkins IR, Raymond R. Boerhaave's syndrome complicated by a large bronchopleural fistula. *Chest* 1994; 105:964–965
- 13 Tsou E, Yeager H Jr, Katz S. Late bronchopleural fistula and *Haemophilus influenzae* empyema complicating longstanding oleothorax: report of two cases. *Chest* 1978; 74:573–575
- 14 Malave G, Foster ED, Wilson JA, et al. Bronchopleural fistula: present day study of an old problem. *Ann Thorac Surg* 1971; 11:1–10
- 15 Pierson DJ, Horton CA, Bates PW. Persistent bronchopleural fistula air leak during mechanical ventilation: a review of 39 cases. *Chest* 1986; 90:321–323
- 16 Hankins JR, Miller JE, Attar S, et al. Bronchopleural fistula: 13 year experience with 77 cases. *J Thorac Cardiovasc Surg* 1978; 76:755–762
- 17 Sato M, Saito Y, Fujimura S, et al. Study of postoperative bronchopleural fistulas: analysis of factors related to bronchopleural fistulas. *Nippon Kyobu Geka Gekai Zasshi* 1989; 37:498–503
- 18 Sonobe M, Nawakagawa M, Ichinose M, et al. Analysis of risk factors in bronchopleural fistula after pulmonary resection for primary lung cancer. *Eur J Cardiothorac Surg* 2000; 18:519–523
- 19 Hsu JT, Bennett GM, Wolff E. Radiologic assessment of bronchopleural fistula with empyema. *Radiology* 1972; 103:41
- 20 Steiger Z, Wilson RF. Management of bronchopleural fistulas. *Surg Gynecol Obstet* 1984; 158:267–271
- 21 Zelefsky MN, Freeman LM, Stern H. A simple approach to the diagnosis of bronchopleural fistula. *Radiology*; 1977; 124:843
- 22 Schandevyl VW, Bossuyt RB. Demonstration of a bronchopleural communication by inhalation of Kr-81m gas. *Clin Nucl Med* 1981; 6:117–119
- 23 Nielsen KR, Blake LM, Mark JB, et al. Localization of bronchopleural fistula using ventilation scintigraphy. *J Nucl Med* 1994; 35:867–869
- 24 Ricci ZJ, Haramati LB, Rosebaum AT, et al. Role of computed tomography in guiding the management of peripheral bronchopleural fistula. *J Thorac Imaging* 2002; 17:214–218
- 25 Alifano M, Sepulveda S, Mulot A, et al. A new method for detection of postpneumonectomy broncho-pleural fistulas. *Ann Thorac Surg* 2003; 75:1662–1664
- 26 ACCP consensus panel. Management of spontaneous pneumothorax. *Chest* 2001; 119:590–602
- 27 Stamatis G, Freitag L, Wencker M, et al. Omentopexy and muscle transposition: two alternative methods in the treatment of pleural empyema and mediastinitis. *Thorac Cardiovasc Surg* 1994; 42:225–232
- 28 Hollaus PH, Huber M, Lax F, et al. Closure of bronchopleural fistula after pneumonectomy with pedicled intercostals muscle flap. *Eur J Cardiothorac Surg* 1999; 16:181–186
- 29 Cooper WA, Miller JJ. Management of bronchopleural fistula after lobectomy. *Semin Thorac Cardiovasc Surg* 2001; 13: 8–12
- 30 Baldwin JC, Mark JBD. Treatment of bronchopleural fistula after pneumonectomy. *J Thorac Cardiovasc Surg* 1985; 90: 813–817
- 31 Miller KS, Sahn SA. Chest tubes: indications, technique, management and complications. *Chest* 1987; 91:258–264
- 32 Downs JB, Chapman RL. Treatment of bronchopleural fistulas during continuous positive pressure ventilation. *Chest*; 1976; 69:363–366
- 33 Gallagher TJ, Smith RA, Kirby RR, et al. Intermittent inspiratory chest tube occlusion to limit bronchopleural cutaneous air leaks. *Crit Care Med* 1976; 4:328–332
- 34 Blanch PB, Koens JC Jr, Layon AJ. A new device that allows synchronous intermittent inspiratory chest tube occlusion with any mechanical ventilator. *Chest* 1990; 97:1426–1430
- 35 Swenson EW, Birath G, Ahbeck A. Resistance to airflow in bronchospirometric catheters. *J Thorac Surg* 1957; 33:275–281
- 36 Zimmerman JE, Colgan DL, Mills M. Management of bronchopleural fistula complicating therapy with positive expiratory pressure (PEEP). *Chest* 1973; 64:526–529
- 37 Ratliff JL, Hill JD, Tucker H, et al. Endobronchial control of bronchopleural fistulae. *Chest* 1977; 71:98–99
- 38 Phillips YY, Lonigan RM, Joyner LR. A simple technique for managing a bronchopleural fistula while maintaining positive pressure ventilation. *Crit Care Med* 1979; 7:351–353
- 39 Bauman MH, Sahn SA. Medical management and therapy of bronchopleural fistulas in the mechanically ventilated patient. *Chest* 1990; 97:721–728
- 40 Carvalho P, Thompson WH, Riggs R, et al. Management of bronchopleural fistula with a variable-resistance valve and a single ventilator. *Chest* 1997; 111:1452–1454
- 41 Carlon GC, Cole R, Klain M, et al. High frequency positive pressure ventilation in the management of a patient with bronchopleural fistula. *Anesthesiology* 1980; 52:160–162
- 42 Shen NH, Lu FL, Wu HW, et al. Management of tension pneumatocele with high-frequency oscillatory ventilation. *Chest* 2002; 121:184
- 43 Sabanathan S, Richardson J. Management of postpneumonectomy bronchopleural fistula. *J Cardiovasc Surg* 1994; 35:449–457
- 44 Chowdhury JK. Percutaneous use of fiberoptic bronchoscope to investigate bronchopleurocutaneous fistula. *Chest* 1979; 75:203–204
- 45 Ellis JH, Sequeira FW, Weber TR, et al. Balloon catheter occlusion of bronchopleural fistulae. *AJR Am J Roentgenol* 1982; 138:157–159
- 46 Mathew OP, Thatch BT. Selective bronchial obstruction for the treatment of bullous interstitial emphysema. *J Pediatr*; 1980; 96:475–477
- 47 Regel G, Sturm JA, Neumann C, et al. Occlusion of bron-

- chopleural fistula after lung injury: a new treatment by bronchoscopy. *J Trauma* 1989; 29:223–226
- 48 Lan R, Lee C, Tsai Y, et al. Fiberoptic bronchial blockade in a small bronchopleural fistula. *Chest* 1987; 92:944–946
  - 49 Hartmann W, Rausch V. A new therapeutic application of the fiberoptic scope [letter]. *Chest* 1977; 71:237
  - 50 Ratliff JL, Hill J, Tucker H, et al. Endobronchial control of bronchopleural fistula. *Chest* 1977; 71:98–99
  - 51 Takaoka K, Inoue S, Ohira S. Central bronchopleural fistulas closed by bronchoscopic injection of absolute ethanol. *Chest* 2002; 122:374–378
  - 52 Hoffberger DS, Walsh F, Sommers E, et al. Utilization of a synthetic absorbable sealant activated by helium cadmium laser bronchoscopy for successful closure of a persistent bronchopleural fistula following lobectomy. *Chest* 2003; 124:290S–S291
  - 53 Menard JW, Prejean CA, Tucker WY. Endoscopic closure of bronchopleural fistulas using a tissue adhesive. *Am J Surg* 1988; 155:415–416
  - 54 Roksvaag H, Skalleberg L, Nordberg C, et al. Endoscopic closure of bronchial fistula. *Thorax*: 1983; 38:696–697
  - 55 Torre M, Chiesa G, Ravini M, et al. Endoscopic gluing of bronchopleural fistula. *Ann Thorac Surg* 1987; 43:295–297
  - 56 Parthasarathi B. Bronchoscopic endobronchial sealing: a novel technique of treating bronchopleural fistula (BPF) [abstract]. *Chest* 2003; 124:147S
  - 57 Wood RE, Lacey SR, Azizkhan RG. Endoscopic management of large, postresection bronchopleural fistulae with methacrylate adhesive (Super Glue). *J Pediatr Surg* 1992; 27:201–202
  - 58 York EL, Lewall DB, Hirji M, et al. Endoscopic diagnosis and treatment of postoperative bronchopleural fistula. *Chest* 1990; 97:1390–1392
  - 59 Jessen C, Sharma P. Use of fibrin glue in thoracic surgery. *Ann Thorac Surg* 1985; 39:521–524
  - 60 Glover W, Chavis TV, Daniel TM, et al. Fibrin glue application through the flexible fiberoptic bronchoscope: closure of bronchopleural fistulas. *J Thorac Cardiovasc Surg* 1987; 93:470–472
  - 61 Onotera RT, Unruh HW. Closure of post-pneumectomy bronchopleural fistula with fibrin sealant. *Thorax*: 1988; 43:1015–1016
  - 62 Kinoshita T, Miyoshi S, Katoh M, et al. Intrapleural administration of a large amount of diluted fibrin glue for intractable pneumothorax. *Chest* 2000; 117:790–795
  - 63 Vietri F, Tosato F, Passaro U, et al. The use of human fibrin glue in fistulous pathology of the lung [in Italian]. *Giornale di Chirurgia* 1991; 12:399–402
  - 64 McCarthy PM, Trastek VF, Bell DG, et al. The effectiveness of fibrin glue sealant for reducing experimental pulmonary air leak. *Ann Thorac Surg* 1988; 45:203–205
  - 65 Hollaus PH, Lax F, Janakiev D, et al. Endoscopic treatment of postoperative bronchopleural fistula: experience with 45 cases. *Ann Thorac Surg* 1998; 66:923–927
  - 66 Martin WR, Siefkin AD, Allen R. Closure of a bronchopleural fistula with bronchoscopic instillation of tetracycline. *Chest* 1991; 99:1040–1042
  - 67 Heffner JE, Standerfer RJ, Torstveit J, et al. Clinical efficacy of doxycycline for pleurodesis. *Chest* 1994; 105:1743–1747
  - 68 Potaris K, Mihos P, Gakidis I. Preliminary results with the use of an albumin-glutaraldehyde tissue adhesive in lung surgery. *Med Sci Monit* 2003; 9:P179–P183
  - 69 Iannettoni JI. Closure of bronchopleural fistulas using albumin-glutaraldehyde tissue adhesive. *Ann Thorac Surg* 2004; 77:326–328
  - 70 Sprung J, Krasna MJ, Yun A, et al. Treatment of a bronchopleural fistula with a Fogarty catheter and oxidized regenerated cellulose (Surgicel). *Chest* 1994; 105:1879–1881
  - 71 Jones DP, David I. Gelfoam occlusion of peripheral bronchopleural fistulas. *Ann Thorac Surg* 1986; 42:334–335
  - 72 Islam SU, Beamis JF, Choi IS. Successful closure of a bronchopleural fistula with platinum vascular occlusion coils and N-Butyl-cyanoacrylate glue. *Chest* 2003; 124:292S–293S
  - 73 Salmon CJ, Ponn RB, Westcott JL. Endobronchial vascular occlusion coils for control of a large parenchymal bronchopleural fistula. *Chest* 1990; 98:233–234
  - 74 Ponn RB, D'Agostino RS, Stern H, et al. Treatment of peripheral bronchopleural fistulas with endobronchial occlusion coils. *Ann Thorac Surg* 1993; 56:1343–1347
  - 75 Hoier-Madse K, Schulze S, Pederson VM, et al. Management of bronchopleural fistula following pneumonectomy. *Scand J Thorac Cardiovasc Surg* 1988; 18:263–266
  - 76 Pridun N, Redl H, Schlag G. Ein neues biologisches Implantat zum Verschluss bronchopleuraler Fisteln. *Z Herz Thorax Gefaßchir* 1987; 1(suppl 1):60–62
  - 77 Miyazaki Y, Sakashita H, Tanaka T, et al. Bronchopleural fistula successfully treated with surgical sponge. *J Bronchol* 2001; 8:282–285
  - 78 Watanabe Y, Matsuo K, Tamaoki A, et al. Bronchial occlusion with endobronchial Watanabe spigot. *J Bronchol* 2003; 10:264–267
  - 79 Albes JM, Schafers HJ, Gebel M, et al. Tracheal stenting for malignant tracheoesophageal fistula. *Ann Thorac Surg* 1994; 57:1263–1266
  - 80 Witt C, Ortner R, Ewert R, et al. Multiple fistulas and tracheobronchial stenosis require extensive stenting of the central airways and esophagus in squamous-cell carcinoma. *Endoscopy* 1996; 28:381–385
  - 81 Colt HG, Meric B, Dumon JF. Double stents for carcinoma of the esophagus invading the tracheobronchial tree. *Gastrointest Endosc* 1992; 38:485–489
  - 82 Freitag L, Tekolf E, Steveling H, et al. Management of malignant esophagotracheal fistulas with airway stenting and double stenting. *Chest*: 1996; 110:1155–1160
  - 83 Baumann MH, Strange C. The clinician's perspective on pneumothorax management. *Chest* 1997; 112:822–828

**Bronchopleural Fistulas\***  
Manuel Lois and Marc Noppen  
*Chest* 2005;128; 3955-3965  
DOI 10.1378/chest.128.6.3955

**This information is current as of April 30, 2009**

<b>Updated Information &amp; Services</b>	Updated Information and services, including high-resolution figures, can be found at: <a href="http://www.chestjournal.org/content/128/6/3955.full.html">http://www.chestjournal.org/content/128/6/3955.full.html</a>
<b>References</b>	This article cites 81 articles, 49 of which can be accessed free at: <a href="http://www.chestjournal.org/content/128/6/3955.full.html#ref-list-1">http://www.chestjournal.org/content/128/6/3955.full.html#ref-list-1</a>
<b>Citations</b>	This article has been cited by 6 HighWire-hosted articles: <a href="http://www.chestjournal.org/content/128/6/3955.full.html#related-urls">http://www.chestjournal.org/content/128/6/3955.full.html#related-urls</a>
<b>Open Access</b>	Freely available online through CHEST open access option
<b>Permissions &amp; Licensing</b>	Information about reproducing this article in parts (figures, tables) or in its entirety can be found online at: <a href="http://www.chestjournal.org/site/misc/reprints.xhtml">http://www.chestjournal.org/site/misc/reprints.xhtml</a>
<b>Reprints</b>	Information about ordering reprints can be found online: <a href="http://www.chestjournal.org/site/misc/reprints.xhtml">http://www.chestjournal.org/site/misc/reprints.xhtml</a>
<b>Email alerting service</b>	Receive free email alerts when new articles cite this article. sign up in the box at the top right corner of the online article.
<b>Images in PowerPoint format</b>	Figures that appear in CHEST articles can be downloaded for teaching purposes in PowerPoint slide format. See any online article figure for directions.

