

# Acute Mesenteric Ischemia

## A Clinical Review

W. Andrew Oldenburg, MD; L. Louis Lau, MD; Thomas J. Rodenberg, MD; Hope J. Edmonds, MD; Charles D. Burger, MD

**A**cute mesenteric ischemia is a life-threatening vascular emergency that requires early diagnosis and intervention to adequately restore mesenteric blood flow and to prevent bowel necrosis and patient death. The underlying cause is varied, and the prognosis depends on the precise pathologic findings. Despite the progress in understanding the pathogenesis of mesenteric ischemia and the development of modern treatment modalities, acute mesenteric ischemia remains a diagnostic challenge for clinicians, and the delay in diagnosis contributes to the continued high mortality rate. Early diagnosis and prompt effective treatment are essential to improve the clinical outcome.

*Arch Intern Med.* 2004;164:1054-1062

Acute mesenteric ischemia (AMI) is a potentially fatal vascular emergency with overall mortality of 60% to 80%,<sup>1-5</sup> and its reported incidence is increasing.<sup>3</sup> Acute mesenteric ischemia comprises a group of pathophysiologic processes that have a common end point—bowel necrosis. The survival rate has not improved substantially during the past 70 years, and the major reason is the continued difficulty in recognizing the condition before bowel infarction occurs.<sup>1,6,7</sup>

Clinical presentation is nonspecific in most cases and can be characterized by an initial discrepancy between severe abdominal pain and minimal clinical findings. Physical examination does not reliably differentiate between ischemic and infarcted bowel. Complications such as ileus, peritonitis, pancreatitis, and gastrointestinal bleeding may also mask the initial signs and symptoms of AMI. The risk factors for AMI, and the clinical course, differ according to the underlying pathologic condition.<sup>6-9</sup> As bowel ischemia rapidly progresses to irreversible bowel necrosis, severe metabolic derangements ensue, leading to a series of events that culminate in multiple organ dysfunction and death. The timely use of di-

agnostic and therapeutic methods to quickly restore blood flow is the key to reducing the high mortality rate associated with AMI.<sup>2,5,7-10</sup>

### PATHOPHYSIOLOGIC PROCESSES

The splanchnic circulation receives approximately 25% of the resting and 35% of the postprandial cardiac output.<sup>11,12</sup> Seventy percent of the mesenteric blood flow is directed to the mucosal and submucosal layers of the bowel, with the remainder supplying the muscularis and serosal layers. The physiologic characteristics of splanchnic blood flow are complex and incompletely understood. Multiple major elements interact to provide the intestinal tract with an appropriate share of the blood supply, including the intrinsic (metabolic and myogenic) and the extrinsic (neural and humoral) regulatory systems.<sup>12,13</sup>

Pressure-flow autoregulation, reactive hyperemia, and hypoxic vasodilation are considered intrinsic controls and are responsible for instantaneous fluctuations in splanchnic blood flow. In the metabolic theory, oxygen delivery rather than blood flow causes adaptive changes in splanchnic circulation. An imbalance between tissue oxygen supply and demand will raise the concentration of local metabolites (eg, hydrogen, potassium, car-

*From the Section of Vascular Surgery (Drs Oldenburg and Lau), the Department of Critical Care (Dr Rodenberg), and the Divisions of Endocrinology (Dr Edmonds) and Pulmonary Medicine (Dr Burger), Mayo Clinic, Jacksonville, Fla. The authors have no relevant financial interest in this article.*

bon dioxide, and adenosine), resulting in vasodilation and hyperemia. In contrast, the myogenic theory suggests that arteriolar tension receptors act to regulate vascular resistance in proportion to transmural pressure. An acute decrease in perfusion pressure is compensated for by a reduction in arteriolar wall tension, thereby maintaining splanchnic blood flow.

The extrinsic neural component of splanchnic circulatory regulation comprises the  $\alpha$ -activated vasoconstrictor fibers. Intense activation of vasoconstrictor fibers through  $\alpha$ -adrenergic stimulation results in vasoconstriction of small vessels and a decrease in mesenteric blood flow. After periods of prolonged  $\alpha$ -adrenergic vasoconstriction, blood flow increases, presumably through  $\beta$ -adrenergic stimulation, which acts as a protective response. After cessation of  $\alpha$ -adrenergic stimulation, brief hyperemia makes the response triphasic. Although various types of neural stimulation (eg, vagal, cholinergic, histaminergic, and sympathetic) can affect the gut, the adrenergic limb of the autonomic nervous system is the predominant and possibly the sole neural influence on splanchnic circulation.

Numerous endogenous and exogenous humoral factors are capable of affecting the splanchnic circulation. Norepinephrine and high levels of epinephrine produce intense vasoconstriction through the stimulation of adrenergic receptors. Other pharmacologic compounds that decrease splanchnic blood flow include vasopressin, phenylephrine, and digoxin.<sup>14</sup> Low-dose dopamine causes splanchnic vasodilation, whereas higher doses lead to vasoconstriction by stimulating  $\alpha$ -adrenergic receptors. Papaverine, adenosine, dobutamine, fenoldopam mesylate, and sodium nitroprusside are exogenous agents that increase mesenteric blood flow. In addition, various naturally occurring agents can serve as splanchnic vasodilators, including acetylcholine, histamine, nitric oxide, leukotrienes, thromboxane analogues, glucagon, and an assortment of gastrointestinal hormones. The effects of prostaglandins are variable.

**Table 1. Physiologic and Pharmacologic Factors Regulating Mesenteric Blood Flow (Extrinsic Regulatory System)**

Decrease Blood Flow	Increase Blood Flow
<b>Humoral (Endogenous and Exogenous)</b>	
Epinephrine (high dose)	Epinephrine (low dose)
Norepinephrine (moderate to high dose)	Norepinephrine (low dose)
Dopamine (high dose)	Dopamine (low dose)
Phenylephrine	Dobutamine
Vasopressin	Sodium nitroprusside
Angiotensin II	Papaverine
Digoxin	Nitric oxide
<b>Neural</b>	
$\alpha$ -Adrenergic receptors	$\beta$ -Adrenergic receptors
Dopaminergic receptors	

In summary, the splanchnic circulation is regulated by a complex array of physiologic and pharmacologic factors (**Table 1**).

### REPERFUSION INJURY

Tissue damage due to alterations in mesenteric blood flow is often the result of cellular injury associated with reperfusion.<sup>15,16</sup> Brief periods of mesenteric ischemia lead to an increase in microvascular permeability, whereas prolonged ischemia leads to disruption of the intestinal mucosal barrier, primarily through the actions of reactive oxygen metabolites and polymorphonuclear neutrophils.

The role of oxygen free radicals in reperfusion injury is demonstrated by the reduction of tissue damage in the presence of antioxidants, xanthine oxidase inhibitors, and free-radical scavenging substances. Polymorphonuclear leukocytes contain enzymes that reduce molecular oxygen to superoxide anions and produce hypochloric acid, providing an additional source of reactive oxygen metabolites. Epithelial cells may produce xanthine oxidase-derived oxidants and initiate the production of proinflammatory agents that attract polymorphonuclear leukocytes.<sup>17</sup> In addition, phospholipase A<sub>2</sub> is activated during reperfusion, increasing the formation of cytotoxic lysophospholipids within the ischemic tissue and up-regulating the production of prostaglandins and leukotrienes.<sup>18</sup> Further understanding of the role of reperfusion injury may present opportunities for protective pharmaco-

logic therapies with agents such as captopril and carvedilol.<sup>19,20</sup> Carvedilol, a new  $\beta$ -adrenoreceptor blocking agent and a free-radical scavenger, has been demonstrated to have an antishock and endothelial-protective effect in a rat splanchnic ischemia reperfusion model.<sup>20</sup>

The degree of reduction in blood flow that the bowel can tolerate without activating these reperfusion mechanisms is remarkable. Only one fifth of the mesenteric capillaries are open at any given time, and normal oxygen consumption can be maintained with only 20% of maximal blood flow. When splanchnic blood flow is restored, oxygen extraction increases, providing relatively constant oxygen consumption over a wide range of blood flow rates.<sup>12</sup> However, when blood flow decreases below a threshold level, oxygen consumption is reduced and oxygen debt ensues.

### CAUSE

Acute mesenteric ischemia can be categorized into 4 specific types based on its cause (**Table 2**).

#### Arterial Embolism

Arterial emboli are the most frequent cause of AMI and are responsible for approximately 40% to 50% of cases.<sup>2,3</sup> Most mesenteric emboli originate from a cardiac source. Myocardial ischemia or infarction, atrial tachyarrhythmias, endocarditis, cardiomyopathies, ventricular aneurysms, and valvular disorders are risk factors for the development of mural thrombus, which can

**Table 2. Clinical Features of Acute Mesenteric Ischemia**

Cause	Incidence, %	Presentation	Risk Factors	Treatment
Arterial embolism	40-50	Acute catastrophe	Arrhythmia, myocardial infarction, rheumatic valve disease, endocarditis, cardiomyopathies, ventricular aneurysms, history of embolic events, recent angiography	Embolectomy, papaverine, excise infarction
Arterial thrombosis	25	Insidious onset with progression to constant pain	Atherosclerosis, prolonged hypotension, estrogen, hypercoagulability	Papaverine, thrombectomy, excise infarction, revascularization
Nonocclusive	20	Acute or subacute	Hypovolemia, hypotension, low cardiac output status, $\alpha$ -adrenergic agonists, digoxin, $\beta$ -receptor blocking agents	Treat cause first, papaverine, excise dead bowel
Venous thrombosis	10	Subacute	Right-sided heart failure, previous deep vein thrombosis, hepatosplenomegaly, primary clotting disorder, malignancy, hepatitis, pancreatitis, recent abdominal surgery or infection, estrogen, polycythemia, sickle cell disease	Thrombectomy, excise dead bowel, heparinize, long-term complication

subsequently embolize to mesenteric arteries.<sup>21</sup> Rarely, a mesenteric artery embolus can occur during or after angiography of the coronary or cerebral circulation. Most visceral arterial emboli preferentially lodge in the superior mesenteric artery (SMA) because it emerges from the aorta at an oblique angle. Whereas 15% of arterial emboli occur at the origin of the SMA, 50% lodge distally to the origin of the middle colic artery, which is the first major branch of the SMA.<sup>5,21</sup> Nearly one third of all patients with an SMA embolus have a history of an antecedent embolic event.

The onset of symptoms is usually dramatic as a result of the poorly developed collateral circulation, and it is characterized by the abrupt onset of severe abdominal pain associated with diarrhea, which may become bloody. Frequently, the diagnosis of SMA embolism can be made intraoperatively based on the distribution of ischemic bowel. Because most SMA emboli lodge distally to the origin of the middle colic artery, allowing the inferior pancreaticoduodenal branches to be perfused, the proximal jejunum is spared, whereas the rest of the small bowel is ischemic or infarcted.

#### Arterial Thrombosis

Acute mesenteric thrombosis accounts for 25% to 30% of all ischemic events.<sup>2-4,22</sup> Almost all mesenteric ischemia due to arterial thrombosis occurs in the setting of severe atherosclerotic disease, with the most

common site near the origin of the SMA.<sup>7</sup> Frequently, patients with this condition can tolerate major visceral artery obstruction because the slow progressive nature of atherosclerosis allows the development of important collaterals. Bowel ischemia or infarction ensues when the last remaining visceral artery or an important collateral artery occludes. The extent of bowel ischemia or infarction is typically greater than that with embolism, extending from the duodenum to the transverse colon. Perioperative mortality ranges from 70% to 100%,<sup>3,4,22</sup> in part because of the delay in diagnosis, the extensive nature of the bowel ischemia-infarction, and the need for more complex surgical revascularization.

#### Nonocclusive Mesenteric Ischemia

Approximately 20% of patients with mesenteric ischemia have nonocclusive disease.<sup>8,23</sup> The pathogenesis of nonocclusive mesenteric ischemia (NOMI) is poorly understood but often involves a low cardiac output state associated with diffuse mesenteric vasoconstriction. Splanchnic vasoconstriction in response to hypovolemia, decreased cardiac output, hypotension, or vasopressors best explain the difference between this entity and other forms of AMI. The resultant low-flow state causes intestinal hypoxia and necrosis. Endogenous and exogenous vasoconstrictors, disseminated intravascular coagulation, and

reperfusion injury may also contribute. Vasoactive drugs, particularly digoxin, have been implicated in the pathogenesis of NOMI. Digitalis preparations induce contraction of splanchnic venous and arterial vascular smooth muscle *in vitro* and *in vivo*.<sup>14</sup> Watershed areas of circulation are more vulnerable in NOMI.

Conditions predisposing to NOMI include age older than 50 years, myocardial infarction, congestive heart failure, aortic insufficiency, cardiopulmonary bypass, renal or hepatic disease, and major abdominal or cardiovascular surgery. However, patients may not have any clear risk factors.<sup>10,23</sup> Because this condition frequently affects critically ill patients who have considerable comorbidities, the onset may be insidious, and the mortality rates are high. Between 1960 and 1980, because of the frequent use of vasopressors in cardiac patients, mortality was nearly 100%. With increasing use of afterload-reducing agents and vasodilators, the mortality rate associated with NOMI has declined.

An unusual form of nonocclusive ischemia has been described in patients who have undergone the stress of a surgical procedure or trauma and are receiving enteral nutrition in intensive care units.<sup>24</sup> The reported incidence of AMI in these patients is 0.3% to 8.5%. The proposed mechanism is an imbalance between demand (created by the enteral feedings) and supply (decreased by systemic hypoperfusion and mesenteric vasoconstriction). Most pa-

tients manifest signs of sepsis, with abdominal distention as a late clinical sign. Survival is poor (56%).

### Mesenteric Venous Thrombosis

Mesenteric venous thrombosis (MVT) is the least common cause of mesenteric ischemia, representing up to 10% of all patients with mesenteric ischemia and 18% of those with AMI. In the past, most cases were thought to be secondary to other intra-abdominal pathologic conditions (such as malignancy, intra-abdominal sepsis, or pancreatitis) or were classified as idiopathic. With improved diagnostic techniques, more cases have been shown to be related to primary clotting disorders, with only 10% of cases now being classified as idiopathic.<sup>3,25,26</sup>

Mesenteric venous thrombosis is usually segmental, with edema and hemorrhage of the bowel wall and focal sloughing of the mucosa. Thrombi usually originate in the venous arcades and propagate to involve the arcuate channels. Hemorrhagic infarctions occur when the intramural vessels are occluded. The thrombus is usually palpable in the superior mesenteric vein.<sup>27</sup> Involvement of the inferior mesenteric vein and large bowel is uncommon. The transition from normal to ischemic intestine is more gradual with venous embolism than with arterial embolism or thrombosis.

Mortality depends on the type of MVT (acute vs chronic) and the extent of venous involvement. Patients with acute disease with involvement of the superior mesenteric or portal vein have a 30-day mortality approaching 30%. Long-term survival is 30% to 40% in patients with acute MVT compared with at least 80% in those with the chronic form.<sup>26</sup>

### PRESENTATION

Many of the signs and symptoms associated with AMI are common to other intra-abdominal pathologic conditions, such as pancreatitis, acute diverticulitis, small-bowel obstruction, and acute cholecystitis. In addition, the clinical presentation often depends on the underlying pathologic abnormalities. In gen-

eral, patients with SMA embolism or thrombosis have an acute onset of symptoms and a rapid deterioration in their clinical condition, whereas those with NOMI or MVT have a more gradual onset and a more protracted clinical course.

With SMA embolism, the onset of symptoms is usually dramatic because of lack of collateral circulation, and it manifests as severe and unrelenting abdominal pain, nausea, vomiting, and urgent bowel evacuation. Classically, the severity of abdominal pain is out of proportion to the physical findings. Dehydration and excessive fluid loss from third-spacing of fluid lead to mental confusion, tachycardia, tachypnea, and circulatory collapse. Laboratory findings include metabolic acidosis with elevated anion gap and lactate levels, leukocytosis, and hemoconcentration.

Patients with SMA thrombosis frequently report a prodromal symptom complex of postprandial pain, nausea, and weight loss associated with chronic intestinal insufficiency.<sup>3,24</sup> Patients with a subacute onset tend to seek medical care much later than those with arterial emboli.<sup>2,27</sup> However, when ischemia from mesenteric thrombosis becomes acute, patients present similarly to those who have acute SMA embolism.

Nonocclusive mesenteric ischemia occurs most frequently in elderly, critically ill patients and in those with severe mesenteric atherosclerosis in the setting of an acute hemodynamic insult. Such patients are often intubated and sedated and, therefore, are unable to alert the clinician to their symptoms. In these circumstances, the intestinal ischemia may not become clinically evident until hours or days after the initial hemodynamic insult. This is particularly important in cases of severe hypotension treated with  $\alpha$ -adrenergic agonists. The hemodynamic insult and its treatment predispose the patient to NOMI. These patients frequently experience unexplained worsening in their clinical condition or a failure to thrive or to follow their anticipated recovery course.

Except in the most fulminant cases, patients with MVT typically

present late (ie, 1-2 weeks after onset), complaining of diffuse, nonspecific abdominal pain associated with anorexia and diarrhea. If the pain is localized, it is most often in the lower quadrants. Compared with arterial thrombosis, MVT generates fewer prodromal symptoms with eating or postprandial pain. Fever, abdominal distention, and Hemocult-positive stool samples are the most common findings. Bloody ascites and large fluid losses with third-spacing may occur, leading to dehydration and hypotension, causing further propagation of the venous thrombosis and worsening of the mesenteric ischemia.

The final common pathway of all the specific causes of mesenteric ischemia is bowel infarction. When infarction occurs, the patient has peritoneal signs, hemodynamic instability, and signs of sepsis with multiorgan failure.

### DIAGNOSIS

Because AMI may proceed to fatal intestinal infarction rapidly, prompt diagnosis and treatment are paramount. A high index of suspicion in the setting of a compatible history and physical examination serves as the cornerstone to early diagnosis of mesenteric ischemia.<sup>5,7,22</sup> Once it is suspected, the clinician should act promptly to confirm the diagnosis and initiate appropriate treatment. Acute mesenteric ischemia should particularly be considered in the differential diagnosis when a patient is older than 60 years; has a history of atrial fibrillation, recent myocardial infarction, congestive heart failure, arterial emboli, or postprandial abdominal pain and weight loss; and is initially seen for abdominal pain that is out of proportion to that suggested by physical examination. Survival is approximately 50% when diagnosis occurs within 24 hours after onset of symptoms, but it drops sharply to 30% or less when diagnosis is delayed.<sup>21</sup>

The most common laboratory abnormalities are hemoconcentration, leukocytosis, and metabolic acidosis, with high anion gap and lactate concentrations. High levels of serum amylase, aspartate aminotransferase, lactate dehydrogenase,

and creatine phosphokinase are frequently observed at presentation, but none is sufficiently sensitive or specific to be diagnostic. Hyperphosphatemia and hyperkalemia are usually late signs and are frequently associated with bowel infarction.<sup>28</sup>

The findings on a plain abdominal radiograph in AMI are also nonspecific.<sup>5,6,29-31</sup> In the early stage of the disease, 25% of patients may have normal findings on abdominal radiography. Characteristic radiographic abnormalities, such as thumbprinting or thickening of bowel loops, occur in less than 40% of patients at presentation. Air in the portal vein is a late finding and is associated with a poor prognosis.<sup>30</sup> As with the laboratory tests, the value of plain abdominal radiography is to exclude other diagnoses, such as intestinal obstruction or a perforated viscus.

Barium enema has no place in the diagnosis of AMI. The introduction of barium and air may increase intraluminal pressure, causing reduced perfusion to the bowel wall, translocation of bacteria, and, potentially, perforation. In addition, the presence of barium may compromise subsequent diagnostic tests, such as computed tomography (CT) and angiography. Rarely, the barium enema can be useful in the diagnosis of colonic ischemia, but it has essentially been replaced by flexible sigmoidoscopy or colonoscopy.<sup>31</sup>

Recent interest in CT for the diagnosis of AMI has resulted in several studies describing thickened bowel walls, intramural hematoma, dilated fluid-filled bowel loops, engorgement of mesenteric vessels, pneumatosis, mesenteric or portal venous gas, infarction of other viscera, and arterial or venous thrombus.<sup>32-34</sup> Abdominal CT has poor sensitivity and specificity in the diagnosis of most types of AMI. Dynamic contrast-enhanced CT may improve sensitivity to 64% and specificity to 92%.<sup>35</sup> Multislice technology has recently been introduced for CT angiography, and this may further improve the results of CT angiography in AMI.<sup>36</sup> Computed tomography is more sensitive in diagnosing venous thrombus than other types of AMI and is the investigation of choice in suspected cases of MVT.<sup>26,37</sup> Thus, along with the

plain abdominal radiograph, CT should be considered complementary but rarely diagnostic.

In the absence of a clinical indication for emergency laparotomy, mesenteric angiography remains the investigation of choice in suspected AMI. Early angiography has been shown to improve survival rates.<sup>21,27,38</sup> Furthermore, angiography coupled with the plain abdominal radiograph reveals the cause of abdominal pain in 25% to 40% of patients who do not have mesenteric ischemia.

Angiography must be biplanar.<sup>27</sup> The anteroposterior view is best for demonstrating the distal mesenteric blood supply and collaterals. Lateral aortography is better for visualizing the origins of major visceral arteries that overlay the aorta in the anteroposterior plane.

Mesenteric angiography can usually differentiate embolic from thrombotic arterial occlusions. Emboli usually lodge where the artery tapers, which is just after the first major branch of the SMA—the middle colic artery. In contrast, thrombotic disease usually involves the origin of the SMA. Thrombotic cases may be characterized by a complete lack of visualization of the SMA origin on the lateral aortogram, with delayed anteroposterior views showing prominent collateral vessels. Mesenteric venous thrombosis is characterized by a generalized slowing of arterial flow (up to 20 seconds) in conjunction with lack of opacification of the corresponding mesenteric or portal venous outflow tracts. This is usually segmental, in contrast to NOMI, which is diffuse and shows normal venous runoff. In addition, NOMI characteristically shows narrowing and multiple irregularities of the major SMA tributaries, the “string of sausages” sign. Venous occlusion and NOMI may show contrast material refluxing back into the aorta on selective SMA angiography.

Various other diagnostic methods and approaches have been used in the evaluation of AMI, but their use is limited by their low negative predictive value. Clinicians must be aware that undue delay caused by insensitive and nonspecific diagnostic techniques may worsen patient

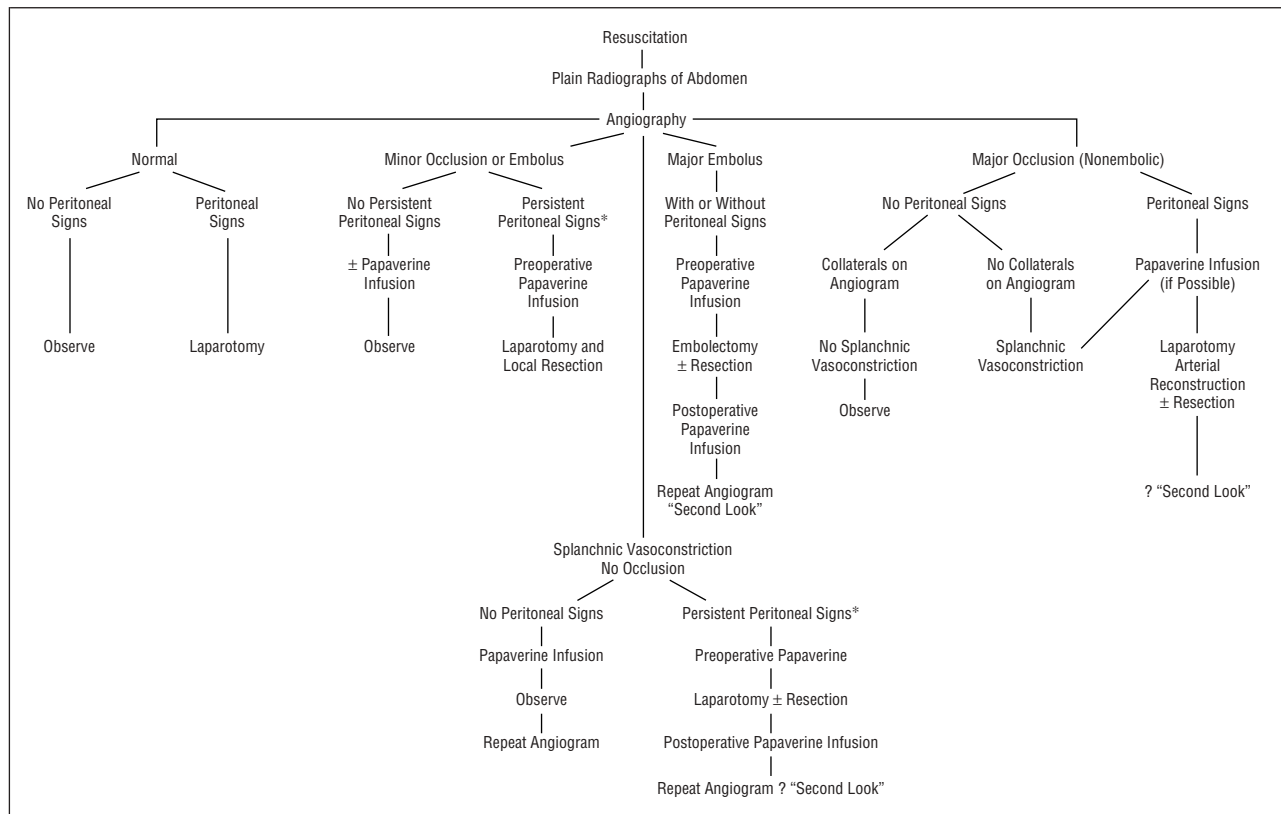
outcome.<sup>27</sup> Other methods that have been investigated include lower gastrointestinal tract endoscopy, peritoneal fluid analysis, radionuclide imaging, Doppler ultrasonography, magnetic resonance imaging, and peritoneoscopy.

Endoscopy has been used to diagnose ischemic colitis; however, it does not visualize much of the small bowel, which is frequently involved in AMI. In addition, endoscopy may not have adequate sensitivity and specificity in detecting ischemic changes (rather than infarction). Although peritoneal fluid analysis may yield abnormal results (elevated white blood cell counts and phosphate, lactate dehydrogenase, and lactate levels) in mesenteric ischemia, its role in the diagnosis of AMI is neither well studied nor widely accepted.<sup>25,39</sup> Radionuclide imaging has been used to identify infarcted bowel in animals, but clinical studies in humans have yet to be performed. Doppler ultrasonography has been used to detect a significant stenosis (>50%) in the mesenteric vessels in patients with chronic mesenteric arterial occlusive disease, but its role in AMI seems limited.<sup>40-43</sup> Magnetic resonance imaging has shown promise in detecting altered flows in the superior mesenteric vessels in chronic ischemia, but its reliability has not been documented in controlled trials.<sup>44,45</sup> The relatively long time needed by most medical centers for scheduling and performing magnetic resonance imaging has made its use impractical in this rapidly progressive disorder.

Peritoneoscopy may also be a useful tool for investigating AMI due to venous thrombosis.<sup>26</sup> Serosanguineous fluid in the abdominal cavity of an older patient with abdominal pain, hemoconcentration, and leukocytosis is strongly suggestive of MVT.

## TREATMENT

Once the diagnosis of AMI is made, treatment should be initiated without delay. This should include active resuscitation and treatment of the underlying condition, with efforts directed toward reducing the associated vasospasm, preventing propagation of the intravascular clotting process, and minimizing the



Schema for the diagnosis and treatment of patients at risk of acute mesenteric ischemia. Emergency laparotomy may be justified without angiography when the clinical suggestion of bowel ischemia is high. Asterisk indicates that peritoneal signs are considered persistent if they are not relieved within 30 minutes of receiving a dose of tolazoline.

reperfusion injury. An algorithm summarizing treatment procedures is shown in the **Figure**.

Intravenous fluid resuscitation with crystalloids and blood products should be started promptly to correct the volume deficit and metabolic derangement. Placement of a Swan-Ganz catheter may be required for judicious fluid resuscitation and hemodynamic monitoring, especially in critically ill patients. Ideally, fluid resuscitation should begin before angiography, and crystalloids may be administered in amounts as high as 100 mL/kg. Supranormalization of hemodynamic values has been attempted, with equivocal results, and it remains to be proven whether such an approach offers an advantage to patients with AMI.<sup>46-48</sup> Broad-spectrum antibiotics should be given as early as possible.

If there are no contraindications to anticoagulation, therapeutic intravenous heparin sodium should be administered to maintain the activated partial thromboplastin time at twice the normal value. Af-

ter the patient's hemodynamic condition has been optimized and anticoagulation therapy has been initiated, efforts should aim at reducing the mesenteric vasospasm. If the diagnosis of AMI is made without the use of mesenteric arteriography, intravenous glucagon infused initially at 1 µg/kg per minute and titrated up to 10 µg/kg per minute as tolerated may help reduce the associated vasospasm. When angiography is used to establish the diagnosis, the angiographic catheter should be left in the SMA for infusions of papaverine or other vasodilators. Papaverine, a phosphodiesterase inhibitor, increases mesenteric blood flow to marginally perfused tissues and may considerably improve bowel salvage. The usual dose is 30 to 60 mg/h. Papaverine use is recommended in cases of arterial embolic or nonocclusive disease because in both conditions the arterial vasospasm persists even after successful treatment of the precipitating event.<sup>3,5,7,27</sup>

The presence of peritoneal signs generally indicates bowel infarction rather than ischemia alone and

mandates emergency laparotomy. Even in the absence of bowel necrosis, surgical procedures are generally required, except in NOMI, in which the management is primarily medical. Therapeutic improvement during preoperative resuscitation may offer a false sense of security, but bowel infarction, sepsis, and multiple organ failure usually follow unless laparotomy, revascularization, and excision of infarcted bowel segments are performed. Visceral revascularization (embolectomy, thrombectomy, endarterectomy, or bypass) should precede bowel resection in almost all patients with occlusive AMI.

For acute mesenteric embolism, a standard embolectomy via a transverse arteriotomy in the proximal SMA should be performed.<sup>3,5,10,27</sup> After embolectomy, the arteriotomy is closed primarily with interrupted nonabsorbable sutures (polypropylene). If the cause of an acute mesenteric embolism is in doubt or if SMA thrombosis is suspected, then a longitudinal arteriotomy is preferred. With this ap-

proach, if a bypass is necessary, the longitudinal arteriotomy can be used as the site for the distal bypass graft anastomosis. If flow is adequately restored without a bypass, then the longitudinal arteriotomy can be closed by patch angioplasty to ensure that the luminal diameter is not compromised.

For AMI from arterial thrombosis due to atherosclerotic disease, a vascular bypass graft is usually necessary. The graft can originate from the infrarenal or supraceliac aorta. To avoid potential intra-abdominal contamination from perforated, infarcted bowel, revascularization should be performed using an autologous vein.

As in embolic disease, revascularization should be performed first, with subsequent resection of clearly nonviable bowel. This allows preservation of potentially viable gut and reduces the possibility of creating a "short-gut syndrome." If the adequacy of perfusion to the bowel is in question, the ends of the bowel may be brought out as stomas. Although nonspecific, the presence of arterial pulsations and the return of bowel peristalsis and normal bowel color suggest intestinal viability.

Visual examination of the exterior of the bowel is unreliable, especially in cases of NOMI, in which the serosa may appear viable despite the presence of infarcted mucosa. The use of intravenous fluorescein and inspection under a Wood lamp has been shown to be more sensitive and specific, but this method is not widely accepted.<sup>49,50</sup> Uniform uptake of fluorescein generally suggests bowel viability. Patchy uptake suggests questionable bowel viability, and these segments are better left in situ, with a plan for a "second-look" operation. Doppler ultrasonography is an alternative and may be used intraoperatively, but studies have not demonstrated any advantage over clinical judgment in assessment of bowel viability.<sup>51</sup>

Effective treatment of NOMI largely depends on the underlying cause. Initial therapy should aim at removing the offending stimulus and correcting the underlying medical condition. Logically, any infarcted bowel must be resected. Vasodilators, anticoagulation, and mesen-

teric regional blockade have been used in cases in which infarction has not yet occurred. Occasionally, direct transcatheter infusion of papaverine into the SMA restores normal blood flow within minutes. However, patients with NOMI have fewer treatment options than those with other forms of AMI because the offending stimulus often originates from the necessary treatment of another disorder. Unless the original provocation or insult is reversed, mortality in NOMI is similar to that in other forms of AMI.

Treatment of MVT is somewhat controversial and depends on the extent of intestinal ischemia. Patients without evidence of bowel infarction often recover spontaneously without operative intervention, and many are treated with anticoagulation alone. The presence of peritoneal signs necessitates emergency laparotomy. Infarcted bowel should be widely resected. Postoperatively, recurrence and progression of thrombosis are common. Heparinization has been shown to reduce the recurrence of thrombosis from 26% to 14% and mortality from 59% to 22%.<sup>25,26</sup> For acute main superior mesenteric vein or portal vein thrombosis, a thrombectomy may be beneficial. Cases of successful treatment with intravascular thrombolytic agents have also been reported.<sup>52-54</sup> However, thrombolysis is contraindicated when bowel infarction is suspected. After initial treatment of the acute event, the possibility of thrombophilia should be investigated. If a prothrombotic condition is detected, long-term warfarin therapy may be necessary.

Even when the primary operation is successful, the intraoperative assessment of bowel viability is often inaccurate, and few reliable signs are available to detect persistent ischemia or developing infarction in the postoperative period. For this reason, a second-look laparotomy after 24 to 48 hours is usually recommended.<sup>3,5,55</sup> The rationale for this second look is based in part on the frequent occurrence of vasospasm after revascularization. Second-look laparoscopy has been advocated as a substitute for second-look laparotomy, but the reliability of this approach remains unproved.<sup>56,57</sup>

Postoperatively, patients treated for AMI are invariably critically ill. Metabolic acidosis and hyperkalemia should be aggressively corrected. Persistent acidosis, especially in the absence of renal failure, should raise concerns about ongoing uncorrected bowel ischemia or infarction. Adequate volume resuscitation is essential to avoid persistent mesenteric hypoperfusion. The mesenteric capillary leak syndrome after mesenteric revascularization is well recognized. Frequently, patients with this condition require 10 to 20 L of crystalloid resuscitation during the first 24 to 48 hours after surgery.

After successful revascularization, efforts should be directed toward limiting any reperfusion injury that may cause progressive mesenteric ischemia or infarction. If the patient's hemodynamic condition allows, infusion of vasodilators should be considered (intravenous glucagon or intra-arterial papaverine). The use of allopurinol, angiotensin-converting enzyme inhibitors, and other free oxygen scavengers may help reduce the reperfusion syndrome.

Sepsis and multiple organ dysfunction syndromes occur in many patients with AMI.<sup>58</sup> The presentation and management of such complications are similar to those of complications from other causes; however, the use of vasopressors may worsen ischemia in marginally viable bowel and exacerbate the condition. Vasopressor options include dopamine (3-8 µg/kg per minute) and epinephrine (0.05-0.10 µg/kg per minute); pure α-adrenergic agents should be avoided, if possible.

## PROGNOSIS

Perioperative mortality in patients undergoing revascularization for AMI ranges from 44% to 90%.<sup>59</sup> Published data on long-term results after successful revascularization are few, and, in general, prognosis is not as favorable as that for patients with chronic mesenteric ischemia. Recurrence is not uncommon, and it carries a poor prognosis. A small proportion of patients survive massive bowel resection and develop short-

gut syndrome, requiring long-term total parenteral alimentation or small-bowel transplantation.

## CONCLUSIONS

Acute mesenteric ischemia is a challenging clinical problem with diverse causes, which often results in delayed diagnosis and treatment. A strong clinical suspicion and an aggressive approach should be adopted in dealing with this condition because the outcome crucially depends on rapid diagnosis and treatment. With better understanding of the pathogenesis of AMI and the availability of a range of diagnostic and interventional techniques and adjuvant pharmacotherapies, an improved outcome can be achieved.

Accepted for publication June 30, 2003.

Corresponding author and reprints: W. Andrew Oldenburg, MD, Section of Vascular Surgery, Mayo Clinic, 4500 San Pablo Rd, Jacksonville, FL 32224 (e-mail: oldenburg.warner@mayo.edu).

## REFERENCES

- Heys SD, Brittenden J, Crofts TJ. Acute mesenteric ischaemia: the continuing difficulty in early diagnosis. *Postgrad Med J*. 1993;69:48-51.
- Lock G. Acute intestinal ischaemia. *Best Pract Res Clin Gastroenterol*. 2001;15:83-98.
- Bradbury AW, Brittenden J, McBride K, Ruckley CV. Mesenteric ischaemia: a multidisciplinary approach. *Br J Surg*. 1995;82:1446-1459.
- Sitges-Serra A, Mas X, Roqueta F, Figueras J, Sanz F. Mesenteric infarction: an analysis of 83 patients with prognostic studies in 44 cases undergoing a massive small-bowel resection. *Br J Surg*. 1988;75:544-548.
- Stoney RJ, Cunningham CG. Acute mesenteric ischemia. *Surgery*. 1993;114:489-490.
- Clark ET, Gerwitz BL. Mesenteric ischemia. In: Hall JB, Schmidt GA, Wood LD, eds. *Principles of Critical Care*. New York, NY: McGraw-Hill Co; 1998:1279-1286.
- Kaleya RN, Boley SJ. Acute mesenteric ischemia: an aggressive diagnostic and therapeutic approach: 1991 Roussel Lecture. *Can J Surg*. 1992;35:613-623.
- Wilcox MG, Howard TJ, Plaskon LA, Unthank JL, Madura JA. Current theories of pathogenesis and treatment of nonocclusive mesenteric ischemia. *Dig Dis Sci*. 1995;40:709-716.
- Berney T, Morales M, Broquet PE, Mentha G, Morel P. Risk factors influencing the outcome of portal and mesenteric vein thrombosis. *Hepatogastroenterology*. 1998;45:2275-2281.
- Vicente DC, Kazmers A. Acute mesenteric ischemia. *Curr Opin Cardiol*. 1999;14:453-458.
- McFadden DW, Rongione AJ. Intestinal circulation and vascular disorders. In: Miller TA, ed. *Modern Surgical Care: Physiologic Foundation & Clinical Applications*. 2nd ed. St Louis, Mo: Quality Medical Publishing; 1998:443-463.
- Granger DN, Richardson PD, Kviety PR, Mortilaro NA. Intestinal blood flow. *Gastroenterology*. 1980;78:837-863.
- Hansen MB, Dresner LS, Wait RB. Profile of neurohumoral agents on mesenteric and intestinal blood flow in health and disease. *Physiol Res*. 1998;47:307-327.
- Mikkelsen E, Andersson KE, Pedersen OL. Effects of digoxin on isolated human mesenteric vessels. *Acta Pharmacol Toxicol (Copenh)*. 1979;45:25-31.
- Schoenberg MH, Beger HG. Reperfusion injury after intestinal ischemia. *Crit Care Med*. 1993;21:1376-1386.
- Zimmerman BJ, Grisham MB, Granger DN. Role of oxidants in ischemia/reperfusion-induced granulocyte infiltration. *Am J Physiol*. 1990;258:G185-G190.
- Zimmerman BJ, Granger DN. Reperfusion-induced leukocyte infiltration: role of elastase. *Am J Physiol*. 1990;259:H390-H394.
- Koike K, Moore EE, Moore FA, Read RA, Carl VS, Banerjee A. Gut ischemia/reperfusion produces lung injury independent of endotoxin. *Crit Care Med*. 1994;22:1438-1444.
- Buyukgebiz O, Aktan AO, Yegen C, et al. Captopril increases endothelin serum concentrations and preserves intestinal mucosa after mesenteric ischemia-reperfusion injury. *Res Exp Med (Berl)*. 1994;194:339-348.
- Christopher TA, Lopez BL, Yue TL, Feuerstein GZ, Ruffolo RR Jr, Ma XL. Carvedilol, a new beta-adrenoreceptor blocker, a vasodilator and free-radical scavenger, exerts an anti-shock and endothelial protective effect in rat splanchnic ischemia and reperfusion. *J Pharmacol Exp Ther*. 1995;273:64-71.
- Boley SJ, Feinstein FR, Sammartano R, Brandt LJ, Sprayregen S. New concepts in the management of emboli of the superior mesenteric artery. *Surg Gynecol Obstet*. 1981;153:561-569.
- Mansour MA. Management of acute mesenteric ischemia. *Arch Surg*. 1999;134:328-330.
- Howard TJ, Plaskon LA, Wiebke EA, Wilcox MG, Madura JA. Nonocclusive mesenteric ischemia remains a diagnostic dilemma. *Am J Surg*. 1996;171:405-408.
- Bergan JJ, Yao JST. Chronic intestinal ischemia. In: Rutherford RB, ed. *Vascular Surgery*. 3rd ed. Philadelphia, Pa: WB Saunders Co; 1989:825-842.
- Abdu RA, Zakhour BJ, Dallis DJ. Mesenteric venous thrombosis: 1911 to 1984. *Surgery*. 1987;101:383-388.
- Rhee RY, Gliovicki P, Mendonca CT, et al. Mesenteric venous thrombosis: still a lethal disease in the 1990s. *J Vasc Surg*. 1994;20:688-697.
- Schuler JJ. Acute mesenteric ischemia. In: Cameron JL, ed. *Current Surgical Therapy*. 5th ed. St Louis, Mo: Mosby-Year Book Inc; 1995:740-745.
- May LD, Berenson MM. Value of serum inorganic phosphate in the diagnosis of ischemic bowel disease. *Am J Surg*. 1983;146:266-268.
- Lund EC, Han SY, Holley HC, Berland LL. Intestinal ischemia: comparison of plain radiographic and computed tomographic findings. *Radiographics*. 1988;8:1083-1108.
- Smerud MJ, Johnson CD, Stephens DH. Diagnosis of bowel infarction: a comparison of plain films and CT scans in 23 cases. *AJR Am J Roentgenol*. 1990;154:99-103.
- Wolf EL, Sprayregen S, Bakal CW. Radiology in intestinal ischemia: plain film, contrast, and other imaging studies. *Surg Clin North Am*. 1992;72:107-124.
- Bartnicka BJ, Balfe DM. CT appearance of intestinal ischemia and intramural hemorrhage. *Radiol Clin North Am*. 1994;32:845-860.
- Fock CM, Kullnig P, Ranner G, Beaufort-Spontin F, Schmidt F. Mesenteric arterial embolism: the value of emergency CT in diagnostic procedure. *Eur J Radiol*. 1994;18:12-14.
- Kriegshauser JS, Reading CC, King BF, Welch TJ. Combined systemic and portal venous gas: sonographic and CT detection in two cases. *AJR Am J Roentgenol*. 1990;154:1219-1221.
- Taourel PG, Deneuille M, Pradel JA, Regent D, Bruel JM. Acute mesenteric ischemia: diagnosis with contrast-enhanced CT. *Radiology*. 1996;199:632-636.
- Laghi A, Iannaccone R, Catalano C, Passariello R. Multislice spiral computed tomography angiography of mesenteric arteries [letter]. *Lancet*. 2001;358:638-639.
- Desai SR, Cox MR, Martin CJ. Superior mesenteric vein thrombosis: computed tomography diagnosis. *Aust N Z J Surg*. 1998;68:811-812.
- Grace PA, Da Costa M, Qureshi A, Sheehan S, Burke P, Bouchier-Hayes D. An aggressive approach to acute superior mesenteric arterial ischemia. *Eur J Vasc Surg*. 1993;7:731-732.
- Kurland B, Brandt LJ, Delaney HM. Diagnostic tests for intestinal ischemia. *Surg Clin North Am*. 1992;72:85-105.
- Volteas N, Labropoulos N, Leon M, Kalodiki E, Chan P, Nicolaidis AN. Detection of superior mesenteric and coeliac artery stenosis with colour flow duplex imaging. *Eur J Vasc Surg*. 1993;7:616-620.
- Harward TR, Smith S, Seeger JM. Detection of coeliac axis and superior mesenteric artery occlusive disease with use of abdominal duplex scanning. *J Vasc Surg*. 1993;17:738-745.
- Danse EM, Van Beers BE, Goffette P, Dardenne AN, Laterre PF, Pringot J. Acute intestinal ischemia due to occlusion of the superior mesenteric artery: detection with Doppler sonography. *J Ultrasound Med*. 1996;15:323-326.
- Zwolak RM. Can duplex ultrasound replace arteriography in screening for mesenteric ischemia? *Semin Vasc Surg*. 1999;12:252-260.
- Burkart DJ, Johnson CD, Reading CC, Ehman RL. MR measurements of mesenteric venous flow: prospective evaluation in healthy volunteers and patients with suspected chronic mesenteric ischemia. *Radiology*. 1995;194:801-806.
- Ha HK, Rha SE, Kim AY, Auh YH. CT and MR diagnoses of intestinal ischemia. *Semin Ultrasound CT MR*. 2000;21:40-55.
- Shoemaker WC, Appel PL, Kram HB, Waxman K, Lee TS. Prospective trial of supranormal values of survivors as therapeutic goals in high-risk surgical patients. *Chest*. 1988;94:1176-1186.
- Tuchschmidt J, Fried J, Astiz M, Rackow E. Elevation of cardiac output and oxygen delivery improves outcome in septic shock. *Chest*. 1992;102:216-220.
- Hayes MA, Timmins AC, Yau EH, Palazzo M, Hinds CJ, Watson D. Elevation of systemic oxygen delivery in treatment of critically ill patients. *N Engl J Med*. 1994;330:1717-1722.
- Galandiuk S, Fazio VW, Petras RE. Fluorescein endoscopy: a technique for noninvasive assessment of intestinal ischemia. *Dis Colon Rectum*. 1988;31:848-853.
- Bulkley GB, Zuidema GD, Hamilton SR, O'Mara CS, Klacsman PG, Horn SD. Intraoperative determi-



- nation of small intestinal viability following ischemic injury: a prospective, controlled trial of two adjuvant methods (Doppler and fluorescein) compared with standard clinical judgment. *Ann Surg.* 1981;193:628-637.
51. Ballard JL, Stone WM, Hallett JW, Pairolero PC, Cherry KJ. A critical analysis of adjuvant techniques used to assess bowel viability in acute mesenteric ischemia. *Am Surg.* 1993;59:309-311.
52. Rivitz SM, Geller SC, Hahn C, Waltman AC. Treatment of acute mesenteric venous thrombosis with transjugular intramesenteric urokinase infusion. *J Vasc Interv Radiol.* 1995;6:219-223.
53. Sehgal M, Haskel ZJ. Use of transjugular intrahepatic portosystemic shunts during lytic therapy of extensive portal splenic and mesenteric venous thrombosis: long-term follow-up. *J Vasc Interv Radiol.* 2000;11:61-65.
54. Train JS, Ross H, Weiss JD, Feingold ML, Khoury-Yacoub A, Khoury PT. Mesenteric venous thrombosis: successful treatment by intraarterial lytic therapy. *J Vasc Interv Radiol.* 1998;9:461-464.
55. Endean ED, Barnes SL, Kwolek CJ, Minion DJ, Schwarcz TH, Mentzer RM Jr. Surgical management of thrombotic acute intestinal ischemia. *Ann Surg.* 2001;233:801-808.
56. Tola M, Portoghese A, Maniga AM. Laparoscopic second-look in acute intestinal ischemia [in Italian]. *Minerva Chir.* 1997;52:527-530.
57. Seshadri PA, Poulin EC, Mamazza J, Schlachta CM. Simplified laparoscopic approach to "second-look" laparotomy: a review. *Surg Laparosc Endosc Percutan Tech.* 1999;9:286-289.
58. Deehan DJ, Heys SD, Brittenden J, Eremin O. Mesenteric ischaemia: prognostic factors and influence of delay upon outcome. *J R Coll Surg Edinb.* 1995;40:112-115.
59. Christensen MG, Lorentzen JE, Schroeder TV. Revascularisation of atherosclerotic mesenteric arteries: experience in 90 consecutive patients. *Eur J Vasc Surg.* 1994;8:297-302.