

CASE RECORDS of the MASSACHUSETTS GENERAL HOSPITAL

Founded by Richard C. Cabot

Nancy Lee Harris, M.D., *Editor*  
Jo-Anne O. Shepard, M.D., *Associate Editor*  
Sally H. Ebeling, *Assistant Editor*

Eric S. Rosenberg, M.D., *Associate Editor*  
Alice M. Cort, M.D., *Associate Editor*  
Christine C. Peters, *Assistant Editor*



## Case 23-2011: A 40-Year-Old Pregnant Woman with Placenta Accreta Who Declined Blood Products

William H. Barth, Jr., M.D., Christopher J. Kwolek, M.D., Joshua L. Abrams, J.D.,  
Jeffrey L. Ecker, M.D., and Drucilla J. Roberts, M.D.

### PRESENTATION OF CASE

*Dr. Britta Panda* (Obstetrics and Gynecology): A 40-year-old woman was seen by the maternal–fetal medicine service at this hospital at 22 weeks 2 days' gestation because of placenta previa and placenta accreta.

Beginning at 12 weeks 1 day's gestation, the patient had received routine prenatal care at a health center affiliated with this hospital. She was gravida 5, para 4, and had had normal vaginal deliveries at term with her first two pregnancies, 16 and 9 years earlier. Seven years earlier, a cesarean section had been performed at term for a breech presentation during labor. An initial low transverse uterine incision was extended into a high vertical incision because of difficulty extracting the fetus. The patient's hematocrit had decreased from 33.6% to 17.6% post partum (reference range for nonpregnant women, 36.0 to 46.0). Five years before this admission, a cesarean section, with a low transverse incision, was performed electively at term; the postpartum hematocrit was 28.9%.

A skin test for tuberculosis had reportedly been positive 8 years earlier, with a normal chest radiograph; isoniazid had been administered for 6 months. The patient had iron-deficiency anemia for which iron supplements had been prescribed but discontinued because of gastrointestinal intolerance. She had had varicella–zoster virus infection, and screening for rubella antibody had been positive. She was taking only prenatal multivitamins and had no known allergies. She was born in a Caribbean country, lived with her husband and children, and worked in a health care field. She declined transfusions of all blood products because of her religious beliefs. Her husband, also a health care worker, did not share these beliefs. She did not drink alcohol, smoke cigarettes, or use illicit drugs. Her mother had hypertension; her father had had hypertension and epilepsy and had died at the age of 70 years. Her sister had sickle cell trait, and the patient's children and half-siblings were well.

On examination at the initial prenatal visit, the weight was 60.3 kg and the blood pressure 100/58 mm Hg; the remainder of the examination was consistent with the gestational stage and was otherwise normal. The hematocrit was 29.1%

From the Departments of Obstetrics and Gynecology (W.H.B., J.L.E.) and Surgery (C.J.K.), the Office of the General Counsel (J.L.A.), and the Department of Pathology (D.J.R.), Massachusetts General Hospital; and the Departments of Obstetrics, Gynecology, and Reproductive Biology (W.H.B., J.L.E.), Surgery (C.J.K.), and Pathology (D.J.R.), Harvard Medical School — both in Boston.

N Engl J Med 2011;365:359-66.  
Copyright © 2011 Massachusetts Medical Society.

(reference range for nonpregnant women, 36.0 to 46.0), and the hemoglobin level 10.1 g per deciliter (reference range for nonpregnant women, 12.0 to 16.0). Other test results, including the remainder of the complete blood count, hemoglobin electrophoresis, and tests of renal and liver function, were normal. All prenatal screening tests were negative, and results of cytopathological examination of a smear of the cervix were normal. The ABO blood type was O, Rh positive, with negative antibody screening. The patient was informed that a repeat cesarean section was advisable, and iron supplementation was prescribed. Eight days later, ultrasonographic examination of the pelvis revealed a normal-appearing single fetus, with biometry consistent with 13 weeks 2 days' gestation, and a normal fetal heart rate. The placenta was forming posteriorly, and the amniotic-fluid volume and adnexa were normal.

At 20 weeks 6 days' gestation, repeat ultrasound examination of the uterus revealed a single active fetus, as well as a right lateral complete placenta previa, large echolucencies in the placenta, loss of the myometrial echolucent stripe near the bladder, and increased venous structures and flow in the anterior lower uterine segment, features suggestive of placenta accreta. The cervix was more than 3 cm long, without funneling, and the fetal anatomy, amniotic-fluid volume, and umbilical cord appeared normal. At 21 weeks 2 days' gestation, the patient's weight was 63.5 kg, the blood pressure 80/64 mm Hg, and the fundal height consistent with 21 weeks' gestation. The fetal heart rate was 140 beats per minute.

Seven days later, the patient was seen at the maternal-fetal medicine service. Management decisions were made.

#### DIFFERENTIAL DIAGNOSIS

*Dr. William H. Barth, Jr.:* I am aware of the final diagnosis in this case. During the routine second-trimester fetal ultrasound examination, we noted a complete placenta previa (Fig. 1A). Taking into account the placenta previa and the patient's history of two previous cesarean deliveries, we estimated the risk of placenta accreta to be about 40%.<sup>1</sup> However, the ultrasonogram also showed large echolucencies within the stroma of the placenta (Fig. 1B), loss of the normal hypoechoic myometrial band beneath the placenta (Fig. 1C), and

increased vascularity around the lower uterine segment (not shown). Together, these additional findings were suggestive of a risk of placenta accreta of more than 60%.<sup>2</sup> Because of the concern about placenta accreta, we met with the patient to discuss the diagnosis of placenta accreta and the implications for maternal and fetal outcome and to begin planning for delivery.

At the initial consultation, we discussed the risks to the fetus that are associated with placenta previa with placenta accreta (especially prematurity in the event of maternal antepartum hemorrhage) and the more substantial risks to the mother, including hemorrhage, the need for blood transfusion, hysterectomy, possible damage to the bladder or other pelvic organs, admission to an intensive care unit, assisted ventilation, pulmonary embolus, and death.<sup>1</sup> At this time, the patient clearly stated that she would decline blood products even if her life were in danger. Although termination of the pregnancy was discussed, the patient conveyed that this was not an option she would consider.

We also discussed options for minimizing the risks of life-threatening blood loss at the time of delivery. These included optimization of maternal iron status, pharmacologic stimulation of erythropoiesis, autologous blood donation and transfusion, acute preoperative hemodilution, and use of a cell-saver autotransfusion device at the time of delivery. We discussed the use of balloons for intravascular occlusion at the time of delivery and our recommendation for a cesarean hysterectomy without attempts to remove the placenta, since the patient did not want additional children.

Because the initial ultrasound study was performed in the second trimester, we planned to repeat the study early in the third trimester to reassess the placental location and signs of placenta accreta. If the placenta previa was confirmed and the findings of accreta were equivocal, we planned to proceed with abdominal and pelvic magnetic resonance imaging (MRI) to clarify the diagnosis.<sup>2</sup> A follow-up ultrasound examination at 27 weeks (Fig. 1D) showed a complete placenta previa and confirmed all the previously noted sonographic signs of placenta accreta. Because the findings on ultrasonography were unequivocal, we did not pursue MRI, believing that no information gained from such a study would alter our surgical planning or preparation.

**Figure 1. Ultrasound Studies.**

A sagittal image from an ultrasonogram obtained during the second trimester shows the cervix (Panel A, calipers) and lower uterine segment with the placenta overlying the internal cervical os (arrow), large and irregular echolucent spaces within the placental stroma (Panel B, arrow), and loss of the normal hypoechoic myometrial band (Panel C, arrow), which suggest invasion of the placenta into the myometrium. A third-trimester ultrasound image (Panel D) shows the placenta (P) with irregular hypoechoic spaces that completely cover the cervix (Cx). The arrow shows loss of the hypoechoic myometrium beneath the placenta.

DR. WILLIAM H. BARTH, JR.'S  
DIAGNOSIS

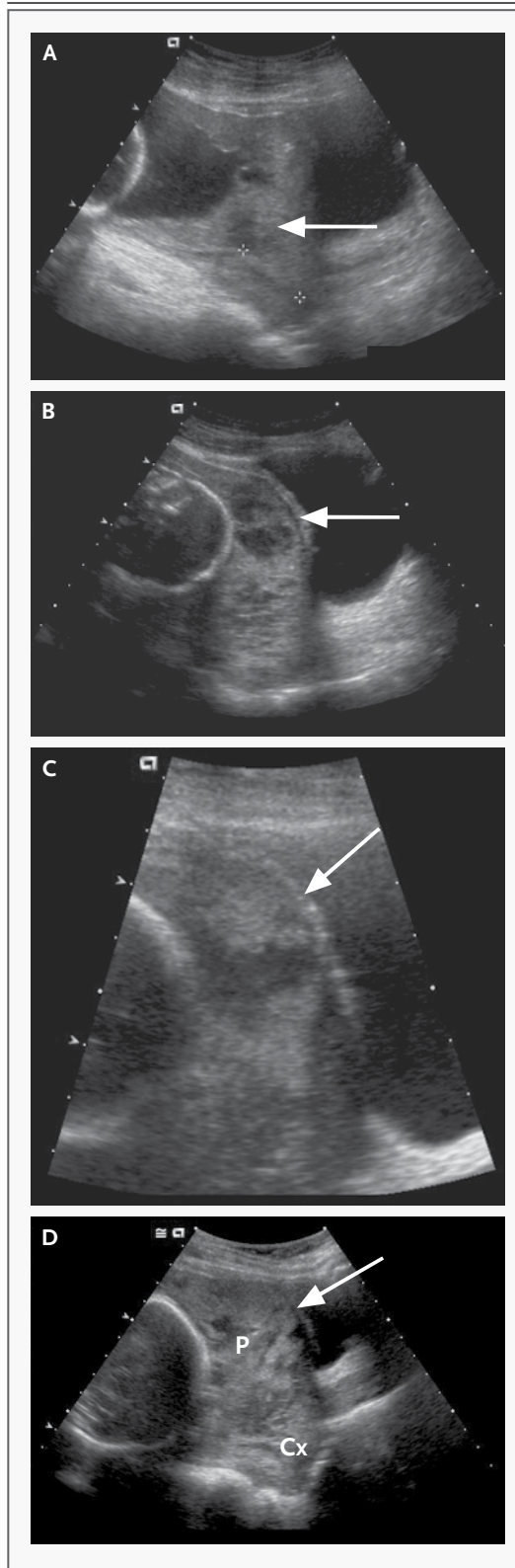
Placenta previa with placenta accreta.

DISCUSSION OF MANAGEMENT

*Dr. Barth:* After consulting with clergy from her church, the patient declined the option of autologous donation and transfusion, as well as acute preoperative hemodilution. She was amenable to iron therapy, pharmacologic stimulation of erythropoiesis, and autotransfusion with the use of a cell-saver system, as long as the autotransfusion circuit remained continuous with her circulation. In consideration of the patient's high risk of hemorrhage, insistence on no blood products, and resulting high risk of maternal death, we assembled a multidisciplinary team that included representatives from maternal–fetal medicine, hematology, social services, hospital counsel, obstetric anesthesiology, vascular surgery, urology, gynecologic oncology, transfusion medicine, obstetrical nursing, and neonatology. Dr. Ecker and Mr. Abrams will discuss the ethical and legal considerations in this case.

**ETHICAL CONSIDERATIONS**

*Dr. Jeffrey L. Ecker:* This patient may well have clinically significant bleeding at the time of her cesarean delivery, but her religion imposes restrictions on her receiving blood transfusions. The patient indicated that she would decline such treatment, even if declining led to her death. Cases and plans like this often make care teams uncomfortable and sometimes lead providers to wonder whether patients — especially new or ex-



pectant mothers — can or should receive transfusions against their stated wishes. As a matter of ethics, I believe it is clear that they should not, and I will review the two ethical principles that are the foundation of my conclusion: respect for autonomy and justice.<sup>3</sup>

Respect for autonomy is the recognized right of competent and appropriately informed patients to make choices regarding their health. Respect for autonomy is not the same as autonomy — patients may not simply make a choice or demand that a provider do whatever they ask, but the right to decline a particular treatment, intervention, or procedure no matter how vigorously recommended or likely to benefit one's health has few, if any limits.<sup>4</sup> The second important principle is justice — the idea that like things should be treated alike. Respect for autonomy should not vary according to sex, whether one has children, or whether someone is pregnant.

What recourse is there, then, for providers who wish a patient like this one had chosen differently? Respect for autonomy does not abrogate a provider's duty to explain. Providers need to be sure that patients understand the nature and consequences of their decisions. Because a patient's understanding may be limited by education, language, and culture, providers should work to overcome such barriers. They should also try to understand the foundations of a patient's decision and, if possible, address concerns or elements that seem to compel patients to choose paths that are not recommended. Providers may also — on their own or with the help of respected others (e.g., friends, family, or clergy) — advocate for a recommended position in an effort to influence a patient's decision. Advocacy, however, must not become coercion, and threatening or creating negative consequences for a patient or a patient's family or community because of the patient's decision is unethical. A physician's role as advocate is also appropriately limited to areas of professional, but not personal, expertise; in our roles as physicians, we should advocate for medical care, not for religious practice.

Sometimes providers may feel so uncomfortable with a patient's choice that they wish not to care for the patient. In such cases, the patient may be encouraged to seek others more comfortable with the chosen care plan, but the first provider has a duty not to abandon the patient until other providers are found.

In summary, in managing the care of this patient, I would make sure that she understood the potential implications of her plan not to receive blood products, including the possibility of death. I would ask her to consider her decision in the context of other things she might value, such as her family. I would revisit the matter during the course of her prenatal care, to ensure that all her questions were answered. If, in the end, her wish not to receive transfusions was clear, I would respect it and prepare for a delivery in which support with blood products was not an option.

*Mr. Joshua L. Abrams:* In analyzing the legal issues surrounding this pregnant patient's stated desire to refuse blood products for religious reasons during any procedure related to the delivery of her baby, one must start with the premise that competent adult patients have the right to consent to their own medical care. This includes the right to refuse medical treatment despite the treating physician's advice and despite the objections of family members and friends of the patient.<sup>5,6</sup> This general rule applies to any patient who declines blood products, regardless of the reason. If this patient wishes to ensure that blood products will not be used, she would usually be asked to execute a statement of refusal of blood products before the procedure. If she is injured or dies because no blood products were used during the procedure, this document will protect the caregivers from a claim that they should have avoided such injury or death by providing blood products. The execution of such a document should include a discussion between the treating provider and the patient about the risks of refusing blood products, and any questions that the patient may have about alternatives to the use of blood products should be answered at this time. The statement should include an affirmation that this discussion has been held and that all questions that the patient had were answered.

The spouse of this patient does not have the right to block her decision, unless the patient is deemed to lack capacity to make her own medical decisions. There are limited circumstances in which a pregnant woman may be forced to accept blood products against her will (although bloodless alternatives should still be considered, even in these situations). If a pregnant patient is not married, she must show that if she dies or is rendered unable to care for the child, someone will

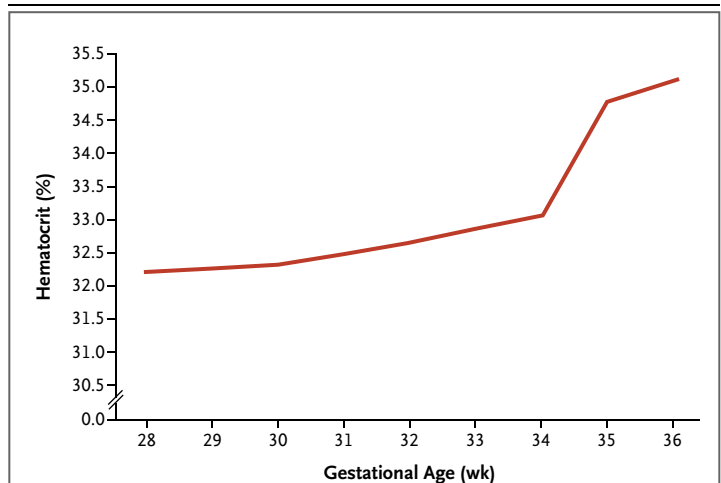


take responsibility for this child and any other surviving children, in her place. Such person or persons must affirmatively state that they will take such responsibility for the child, in the patient's place, before the procedure.<sup>7,8</sup> If there is already a legal parent or guardian of the other children, or if the patient is married, this affirmation is unnecessary, since a legal parent or guardian already has the legal responsibility to care for the children. If no affirmed caregiver for the child or children exists, then the mother can be required to accept blood products if they are necessary to prevent her death. In this case, the patient is married, and her husband is legally responsible for the child. Therefore, the above affirmation is unnecessary; the husband cannot abdicate this responsibility, and the patient cannot legally be forced to accept blood products.

#### PLANNING FOR DELIVERY

*Dr. Barth:* Through additional discussions with the patient, her spouse, maternal–fetal medicine providers, social services, and legal counsel, we resolved and documented in advance that the patient's decision to decline a blood transfusion would be honored, even if doing so would result in her death. Although the patient had been taking 325 mg of oral ferrous sulfate once a day, laboratory evaluation at 27 weeks showed mild iron-deficiency anemia and a hematocrit of 29.1%. Advised by the consulting hematologists, the patient began taking 150 mg of iron polysaccharide twice daily and 2 weeks later began treatment with 300  $\mu$ g of darbepoetin alfa once every 2 weeks (Fig. 2).

At the completion of 36 weeks of gestation, we planned a repeat cesarean section to be followed immediately by hysterectomy, without attempts to remove the placenta in the vascular surgery suite of the main operating room. With input from the multidisciplinary team, we planned for a number of maneuvers not typically performed during a routine cesarean section. The maneuvers occurred in the following order: establishment of large-bore intravenous access, placement of an arterial catheter to monitor blood pressure and to obtain needed laboratory samples, placement of an epidural anesthetic, preoperative placement of ureteral stents, and fluoroscopic intravascular placement of occlusive balloons in the internal iliac arteries, which would be inflated immediately after delivery of the fetus. We also



**Figure 2. Maternal Hematologic Response to Additional Iron Supplementation and Stimulation of Erythropoiesis with Darbepoetin Alfa.**

Beginning when the patient was at 28 weeks of gestation, the prescription for 325 mg of ferrous sulfate daily was changed to 150 mg of iron polysaccharide twice a day. Two weeks later, 300  $\mu$ g of darbepoetin alfa was administered every 2 weeks to stimulate erythropoiesis.

planned for the use of a cell-saver autotransfusion device once the operative field had been cleared of amniotic fluid.<sup>9</sup> We chose elective delivery at a gestational age of 36 weeks, believing that the neonatal risks of late preterm birth were outweighed by the difficulties that might be encountered by assembling the broad multidisciplinary team and resources after hours in an emergency. Two days before the delivery, we administered a course of betamethasone for the promotion of fetal pulmonary maturity.

#### MINIMIZING BLOOD LOSS IN PLACENTA ACCRETA AND PLACENTA PERCRETA

*Dr. Christopher J. Kwolek:* Placenta accreta occurs when the chorionic villi of the placenta come into contact with the myometrium of the uterus. Placenta percreta occurs when the villi penetrate the uterine serosa and may be present on adjacent structures such as the bladder (Table 1). More than 80% of patients with placenta percreta have concomitant placenta previa, with a risk of clinically significant blood loss of more than 3000 ml.

Several techniques have been described to minimize the risk of peripartum blood loss in a patient such as this one by decreasing pelvic blood flow. Open surgical devascularization may

**Table 1. Classification of Abnormal Placental Attachment.**

Diagnosis	Histopathological Features
Placenta accreta	Placenta adheres to myometrium with no intervening decidua.
Placenta increta	Placenta is within (surrounded by) the myometrium.
Placenta percreta	Placental tissue is extrauterine or on the uterine serosa.

involve ligation of the internal iliac arteries or uterine artery branches. Temporary clamping of the infrarenal aorta or the common iliac arteries has also been described. However, performing these procedures before delivering the fetus will compromise fetal blood flow. In addition, exposure of these vessels before delivery may be difficult because of the size of the gravid uterus. Waiting until after the fetus is delivered allows for improved exposure but may lead to greatly increased blood loss.

Catheter-based techniques such as coil or foam embolization or temporary balloon occlusion have also been successful in decreasing peripartum blood loss. Additional risks such as radiation exposure to the fetus and possible thrombosis or embolization to the femoral vessels in the legs also need to be considered. Although temporary balloon occlusion has the advantage of being reversible, it often needs to be combined with hysterectomy to minimize the chance of postpartum bleeding complications. New operating-room imaging suites now allow for the performance of these procedures in the operating room, eliminating the need to transfer patients to the radiology department, with catheters, guide wires, and sheaths in place. The suites also provide immediate access to anesthesia and operating-room support staff, as well as instrumentation such as cell-saver autotransfusion devices and rapid-transfusion devices.

In one study, balloon occlusion of the arterial inflow was shown to decrease the bleeding that is associated with placenta accreta, as compared with historical controls.<sup>10</sup> The authors found a decrease in estimated blood loss, a decreased transfusion requirement, and a decreased duration of surgery in patients undergoing temporary balloon occlusion of the internal iliac artery. In this patient, we chose to combine temporary

balloon occlusion of the internal iliac arteries with hysterectomy, to minimize the risk of bleeding complications.

To achieve temporary balloon occlusion, we planned bilateral, retrograde puncture of the common femoral artery, with placement of 6-French sheaths, followed by selective catheterization of the ipsilateral internal iliac artery with the use of a rim catheter and bilateral internal iliac artery angiography. We then planned to place an angioplasty balloon, 8 mm by 2 cm, in each proximal internal artery and to inflate the balloons under fluoroscopic guidance to confirm successful occlusion of the internal iliac artery. During the delivery, we planned to use a pressure manometer–endoflator to inflate and deflate the balloons to pressure without the use of fluoroscopy. We planned to secure the sheaths and catheters to the skin, with the endoflator attached, and inflate the internal iliac balloons to nominal pressure (4 atm) at the time of delivery. On completion of the hysterectomy, we planned to deflate the balloons sequentially to inspect for bleeding and to remove them under fluoroscopic guidance after the abdomen was closed.

#### DELIVERY

*Dr. Panda:* The patient was admitted at 36 weeks 1 day's gestation and taken to the operating room by me and Dr. Michael Greene (Obstetrics and Gynecology) as the first case early in the morning. The preoperative hematocrit was 34.3% and the hemoglobin 11.7 g per deciliter. The anesthesia team started the procedure by placing catheters for fluid administration and pressure monitoring — two large-bore peripheral intravenous infusion catheters, an internal jugular catheter for central venous pressure, and a radial-artery catheter — followed by epidural anesthesia. The urology team then performed cystoscopy with the bilateral placement of ureteral stents. This was followed by the vascular-surgery team, which proceeded in accordance with the plan described earlier by Dr. Kwolek. A perfusionist was operating the cell-saver device.

General anesthesia was administered, and then the obstetrics and gynecologic-oncology teams took over. A vertical incision was made on the skin from the symphysis pubis to approximately 4 cm above the umbilicus, followed by a vertical incision on the uterus above the implantation of

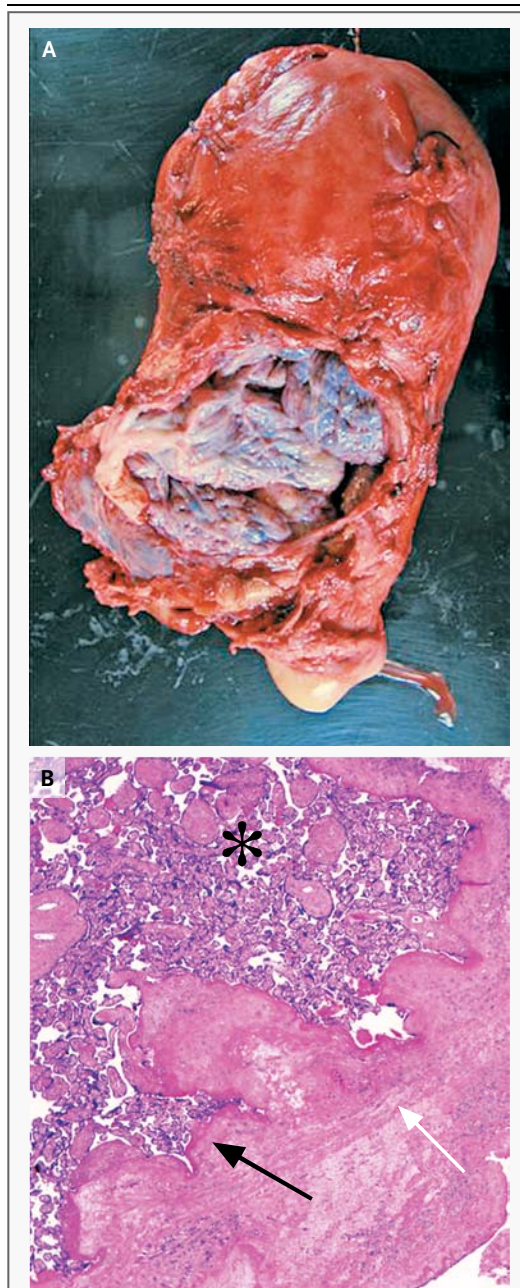
the placenta. A female infant was delivered, weighing 2550 g with 1-minute and 5-minute Apgar scores of 4 and 8, respectively. After delivery, the balloons were inflated, and we quickly closed the uterus. We then examined the pelvis, and it appeared that placental tissue was present outside the uterus, extending toward both pelvic sidewalls. With Dr. Marcela Del Carmen of Gynecologic Oncology, we performed a hysterectomy, removing the uterus, cervix, and placenta in one piece. We used several figure-of-eight stitches to control the bleeding from the vascular pedicles. Hemostasis persisted after the balloons were deflated. The bladder was found to be intact after it was filled with normal saline stained with indigo carmine. The incisions were closed in the usual fashion.

The patient remained stable throughout the procedure, with an estimated blood loss of 3 liters. She received back 1.1 liters through the cell-saver device. After a total of 7 hours in the operating room, she was transferred to the surgical intensive care unit, where she remained stable; the trachea was extubated later that day. On postoperative day 1, the hematocrit was 26.4% and the hemoglobin 9.3 g per deciliter.

#### PATHOLOGICAL DISCUSSION

*Dr. Drucilla J. Roberts:* A gravid hysterectomy specimen with the placenta in place was received in the pathology department. The gross examination showed a uterus with a lower uterine segment that had been disrupted during surgical manipulation and no exposed placental tissues on the surface (Fig. 3A). There was a complete placenta previa, and the placenta was strongly adherent to the lower uterine segment. Histologic sections through the disrupted margins showed that the placenta had adhered directly to the scarred myometrium, without intervening decidua, a finding that is diagnostic of placenta accreta (Fig. 3B and Table 1). The lower uterine segment anteriorly at the disrupted regions was markedly thinned and in many places had very little myometrium between the placenta and the serosal surface. We did not find placenta increta or placenta percreta (Table 1). The remaining uterine sections and sections of the placenta were unremarkable.

The histologic sections are clearly diagnostic of placenta accreta in this case, but a diagnosis



**Figure 3. Pathological Examination of the Uterus.**

In Panel A, an anatomical view of the gross specimen (anterior, with cervix inferior) shows a large area of disruption in the lower uterine segment, making the placenta in situ visible. No placental tissues are present on the serosal surface of the uterus. A photomicrograph of the anterior lower uterine segment (Panel B, hematoxylin and eosin) shows that the placenta (asterisk) is adhering (black arrow) directly to the scarred and thinned myometrium (white arrow).

of placenta accreta can be difficult to make, even with the uterus and placenta in situ. Often the diagnosis is best made clinically. Placenta increta and placenta percreta are rare, and these conditions can be definitively diagnosed only by pathological examination of the gravid uterus. Most cases of placenta increta and placenta percreta are caused not by abnormal placental implantation (i.e., a placenta that is growing into the uterus pathologically) but, rather, by dehiscence or rupture of a scarred uterus at the site of placental implantation.<sup>11</sup>

*Dr. Michael F. Greene (Obstetrics and Gynecology):* The patient was discharged from the hospital on postoperative day 8; the hemoglobin concentration was 10.3 g per deciliter, and the hematocrit 31.5%. At a scheduled visit on postoperative day 20, she had minimal discomfort from her incision and no vaginal bleeding. The hemoglobin level was 11.4 g per deciliter, the hematocrit 36.4%, and the reticulocyte count 4.4%. Serum levels of ferritin

(66 ng per milliliter), iron (89  $\mu$ g per deciliter [16  $\mu$ mol per liter]), and total iron-binding capacity (273  $\mu$ g per deciliter [49  $\mu$ mol per liter]) were in the normal range. At her final scheduled visit on postoperative day 41, the patient was feeling well and reported that she was breast-feeding successfully. The abdominal incision was well healed, the vaginal mucosa was well estrogenized, and the vaginal apex was well healed. Laboratory studies were not repeated. She was discharged to the care of her primary care physician.

#### ANATOMICAL DIAGNOSIS

#### Placenta previa and placenta accreta.

This case was presented at the Obstetrics and Gynecology Grand Rounds.

No potential conflict of interest relevant to this article was reported.

Disclosure forms provided by the authors are available with the full text of this article at NEJM.org.

We thank Dr. Michael F. Greene for assistance with preparing the case history and editing an earlier version of the manuscript.

#### REFERENCES

1. Silver RM, Landon MB, Rouse DJ, et al. Maternal morbidity associated with multiple repeat cesarean deliveries. *Obstet Gynecol* 2006;107:1226-32.
2. Warshak CR, Eskander R, Hull AD, et al. Accuracy of ultrasonography and magnetic resonance imaging in the diagnosis of placenta accreta. *Obstet Gynecol* 2006; 108:573-81.
3. Beauchamp TL, Childress JF. Principles of biomedical ethics. 5th ed. Oxford, England: Oxford University Press, 2001.
4. Gyamfi C, Gyamfi MM, Berkowitz RL. Ethical and medicolegal considerations in the obstetric care of a Jehovah's Witness. *Obstet Gynecol* 2003;102:173-80.
5. Superintendent of Belchertown State School v. Saikewicz. 373 Mass 728 (1977).
6. Shine v. Vega. 429 Mass 456 (1999).
7. Norwood Hospital v. Munoz. 409 Mass 116 (1991)
8. Beth Israel Hospital v. Stockton. Massachusetts Lawyers Weekly. June 24, 1991.
9. Rebarber A, Lonser R, Jackson S, Copel JA, Sipes S. The safety of intraoperative autologous blood collection and autotransfusion during cesarean section. *Am J Obstet Gynecol* 1998;179:715-20.
10. Tan CH, Tay KH, Sheah K, et al. Perioperative endovascular internal iliac artery occlusion balloon placement in management of placenta accreta. *AJR Am J Roentgenol* 2007;189:1158-63.
11. Tantbirojn P, Crum CP, Parast MM. Pathophysiology of placenta creta: the role of decidua and extravillous trophoblast. *Placenta* 2008;29:639-45.

Copyright © 2011 Massachusetts Medical Society.

#### LANERN SLIDES UPDATED: COMPLETE POWERPOINT SLIDE SETS FROM THE CLINICOPATHOLOGICAL CONFERENCES

Any reader of the *Journal* who uses the Case Records of the Massachusetts General Hospital as a teaching exercise or reference material is now eligible to receive a complete set of PowerPoint slides, including digital images, with identifying legends, shown at the live Clinicopathological Conference (CPC) that is the basis of the Case Record. This slide set contains all of the images from the CPC, not only those published in the *Journal*. Radiographic, neurologic, and cardiac studies, gross specimens, and photomicrographs, as well as unpublished text slides, tables, and diagrams, are included. Every year 40 sets are produced, averaging 50-60 slides per set. Each set is supplied on a compact disc and is mailed to coincide with the publication of the Case Record.

The cost of an annual subscription is \$600, or individual sets may be purchased for \$50 each. Application forms for the current subscription year, which began in January, may be obtained from the Lantern Slides Service, Department of Pathology, Massachusetts General Hospital, Boston, MA 02114 (telephone 617-726-2974) or e-mail [Pathphotoslides@partners.org](mailto:Pathphotoslides@partners.org).