

Unexpectedly High Recanalization Rate in Patients with Pulmonary Embolism Treated with Anticoagulants Alone



To the Editor:

The rate of residual thrombosis, defined as the long-term persistence of thrombotic material in the pulmonary artery tree after pulmonary embolism (PE), is uncertain. Although a systematic review reported low recanalization rates (43% at 6 mo) (1), most studies used perfusion or ventilation–perfusion lung scanning or older generation computed tomography (CT) scanners. In a prospective study we determined the rate of residual thrombosis in a cohort of consecutive patients with acute PE as detected by 64-row multidetector CT (MDCT), treated with anticoagulants alone and reassessed 6 months later with the same high-technology procedure.

Methods

Consecutive patients referring to six institutions in Italy with the first episode of symptomatic PE were eligible provided they were clinically stable and that the diagnosis was confirmed by MDCT (2). Patients with previous PE were excluded, as were those requiring thrombolysis, patients with contraindications to anticoagulation or to the radiological procedure, those with life expectancy less than 6 months, pregnant patients, and those refusing participation. The study protocol was approved by the ethics board in each center.

All recruited patients underwent D-dimer, troponin I, and pro-brain natriuretic peptide testing and transthoracic echocardiography. Right ventricular dysfunction was defined according to widely accepted criteria (3, 4). The Pulmonary Embolism Severity Index score (5) and the scoring system of the European Society of Cardiology (6) were used to quantify the short-term risk of unfavorable outcome. Patients were treated with full-dose unfractionated heparin, low molecular weight heparin, or fondaparinux followed by vitamin K antagonists for 6 months, except for patients with cancer, who had heparin treatment throughout the whole period.

After completion of the 6-month period, surviving patients who did not experience recurrent PE underwent a second MDCT. The degree of artery obstruction (CT index) at baseline and after 6 months was calculated by two independent radiologists using the Qanadli scoring system (7). In case of disagreement, a consensus reading was performed. Residual thrombotic obstruction was defined in the presence of an intraluminal filling defect,

eccentrically located thrombus, vessel narrowing or occlusion, intimal irregularities, bands and webs, and poststenotic dilation (8, 9).

We assessed the association of several baseline parameters with the occurrence of residual thrombosis, using the chi-square or Fisher exact test for the categorical variables, and the Mann-Whitney test for the continuous variables. All variables with a significance level less than 0.1 were included in a multivariate logistic regression model and results were expressed as odds ratios (ORs) with 95% confidence intervals (CIs).

Results

Of the 167 patients with PE who were referred to the study centers between February 2010 and September 2012, 113 fulfilled the eligibility criteria, completed the 6-month follow-up, and underwent the second MDCT (Figure 1). Table 1 shows the main baseline characteristics of the whole cohort as well as of patients with and without residual thrombosis. Up to one-third of patients were at intermediate risk of severe complications or met at least one criterion for right ventricular dysfunction. At baseline, the mean CT index was 35.0%. Ninety-six patients achieved full recanalization, whereas in the remaining 17 (OR, 15.0%; 95% CI, 8.5 to 21.6) the CT index decreased from 50.0 to 5.6%. In only one patient was an intraluminal filling defect seen, whereas the

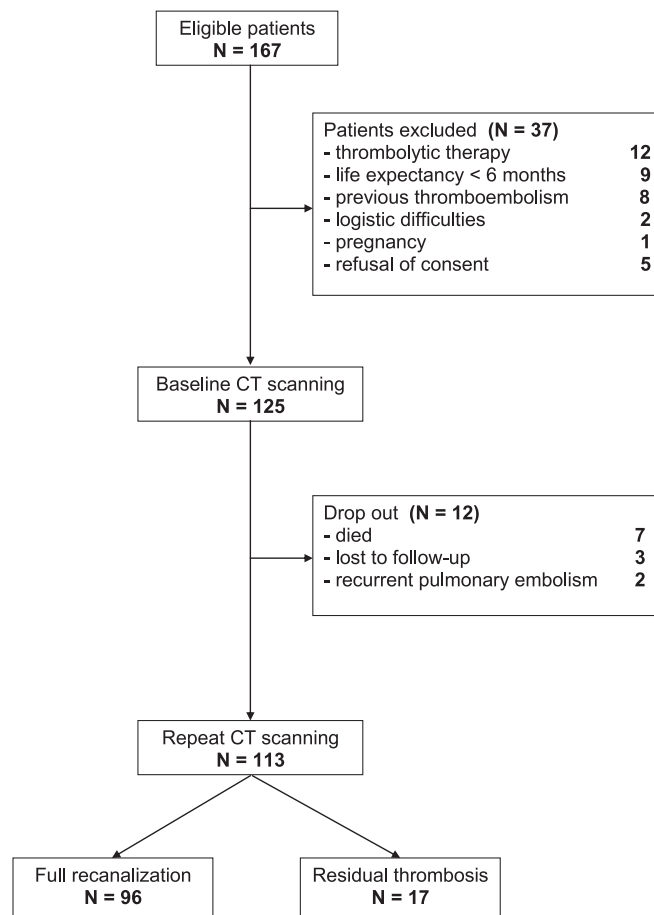


Figure 1. Flow diagram of the study. CT = computed tomography.

Supported by a grant from the University of Padua (CPDA091731) and from the Government of Regione Veneto-DGRV N.4273-09.

Author Contributions: Study concept and design: P. Prandoni, A.P., and R.P.; acquisition of data: G.B., S.C., G.D.C., L.F., V.V., P. Pauletto, G.V., S.V., and A.V.; analysis and interpretation of data: R.P., P. Prandoni, A.P., L.F., and A.C.F.; drafting of the manuscript: R.P., P. Prandoni, and A.C.F.; critical revision of the manuscript for important intellectual content: G.B., S.C., G.D.C., P. Pauletto, G.V., S.V., and A.V.; statistical analysis: A.C.F.; obtained funding: A.P., P. Prandoni, and R.P.; administrative, technical, or material support: G.D.C., L.F., V.V., and R.P.; study supervision: G.B., S.C., G.D.C., P. Pauletto, G.V., S.V., and A.V.; R.P. and P. Prandoni had full access to all of the data in the study and take responsibility for the integrity of the data and the accuracy of the data analysis. All authors approved the final version of the manuscript.

Table 1: Baseline Characteristics of Study Patients according to Residual Obstruction on Computed Tomographic Scanning

Features	All Patients (n = 113)	No Residual Thrombosis (n = 96)	Residual Thrombosis (n = 17)	P Value
Age (yr), mean (SD)	65.8 (14.8)	65.5 (15.2)	67.5 (12.4)	0.69
Male sex	52 (45.5)	38 (39.6)	14 (82.3)	0.001
BMI, mean (SD)	27.6 (5.0)	27.4 (5.0)	28.3 (5.5)	0.78
Familial history of VTE*	10 (8.9)	8 (8.4)	2 (11.8)	0.65
Unprovoked PE	68 (60.2)	55 (57.3)	13 (76.5)	0.14
Active cancer	10 (8.9)	9 (9.4)	1 (5.9)	1.0
Recent trauma or surgery	14 (12.4)	13 (13.5)	1 (5.9)	0.69
Immobility	13 (11.5)	12 (12.5)	1 (5.9)	0.69
Recent long journey	7 (6.2)	6 (6.3)	1 (5.9)	0.95
Ongoing hormonal therapy	10 (8.9)	10 (10.4)	0 (0.0)	0.35
Known thrombophilia†	11 (9.8)	9 (9.5)	2 (11.8)	0.67
Chronic lung disease	18 (15.9)	14 (14.6)	4 (23.5)	0.47
Concomitant DVT	67 (59.3)	55 (57.3)	12 (70.6)	0.42
PESI score, mean (SD)	77.9 (21.4)	77.7 (21.8)	80.2 (19.1)	0.53
Class 1–2	75 (66.4)	66 (68.8)	9 (52.9)	0.20
Class 3–5	38 (33.6)	30 (31.2)	8 (47.5)	0.20
ESC scoring system				0.90
Low risk	80 (70.8)	67 (69.8)	13 (76.5)	0.90
Intermediate (lower level) risk	27 (23.9)	24 (25.0)	3 (17.7)	0.90
Intermediate (upper level) risk	6 (5.3)	5 (5.2)	1 (5.9)	0.90
Troponin I (μg/L), mean (SD)	—	0.085 (0.217)	0.652 (1.868)	0.10
NT-pro-BNP (ng/L), mean (SD)	—	1,047 (1,953)	1,434 (1,470)	0.67
D-dimer (μg/L), mean (SD)	—	3,504 (3,668)	2,197 (1,935)	0.55
Right ventricular dysfunction on echo	31 (40.2)	27 (40.2)	4 (40)	1.0
CT index at diagnosis, mean (SD)	35.0 (22.8)	31.4 (22.1)	50.0 (23.3)	0.005

Definition of abbreviations: BMI = body mass index; DVT = deep vein thrombosis; ESC = European Society of Cardiology; NT-pro-BNP = N-terminal pro-brain natriuretic peptide; PE = pulmonary embolism; PESI = Pulmonary Embolism Severity Index; VTE = venous thromboembolism. Data are presented as numbers and percentages unless otherwise indicated.

*Venous thromboembolic episode in a first-degree relative.

†Antithrombin, protein C or S defects, factor V Leiden, G20210A prothrombin variant, anti-phospholipid antibodies.

remaining patients showed eccentric defects, vessel narrowing or occlusion, bands, webs, and poststenotic dilation. Male sex and the severity of pulmonary obstruction were independently associated with the occurrence of residual thrombosis (OR, 7.68; 95% CI, 1.99 to 29.75 and OR, 2.86; 95% CI, 1.35 to 6.06, respectively).

Discussion

Most patients with acute symptomatic PE achieve full pulmonary artery recanalization after 6 months of anticoagulants alone, and in the remaining patients the thrombotic burden decreases by more than 80%. Accordingly, routine use of follow-up imaging for diagnostic purposes, which is quite common in Italy, seems unjustified.

As we did not monitor patients beyond 6 months, we cannot exclude that repeating CT scanning has the potential to identify patients at risk for chronic thromboembolic pulmonary hypertension. Indeed, most residual defects were small and compatible with chronic sequelae of PE (10, 11). Besides, these were strongly related to the severity of PE, which in turn was found to increase the risk of late pulmonary hypertension (12). However, as detection of these small, unspecific residual defects is unlikely to have any appreciable relevance in the management of patients with PE, repeating CT scanning for prognostic implications does not seem justified.

At present, it is unclear what mechanism accounts for this high recanalization rate, which contrasts with that of the leg veins after

deep vein thrombosis (13). Indirect evidence suggests that hemostasis is vascular bed specific. In the lungs, thrombomodulin, prostacyclin, tissue-type plasminogen activator, and urokinase-type plasminogen activator may temper the procoagulant forces and promote early lysis of thrombotic material (14).

The unexpectedly high recanalization rate seen in our patients contrasts with that reported in studies using perfusion or ventilation–perfusion lung scanning (1), probably because of the lower specificity of these procedures. We cannot exclude, however, that some degree of residual disease may persist beyond recanalization and that even high-technology CT scanners fail to identify it (15). Although our study is the largest conducted to date for assessing residual thrombotic obstruction by CT scanning, the sample size was relatively small because of the relatively low rate of patients with PE who could be admitted during the study period to the medical departments where the investigation was conducted. However, the characteristics of patients who were enrolled are fully consistent with those of patients with PE recruited for diagnostic purposes in major international studies (16, 17). According to guidelines, decisions about the optimal duration of anticoagulation in patients with venous thromboembolism should be made at 3 months (18). We decided to evaluate the occurrence of residual thrombosis after 6 months because both in Italy and elsewhere current practice involves treating patients with PE for at least 6 months. Because of the exclusion of unstable patients requiring thrombolysis and of

those with previous PE, our conclusions cannot apply to these categories.

In summary, most patients with the first episode of acute PE achieve full recanalization of pulmonary arteries after 6 months of anticoagulation alone, and in the remaining patients the thrombotic burden decreases by more than 80%. Residual thrombosis is more likely to occur in males and in patients with severe pulmonary artery obstruction. Because CT scanning is expensive and it may expose patients to high radiation and to the risk of renal failure, repeating it on a routine basis in patients being treated for PE cannot be recommended. ■

Author disclosures are available with the text of this letter at www.atsjournals.org.

Raffaele Pesavento, M.D.
Lucia Filippi, M.D.
Antonio Pagnan, M.D.
University Hospital of Padua
Padua, Italy

Adriana Visonà, M.D.
Civic Hospital of Castelfranco Veneto
Castelfranco Veneto, Italy

Paolo Pauletto, M.D.
University Hospital of Treviso
Treviso, Italy

Giorgio Vescovo, M.D.
Civic Hospital of Vicenza
Vicenza, Italy

Stefano Cuppini, M.D.
Civic Hospital of Rovigo
Rovigo, Italy

Giampietro Beltramello, M.D.
Civic Hospital of Bassano del Grappa
Bassano del Grappa, Italy

Sabina Villalta, M.D.
University Hospital of Treviso
Treviso, Italy

Giorgio De Conti, M.D.
Valentina Vedovetto, M.D.
Anna Chiara Frigo, M.D.
Paolo Prandoni, M.D., Ph.D.
University Hospital of Padua
Padua, Italy

For the PROVE Investigators Group*

*Additional investigators of the Pulmonary Residual Obstruction in the Venetian Area (PROVE) Study (all in Italy): M. Gazzola, G. Menegati, M. Milan (Padua); A. Benettin, E. Callegari (Treviso); B. Zalunardo (Castelfranco Veneto); C. Bolin, A. Dalla Pozza (Vicenza); G. Maretto, M. Marzolo, E. Ramazzina (Rovigo); G. Busa (Bassano del Grappa).

References

- Nijkeuter M, Hovens MM, Davidson BL, Huisman MV. Resolution of thromboemboli in patients with acute pulmonary embolism: a systematic review. *Chest* 2006;129:192–197.
- Pesavento R, de Conti G, Minotto I, Filippi L, Mongiat M, de Faveri D, Maurizi F, Dalla Valle F, Piovella C, Pagnan A, *et al.*; TACEP Study. The value of 64-detector row computed tomography for the exclusion of pulmonary embolism. *Thromb Haemost* 2011;105:901–907.
- Lindqvist P, Calcutteea A, Henein M. Echocardiography in the assessment of right heart function. *Eur J Echocardiogr* 2008;9:225–234.
- Rudski LG, Lai WW, Afilalo J, Hua L, Handschumacher MD, Chandrasekaran K, Solomon SD, Louie EK, Schiller NB. Guidelines for the echocardiographic assessment of the right heart in adults: a report from the American Society of Echocardiography endorsed by the European Association of Echocardiography, a registered branch of the European Society of Cardiology, and the Canadian Society of Echocardiography. *J Am Soc Echocardiogr* 2010;23:685–713, quiz 786–788.
- Aujesky D, Obrosky DS, Stone RA, Auble TE, Perrier A, Cornuz J, Roy PM, Fine MJ. Derivation and validation of a prognostic model for pulmonary embolism. *Am J Respir Crit Care Med* 2005;172:1041–1046.
- Torbicki A, Perrier A, Konstantinides S, Agnelli G, Galiè N, Pruszczyk P, Bengel F, Brady AJ, Ferreira D, Janssens U, *et al.*; ESC Committee for Practice Guidelines (CPG). Guidelines on the diagnosis and management of acute pulmonary embolism: the Task Force for the Diagnosis and Management of Acute Pulmonary Embolism of the European Society of Cardiology (ESC). *Eur Heart J* 2008;29:2276–2315.
- Qanadli SD, El Hajjam M, Vieillard-Baron A, Joseph T, Mesurolle B, Oliva VL, Barré O, Bruckert F, Dubourg O, Lacombe P. New CT index to quantify arterial obstruction in pulmonary embolism: comparison with angiographic index and echocardiography. *AJR Am J Roentgenol* 2001;176:1415–1420.
- Castañer E, Gallardo X, Ballesteros E, Andreu M, Pallardó Y, Mata JM, Riera L. CT diagnosis of chronic pulmonary thromboembolism. *Radiographics* 2009;29:31–50, discussion 50–53.
- Wijesuriya S, Chandratreya L, Medford AR. Chronic pulmonary emboli and radiologic mimics on CT pulmonary angiography: a diagnostic challenge. *Chest* 2013;143:1460–1471.
- Fedullo P, Kerr KM, Kim NH, Auger WR. Chronic thromboembolic pulmonary hypertension. *Am J Respir Crit Care Med* 2011;183:1605–1613.
- Morris TA, Marsh JJ, Chiles PG, Auger WR, Fedullo PF, Woods VL Jr. Fibrin derived from patients with chronic thromboembolic pulmonary hypertension is resistant to lysis. *Am J Respir Crit Care Med* 2006;173:1270–1275.
- Pengo V, Lensing AW, Prins MH, Marchiori A, Davidson BL, Tiozzo F, Albanese P, Biasiolo A, Pegoraro C, Iliceto S, *et al.*; Thromboembolic Pulmonary Hypertension Study Group. Incidence of chronic thromboembolic pulmonary hypertension after pulmonary embolism. *N Engl J Med* 2004;350:2257–2264.
- Prandoni P, Lensing AWA, Prins MH, Bernardi E, Marchiori A, Bagatella P, Frulla M, Mosen L, Tormene D, Piccioli A, *et al.* Residual venous thrombosis as a predictive factor of recurrent venous thromboembolism. *Ann Intern Med* 2002;137:955–960.
- Rosenberg RD, Aird WC. Vascular-bed-specific hemostasis and hypercoagulable states. *N Engl J Med* 1999;340:1555–1564.
- Tunari N, Gibbs SJ, Win Z, Gin-Sing W, Graham A, Gishen P, Al-Nahhas A. Ventilation-perfusion scintigraphy is more sensitive than multidetector CTPA in detecting chronic thromboembolic pulmonary disease as a treatable cause of pulmonary hypertension. *J Nucl Med* 2007;48:680–684.
- Stein PD, Fowler SE, Goodman LR, Gottschalk A, Hales CA, Hull RD, LEEPER KV Jr, Popovich J Jr, Quinn DA, Sos TA, *et al.*; PIOPED II Investigators. Multidetector computed tomography for acute pulmonary embolism. *N Engl J Med* 2006;354:2317–2327.
- van Belle A, Büller HR, Huisman MV, Huisman PM, Kaasjager K, Kamphuisen PW, Kramer MH, Kruij MJ, Kwakkel-van Erp JM, Leebeek FW, *et al.*; Christopher Study Investigators. Effectiveness of managing suspected pulmonary embolism using an algorithm combining clinical probability, D-dimer testing, and computed tomography. *JAMA* 2006;295:172–179.
- Kearon C, Akl EA, Comerota AJ, Prandoni P, Bounameaux H, Goldhaber SZ, Nelson ME, Wells PS, Gould MK, Dentali F, *et al.*; American College of Chest Physicians. Antithrombotic therapy for VTE disease: antithrombotic therapy and prevention of thrombosis, 9th ed: American College of Chest Physicians evidence-based clinical practice guidelines. *Chest* 2012;141(2 Suppl):e419S–e494S. [Published erratum appears in *Chest* 142:1698–1704.]

Copyright © 2014 by the American Thoracic Society