

# Stroke

American Stroke  
Association<sup>SM</sup>

JOURNAL OF THE AMERICAN HEART ASSOCIATION

A Division of American  
Heart Association



**Left Atrial Appendage Exclusion for Stroke Prevention in Patients With  
Nonrheumatic Atrial Fibrillation**  
Orhan Onalan and Eugene Crystal

*Stroke* 2007, 38:624-630

doi: 10.1161/01.STR.0000250166.06949.95

Stroke is published by the American Heart Association, 7272 Greenville Avenue, Dallas, TX 75214  
Copyright © 2007 American Heart Association. All rights reserved. Print ISSN: 0039-2499. Online  
ISSN: 1524-4628

The online version of this article, along with updated information and services, is  
located on the World Wide Web at:

<http://stroke.ahajournals.org/content/38/2/624>

Subscriptions: Information about subscribing to *Stroke* is online at  
<http://stroke.ahajournals.org/subscriptions/>

Permissions: Permissions & Rights Desk, Lippincott Williams & Wilkins, a division of Wolters  
Kluwer Health, 351 West Camden Street, Baltimore, MD 21202-2436. Phone: 410-528-4050. Fax:  
410-528-8550. E-mail:  
[journalpermissions@lww.com](mailto:journalpermissions@lww.com)

Reprints: Information about reprints can be found online at  
<http://www.lww.com/reprints>

# Left Atrial Appendage Exclusion for Stroke Prevention in Patients With Nonrheumatic Atrial Fibrillation

Orhan Onalan, MD; Eugene Crystal, MD

**Abstract**—The efficacy of oral anticoagulation (OAC) for stroke prevention in patients with nonrheumatic atrial fibrillation (AF) has clearly been established. However, a substantial number of patients with AF who are at high risk for thromboembolic events are not candidates for long-term OAC. The left atrial appendix (LAA) is the most common place of thrombosis in patients with AF, and it can easily be excluded from the systemic circulation at the time of cardiac surgery by excision, ligation, suturing, or stapling. Currently, removal of the LAA at the time of mitral valve surgery is recommended to reduce future stroke risk. The ongoing LAA Occlusion Study (LAAOS) is evaluating the efficacy of the routine LAA occlusion in patients undergoing elective coronary artery bypass graft surgery. Recently, two devices specifically designed for percutaneous transcatheter LAA occlusion have been introduced: the Percutaneous LAA Transcatheter Occlusion (PLAATO; Appriva Medical Inc) and WATCHMAN LAA system (Atritech, Inc). More than 200 PLAATO devices were implanted worldwide in patients with nonrheumatic AF who were at high risk for ischemic stroke and not candidates for long-term OAC. In a follow-up time of 258 patient-years, an estimated 61% reduction in stroke risk was achieved with PLAATO procedure. The WATCHMAN Left Atrial Appendage System for Embolic PROTECTION in Patients With Atrial Fibrillation (PROTECT AF) study was designed to demonstrate the safety and efficacy of the WATCHMAN device in patients with nonvalvular AF who are eligible for long-term OAC. The trial is assessing whether the treatment arm (WATCHMAN device) is noninferior to the control arm (warfarin). Although present results suggest that LAA occlusion may reduce the long-term stroke risk, available data are still very limited. At present, percutaneous LAA occlusion may be an acceptable option in selected high-risk patients with AF who are not candidates for OAC. The current understanding of LAA exclusion for the prevention of stroke in patients with nonrheumatic AF is the major focus of this review. (*Stroke*. 2007;38[part 2]:624-630.)

**Key Words:** atrial fibrillation ■ left atrial appendage ■ stroke

Atrial fibrillation (AF) affects 3% to 5% of the population older than 65 years and it is responsible for 15% to 20% of ischemic strokes.<sup>1,2</sup> Overall, the risk of stroke in patients with nonrheumatic AF is approximately 5% per year<sup>3</sup>

## Left Atrial Appendage and Thromboembolism in Atrial Fibrillation

In patients with AF, the most common place of thrombosis is the left atrial appendage (LAA). In a review of 23 studies in which LAA was examined by autopsy, transesophageal echocardiography (TEE), or direct intraoperative inspection, intracardiac thrombus was identified in 13% of cases of both nonvalvular and valvular AF.<sup>4</sup> Furthermore, 57% of atrial thrombi in valvular AF occurred in the appendage, whereas in nonvalvular AF, 90% of left atrial thrombi were located in the atrial appendage (Table 1).

### Strategies for Prevention of Thromboembolism in Atrial Fibrillation

There are three logical ways to prevent cardioembolic events in patients with AF. The first is chronic anticoagulation. The

second is to exclude the LAA as a major embolic source from the circulation. The third is to prevent emboli from entering vital parts of the circulation.<sup>5</sup>

Multiple randomized, controlled trials have clearly established the efficacy of oral anticoagulation (OAC) in lowering the risk of stroke and death in patients with nonrheumatic AF.<sup>6</sup> However, chronic OAC is contraindicated in 14% to 44% patients with AF who are at risk of stroke.<sup>7</sup> Even in eligible patients, there are various barriers against prescription and maintenance of long-term OAC mainly related to the narrow therapeutic window requiring rigorous laboratory follow up. In clinical practice, oral anticoagulants are prescribed to only 15% to 66% of patients with AF who are at high risk for thromboembolic events and have no clear contraindication to their use.<sup>7</sup>

Because of the fact that in most patients, the LAA is a discrete anatomic structure,<sup>8-10</sup> it may be relatively easily excluded from systemic circulation (LAA exclusion) by excision at the time of cardiac surgery. Other techniques for LAA exclusion are obliteration or occlusion of this anatomic structure by ligation,

Received June 1, 2006; final revision received October 2, 2006; accepted October 3, 2006.

From Arrhythmia Services, Division of Cardiology, Sunnybrook Health Science Centre, University of Toronto, Toronto, Canada.

Correspondence to Eugene Crystal MD, Sunnybrook Health Sciences Centre, 2075 Bayview Avenue, Suite D-377, Toronto, ON M4N 3M5, Canada.

E-mail: eugene.crystal@sunnybrook.ca

© 2007 American Heart Association, Inc.

Stroke is available at <http://www.strokeaha.org>

DOI: 10.1161/01.STR.0000250166.06949.95

**TABLE 1. Review of Published Reports Detailing the Frequency and Site of Thrombus Location in Patients With Nonrheumatic Atrial Fibrillation\***

Setting	No. of Patients	Thrombus Location (n, %)		
		LA Appendage	LA Cavity	Total
TEE†	317	66 (20.8)	1 (0.3)	67 (21.1)
TEE	233	34 (14.6)	1 (0.4)	35 (15.0)
Autopsy	506	35 (6.9)	12 (2.4)	47 (9.3)
TEE	52	2 (3.8)	2 (3.8)	4 (7.7)
TEE	48	12 (25.0)	1 (2.1)	13 (27.1)
TEE and operation	171	8 (4.7)	3 (1.8)	11 (6.4)
ACUTE	549	67 (12.2)	9 (1.6)	76 (13.8)
TEE	272	19 (7.0)	0 (0)	19 (7.0)
TEE	60	6 (10.0)	0 (0)	6 (10.0)
Total	2208	249 (11.3)	29 (1.3)	278 (12.6)

\*Modified from references 4 and 43; †5% of patients in this trial had mitral stenosis or prosthetic mitral valve.

LA indicates left atrium; ACUTE, Assessment of Cardioversion Using Transesophageal Echocardiography Multicenter Trial.

sutures, staplers, or implantable devices. Recently, less invasive thoracoscopic and percutaneous transcatheter procedures using these techniques have been introduced for LAA exclusion. This is the major focus of this review.

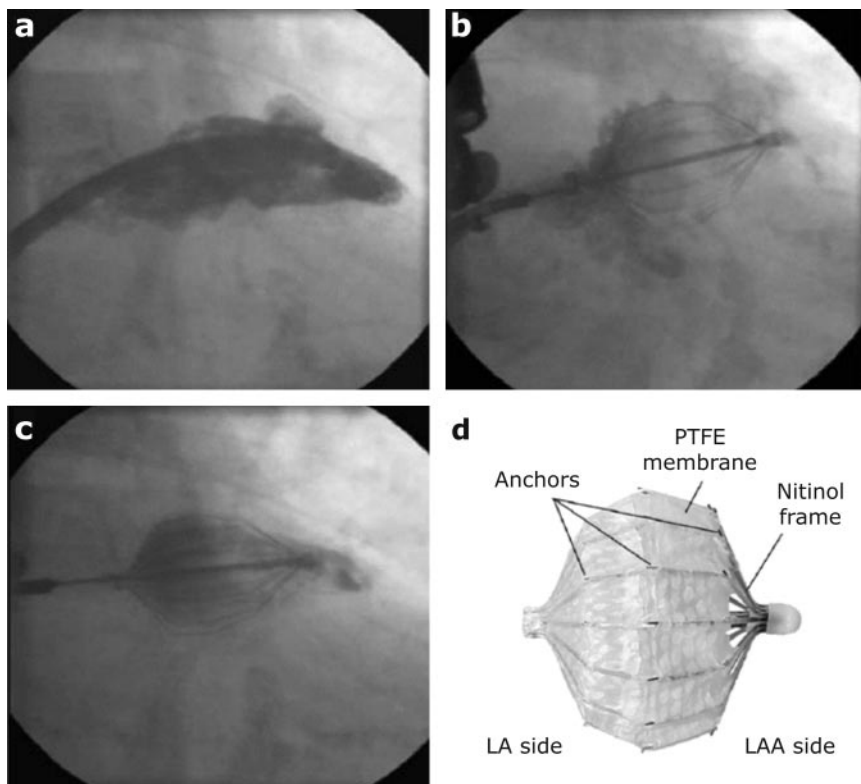
### Exclusion of the Left Atrial Appendage During Open Chest Surgery

Exclusion of LAA from systemic circulation was suggested when it was observed that in rheumatic heart disease, the

major site of thrombi is the left atrium and its appendage.<sup>11-13</sup> After the feasibility of canine LAA resection was shown by Hellerstein and his associates,<sup>11</sup> Maden<sup>12</sup> performed a LAA excision in two patients with AF and rheumatic mitral valve disease in 1949. In 1950, Beal et al<sup>13</sup> reported two cases of left and one case of right atrial appendectomy for prophylaxis of thromboembolism.

Johnson et al<sup>14</sup> reported prophylactic LAA excision in 437 patients undergoing open heart surgery, including 17 patients with preoperative AF. No later strokes were attributed to AF. In subsequent years, no patients were found to have atrial clots on TEE. The authors concluded that routine LAA excision is safe and should be considered whenever the chest is opened. Consistent with this, the absence of LAA ligation and the presence of left atrial thrombus were the only independent predictors of an embolic event during a mean follow up of 69.4 months in patients with previous mitral valve replacement.<sup>15</sup>

The LAA Occlusion Study (LAAOS) is evaluating the efficacy of the LAA occlusion in patients undergoing elective coronary artery bypass grafting (CABG) surgery with any one of the following four risk factors for AF and stroke: age >75 years, hypertension and age >65 years, previous stroke, or a history of AF.<sup>16</sup> Patients on OAC were not excluded. At the time of CABG surgery, suitable patients are randomized to undergo LAA occlusion or serve as a control in a 2:1 fashion favoring LAA occlusion. Recently, results of the pilot study (52 patients in the LAA occlusion and 25 patients in the control group) evaluating safety and efficacy of LAA occlusion performed at the time of CABG surgery were published.<sup>17</sup> Among patients having a postoperative TEE, complete occlusion of the LAA was achieved in 45% (five of 11)



**Figure 1.** LAA angiogram performed during PLAATO procedure. a, LAA angiogram before device implantation provides information on the size and morphology of the LAA cavity and ostium. Completeness of LAA occlusion could be evaluated by (b) proximal and (c) distal dye injection after PLAATO device deployed into the LAA. d, PLAATO device. LA indicates left atrial; PTFE, polytetrafluoroethylene.

of cases using sutures and in 72% (24 of 33) using a stapler. In addition to the use of a stapler, increased surgeon experience was associated with a higher rate of LAA occlusion. Two patients in the LAA occlusion group had perioperative thromboembolic events and no additional stroke was noted during an average follow up of  $13 \pm 7$  months.

LAA occlusion is widely accepted, but the evidence base is limited. In many centers, the LAA is removed during mitral valve surgery to reduce stroke risk in patients with valvular heart disease undergoing cardiac operation.<sup>18,19</sup>

### Thoracoscopic Left Atrial Appendectomy

Odell et al<sup>20</sup> performed the first thoracoscopic obliteration (five with a stapler and five with an Endoloop) of the LAA in dogs and human cadavers and showed the feasibility of this method. Johnson et al<sup>14</sup> performed thoracoscopic LAA excision in seven patients with chronic AF as an isolated surgical procedure. Blackshear et al<sup>21</sup> reported results of the first study with thoracoscopic obliteration of LAA in 15 (loop snare in eight patients and a stapler in seven patients) patients with at least one risk factor for stroke and either an absolute contraindication to OAC or documentation of prior LAA thrombosis despite adequate OAC. The procedure was completed in 14 of 15 patients; one patient required urgent conversion to open thoracotomy because of bleeding. Patients were followed for 8 to 60 months. One fatal stroke occurred 55 months after surgery and one nondisabling stroke 3 months after surgery happened. Two deaths were observed: one after coronary bypass surgery performed 34 months after the initial operation and one from hepatic failure in a patient with chronic hepatitis C. This study confirmed that the procedure is technically feasible, but its effect on prevention of stroke needs to be evaluated.

Newly developed minimally invasive/thoracoscopic tools for LAA occlusion have emerged recently.<sup>22,23</sup> The tools are either a stapler<sup>24,25</sup> or clipping device.<sup>22,23</sup> The clipping device, constructed from two stainless steel strips covered with a knit braided polyester fabric (AtriCure, Inc), was successfully implanted at the base of the left atrial appendage in animals.<sup>22,23</sup> Accordingly, numerous recent reports suggest a recent expansion of minimal invasive/thoracoscopic LAA occlusion, especially when performed in conjunction with the minimally invasive MAZE procedure for ablation of atrial fibrillation.<sup>24,25</sup>

### Percutaneous Transcatheter Occlusion of the Left Atrial Appendage

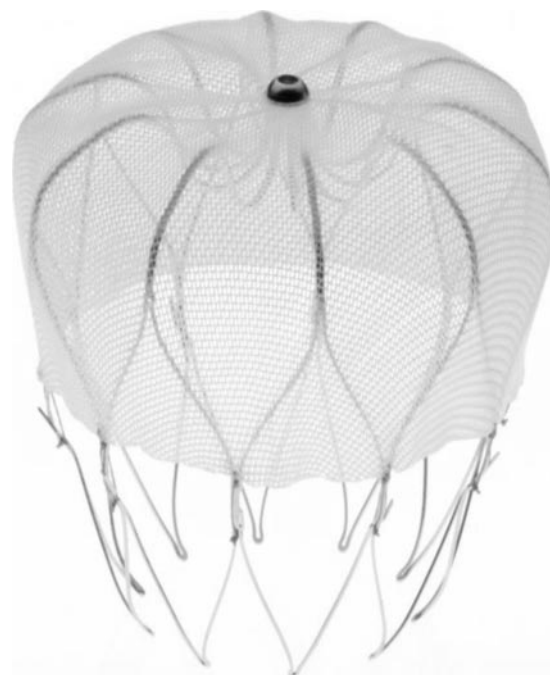
Currently, there are two devices specifically designed for LAA occlusion: the Percutaneous LAA Transcatheter Occlusion (PLAATO; Appriva Medical Inc) and the WATCHMAN LAA system (Atritech, Inc).

#### The PLAATO System

The PLAATO was the first device developed specifically for LAA occlusion.<sup>26,27</sup> The PLAATO device consists of a self-expandable nitinol cage covered with an occlusive expanded polytetrafluoroethylene membrane (Figure 1). The membrane occludes the orifice of the LAA but allows tissue incorporation into the device, and small anchors along the

struts to assist with device anchoring and encourage healing. After venous and transseptal puncture, the device is delivered under TEE and fluoroscopic guidance through a specially designed sheath and deployed into the LAA. The delivery system allows for the collapse and repositioning or complete removal of the implant in the case of a suboptimal result. Adequacy of LAA occlusion can be assessed by distal (through a special lumen in the device) and proximal (through the distal sheath in the left atrium) dye injections (Figure 1) as well as TEE imaging. Several sizes of the device (range of diameters: 15 to 32 mm) have been developed to accommodate the variations in LAA anatomy and a device with 20% to 40% oversizing has been preferred. Other details of implantation technique have been explained elsewhere.<sup>26,28</sup>

Initial animal study and early clinical experience have shown the feasibility of the PLAATO procedure.<sup>26,27</sup> Recently, results of two concurrent feasibility studies that were conducted in Europe and North America were published.<sup>28</sup> The LAA occlusion was successful in 108 of 111 (97.3%) patients with nonrheumatic AF who were at high risk for ischemic stroke and not candidates for long-term OAC. A total of nine procedure-related serious adverse events occurred in seven patients. None of the serious adverse events were considered to be device-related. Successful LAA occlusion was achieved in 97.7%, 100%, and 98% of patients immediately after the procedure, at 1 month, and at 6 months, respectively. There was no mobile thrombus, mitral valve damage, or pulmonary vein obstruction seen on TEE performed up to 6 months after the procedure. No device migration or dislodgement was noted. There were seven major adverse events in five patients, including two strokes and four cardiac or neurologic deaths, during the average



**Figure 2.** WATCHMAN LAA device. The implant has a 160- $\mu\text{m}$  polytetrafluoroethylene membrane on the proximal face of a nitinol cage and incorporates a row of fixation bars around the midperimeter.

**TABLE 2. Summary of Human Experience With Percutaneous Transcatheter LAA Occlusion**

Device/Procedure	N	Mean Age, Years	Reported Serious Procedural Complication	Mean Follow Up, Months	Stroke	TIA	Deaths	Efficacy
<b>PLAATO</b>								
Ostermayer, 2005 <sup>28</sup>	108	71	1 pleural effusion 2 pericardial effusion 2 cardiac tamponade 1 hemothorax 1 deep vein thrombosis 1 brachial plexus palsy 1 dyspnea requiring reintubation	9.8	2	3	6	65% reduction in stroke risk*
Bayard, 2005 <sup>29</sup>	205	NA	6 pericardial effusion 7 cardiac tamponade	14.7	5	NA	9	61% reduction in stroke risk*
<b>WATCHMAN</b>								
Sick, 2006 <sup>32</sup>	66	69	2 device embolization 5 pericardial effusion (2 requiring intervention) 1 air embolism	7.8†	0	2	1	Warfarin could be stopped at 6 months in 97.1% of patients
<b>AMPLATZ</b>								
Meier, 2003 <sup>34</sup>	16‡	66§	1 device embolization	4	0	0	0	—
<b>PATCH</b>								
Sideris, 2006 <sup>35</sup>	5	NA	0	NA	0	0	0	—

\*Estimated stroke risk reduction based on CHADS2 (congestive heart failure, hypertension, age >75 years, diabetes, stroke, or TIA) stroke risk scoring system; †based on 101.4 implant-years; ‡in six patients as an additional procedure; §calculated from provided data. N indicates no. of implanted patients; NA, not available.

follow up of 9.8 months (90.7 documented implant years). A total of six patients (5.4%) died during the study period and none were adjudicated as device- or procedure-related. Of the 111 enrolled patients, two experienced a stroke 173 and 215 days after the implant procedure. Three transient ischemic attacks (TIA) occurred in two patients. The observed and estimated annual stroke rate was 2.2% and 6.3%, respectively, representing a 65% relative stroke risk reduction with the PLAATO procedure. Currently, data on 210 patients who underwent the PLAATO procedure worldwide are available.<sup>29</sup> Device implantation was successful in 205 of 210 (97.6%) patients. In a follow up of 258 patient-years (mean follow up of 14.7 months), five patients had a stroke with an estimated 61% reduction from the expected annual risk of stroke. Nine patients died for various reasons not related to the procedure or the device.

Preliminary data regarding the long-term risk of thrombus formation and the development of pulmonary venous obstruction with the PLAATO procedure were recently reported.<sup>30</sup> In 48 patients (84 patient-years), echocardiographic examinations were performed 24 hours before the procedure; during the occlusion; before discharge from the hospital; and after 1, 3, 6, 12, 24, 36, and 48 months. Presence of thrombi could be documented in two cases in follow up. In one patient, a thrombus was detected on the surface of the occluding device; another patient showed a thrombus at the interatrial septum. Peak flow velocities of the pulmonary veins were not significantly higher after positioning of the device. In 34 patients who underwent the PLAATO procedure, cerebral MRI was performed before the procedure 48 hours after and 6, 12, and 24 months after the procedure to assess for cerebral microembolism.<sup>31</sup> MRI performed before the occlusion de-

tected the presence of former cerebral embolism in 12 of the 34 patients. Follow-up MRI studies excluded the presence of new strokes in all patients.

**WATCHMAN LAA System**

Another percutaneous device for LAA occlusion is the WATCHMAN LAA system (Atritech, Inc., Minneapolis, Minn). The device is placed in the LAA through a transseptal approach. The implant has a 160-µm polyethylene membrane on the proximal face of a nitinol cage and incorporates a row of fixation barbs around the midperimeter (Figure 2). The WATCHMAN device is available in five sizes (from 21 to 33 mm). The device has been implanted since 2002 in Europe and since 2003 in the United States.<sup>32</sup> Patients were assessed at 45 days and 6 months postprocedure with TEE and chest x-ray and had annual clinical assessments thereafter. Clinical end point was rate of ischemic stroke, systemic embolism, and major bleeding. In 66 patients worldwide, the device has been implanted successfully with 101.4 cumulative implant years. Two patients experienced device embolization; both were successfully retrieved percutaneously and no further embolizations occurred. Five pericardial effusions (two of them needing percutaneous puncture) and one major air embolism occurred without long-term sequelae. At follow up, if the device was found to be stable and no thrombus was detected on TEE, then warfarin was stopped. In 97.1% of patients warfarin could be discontinued at 6 months. Four patients, however, had a flat thrombus on the device at 6 months and one of these patients had a TIA. Another patient with a history of TIA experienced the event without visible LAA thrombus. No ischemic stroke or systemic embolism has occurred. One patient died after 9 months as a result of an

**TABLE 3. Summary of Reported Rate of Incomplete LAA Occlusion\***

	Evaluation Time	Criteria for Incomplete LAA Occlusion	Incomplete LAA occlusion rates
<b>Surgical LAA occlusion</b>			
Healey, 2005 <sup>17</sup>	8 weeks after surgery	A residual LAA length of >1.0 cm or Presence of leak	55% with sutures (6 of 11) 28% with staple (9 of 33) 34% overall
Kanderian, 2006 <sup>36</sup>	2 weeks to 9 years after surgery	Patent LAA Residual LAA Flow in the LAA	9.5% with excision (2 of 21) 72% with suture (55 of 76) 66% with staple (23 of 35)
Katz, 2000 <sup>37</sup>	Postoperatively and 6 days to 13 years (mean: 64 months) after surgery	Presence of leak	36% (18 of 50)
Garcia-Fernandez, 2003 <sup>15</sup>	1–329 months (median: 69.4) after surgery	Presence of leak	10% (6 of 58)
Schneider, 2005 <sup>38</sup>	23–159 days (mean: 51) after surgery	Presence of leak	83% (5 of 6)
<b>Percutaneous transcatheter LAA occlusion</b>			
Ostermayer, 2005 <sup>28</sup>	6 months after procedure	Moderate to severe leak	2% (1 of 50)
Meier, 2003 <sup>34</sup>	1 day to 5 months after procedure	Flow in the LAA	0% (0 of 14)

\*Incomplete occlusion was evaluated with transesophageal echocardiography in all studies.

ascending aortic dissection. Autopsy documented a stable, well-endothelialized device. Preliminary data suggest the WATCHMAN LAA system is safe and feasible. A prospective, randomized study comparing the WATCHMAN device with long-term warfarin therapy is currently recruiting patients.<sup>33</sup> The WATCHMAN Left Atrial Appendage System for Embolic PROTECTION in Patients With Atrial Fibrillation (PROTECT AF) study is designed to demonstrate the safety and efficacy of the WATCHMAN device in patients with nonvalvular atrial fibrillation who are eligible for long-term OAC. The trial is assessing whether the treatment arm (WATCHMAN device) is noninferior to the control arm (warfarin) and is expected to enroll 200 patients.

LAA can also be occluded by the Amplatzer septal occluder device with a somewhat similar technique to that used in the closure of interatrial septal defects.<sup>34</sup> Short-term results from 15 patients who underwent LAA occlusion with this approach are favorable. Moreover, successful transcatheter patch obliteration of the LAA was also reported.<sup>35</sup> Currently available data on experience with the percutaneous transcatheter LAA occlusion is summarized in Table 2.

### Potential Concerns With Left Atrial Appendage Exclusion

Despite the advantage of direct visualization of the LAA, incomplete occlusion is one of the major concerns with surgical approach (Table 3). In the LAAOS study of patients having a postoperative TEE, incomplete occlusion of the LAA was observed in 55% of cases using sutures and in 28% of those using a stapler.<sup>17</sup> One retrospective study evaluated success rates of different surgical LAA occlusion techniques by TEE performed 2 weeks to 9 years after surgery.<sup>36</sup> Among 134 patients who underwent the procedure between 1993 and 2004, incomplete LAA occlusion was detected in two of 21 (9.5%) patients with excision, 55 of 76 (72%) patients with suture, and 23 of 35 (66%) patients with staples suggesting that excision is the most efficient way to exclude LAA. It appears that partial exclusion reduces the efficacy of this

procedure. In one series, TEE revealed incomplete LAA ligation in 18 of 50 (36%) patients who underwent mitral valve surgery and ligation of the LAA.<sup>37</sup> Moreover, spontaneous echo contrast or thrombus was identified within appendages in nine of 18 (50%) patients with incomplete ligation, and four of these 18 (22%) patients had thromboembolic events. In a retrospective echocardiographic study, incomplete ligation of LAA was noted in six of 58 patients who underwent mitral valve surgery, and it was associated with a significant increase in embolic events.<sup>15</sup> Among six consecutive patients who had LAA closure at the time of valve surgery, complete LAA closure was detected in only one patient on TEE performed 23 to 159 days (mean: 51 days) postoperatively.<sup>38</sup> All patients with incomplete LAA closure had spontaneous echocardiographic contrast or thrombus in the LAA and one of these patients experienced a stroke 4 weeks after surgery.

There are also some potential procedural or device-related risks with percutaneous closure of LAA. Although rare, over- or undersizing, device migration, dislodgement or embolization, and cardiac perforation may be potential problems; and repeat procedures may be required. Iatrogenic small atrial septal defects usually disappeared within 6 months of the procedure. Persistence of atrial septal defects up to 6 months was observed in three of 48 (6%) patients evaluated with TEE.<sup>30</sup> Traumatic damage to adjacent structures, including left pulmonary veins and the circumflex branch of the left coronary artery may occur. The most common complication after percutaneous closure of LAA is hemopericardium, and this developed in 6% of patients (13 of 210) and more than half of these cases developed cardiac tamponade.<sup>29</sup> One patient had to be operated on for this complication.<sup>29</sup> Despite being a percutaneous technique, more than half of the PLAATO procedures (51.3%) were performed under general anesthesia.<sup>28</sup>

It should be noted that not all LAAs may not be suitable for occlusion. For example, LAA may be too large or too fragile.

In the LAAOS study, LAA was not suitable for occlusion in 20 (21%) during surgery.<sup>17</sup>

There are other concerns related to the function of the LAA. The LAA may play a role in mediating thirst<sup>39</sup> because it is the most important source of atrial natriuretic factor and may have a modulator role in the regulation of left atrial volume–pressure relationships. Thus, LAA occlusion may contribute to the altered left atrial compliance.<sup>40</sup> Reduced atrial natriuretic peptide release and water retention was observed in patients with bilateral atrial appendectomy.<sup>41</sup> On the other hand, preserving the right atrial appendage may attenuate this effect.<sup>42</sup> Therefore, fluid retention may not be a problem with isolated LAA occlusion.

### Conclusion

Although present results suggest that the LAA occlusion may reduce the long-term stroke risk, available data are still very limited. Currently, two pivotal randomized studies are underway (LAAOS and PROTECT AF), and it is worthwhile to wait for the results of these studies before making a definite conclusion. Nevertheless, at present, data on embolic risk reduction with percutaneous LAA occlusion is encouraging, and it may be an acceptable option in selected high-risk patients with AF who are not candidates for OAC. In addition, a LAA occlusion may be able to reduce recurrence in patients who developed stroke despite being on OAC.

### Disclosure

None.

### References

- Go AS, Hylek EM, Phillips KA, Chang Y, Henault LE, Selby JV, Singer DE. Prevalence of diagnosed atrial fibrillation in adults: national implications for rhythm management and stroke prevention: the anticoagulation and risk factors in atrial fibrillation (ATRIA) study. *JAMA*. 2001; 285:2370–2375.
- Crystal E, Connolly SJ. Role of oral anticoagulation in management of atrial fibrillation. *Heart*. 2004;90:813–817.
- Risk factors for stroke and efficacy of antithrombotic therapy in atrial fibrillation: analysis of pooled data from five randomized controlled trials. *Arch Intern Med*. 1994;154:1449–1457.
- Blackshear JL, Odell JA. Appendage obliteration to reduce stroke in cardiac surgical patients with atrial fibrillation. *Ann Thorac Surg*. 1996; 61:755–759.
- Nishri B, Lieber BB, Cherniahovsky O, Chibulsky G, Fouchs Y, Rapaport A, Bushi D, Harris D, Grad Y. The effect of radial force on the migration characteristics of a new permanent arterial diversion device for embolic stroke prevention. Summer bioengineering Conference; Key Biscayne, Florida. Available at: <http://www.tulane.edu/~sbc2003/pdfdocs/0171.PDF>. Accessed March 13, 2005.
- Hart RG, Benavente O, McBride R, Pearce LA. Antithrombotic therapy to prevent stroke in patients with atrial fibrillation: a meta-analysis. *Ann Intern Med*. 1999;131:492–501.
- Onalan O, Lashevsky I, Hamad A, Crystal E. Nonpharmacologic stroke prevention in atrial fibrillation. *Exp Rev Cardiovasc Ther*. 2005;3: 619–633.
- Donal E, Yamada H, Leclercq C, Herpin D. The left atrial appendage, a small, blind-ended structure: a review of its echocardiographic evaluation and its clinical role. *Chest*. 2005;128:1853–1862.
- Stollberger C, Schneider B, Finsterer J. Elimination of the left atrial appendage to prevent stroke or embolism? Anatomic, physiologic, and pathophysiologic considerations. *Chest*. 2003;124:2356–2362.
- Al-Saady NM, Obel OA, Camm AJ. Left atrial appendage: structure, function, and role in thromboembolism. *Heart*. 1999;82:547–554.
- Hellerstein HK, Sinaiko E, Dolgin M. Amputation of the canine atrial appendages. *Proceedings of the Society for Experimental Biology and Medicine*. 1947;66:337.
- Madden JL. Resection of the left auricular appendix—a prophylaxis for recurrent arterial emboli. *JAMA*. 1949;140:769–772.
- Beal JM, Longmire WP, Leake WH. Resection of the auricular appendages. *Ann Surg*. 1950;132:517–530.
- Johnson WD, Ganjoo AK, Stone CD, Sriyvas RC, Howard M. The left atrial appendage: our most lethal human attachment! Surgical implications. *Eur J Cardiothorac Surg*. 2000;17:718–722.
- Garcia-Fernandez MA, Perez-David E, Quiles J, Peralta J, Garcia-Rojas I, Bermejo J, Moreno M, Silva J. Role of left atrial appendage obliteration in stroke reduction in patients with mitral valve prosthesis: a transechocardiographic study. *J Am Coll Cardiol*. 2003;42:1253–1258.
- Crystal E, Lamy A, Connolly SJ, Kleine P, Hohnloser SH, Semelhago L, Abouzahr L, Cybulsky I, Shragge B, Teoh K, Lonn E, Sawchuk C, Oezaslan F. Left atrial appendage occlusion study (LAAOS): a randomized clinical trial of left atrial appendage occlusion during routine coronary artery bypass graft surgery for long-term stroke prevention. *Am Heart J*. 2003;145:174–178.
- Healey JS, Crystal E, Lamy A, Teoh K, Semelhago L, Hohnloser SH, Cybulsky I, Abouzahr L, Sawchuk C, Carroll S, Morillo C, Kleine P, Chu V, Lonn E, Connolly SJ. Left atrial appendage occlusion study (LAAOS): results of a randomized controlled pilot study of left atrial appendage occlusion during coronary bypass surgery in patients at risk for stroke. *Am Heart J*. 2005;150:288–293.
- Bando K, Kobayashi J, Hirata M, Satoh T, Niwaya K, Tagusari O, Nakatani S, Yagihara T, Kitamura S. Early and late stroke after mitral valve replacement with a mechanical prosthesis: risk factor analysis of a 24-year experience. *J Thorac Cardiovasc Surg*. 2003;126:358–364.
- Bonow RO, Carabello B, de Leon AC Jr, Edmunds LH Jr, Fedderly BJ, Freed MD, Gaasch WH, McKay CR, Nishimura RA, O’Gara PT, O’Rourke RA, Rahimtoola SH, Ritchie JL, Cheitlin MD, Eagle KA, Gardner TJ, Garson A Jr, Gibbons RJ, Russell RO, Ryan TJ, Smith SC Jr. Guidelines for the management of patients with valvular heart disease: executive summary. A report of the American College of Cardiology/American Heart Association Task Force on Practice Guidelines (Committee on Management of Patients With Valvular Heart Disease). *Circulation*. 1998;98:1949–1984.
- Odell JA, Blackshear JL, Davies E, Byrne WJ, Kollmorgen CF, Edwards WD, Orszulak TA. Thoracoscopic obliteration of the left atrial appendage: potential for stroke reduction. *Ann Thorac Surg*. 1996;61: 565–569.
- Blackshear JL, Johnson WD, Odell JA, Baker VS, Howard M, Pearce L, Stone C, Packer DL, Schaff HV. Thoracoscopic extracardiac obliteration of the left atrial appendage for stroke risk reduction in atrial fibrillation. *J Am Coll Cardiol*. 2003;42:1249–1252.
- Salzberg SP, Anyanwu A, Filsoufi F, Rahmanian P, Castillo J, Fallon J, Adams DH. Left-atrial appendage occlusion with a new clip device: preliminary results in primates. *International Society for Minimally Invasive Cardiothoracic Surgery. 8th Annual Scientific Meeting*. 2005. Available at: [www.ismics.org/abstracts/2006/MP11.cgi](http://www.ismics.org/abstracts/2006/MP11.cgi). Accessed May 1, 2006.
- Kamohara K, Fukamachi K, Ootaki Y, Akiyama M, Zahr F, Kocpek MW, Dessoffey R, Popovic ZB, Daimon M, Cosgrove DM, Gillinov AM. A novel device for left atrial appendage exclusion. *J Thorac Cardiovasc Surg*. 2005;130:1639–1644.
- Wolf RK, Schneeberger EW, Osterday R, Miller D, Merrill W, Flege JB Jr, Gillinov AM. Video-assisted bilateral pulmonary vein isolation and left atrial appendage exclusion for atrial fibrillation. *J Thorac Cardiovasc Surg*. 2005;130:797–802.
- Balkhy HH, Chapman PD, Arnsdorf SE. Minimally invasive atrial fibrillation ablation combined with a new technique for thoracoscopic stapling of the left atrial appendage: case report. *Heart Surg Forum*. 2004;7: 353–355.
- Sievert H, Lesh MD, Trepels T, Omran H, Bartorelli A, Della Bella P, Nakai T, Reisman M, DiMario C, Block P, Kramer P, Fleschenberg D, Krumdorf U, Scherer D. Percutaneous left atrial appendage transcatheter occlusion to prevent stroke in high-risk patients with atrial fibrillation: early clinical experience. *Circulation*. 2002;105:1887–1889.
- Nakai T, Lesh MD, Gerstenfeld EP, Virmani R, Jones R, Lee RJ. Percutaneous left atrial appendage occlusion (PLAATO) for preventing cardioembolism: first experience in canine model. *Circulation*. 2002;105: 2217–2222.
- Ostermayer SH, Reisman M, Kramer PH, Matthews RV, Gray WA, Block PC, Omran H, Bartorelli AL, Della Bella P, Di Mario C, Pappone C, Casale PN, Moses JW, Poppas A, Williams DO, Meier B, Skanes A, Teirstein PS, Lesh MD, Nakai T, Bayard Y, Billinger K, Trepels T,

- Krumsdorf U, Sievert H. Percutaneous left atrial appendage transcatheter occlusion (PLAATO system) to prevent stroke in high-risk patients with non-rheumatic atrial fibrillation: results from the international multi-center feasibility trials. *J Am Coll Cardiol*. 2005;46:9–14.
29. Bayard Y, Omran H, Kramer P, Matthews R, Reisman M, Block P, Ostermayer S, Leetz M, Fischer E, Sievert H. Worldwide experience of percutaneous left atrial appendage transcatheter occlusion (PLAATO). *J Neurol Sci*. 2005;238:S70–S70.
  30. Schmidt H, Hammerstingl C, von der Recke G, Hardung D, Omran H. Long-term follow-up in patients with percutaneous left atrial appendage transcatheter occlusion system (PLAATO): risk of thrombus formation and development of pulmonary venous obstruction after percutaneous left atrial appendage occlusion. *J Am Coll Cardiol*. 2006;47:36A.
  31. Omran H, Schmidt H, Hammerstingl C, von der Recke G, Luderitz B, Hardung D. Percutaneous occlusion of the left atrial appendage: cerebral magnetic resonance imaging to determine long term risk of cerebral embolism after the procedure. *J Am Coll Cardiol*. 2005;45:101A.
  32. Sick PB, Ulrich M, Hauptmann KE, Grube E, Holmes D, Turi Z, Mooney M, Almany S, Mishkel G, Yakubov S, Schuler G. Stroke prevention technology for patients with non-valvular AF—worldwide experience with the new watchman LAA system. *J Am Coll Cardiol*. 2006;47:36A.
  33. Protect AF—WATCHMAN left atrial appendage system for embolic protection in patients with atrial fibrillation. Available at: [www.Clinicaltrials.gov/ct/show/nct00129545?Order=1](http://www.Clinicaltrials.gov/ct/show/nct00129545?Order=1). Accessed April 9, 2006.
  34. Meier B, Palacios I, Windecker S, Rotter M, Cao QL, Keane D, Ruiz CE, Hijazi ZM. Transcatheter left atrial appendage occlusion with Amplatzer devices to obviate anticoagulation in patients with atrial fibrillation. *Catheter Cardiovasc Interv*. 2003;60:417–422.
  35. Sideris EB, Toumanidis S, Rokas S, Macuil B, Mouloupoulos S. Transcatheter patch obliteration of the left atrial appendage: experimental validation and early clinical experience. *J Am Coll Cardiol*. 2006;47:1B.
  36. Kanderian AS, Gillinov AM, Pettersson GB, Klein AL. Success of surgical left atrial appendage occlusion techniques assessed by transesophageal echocardiography. *J Am Coll Cardiol*. 2006;47:152A.
  37. Katz ES, Tsiamtsiouris T, Applebaum RM, Schwartzbard A, Tunick PA, Kronzon I. Surgical left atrial appendage ligation is frequently incomplete: a transesophageal echocardiographic study. *J Am Coll Cardiol*. 2000;36:468–471.
  38. Schneider B, Stollberger C, Sievers HH. Surgical closure of the left atrial appendage—a beneficial procedure. *Cardiology*. 2005;104:127–132.
  39. Zimmerman MB, Blaine EH, Stricker EM. Water intake in hypovolemic sheep: effects of crushing the left atrial appendage. *Science*. 1981;211:489–491.
  40. Stollberger C, Finsterer J, Ernst G, Schneider B. Is left atrial appendage occlusion useful for prevention of stroke or embolism in atrial fibrillation. *Z Kardiol*. 2002;91:376–379.
  41. Yoshihara F, Nishikimi T, Kosakai Y, Isobe F, Matsuoka H, Takishita S, Kawashima Y, Saito Y, Matsuo H, Kangawa K. Atrial natriuretic peptide secretion and body fluid balance after bilateral atrial appendectomy by the maze procedure. *J Thorac Cardiovasc Surg*. 1998;116:213–219.
  42. Omari BO, Nelson RJ, Robertson JM. Effect of right atrial appendectomy on the release of atrial natriuretic hormone. *J Thorac Cardiovasc Surg*. 1991;102:272–279.
  43. Klein AL, Grimm RA, Murray RD, Apperson-Hansen C, Asinger RW, Black IW, Davidoff R, Erbel R, Halperin JL, Orsinelli DA, Porter TR, Stoddard MF. Use of transesophageal echocardiography to guide cardioversion in patients with atrial fibrillation. *N Engl J Med*. 2001;344:1411–1420.