



BTS guidelines for the insertion of a chest drain

D Laws, E Neville and J Duffy

Thorax 2003 58: ii53-ii59

doi: 10.1136/thorax.58.suppl_2.ii53

Updated information and services can be found at:

http://thorax.bmj.com/content/58/suppl_2/ii53.full.html

These include:

References

This article cites 61 articles, 26 of which can be accessed free at:

http://thorax.bmj.com/content/58/suppl_2/ii53.full.html#ref-list-1

Article cited in:

http://thorax.bmj.com/content/58/suppl_2/ii53.full.html#related-urls

Email alerting service

Receive free email alerts when new articles cite this article. Sign up in the box at the top right corner of the online article.

Notes

To order reprints of this article go to:

<http://thorax.bmj.com/cgi/reprintform>

To subscribe to *Thorax* go to:

<http://thorax.bmj.com/subscriptions>

BTS guidelines for the insertion of a chest drain

D Laws, E Neville, J Duffy, on behalf of the British Thoracic Society Pleural Disease Group, a subgroup of the British Thoracic Society Standards of Care Committee

Thorax 2003;58(Suppl II):ii53–ii59

1 BACKGROUND

In current hospital practice chest drains are used in many different clinical settings and doctors in most specialities need to be capable of their safe insertion. The emergency insertion of a large bore chest drain for tension pneumothorax following trauma has been well described by the Advanced Trauma and Life Support (ATLS) recommendations in their instructor's manual¹ and there have been many general descriptions of the step by step method of chest tube insertion.^{2–9}

It has been shown that physicians trained in the method can safely perform tube thoracostomy with 3% early complications and 8% late.¹⁰ In these guidelines we discuss the safe insertion of chest tubes in the controlled circumstances usually encountered by physicians. A summary of the process of chest drain insertion is shown in fig 1.

2 TRAINING

- **All personnel involved with insertion of chest drains should be adequately trained and supervised. [C]**

Before insertion of a chest drain, all operators should have been adequately trained and have completed this training appropriately. In all other circumstances, insertion should be supervised by an appropriate trainer. This is part of the SHO core curriculum training process issued by the Royal College of Physicians and trainees should be expected to describe the indications and complications. Trainees should ensure each procedure is documented in their log book and signed by the trainer. With adequate instruction, the risk of complications and patient pain and anxiety can be reduced.¹¹

These guidelines will aid the training of junior doctors in the procedure and should be readily available for consultation by all doctors likely to be required to carry out a chest tube insertion.

3 INDICATIONS

Chest tubes may be useful in many settings, some of which are listed in box 1.

4 PRE-DRAINAGE RISK ASSESSMENT

- **Risk of haemorrhage: where possible, any coagulopathy or platelet defect should be corrected prior to chest drain insertion but routine measurement of the platelet count and prothrombin time are only recommended in patients with known risk factors. [C]**
- **The differential diagnosis between a pneumothorax and bullous disease requires careful radiological assessment. Similarly it is important to differentiate between the presence of collapse and a**

Box 1 Indications for chest drain insertion

- Pneumothorax
 - in any ventilated patient
 - tension pneumothorax after initial needle relief
 - persistent or recurrent pneumothorax after simple aspiration
 - large secondary spontaneous pneumothorax in patients over 50 years
- Malignant pleural effusion
- Empyema and complicated parapneumonic pleural effusion
- Traumatic haemopneumothorax
- Postoperative—for example, thoracotomy, oesophagectomy, cardiac surgery

pleural effusion when the chest radiograph shows a unilateral “whiteout”.

- **Lung densely adherent to the chest wall throughout the hemithorax is an absolute contraindication to chest drain insertion. [C]**
- **The drainage of a post pneumonectomy space should only be carried out by or after consultation with a cardiothoracic surgeon. [C]**

There is no published evidence that abnormal blood clotting or platelet counts affect bleeding complications of chest drain insertion. However, where possible it is obvious good practice to correct any coagulopathy or platelet defect prior to drain insertion. Routine pre-procedure checks of platelet count and/or prothrombin time are only required in those patients with known risk factors. For elective chest drain insertion, warfarin should be stopped and time allowed for its effects to resolve.

5 EQUIPMENT

All the equipment required to insert a chest tube should be available before commencing the procedure and are listed below and illustrated in fig 2.

- Sterile gloves and gown
- Skin antiseptic solution, e.g. iodine or chlorhexidine in alcohol
- Sterile drapes
- Gauze swabs
- A selection of syringes and needles (21–25 gauge)
- Local anaesthetic, e.g. lignocaine (lidocaine) 1% or 2%
- Scalpel and blade
- Suture (e.g. “1” silk)
- Instrument for blunt dissection (e.g. curved clamp)

See end of article for authors' affiliations

Correspondence to:
Dr D Laws, Department of Thoracic Medicine, Royal Bournemouth Hospital, Castle Lane East, Bournemouth BH7 7DW, UK; diane.laws@rbch-tr.swest.nhs.uk

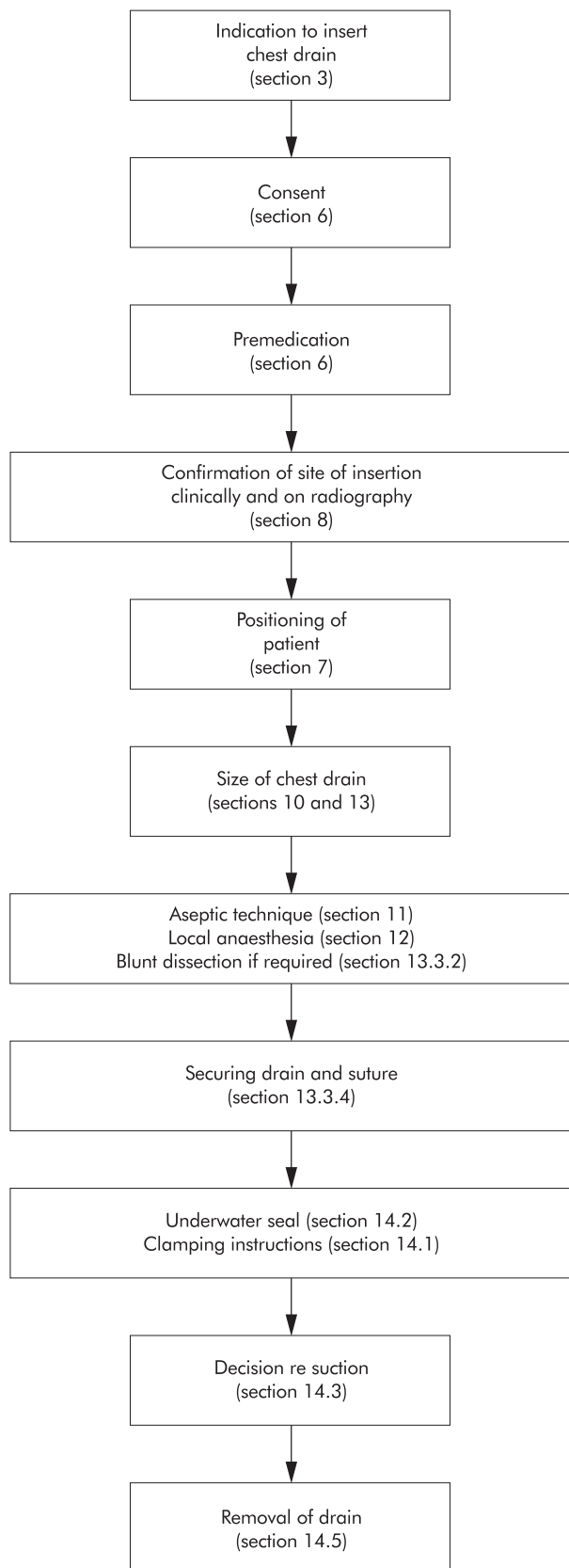


Figure 1 Summary of chest drain insertion process.

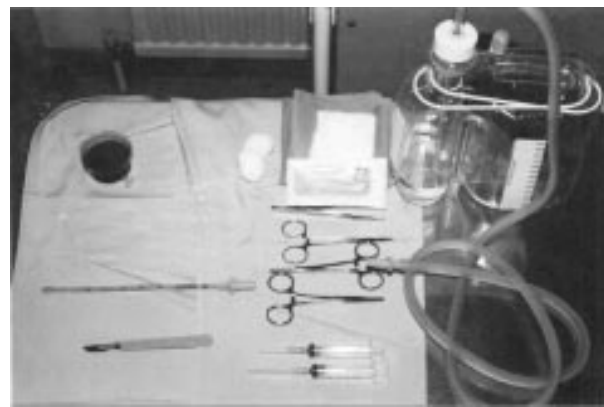

Figure 2 Equipment required for insertion of chest drains.

- Guidewire with dilators (if small tube being used)
- Chest tube
- Connecting tubing
- Closed drainage system (including sterile water if underwater seal being used)
- Dressing

Equipment may also be available in kit form.

6. CONSENT AND PREMEDICATION

- **Prior to commencing chest tube insertion the procedure should be explained fully to the patient and consent recorded in accordance with national guidelines. [C]**
- **Unless there are contraindications to its use, premedication (benzodiazepine or opioid) should be given to reduce patient distress. [B]**

Consent should be taken and recorded in keeping with national guidelines. The General Medical Council (GMC) guidelines for consent state that it is the responsibility of the doctor carrying out a procedure, or an appropriately trained individual with sufficient knowledge of a procedure, to explain its nature and the risks associated with it. It is within the rights of a competent individual patient to refuse such treatment. In the case of an emergency, when the patient is unconscious and the treatment is lifesaving, treatment may be carried out but must be explained as soon as the patient is sufficiently recovered to understand. If possible, an information leaflet should be given before the procedure.

Chest drain insertion has been reported to be a painful procedure with 50% of patients experiencing pain levels of 9–10 on a scale of 10 in one study,¹¹ and therefore premedication should be given. Despite the apparent common sense of this approach, there is little established evidence of the effect from these medications. Premedication could be an intravenous anxiolytic—for example, midazolam 1–5 mg titrated to achieve adequate sedation—given immediately before the procedure or an intramuscular opioid given 1 hour before, although neither drug has been shown to be clearly superior. Both these classes of drugs may cause respiratory depression and patients with underlying lung disease such as COPD should be observed as reversal agents—for example, naloxone or flumazenil—are occasionally necessary.

While the use of atropine as part of premedication for fibre-optic bronchoscopy has been assessed, no controlled trial of its use in chest tube insertion has been identified, although it is advocated in some centres. Case reports of vasovagal reactions¹² and a death due to vagal stimulation following tube insertion¹³ may support its use as premedication.

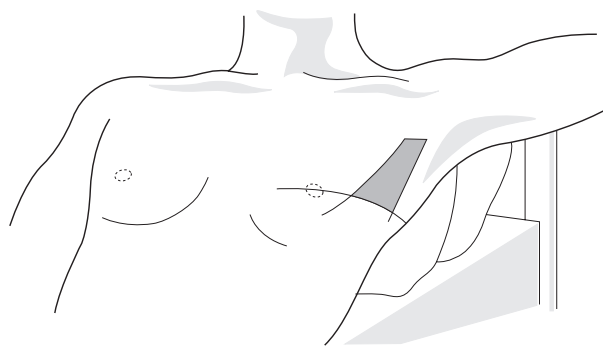


Figure 3 Diagram to illustrate the “safe triangle”.

7 PATIENT POSITION

The preferred position for drain insertion is on the bed, slightly rotated, with the arm on the side of the lesion behind the patient's head to expose the axillary area.⁷⁻⁹ An alternative is for the patient to sit upright leaning over an adjacent table with a pillow or in the lateral decubitus position.¹⁴ Insertion should be in the “safe triangle” illustrated in fig 3. This is the triangle bordered by the anterior border of the latissimus dorsi, the lateral border of the pectoralis major muscle, a line superior to the horizontal level of the nipple, and an apex below the axilla.

8 CONFIRMING SITE OF DRAIN INSERTION

- **A chest tube should not be inserted without further image guidance if free air or fluid cannot be aspirated with a needle at the time of anaesthesia. [C]**
- **Imaging should be used to select the appropriate site for chest tube placement. [B]**
- **A chest radiograph must be available at the time of drain insertion except in the case of tension pneumothorax. [C]**

Immediately before the procedure the identity of the patient should be checked and the site and side for insertion of the chest tube confirmed by reviewing the clinical signs and the chest radiograph. Fluoroscopy, ultrasonography, and CT scanning can all be used as adjunctive guides to the site of tube placement.¹⁵ Before insertion, air or fluid should be aspirated; if none is forthcoming, more complex imaging than a chest radiograph is required.

The use of ultrasonography guided insertion is particularly useful for empyema and effusions as the diaphragm can be localised and the presence of loculations and pleural thickening defined.¹⁶ Using real time scanning at the time of the procedure can help to ensure that the placement is safe despite the movement of the diaphragm during respiration. The complication rate following image guided thoracocentesis is low with pneumothoraces occurring in approximately 3% of cases.¹⁷ Success rates of image guided chest tube insertion are reported to be 71–86%.¹² If an imaging technique is used to indicate the site for drain insertion but the procedure is not carried out at the time of imaging, the position of the patient at the time must be clearly documented to aid accurate insertion when the patient returns to the ward. It is recommended that ultrasound is used if the effusion is very small or initial blind aspiration fails.

9 DRAIN INSERTION SITE

The most common position for chest tube insertion is in the mid axillary line,²⁻⁹ through the “safe triangle”¹⁸ illustrated in fig 3 and described above. This position minimises risk to underlying structures such as the internal mammary artery and avoids damage to muscle and breast tissue resulting in

unsightly scarring. A more posterior position may be chosen if suggested by the presence of a locule. While this is safe, it is not the preferred site as it is more uncomfortable for the patient to lie on after insertion and there is a risk of the drain kinking.

For apical pneumothoraces the second intercostal space in the mid clavicular line is sometimes chosen but is not recommended routinely as it may be uncomfortable for the patient and may leave an unsightly scar. Loculated apical pneumothoraces are not uncommonly seen following thoracotomy and may be drained using a posteriorly sited (suprascapular) apical tube.¹⁹⁻²⁰ This technique should be performed by an operator experienced in this technique—for example, a thoracic surgeon. If the drain is to be inserted into a loculated pleural collection, the position of insertion will be dictated by the site of the locule as determined by imaging.

10 DRAIN SIZE

- **Small bore drains are recommended as they are more comfortable than larger bore tubes [B] but there is no evidence that either is therapeutically superior.**
- **Large bore drains are recommended for drainage of acute haemothorax to monitor further blood loss. [C]**

The use of large bore drains has previously been recommended^{6-8,21} as it was felt that there was an increase in the frequency of drain blockage, particularly by thick malignant or infected fluid. The majority of physicians now use smaller catheters (10–14 French (F)) and studies have shown that these are often as effective as larger bore tubes²² and are more comfortable and better tolerated by the patient.²³ There remains intense debate about the optimum size of drainage catheter²⁴⁻²⁶ and no large randomised trials directly comparing small and large bore tubes have been performed.

In pneumothoraces 9 F catheters have been used with success rates of up to 87%, although in a few patients the air leak seems to exceed the capacity of this small catheter.²⁷ In the event of failure to drain a pneumothorax due to excessive air leakage, it is recommended that a larger bore tube be inserted. There is no evidence to suggest that surgical emphysema rates vary between the size of drains. Ultrasonographically guided insertion of pigtail catheters for treatment of malignant pleural effusions for sclerotherapy has been particularly well studied with good effect.²⁸⁻³² The use of small bore pigtail catheters has allowed outpatient treatment of malignant pleural effusions which have not responded to chemotherapy.³³ Empyemas are often successfully drained with ultrasonically placed small bore tubes with the aid of thrombolytic agents.³⁴⁻³⁵

In the case of acute haemothorax, however, large bore tubes (28–30 F minimum) continue to be recommended for their dual role of drainage of the thoracic cavity and assessment of continuing blood loss.³⁶

11 ASEPTIC TECHNIQUE

- **Aseptic technique should be employed during catheter insertion. [C]**
- **Prophylactic antibiotics should be given in trauma cases. [A]**

As a chest drain may potentially be in place for a number of days, aseptic technique is essential to avoid wound site infection or secondary empyema. Although this is uncommon, estimations of the empyema rate following drain insertions for trauma are approximately 2.4%.³⁷ While the full sterile technique afforded by a surgical theatre is usually unnecessary, sterile gloves, gown, equipment and the use of sterile towels after effective skin cleansing using iodine or chlorhexidine are recommended. A large area of skin cleansing should

be undertaken. In a study of chest tubes inserted in trauma suites using full aseptic technique, there were no infective complications in 80 cases.³⁸

Studies of the use of antibiotic prophylaxis for chest tube insertion have been performed but have failed to reach significance because of small numbers of infectious complications. However, a meta-analysis of these studies has been performed which suggested that, in the presence of chest trauma (penetrating or blunt), the use of prophylactic antibiotics reduces the absolute risk of empyema by 5.5–7.1% and of all infectious complications by 12.1–13.4%.³⁹ The use of prophylactic antibiotics in trauma cases is therefore recommended. The antibiotics used in these studies were cephalosporins or clindamycin.

The use of prophylactic antibiotics is less clear in the event of spontaneous pneumothorax or pleural effusion drainage as no studies were found which addressed these circumstances. In one study only one infectious complication (in the chest tube track) occurred in a series of 39 spontaneous pneumothoraces treated with chest tubes.⁴⁰

12 ANAESTHESIA

- **Local anaesthetic should be infiltrated prior to insertion of the drain. [C]**

Local anaesthetic is infiltrated into the site of insertion of the drain. A small gauge needle is used to raise a dermal bleb before deeper infiltration of the intercostal muscles and pleural surface. A spinal needle may be required in the presence of a thick chest wall.

Local anaesthetic such as lignocaine (up to 3 mg/kg) is usually infiltrated. Higher doses may result in toxic levels. The peak concentration of lignocaine was found to be <3 µg/ml (that is, a low risk of neurotoxic effects) in 85% of patients given 3 mg/kg intrapleurally.⁴¹ The volume given is considered to be more important than the dose to aid spread of the effective anaesthetic area. The use of adrenaline to aid haemostasis and localise the anaesthesia is used in some centres but is not evidence based.

13 INSERTION OF CHEST TUBE

- **Chest drain insertion should be performed without substantial force. [C]**

Insertion of a chest tube should never be performed with any substantial force since this risks sudden chest penetration and damage to essential intrathoracic structures. This can be avoided either by the use of a Seldinger technique or by blunt dissection through the chest wall and into the pleural space before catheter insertion. Which of these approaches is appropriate depends on the catheter size and is discussed below.

13.1 Small bore tube (8–14 F)

- **Insertion of a small bore drain under image guidance with a guidewire does not require blunt dissection.**

Small bore chest tubes are usually inserted with the aid of a guidewire by a Seldinger technique. Blunt dissection is unnecessary as dilators are used in the insertion process. After infiltration with local anaesthesia, a needle and syringe are used to localise the position for insertion by the identification of air or pleural fluid. A guidewire is then passed down the hub of the needle, the needle is removed, and the tract enlarged using a dilator. A small bore tube can then be passed into the thoracic cavity along the wire. These have been successfully used for pneumothorax, effusions, or loculated empyemas.^{15 23 42}

13.2 Medium bore tube (16–24 F)

Medium sized chest drains may be inserted by a Seldinger technique or by blunt dissection as outlined below. As the

incision size should afford a snug fit around the chest tube, it is not possible to insert a finger to explore the pleura when inserting this size of tube. Exploration with a finger is felt to be unnecessary for the elective medical insertion of these medium sized chest tubes.

13.3 Large bore tube (>24 F)

- **Blunt dissection into the pleural space must be performed before insertion of a large bore chest drain. [C]**

13.3.1 Incision

- **The incision for insertion of the chest drain should be similar to the diameter of the tube being inserted. [C]**

Once the anaesthetic has taken effect an incision is made. This should be slightly bigger than the operator's finger and tube. The incision should be made just above and parallel to a rib.

13.3.2 Blunt dissection

Many cases of damage to essential intrathoracic structures have been described following the use of trocars to insert large bore chest tubes. Blunt dissection of the subcutaneous tissue and muscle into the pleural cavity has therefore become universal⁴³ and is essential. In one retrospective study only four technical complications were seen in 447 cases using blunt dissection.³⁷ Using a Spencer-Wells clamp or similar, a path is made through the chest wall by opening the clamp to separate the muscle fibres. For a large chest drain, similar in size to the finger, this track should be explored with a finger through into the thoracic cavity to ensure there are no underlying organs that might be damaged at tube insertion.²⁻⁹ The creation of a patent track into the pleural cavity ensures that excessive force is not needed during drain insertion.

13.3.3 Position of tube tip

- **The position of the tip of the chest tube should ideally be aimed apically for a pneumothorax or basally for fluid. However, any tube position can be effective at draining air or fluid and an effectively functioning drain should not be repositioned solely because of its radiographic position. [C]**

In the case of a large bore tube, after gentle insertion through the chest wall the trocar positioned a few centimetres from the tube tip can afford support of the tube and so help its positioning without incurring organ damage. A smaller clamp can also be used to direct the tube to its desired position.^{1 3}

If possible, the tip of the tube should be aimed apically to drain air and basally for fluid. However, successful drainage can still be achieved when the drain is not placed in an ideal position,²¹ so effectively functioning tubes should not be repositioned simply because of a suboptimal radiographic appearance.

13.3.4 Securing the drain

- **Large and medium bore chest drain incisions should be closed by a suture appropriate for a linear incision. [C]**
- **"Purse string" sutures must not be used. [C]**

Two sutures are usually inserted—the first to assist later closure of the wound after drain removal and the second, a stay suture, to secure the drain.

The wound closure suture should be inserted before blunt dissection. A strong suture such as "1" silk is appropriate.^{6 21} A "mattress" suture or sutures across the incision are usually employed and, whatever closure is used, the stitch must be of a type that is appropriate for a linear incision (fig 4). Complicated "purse string" sutures must not be used as they convert

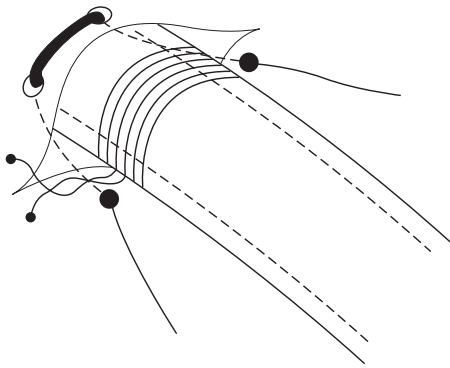


Figure 4 Example of stay and closing sutures.

a linear wound into a circular one that is painful for the patient and may leave an unsightly scar.⁹ A suture is not usually required for small gauge chest tubes.

The drain should be secured after insertion to prevent it falling out. Various techniques have been described,⁴⁴ but a simple technique of anchoring the tube has not been the subject of a controlled trial. The chosen suture should be stout and non absorbable to prevent breaking (e.g. "1" silk),⁶ and it should include adequate skin and subcutaneous tissue to ensure it is secure (fig 4).

Large amounts of tape and padding to dress the site are unnecessary and concerns have been expressed that they may restrict chest wall movement⁶ or increase moisture collection. A transparent dressing allows the wound site to be inspected by nursing staff for leakage or infection. An omental tag of tape has been described² which allows the tube to lie a little away from the chest wall to prevent tube kinking and tension at the insertion site (fig 5).

14 MANAGEMENT OF DRAINAGE SYSTEM

14.1 Clamping drain

- **A bubbling chest tube should never be clamped.** [C]
- **Drainage of a large pleural effusion should be controlled to prevent the potential complication of re-expansion pulmonary oedema.** [C]
- **In cases of pneumothorax, clamping of the chest tube should usually be avoided.** [B]
- **If a chest tube for pneumothorax is clamped, this should be under the supervision of a respiratory physician or thoracic surgeon, the patient should be managed in a specialist ward with experienced nursing staff, and the patient should not leave the ward environment.** [C]

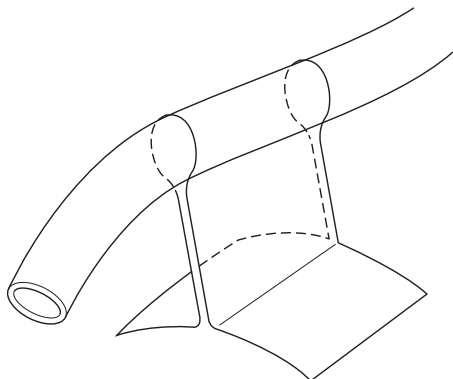


Figure 5 Omental tag to support the tube while allowing it to lie a little away from the chest wall.

- **If a patient with a clamped drain becomes breathless or develops subcutaneous emphysema, the drain must be immediately unclamped and medical advice sought.** [C]

There is no evidence to suggest that clamping a chest drain prior to its removal increases success or prevents recurrence of a pneumothorax and it may be hazardous. This is therefore generally discouraged. Clamping a chest drain in the presence of a continuing air leak may lead to the potentially fatal complication of tension pneumothorax.^{3, 6, 9} A bubbling drain therefore should never be clamped. However, many experienced specialist physicians support the use of the clamping of non-bubbling chest drains inserted for pneumothorax to detect small air leaks not immediately obvious at the bedside. By clamping the chest drain for several hours, followed by a chest radiograph, a minor air leak may be detected, avoiding the need for later chest drain reinsertion. In the ACCP Delphi consensus statement⁴⁵ about half the consensus group supported clamping and half did not, and this seems similar to the UK spread of opinion. Drain clamping is therefore not generally recommended for safety reasons, but is acceptable under the supervision of nursing staff who are trained in the management of chest drains and who have instructions to unclamp the chest drain in the event of any clinical deterioration. Patients with a clamped chest drain inserted for pneumothorax should not leave the specialist ward area.

There have been reports of re-expansion pulmonary oedema following rapid evacuation of large pleural effusions⁴⁶ as well as in association with spontaneous pneumothorax.^{47, 48} This has been reported to be fatal in some cases (up to 20% of subjects in one series of 53 cases⁴⁹). In the case of spontaneous pneumothorax this is a rare complication with no cases of re-expansion pulmonary oedema reported in two large studies of 400 and 375 patients, respectively.^{50, 51} It is usually associated with delayed diagnosis and therefore awareness of its potential occurrence is sufficient.

Milder symptoms suggestive of re-expansion oedema are common after large volume thoracentesis in pleural effusion, with patients experiencing discomfort and cough. It has been suggested that the tube be clamped for 1 hour after draining 1 litre.⁵² While there is no evidence for actual amounts, good practice suggests that no more than about 1.5 litres should be drained at one time, or drainage should be slowed to about 500 ml per hour.

14.2 Closed system drainage

- **All chest tubes should be connected to a single flow drainage system e.g. under water seal bottle or flutter valve.** [C]
- **Use of a flutter valve system allows earlier mobilisation and the potential for earlier discharge of patients with chest drains.**

The chest tube is then attached to a drainage system which only allows one direction of flow. This is usually the closed underwater seal bottle in which a tube is placed under water at a depth of approximately 3 cm with a side vent which allows escape of air, or it may be connected to a suction pump.^{2-4, 7} This enables the operator to see air bubble out as the lung re-expands in the case of pneumothorax or fluid evacuation rate in empyemas, pleural effusions, or haemothorax. The continuation of bubbling suggests a continued visceral pleural air leak, although it may also occur in patients on suction when the drain is partly out of the thorax and one of the tube holes is open to the air. The respiratory swing in the fluid in the chest tube is useful for assessing tube patency and confirms the position of the tube in the pleural cavity. The disadvantages of the underwater seal system include obligatory inpatient management, difficulty of patient mobilisation, and the risk of knocking over the bottle.

The use of integral Heimlich flutter valves has been advocated in patients with pneumothoraces, especially as they permit ambulatory or even outpatient management which has been associated with a 85–95% success rate.^{53–54} In 176 cases of pneumothorax treated with small chest tubes and a Heimlich flutter valve there were only eight failures (hospital admissions for problems with tube function or placement). The mean length of inpatient stay has been quoted at 5 hours with a thoracic vent and 144 hours with an underwater seal, with a cost saving US\$5660.⁵³ Case reports of incorrect use (wrong direction of flow) of such valves have been described, however, with tension pneumothorax as a result.⁵⁵ Flutter valves cannot be used with fluid drainage as they tend to become blocked. However, in the UK a similar short hospital stay is achieved by initial aspiration of pneumothoraces (see guidelines on pneumothorax, page ii39).

The use of a drainage bag with an incorporated flutter valve and vented outlet has been successfully used postoperatively.^{56–57} A randomised trial of 119 cases following elective thoracotomy compared the use of an underwater seal with the flutter bag and found no difference in drainage volumes, requirement for suction, or complications with the added advantage of earlier mobilisation with drainage bags.⁵⁷ In cases of malignant pleural effusion drainage a closed system using a drainage bag or aspiration via a three way tap has been described to aid palliation and outpatient management.³³ One report of a modified urinary collecting bag for prolonged underwater chest drainage has been described for use with empyemas, bronchopulmonary fistula, and pneumothorax associated with emphysema with no complications in the 12 patients studied.⁵⁸

14.3 Suction

- **When chest drain suction is required, a high volume/low pressure system should be used. [C]**
- **When suction is required, the patient must be nursed by appropriately trained staff. [C]**

The use of high volume/low pressure suction pumps has been advocated in cases of non-resolving pneumothorax or following chemical pleurodesis,⁶ but there is no evidence to support its routine use in the initial treatment of spontaneous pneumothorax.^{59–60} If suction is required, this may be performed via the underwater seal at a level of 10–20 cm H₂O. A high volume pump (e.g. Vernon-Thompson) is required to cope with a large leak. A low volume pump (e.g. Roberts pump) is inappropriate as it is unable to cope with the rapid flow, thereby effecting a situation similar to clamping and risking formation of a tension pneumothorax. A wall suction adaptor may also be effective, although chest drains must not be connected directly to the high negative pressure available from wall suction.

In the management of pleural infection, the use of suction is less clear. Most studies are observational and have used suction applied via the chest tube after flushing to prevent blocking and have reported success, but this has not been compared with cases without suction. This is discussed further in the guideline on pleural infection (page ii18).

There is no evidence that briefly disconnecting a drain from suction used for spontaneous pneumothorax or pleural effusion is disadvantageous. Therefore, as long as adequate instruction is given to patient, portering and nursing staff with regard to keeping the underwater seal bottle below the level of the chest, it is acceptable to stop suction for short periods such as for radiography.

14.4 Ward instructions

- **Patients with chest tubes should be managed on specialist wards by staff who are trained in chest drain management. [C]**

Audit points

- The presence and use of an appropriate nursing chest drain observation chart should be noted.
- The frequency of chest drain complications should be recorded.
- The use of premedication and analgesics and patient pain scores relating to chest drain insertion should be recorded.
- The duration of chest tube drainage should be recorded.

- **A chest radiograph should be performed after insertion of a chest drain. [C]**

Patients should be managed on a ward familiar with chest tubes. Instruction to and appropriate training of the nursing staff is imperative. If an underwater seal is used, instructions must be given to keep the bottle below the insertion site at all times, to keep it upright, and to ensure that adequate water is in the system to cover the end of the tube.⁹ Daily reassessment of the amount of drainage/bubbling and the presence of respiratory swing should be documented, preferably on a dedicated chest drain chart. Instruction with regard to chest drain clamping must be given and recorded.⁶¹

Patients should be encouraged to take responsibility for their chest tube and drainage system. They should be taught to keep the underwater seal bottle below the level of their chest and to report any problems such as pulling on the drain insertion site. Educational material (e.g. leaflets) should be available on the ward for patients and nursing staff.

A chest radiograph should be performed to assess tube position, exclude complications such as pneumothorax or surgical emphysema, and assess the success of the procedure in the volume of fluid drainage or pneumothorax resolution. Concern has previously been expressed in cases where the tube enters the lung fissure. In a study of 66 patients with chest tubes inserted for acute chest trauma, 58% of which were located within a pulmonary fissure,⁶² no difference in outcome was seen between these cases and those in whom the tube was located outside the fissures.

14.5 Removal of the chest tube

- **In cases of pneumothorax, the chest tube should not be clamped at the time of its removal. [B]**

In cases of pneumothorax, there is no evidence that clamping a chest drain at the time of its removal is beneficial.⁶⁰

The chest tube should be removed either while the patient performs Valsalva's manoeuvre or during expiration with a brisk firm movement while an assistant ties the previously placed closure suture.^{2–4 7 8} The timing of removal is dependent on the original reason for insertion and clinical progress (see guidelines for management of pneumothorax (page ii39), malignant pleural effusions (page ii29), and pleural infections (page ii18)).

In the case of pneumothorax, the drain should not usually be removed until bubbling has ceased and chest radiography demonstrates lung reinflation.⁴ Clamping of the drain before removal is generally unnecessary. In one study the removal of chest tubes after continuous suction was compared with the removal after a period of disconnection from suction to an underwater seal. No significant difference was seen between these two methods with only two of 80 cases (2.5%) requiring reinsertion of a chest tube.³⁸

15 PATIENTS REQUIRING ASSISTED VENTILATION

During the insertion of a chest tube in a patient on a high pressure ventilator (especially with positive end expiratory pressure (PEEP)), it is essential to disconnect from the ventilator at the time of insertion to avoid the potentially serious

complication of lung penetration,⁶³ although as long as blunt dissection is carried out and no sharp instruments are used, this risk is reduced.⁶⁴

ACKNOWLEDGEMENTS

The authors are grateful to Dr Richard Holmes for figs 3, 4, and 5.

Authors' affiliations

D Laws, Department of Thoracic Medicine, Royal Bournemouth Hospital, Bournemouth BH7 7DW, UK

E Neville, Respiratory Centre, St Mary's Hospital, Portsmouth PO3 6AD, UK

J Duffy, Cardiothoracic Surgery Department, City Hospital, Nottingham NG5 1PB, UK

REFERENCES

- American College of Surgeons Committee on Trauma**. In: *Thoracic trauma. Advanced Trauma Life Support program for physicians: instructor manual*. Chicago: American College of Surgeons, 1993. [IV]
- Miller KS**, Sahn SA. Review. Chest tubes. Indications, technique, management and complications. *Chest* 1987;**91**:258–64. [IV]
- Parmar JM**. How to insert a chest drain. *Br J Hosp Med* 1989;**42**:231–3. [IV]
- Treasure T**, Murphy JP. Pneumothorax. *Surgery* 1989;**75**:1780–6. [IV]
- Westaby S**, Brayley N. Thoracic trauma – I. *BMJ* 1990;**330**:1639–44. [IV]
- Harriss DR**, Graham TR. Management of intercostal drains. *Br J Hosp Med* 1991;**45**:383–6. [IV]
- Iberty TJ**, Stern PM. Chest tube thoracostomy. *Crit Care Clin* 1992;**8**:879–95. [IV]
- Quigley RL**. Thoracocentesis and chest tube drainage. *Crit Care Clin* 1995;**11**:111–26. [IV]
- Tomlinson MA**. Treasure T. Insertion of a chest drain : how to do it. *Br J Hosp Med* 1997;**58**:248–52. [IV]
- Collop NA**, Kim S, Sahn SA. Analysis of tube thoracostomy performed by pulmonologists at a teaching hospital. *Chest* 1997;**112**:709–13. [III]
- Luketich JD**, Kiss MD, Hershey J, et al. Chest tube insertion: a prospective evaluation of pain management. *Clin J Pain* 1998;**14**:152–4. [IIa]
- Reinhold C**, Illescas FF, Atri M, et al. The treatment of pleural effusions and pneumothorax with catheters placed percutaneously under image guidance. *AJR* 1989;**152**:1189–91. [III]
- Ward EW**, Hughes TE. Sudden death following chest tube insertion: an unusual case of vagus nerve irritation. *J Trauma* 1994;**36**:258–9. [IV]
- Boland GW**, Lee MJ, Silverman S, et al. Review. Interventional radiology of the pleural space. *Clin Radiol* 1995;**50**:205–14. [IV]
- Klein JS**, Schulz S, Heffner JE. Interventional radiology of the chest: image-guided percutaneous drainage of pleural effusions, lung abscess, and pneumothorax. *AJR* 1995;**164**:581–8. [IV]
- Rosenberg ER**. Ultrasound in the assessment of pleural densities. *Chest* 1983;**84**:283–5. [IV]
- Harnsberger HR**, Lee TG, Mukuno DH. Rapid, inexpensive real time directed thoracocentesis. *Radiology* 1983;**146**:545–6. [IV]
- Holden MP**. Management of intercostal drainage tubes. In: *Practice of cardiothoracic surgery*. Bristol: John Wright, 1982: 3. [IV]
- Aslam PA**, Hughes FA. Insertion of an apical tube. *Surg Gynecol Obstet* 1970;**130**:1097. [IV]
- Galvin IF**, Gibbons JRP, Magout M, et al. Placement of an apical chest tube by a posterior approach. *Br J Hosp Med* 1990;**44**:330–1. [IV]
- Hyde J**, Sykes T, Graham T. Reducing morbidity from chest drains. *BMJ* 1997;**311**:914–5. [IV]
- Clements P**, Ewald T, Grode G, et al. Treatment of malignant pleural effusion : pleurodesis using a small bore catheter. A prospective randomized study. *Respir Med* 1998;**92**:593–6. [Ib]
- Patz EF**, Goodman PC, Erasmus JJ. Percutaneous drainage of pleural collections. *J Thorac Imaging* 1998;**13**:83–92. [IV]
- Henderson AF**, Banham SW, Moran F. Re-expansion pulmonary oedema: a potentially serious complication of delayed diagnosis of pneumothorax. *BMJ* 1985;**29**:593–4. [IV]
- Thomas RJ**, Sagar SM. What size pleural tube for pleural effusions (letter)? *Br J Hosp Med* 1990;**43**:184. [IV]
- Taylor PM**. Catheters smaller than 24 French gauge can be used for chest drains (letter). *BMJ* 1997;**315**:186. [IV]
- Conces DJ**, Tarver RD, Gray WC, et al. Treatment of pneumothoraces utilizing small caliber chest tubes. *Chest* 1988;**94**:55–7. [III]
- Parker LA**, Charnock GC, Delany DJ. Small bore catheter drainage and sclerotherapy for malignant pleural effusions. *Cancer* 1989;**64**:1218–21. [III]
- Morrison MC**, Mueller PR, Lee MJ, et al. Sclerotherapy of malignant pleural effusion through sonographically placed small-bore catheters. *AJR* 1992;**158**:41–3. [III]
- Goff BA**, Mueller PR, Muntz HG, et al. Small chest tube drainage followed by bleomycin sclerosis for malignant pleural effusions. *Obstet Gynecol* 1993;**81**:993–6. [III]
- Seaton KG**, Patz EF, Goodman PC. Palliative treatment of malignant pleural effusions: value of small-bore catheter thoracostomy and doxycycline sclerotherapy. *AJR* 1995;**164**:589–91. [Ib]
- Thompson RL**, Yau JC, Donnelly RF, et al. Pleurodesis with iodized talc for malignant effusions using pigtail catheters. *Ann Pharmacother* 1998;**32**:739–42. [Ib]
- Van Le L**, Parker LA, DeMars LR, et al. Pleural effusions: outpatient management of pigtail catheter chest tubes. *Gynecol Oncol* 1994;**54**:215–7. [IV]
- Matsumoto AH**. Image-guided drainage of complicated pleural effusions and adjunctive use of intrapleural urokinase. *Chest* 1995;**108**:1190–1. [IV]
- Moulton JS**, Benkert RE, Weisiger KH, et al. Treatment of complicated pleural fluid collections with image guided drainage and intra cavity urokinase. *Chest* 1995;**108**:1252–9. [III]
- Parry GW**, Morgan WE, Salama FD. Management of haemothorax. *Ann R Coll Surg Engl* 1996;**78**:325–6. [IV]
- Millikan JS**, Moore EE, Steiner E, et al. Complications of tube thoracostomy for acute trauma. *Am J Surg* 1980;**140**:738–41. [III]
- Davis JW**, MacKersie RC, Hoyt DB, et al. Randomised study of algorithms for discontinuing tube thoracostomy drainage. *J Am Coll Surg* 1994;**179**:553–7. [Ib]
- Fallon WF**, Wears RL. Prophylactic antibiotics for the prevention of infectious complications including empyema following tube thoracostomy for trauma: results of a meta-analysis. *J Trauma* 1992;**33**:110–7. [Ia]
- LeBlanc KA**, Tucker WY. Prophylactic antibiotics and closed tube thoracostomy. *Surg Gynecol Obstet* 1985;**160**:259–63. [Ib]
- Wooten SA**, Barbarash RA, Strange C, et al. Systemic absorption of tetracycline following intrapleural instillation. *Chest* 1988;**94**:960–3. [IIa]
- Mellor DJ**. A new method of chest drain insertion. *Anaesthesia* 1996;**51**:713–4. [IV]
- Haggie JA**. Management of pneumothorax: chest drain trocar is unsafe and unnecessary. *BMJ* 1993;**307**:443. [IV]
- Rashid MA**, Wikstrom T, Ortenwall P. A simple technique for anchoring chest tubes. *Eur Respir J* 1998;**12**:958–9. [IV]
- Baumann MH**, Strange C, Heffner JE, et al. Management of spontaneous pneumothorax. An American College of Chest Physicians Delphi Consensus Statement. *Chest* 2001;**119**:590–602.
- Trapnell DH**, Thurston JGB. Unilateral pulmonary oedema after pleural aspiration. *Lancet* 1970;**i**:1367–9. [IV]
- Rozenman J**, Yellin A, Simansky DA, et al. Re-expansion pulmonary oedema following pneumothorax. *Respir Med* 1996;**90**:235–8. [IV]
- Henderson AK**. Further advice on inserting a chest drain (letter and reply). *Br J Hosp Med* 1990;**43**:82. [IV]
- Mafhood S**, Hix WR, Aaron BI, et al. Re-expansion pulmonary oedema. *Ann Thorac Surg* 1988;**45**:340–5. [IV]
- Mills M**, Balsch B. Spontaneous pneumothorax : a series of 400 cases. *Ann Thorac Surg* 1965;**1**:286. [IV]
- Brooks J**. Open thoracotomy in the management of spontaneous pneumothorax. *Ann Surg* 1973;**177**:798. [IV]
- Hall M**, Jones A. Clamping may be appropriate to prevent discomfort and reduce risk of oedema (letter). *BMJ* 1997;**315**:313. [IV]
- Roegela M**, Roeggl G, Muellner M, et al. The cost of treatment of spontaneous pneumothorax with the thoracic vent compared with conventional thoracic drainage (letter). *Chest* 1996;**110**:303. [Ib]
- Ponn RB**, Silverman HJ, Federico JA. Outpatient chest tube management. *Ann Thorac Surg* 1997;**64**:1437–40. [III]
- Mainini SE**, Johnson FE. Tension pneumothorax complicating small-caliber chest tube insertion. *Chest* 1990;**97**:759–60. [IV]
- Matthews HR**, Mcguigan JA. Closed chest drainage without an underwater seal. *Thorax* 1988;**41**:804P. [IV]
- Graham ANJ**, Cosgrove AP, Gibbons JRP, et al. Randomised clinical trial of chest drainage systems. *Thorax* 1992;**47**:461–2. [Ib]
- Bar-El Y**, Leiberman Y, Yellin A. Modified urinary collecting bag for prolonged underwater chest drainage. *Ann Thorac Surg* 1992;**54**:995–6. [Ib]
- Sharma TN**, Agrihotri SP, Jain NK, et al. Intercostal tube thoracostomy in pneumothorax : factors influencing re-expansion of lung. *Ind J Chest Dis Allied Sci* 1988;**30**:32–5. [III]
- So SY**, Yu DY. Catheter drainage of spontaneous pneumothorax: suction or no suction, early or late removal? *Thorax* 1982;**37**:46–8. [Ib]
- Williams T**. To clamp or not to clamp. *Nursing Times* 1992;**88**:33. [IV]
- Curtin JJ**, Goodman LR, Quebbeman EJ, et al. Thoracostomy tubes after acute chest injury: relationship between location in a pleural fissure and function. *AJR* 1994;**163**:1339–42. [IIa]
- Peek GJ**, Firmin RK, Arsiwala S. Chest tube insertion in the ventilated patient. *Injury* 1995;**26**:425–6. [IV]
- Main A**. As few sharp objects as possible should be used on entering pleural space (letter). *BMJ* 1998;**316**:68. [IV]