

VIDEOS IN CLINICAL MEDICINE

Cricothyroidotomy

James Hsiao, M.D., and Victor Pacheco-Fowler, M.D.

INDICATIONS

Cricothyroidotomy is an emergency procedure performed on patients with severe respiratory distress in whom attempts at orotracheal or nasotracheal intubation either have failed or were deemed to have an unacceptable level of risk. The procedure involves making an incision in the cricothyroid membrane, which lies between the thyroid and cricoid cartilages, and inserting a tracheostomy tube into the trachea to allow ventilation.

The major indication for cricothyroidotomy is the inability to establish an airway through orotracheal or nasotracheal intubation, which may be due to difficult patient anatomy, excessive blood in the mouth or nose, massive facial trauma, or airway obstruction resulting from angioedema, trauma, burns, or a foreign body obstructing the airway.

The rate of failed emergency department intubations and subsequent surgical airway management is lower than 0.6%.¹ In the emergency department, cricothyroidotomy has been used for 1.0 to 2.8% of all intubation attempts in patients with trauma.²⁻⁴ Whenever possible, cricothyroidotomy should be performed by physicians fully trained and skilled in carrying out the procedure, such as emergency physicians, surgeons, and intensivists.

A tracheostomy tube placed during a cricothyroidotomy performed under emergency conditions can be left in place for up to 72 hours. Because of the potential complications of cricothyroidotomy, including subglottic stenosis and damage to the thyroid and cricoid cartilages, a cricothyroidotomy should be converted to a tracheostomy if airway access is needed for more than 72 hours.⁵ Although tracheostomy is preferred for long-term management, it should be performed in the controlled setting of the operating room. In urgent situations, cricothyroidotomy should be performed.

Surgical cricothyroidotomy involves inserting a tracheostomy tube into the trachea through an incision in the cricothyroid membrane. In needle cricothyroidotomy, a catheter is placed over a needle that penetrates the membrane, allowing ventilation by a pressurized stream of oxygen. Because the catheter has a smaller diameter, it is less effective in providing adequate ventilation and should be used only as a temporizing measure while preparation is made for surgical cricothyroidotomy or tracheostomy. Needle cricothyroidotomy is the preferred method of establishing an emergency airway in children younger than 10 to 12 years, since the larynx is more easily damaged by surgical cricothyroidotomy in this age group, with a higher incidence of postoperative airway complications.⁶

CONTRAINDICATIONS

Cricothyroidotomy should not be performed when there is massive trauma to the larynx or cricoid cartilage. When orotracheal and nasotracheal intubation are viable options, they should be attempted before cricothyroidotomy is considered.

From the Department of Emergency Medicine, New York–Presbyterian Hospital, New York. Address reprint requests to Dr. Hsiao at 445 East 68th St., #7H, New York, NY 10065, or at james_j_hsiao@yahoo.com.

N Engl J Med 2008;358:e25.

Copyright © 2008 Massachusetts Medical Society.

PREPARATION

Since cricothyroidotomy is an emergency procedure, there may not be time to obtain informed consent, and the patient may not be able to provide consent. The procedure should be performed in emergency situations even in the absence of informed consent.

For sterilization and local anesthesia, the following are needed: gloves, a protective gown, a face shield, chlorhexidine or povidone iodine (Betadine, Purdue Pharma), gauze pads, 1% or 2% lidocaine with epinephrine, and a 6-ml syringe with a 25-gauge needle. To perform the procedure, the following are needed: a tracheostomy tube, a scalpel with a number 10 or 11 blade, a curved hemostat, a Trousseau dilator, a tracheal hook, a 10-ml syringe, and suture or tying material. A bag-valve device and an oxygen source should be available to ventilate the patient once the procedure has been performed.

A tracheostomy tube with an internal diameter of 6 mm should be used. A tube with an internal diameter larger than 7 mm would be difficult to insert into the cricothyroid membrane.

The tracheostomy tube comprises three parts (Fig. 1). The outer cannula has a neck plate extending from the sides that allows the tube to be secured to the neck with sutures or a cloth tie. The inner cannula has an adaptor at the end that attaches to a bag-valve device or mechanical ventilator. The obturator provides a smooth surface to guide insertion of the tube (Fig. 1).

A 6-mm endotracheal tube can be used as an alternative to the tracheostomy tube, but this option is much less preferable because an endotracheal tube is more difficult to secure to the patient's neck. Endotracheal tube holders or other devices may be used to help secure an endotracheal tube to the neck. Another advantage of the tracheostomy tube is that it is shorter than an endotracheal tube and therefore easier to suction.⁷

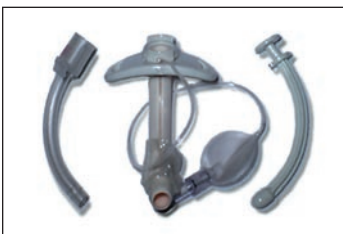

Figure 1. Components of the Tracheostomy Tube.

Shown from left to right are the inner cannula, outer cannula, and obturator.

PROCEDURE

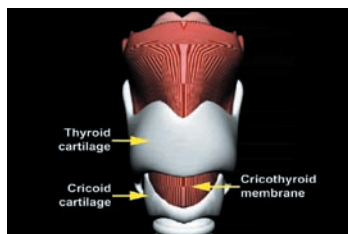


Figure 2. Landmarks for Cricothyroidotomy.

The incision is made in the cricothyroid membrane.

Place the patient in the supine position. Since this procedure is performed in extremely urgent circumstances, there is usually not time to drape the patient. Chlorhexidine or povidone iodine should be applied if time permits. If the patient is awake, administer local anesthesia.

Directions are given for a right-handed operator. Side-specific designations should be reversed for left-handed operators.

To perform cricothyroidotomy, stand on the patient's right side. Stabilize the larynx with your left thumb and middle finger, and use your index finger to palpate the thyroid cartilage. Move your index finger down until you palpate the cricoid cartilage. The space between the thyroid and cricoid cartilages is the cricothyroid membrane. This is where you will make the incision (Fig. 2).

Use the scalpel to make a 2.5-cm vertical incision through the skin and subcutaneous tissue. Use the curved hemostat to make a blunt dissection in the subcutaneous tissue. The initial incision should be vertical for two reasons: first, a vertical incision will avoid injury to the recurrent laryngeal nerves, which run parallel to the trachea, and second, an initial incision above or below the cricothyroid membrane, if vertical, will allow extension of the incision as needed. Starting with a horizontal incision that is too low or too high would necessitate a new incision in the correct location.

Next, use the scalpel to make a horizontal incision through the cricothyroid membrane. You may feel a pop as you enter the trachea. Extend the incision laterally, turn the blade, and extend it in the opposite direction.

To avoid penetrating too deeply and perforating the esophagus, which lies posterior to the trachea, do not go more than 1.3 cm (1/2 inch) deep (Fig. 3). To minimize the risk of esophageal perforation, hold the scalpel between your thumb and index finger, and allow your middle finger to extend down the side of the scalpel, leaving the distal 1.3 cm of the blade exposed. If the patient is trying to breathe, once you enter the trachea, airflow should be audible and may also be visible.

Once the trachea has been entered, make sure the blade stays within the incision, so that communication with the trachea is never lost. Insert a tracheal hook, and pull upward on the distal portion of the incision, elevating the larynx. Once the tracheal hook is in place, you may remove the blade.

Insert a Trousseau dilator and open the membrane vertically, then insert the tracheostomy tube. Holding the cannula in place, remove the obturator and attach the adaptor. Inflate the cuff with a 10-ml syringe. Attach a bag-valve unit and ventilate the patient. Look for symmetric chest rise and auscultate for symmetric breath sounds. Tie or suture the tracheostomy tube in place. Dispose of needles and sharps in an appropriate container.

If an endotracheal tube is used in place of a tracheostomy tube, make sure the tube is not inserted to a depth of more than 2 to 3 cm. Deeper placement of the tube may cause it to go down the right mainstem bronchus.

COMPLICATIONS

There are three major complications of cricothyroidotomy. First, esophageal perforation occurs when the blade penetrates too deeply. To prevent this, allow only the distal 1.3 cm of the blade to enter the trachea. Second, subcutaneous emphysema may occur if the horizontal incision is too wide, allowing air to become trapped in the subcutaneous tissue. Third, excessive bleeding or hemorrhage may occur if a vessel is ruptured. If minor vessels are injured, the bleeding can be controlled with direct pressure. If there is rupture of major vessels, such as the carotid artery or internal jugular vein, ligation may be required.

POSTPROCEDURAL CARE

After the procedure, obtain a chest x-ray film to confirm placement of the tracheostomy tube. Call for respiratory therapy so the patient can be mechanically ventilated. Obtain a surgical consult so that definitive tracheostomy can be performed, if necessary. A tracheostomy tube placed during an emergency cricothyroidotomy can be left in place for up to 72 hours.

No potential conflict of interest relevant to this article was reported.

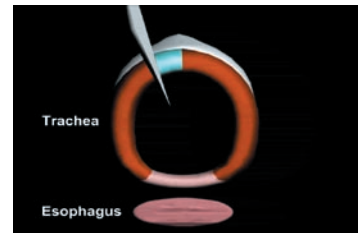


Figure 3. Cross-Sectional View of Trachea and Esophagus.

REFERENCES

1. Bair AE, Filbin MR, Kulkarni RG, Walls RM. The failed intubation attempt in the emergency department: analysis of prevalence, rescue techniques, and personnel. *J Emerg Med* 2002;23:131-40. [Erratum, *J Emerg Med* 2002;23:325.]
2. Bushra JS, McNeil B, Wald DA, Schwell A, Karras DJ. A comparison of trauma intubations managed by anesthesiologists and emergency physicians. *Acad Emerg Med* 2004;11:66-70.
3. Erlandson MJ, Clinton JE, Ruiz E, Cohen J. Cricothyrotomy in the emergency department revisited. *J Emerg Med* 1989;7:115-8.
4. Bair AE, Panacek EA, Wisner DH, Bales R, Sakles JC. Cricothyrotomy: a 5-year experience at one institution. *J Emerg Med* 2003;24:151-6.
5. Esses BA, Jafek BW. Cricothyroidotomy: a decade of experience in Denver. *Ann Otol Rhinol Laryngol* 1987;96:519-24.
6. Sise MJ, Shackford SR, Cruickshank JC, Murphy G, Fridlund PH. Cricothyroidotomy for long-term tracheal access: a prospective analysis of morbidity and mortality in 76 patients. *Ann Surg* 1984;200:13-7.
7. Gens DR. Surgical airway management. In: Tintinalli JE, Kelen GD, Stapczynski JS, eds. *Emergency medicine: a comprehensive study guide*. 6th ed. New York: McGraw-Hill, 2004:119-24.

Copyright © 2008 Massachusetts Medical Society.