

Extracorporeal carbon dioxide removal as an alternative to endotracheal intubation for non-invasive ventilation failure in acute exacerbation of COPD **2CO₄, 3COO**

S Cole, N Barrett, G Glover, C Langrish, C Meadows, K Daly, N Agnew, N Gooby, N Ioannou

Extracorporeal carbon dioxide removal (ECCO₂R) is an efficient technique used in the management of hypercapnic respiratory failure. Its application in mechanically ventilated patients has been studied for over 30 years. We describe a case of severe, acute exacerbation of chronic obstructive pulmonary disease (AECOPD) unresponsive to non-invasive ventilation (NIV), where initiation of ECCO₂R was used effectively to prevent endotracheal intubation.

Keywords: *pulmonary disease, chronic obstructive; noninvasive ventilation; extracorporeal membrane oxygenation; extracorporeal circulation*

Introduction

Blood oxygenation and clearance of carbon dioxide may be achieved using extracorporeal life support. This technology was originally described in 1972, by Hill *et al*, where 'shock-lung' was treated using a membrane oxygenator,¹ and its use has been associated with a survival benefit when compared with conventional ventilation for patients with severe respiratory failure.²

Adjustment of extracorporeal systems primarily to assist in carbon dioxide clearance was described by Gattinoni and Kolobow in the late 1970s.^{3,4} Adequate carbon dioxide clearance can be achieved with lower blood flows through extracorporeal circuits; thus, smaller, less invasive cannulae can be used.⁵ Early devices used an arterio-venous configuration but more recently, devices using a veno-venous approach have been developed. Although there is limited evidence on which to base practice, such an approach is intuitively appealing as it avoids the problems associated with arterial cannulation and can be performed using a single, dual-lumen cannula in either the femoral or internal jugular vein.

In severe acute exacerbation of chronic obstructive pulmonary disease (AECOPD), non-invasive ventilation (NIV) has been shown to reduce rates of endotracheal intubation, mortality and hospital length of stay; however, it carries a 14% risk of failure.⁶ Invasive mechanical ventilation, while at times life-saving, is associated with complications including barotrauma, prolonged respiratory weaning and the development of ventilator-associated pneumonia. Furthermore, patients who convert from NIV to invasive ventilation have a substantially higher mortality rate (30% compared to 7%).⁷ It is unclear whether this higher mortality rate is due to mechanical ventilation *per se* or is inherent in disease of a certain severity. It is also unknown whether using veno-venous extracorporeal

carbon dioxide removal (ECCO₂R) for AECOPD could avoid the need for invasive mechanical ventilation and improve mortality. However, there are several case reports and series supporting its use.⁸⁻¹⁰

Case report

A 62-year-old female was admitted from the community to the high dependency unit of Guy's and St Thomas' hospital, a nationally commissioned severe respiratory failure centre, following a 12-hour history of increasing shortness of breath and cough. She had known chronic obstructive pulmonary disease (COPD) (GOLD class 3), with two hospital admissions in the preceding two months, but without prior admission to intensive care. She was a life-long cigarette smoker of 40 pack years and continued to smoke before admission. Her medications included inhaled tiotropium, 18 µg daily, and inhaled salbutamol as required. Other medical conditions included bipolar affective disorder and osteoporosis. Her pre-morbid exercise tolerance allowed her to climb one flight of stairs and she did not require home oxygen therapy.

Initial examination revealed a cachectic lady who was unable to complete full sentences due to breathlessness. A diffuse, polyphonic, expiratory wheeze was present. The white cell count was raised at 18 x 10⁹/L; serum C-reactive protein was mildly raised at 23 mg/L. A chest radiograph showed hyper-inflated lung fields but did not show focal consolidation or evidence of pneumothoraces.

Nebulised bronchodilators, intravenous magnesium, hydrocortisone, doxycycline and an aminophylline infusion were commenced. Sputum was cultured and subsequently revealed a significant growth of *Haemophilus influenzae*. Following initial bronchodilator therapy, the patient remained in type 2 respiratory failure with pH 7.27, pCO₂ 7.31 kPa, pO₂ 8.88 kPa, HCO₃⁻ 24.8 mmol/L and NIV was initiated (IPAP

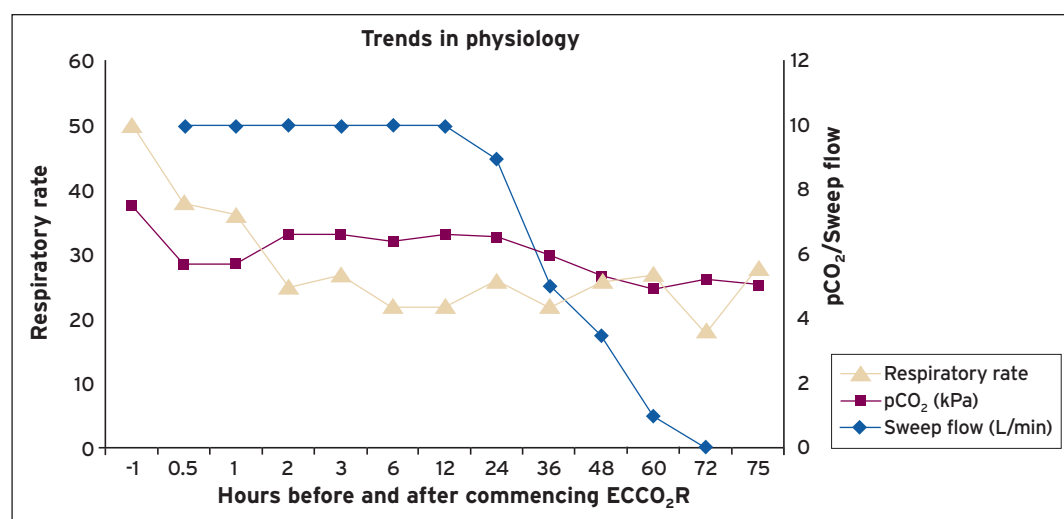


Figure 1 Non-linear plot of respiratory rate, arterial pCO₂ and sweep flow against time.

22 cm H₂O, EPAP 5 cm H₂O, FiO₂ 0.28) with a NIPPY 3+ ventilator (B&D Electromedical, UK).

Over the first three days of her admission there was substantial clinical improvement with normalisation of arterial pH and pCO₂. However on day four her condition deteriorated, with progressive tachypnoea (50 breaths per minute), raised work of breathing and signs of significant exhaustion on NIV (IPAP 22 cm H₂O, EPAP 6 cm H₂O, FiO₂ 0.28). Arterial blood gas showed pH 7.34, pCO₂ 7.48 kPa, pO₂ 7.48 kPa, HCO₃⁻ 30.4 mmol/L. Despite her condition, the patient expressed a clear preference to avoid endotracheal intubation and veno-venous ECCO₂R was commenced with the aim of achieving this.

The patient was transferred to our 30-bedded level 3 intensive care unit where a 15.5 French gauge, dual-lumen cannula was inserted percutaneously under local anaesthesia into the right femoral vein using a Seldinger technique; the procedure was well tolerated and without complication. Veno-venous ECCO₂R was commenced using the Hemolung system (ALung Technologies, Pittsburgh, USA). Measured carbon dioxide clearance provided by the circuit was approximately 90 mL/min at a blood flow of 370 mL/min and sweep gas flow (FiO₂ 0.21) of 10 L/min. Systemic heparinisation was commenced with a target APTTR of 1.5-2.

On commencement of veno-venous ECCO₂R, NIV was discontinued at patient request. Within 30 minutes of starting ECCO₂R therapy, the patient reported a reduced sensation of breathlessness and her respiratory rate had improved to less than 40 breaths per minute. By two hours after initiation of support, her respiratory rate was less than 30 breaths per minute (see **Figure 1**).

Within six hours the patient was able to converse and fully engage with her treatment, which included intensive physiotherapy, bronchodilators, steroids and antibiotics. On day two of ECCO₂R and despite being femorally cannulated, the patient was able to transfer from bed to chair with nursing assistance. By the third day of ECCO₂R support, the patient's bronchospasm had improved significantly and following a successful trial of cessation of extracorporeal support (zero sweep flow) the femoral cannula was removed. Routine screening using Doppler ultrasound did not show evidence of

deep vein thrombosis of the right leg following decannulation. On day 10 of her hospital admission, the patient was transferred to the respiratory ward, and after a further three days was discharged from hospital at her baseline level of function. After 30 days she was alive and had not been readmitted to hospital. She did not require home oxygen therapy following discharge.

Discussion

Studies in the use of ECCO₂R in AECOPD are limited. There are case reports from Germany,⁸ Japan⁹ and the US¹⁰ and this is the first description in the UK of the use of ECCO₂R to prevent endotracheal intubation.

An observational study¹¹ in Germany compared 21 patients treated with arterio-venous ECCO₂R after failure to respond to NIV (14 of whom had AECOPD), to 21 control patients, propensity score matched for age, diagnosis, Simplified Acute Physiology Score II and arterial pH, who had proceeded to endotracheal intubation. Only two patients managed with ECCO₂R proceeded to invasive mechanical ventilation and there was a trend towards reduced length of stay, though there was no mortality difference.

A small pilot study in India and Germany¹² made use of veno-venous ECCO₂R for patients with AECOPD. Eight of nine patients failing to respond to, or wean from, NIV and treated with ECCO₂R, avoided intubation; the remaining patient developed worsening respiratory failure and declined intubation. Details of successfully treated patients were reported subsequently in a case series¹³ and a case report.⁸ Although this was a small feasibility study, it suggested that ECCO₂R may help prevent the need for endotracheal intubation in AECOPD.

The hazards of invasive ventilation are well described. By avoiding endotracheal intubation there may be several advantages of employing ECCO₂R. Potential risks of airway trauma, tracheostomy, prolonged ventilatory wean and ventilator-induced lung injury are avoided. Ventilator-associated pneumonia may be avoided and by encouraging spontaneous breathing, respiratory muscle weakness may be reduced. A reduction or lack of need for sedation improves autonomy and interaction and avoids a risk factor for delirium.

Furthermore, improved interaction allows more effective engagement in physiotherapy and spontaneous breathing has been shown to allow more effective delivery of bronchodilator therapy than during mechanical ventilation.¹⁴

However, substituting ECCO₂R for invasive mechanical ventilation will not offer the advantages of tracheo-bronchial suctioning and airway protection in the drowsy, hypercapnic patient. Risks of cannulation include haemorrhage, infection, neurovascular damage, vessel stenosis/thrombosis and pneumothorax. Furthermore, there is a requirement for systemic heparinisation which increases the risk of bleeding. Circuit-related problems include disconnection, risk of air embolisation and haemolysis secondary to the pump (the latter is much reduced by the use of modern centrifugal pumps).

On balance, it would appear that for a select group of patients there may be advantages to avoiding endotracheal intubation by using veno-venous ECCO₂R.

Conclusion

This case report illustrates an alternative treatment strategy for patients with AECOPD who deteriorate despite treatment with NIV. With significant tachypnoea, a high work of breathing and exhaustion, our patient would have undoubtedly proceeded to invasive mechanical ventilation had the timely use of ECCO₂R not been instituted. However, it is unknown whether it altered her ultimate outcome.

At present, unfamiliarity with ECCO₂R devices and the resource implications may preclude widespread uptake. However, there is a convincing theoretical benefit to its use in AECOPD and as technology continues to evolve, efficacy and safety are likely to improve. Randomised controlled trials are required to establish the role of ECCO₂R in AECOPD and its effect on clinically relevant patient outcomes.

Consent

Written consent for publication of this report was gained from the patient.

Declaration of interests

NB is a Member of the ALung Inc Medical Advisory board and has received reimbursement for travel expenses and research grants from ALung Inc. All payments have been paid to Guy's and St Thomas' NHS Foundation Trust, with NB receiving no personal payments.

Both NA and NG will receive payments and travel funding from Maquet for delivering Cardiohelp training.

References

- Hill JD, O'Brien TG, Murray JJ *et al*. Prolonged extracorporeal oxygenation for acute post-traumatic respiratory failure (shock-lung syndrome). Use of the Bramson membrane lung. *N Engl J Med* 1972;286:629-34.
- Peek GJ, Mugford M, Tiruvoipati R *et al*. Efficacy and economic assessment of conventional ventilatory support versus extracorporeal membrane oxygenation for severe adult respiratory failure (CESAR): a multicentre randomised controlled trial. *Lancet* 2009;374:1351-63.

- Gattinoni L, Kolobow T, Tomlinson T *et al*. Low-frequency positive pressure ventilation with extracorporeal carbon dioxide removal (LFPPV-ECCO₂R): an experimental study. *Anesth Analg* 1978;57:470-77.
- Kolobow T, Gattinoni L, Tomlinson TA, Pierce JE. Control of breathing using an extracorporeal membrane lung. *Anesthesiol* 1977;46:138-41.
- Terragni P, Maiolo G, Ranieri VM. Role and potentials of low-flow CO₂ removal system in mechanical ventilation. *Curr Opin Crit Care* 2012;18:93-98.
- Lightowler JV, Wedzicha JA, Elliott MW, Ram FS. Non-invasive positive pressure ventilation to treat respiratory failure resulting from exacerbations of chronic obstructive pulmonary disease: Cochrane systematic review and meta-analysis. *BMJ* 2003;326:185-89.
- Chandra D, Stamm JA, Taylor B *et al*. Outcomes of noninvasive ventilation for acute exacerbations of chronic obstructive pulmonary disease in the United States, 1998-2008. *Am J Respir Crit Care Med* 2012;185:152-59.
- Bonin F, Sommerwerck U, Lund LW, Teschler H. Avoidance of intubation during acute exacerbation of chronic obstructive pulmonary disease for a lung transplant candidate using extracorporeal carbon dioxide removal with the Hemolung. *J Thorac Cardiovasc Surg* 2013;145:e43-44.
- Otsu T, Ezaki K, Nogami T *et al*. [A case of exacerbation of chronic pulmonary disease successfully treated by extracorporeal lung assist with a membrane lung]. *Nihon Kyobu Shikkan Gakkai Zasshi* 1986;24:1131-34. In Japanese.
- Cardenas VJ Jr, Lynch JE, Ates R *et al*. Venovenous carbon dioxide removal in chronic obstructive pulmonary disease: experience in one patient. *ASAIO J* 2009;55:420-22.
- Kluge S, Braune SA, Engel M *et al*. Avoiding invasive mechanical ventilation by extracorporeal carbon dioxide removal in patients failing non-invasive ventilation. *Intensive Care Med* 2012;38:1632-39.
- Burki NK, Mani RK, Herth FJ *et al*. A novel extracorporeal CO₂ removal system: results of a pilot study of hypercapnic respiratory failure in patients with COPD. *Chest* 2013;143:678-86.
- Mani RK, Schmidt W, Lund LW, Herth FJ. Respiratory dialysis for avoidance of intubation in acute exacerbation of COPD. *ASAIO J* 2013;59:675-78.
- Malliotakis P, Mouloudi E, Prinianakis G *et al*. Influence of respiratory efforts on B2-agonist induced bronchodilation in mechanically ventilated COPD patients: a prospective clinical study. *Respir Med* 2007;101:300-07.

Stephen Cole Specialty Registrar, Anaesthesia and Intensive Care Medicine
stephen.cole3@nhs.net

Nicholas A Barrett Consultant in Critical Care Medicine

Guy Glover Consultant in Critical Care Medicine

Chris IS Langrish Consultant in Critical Care Medicine

Chris Meadows Consultant in Critical Care Medicine

Kathleen Daly Consultant Nurse, Critical Care

Nicola Agnew Senior Clinical Perfusionist

Nigel Gooby Senior Clinical Perfusionist

Nicholas Ioannou Consultant in Critical Care Medicine

Department of Critical Care, Guy's and St Thomas' NHS Foundation Trust, London