

than an artery. However, ultrasound examination of the wire in the vein proceeds down the neck until the wire can no longer be seen, but this does not confirm that the wire tip has been identified. In other words, the tip could well be in an artery but not visualized, leading to an accidental arterial dilation. Manometry minimizes this risk by inserting a thin catheter into the structure into which the wire will ultimately be reintroduced, allowing confirmation that the blood column is low pressure and reinsertion of the wire into what is certainly the vein as possible.

I would add incidentally that the technique is very conducive to a teaching model. In contrast to the experience of Ezaru et al.,<sup>1</sup> the overwhelming majority of central venous catheterizations at our institution are performed by trainees under the supervision of an attending anesthesiologist. Successful manometry is a key waypoint reassuring the teacher that the procedure is going well.

Warren Sandberg, MD, PhD

Harvard Medical School

Boston, Massachusetts

Department of Anesthesia, Critical Care and

Pain Medicine

Massachusetts General Hospital

Boston, Massachusetts

wsandberg@partners.org

## REFERENCES

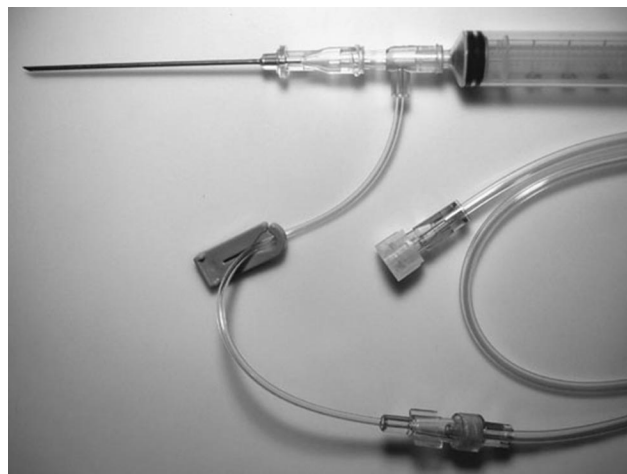
1. Ezaru CS, Mangione MP, Oravitz TM, Ibinson JW, Bjerke RJ. Eliminating arterial injury during central venous catheterization using manometry. *Anesth Analg* 2009; 109:130–4
2. Leibowitz AB, Rozner MA. Pro: Manometry should routinely be used during central venous catheterization. *Anesth Analg* 2009;109:3–5
3. Leone BJ. Con: Manometry during internal jugular cannulation: case not proven. *Anesth Analg* 2009;109:6–7

DOI: 10.1213/ANE.0b013e3181bc4727

## Pressure Waveform Monitoring During Central Venous Catheterization

### To the Editor:

Recently, Ezaru et al.<sup>1</sup> confirmed the previous results of Jobes et al.<sup>2</sup> showing that color and pulsatility are not completely reliable for detecting intraarterial puncture during central venous catheter insertion. Jobes



**Figure 1.** A sterile T-shaped adapter is placed between the needle and the syringe. A length of sterile pressure tubing is attached to the pigtail on the T-shaped adapter. The end of the pressure tubing is handed off to a nonsterile assistant who connects the tubing to the pressure transducer and flushes the system with saline. After the blood vessel is punctured with the needle (with or without ultrasound guidance) and blood is aspirated into the syringe, the pressure waveform is instantly present on the monitor screen. After confirming that the waveform is venous, the syringe is removed from the T-shaped adapter, or the syringe and T-shaped adapter are removed together from the needle, and a wire is passed through the needle; if an IV catheter-over-needle was used, the syringe, T adapter, and needle are removed together, and a wire is passed through the IV catheter.

et al.<sup>2</sup> used transduction of a pressure waveform, whereas Ezaru et al. used manometry.

Since the mid-1980s, we have used the T-Connector (Smiths Medical) (Fig. 1) to transduce a pressure waveform during central venous catheter insertion.<sup>3</sup> The T-Connector has the advantage of allowing observation of a pressure waveform without the inconvenience of disconnecting the syringe and reconnecting transducer or manometry tubing to the needle or catheter. The present cost of the T-Connector is \$0.96.

For those who prefer to use a standard IV catheter-over-needle (e.g., “angiocath”) to puncture the blood vessel, rather than a bare needle, this same approach can be used by simply substituting the IV catheter-over-needle for the bare needle. After puncturing the blood vessel and aspirating blood, the IV catheter is advanced fully into the vessel, with the needle remaining partially inserted in the catheter, and the pressure waveform is observed.

We always measure a pressure waveform even when using ultrasound guidance, because inadvertent

arterial puncture or cannulation can occur despite the use of ultrasound.<sup>3,4</sup> Clear visualization of the guidewire in the vein with ultrasound provides reassurance that the guidewire has been properly placed; however, rarely, a wire may traverse the vein and enter the artery, and this may not be appreciated with ultrasound, particularly if it occurs below the level of the clavicle where visualization with ultrasound is difficult or impossible.

It seems reasonable to use an inexpensive piece of plastic in order to reduce the incidence of serious complications.

Andrew Bowdle, MD, PhD

University of Washington

Seattle, Washington

bowdle@u.washington.edu

Evan Kharasch, MD, PhD

Washington University

St. Louis, Missouri

Howard Schwid, MD, PhD

University of Washington

Seattle, Washington

## REFERENCES

1. Ezaru CS, Mangione MP, Oravitz TM, Ibinson JW, Bjerke RJ. Eliminating arterial injury during central venous catheterization using manometry. *Anesth Analg* 2009;109:130–4

2. Jobes DR, Schwartz AJ, Greenhow DE, Stephenson LW, Ellison N. Safer jugular vein cannulation: recognition of arterial puncture and preferential use of the external jugular route. *Anesthesiology* 1983;59:353–5
3. Bowdle TA, Edwards M, Domino KB. Reducing errors in cardiac anesthesiology. In: Kaplan JA, ed. *Kaplan's cardiac anesthesia*. 5th ed. Philadelphia: Saunders, 2006;1217–34
4. Augoustides JG, Horak J, Ochroch AE, Vernick WJ, Gambone AJ, Weiner J, Pinchasi D, Kowalchuk D, Savino JS, Jobes DR. A randomized controlled clinical trial of real-time needle-guided ultrasound for internal jugular venous cannulation in a large university anesthesia department. *J Cardiothorac Vasc Anesth* 2005;19:310–5

DOI: 10.1213/ANE.0b013e3181bea01d

### In Response:

We thank all of the authors who corresponded (not all were published) and weighed in on what we consider **a critical patient safety issue**. Ibinson et al.<sup>1</sup> (the authors of the article that sparked the pro and con editorials) clarified the data with regard to the effectiveness of using manometry, and their letter clearly strengthens our position. However, we believe that their concern regarding the infectious risk of using ultrasound in properly trained hands is overstated. In fact, many surgeons and interventional radiologists have wholeheartedly embraced this technology, and their procedures do not seem to be associated with any increased risk of infection over the past few years.

Ellison et al.<sup>2</sup> support our position using a rather lofty philosophical analogy. They also comment on the utility of **ultrasound**, which we believe is a **complementary technique** in central line insertion, but it **should not be used in place of manometry**. Although ultrasound helps identify the anatomy and might be able to demonstrate a short length of guidewire in the vein, the guidewire cannot always be visualized, and the tip of the guidewire might be in the artery while the entry part of the wire appears to be in the vein. These ultrasound pitfalls are addressed in the letters by Sandberg<sup>3</sup> and Bowdle et al.<sup>4</sup> reiterating our suggestion that kits can and should be customized to one's individual technical needs.

Mittnacht<sup>5</sup> discusses the case of **carotid dissection during ultrasound-assisted** (but not guided) central venous catheterization.<sup>6</sup> Similar to the letter by Sandberg, Mittnacht also explains the potential problems with ultrasound guidewire visualization and makes the case for real-time ultrasound guidance, which one of us (ABL) strongly advocates, whereas the other (MAR) does not.

However, we both agree with the concluding paragraph in the article by Mittnacht, stating that a variety of techniques should be brought to bear to **prevent this largely life-threatening complication that seems to occur far too often**.

Andrew B. Leibowitz, MD

*Departments of Anesthesiology and Surgery  
Mount Sinai School of Medicine  
New York, New York*

Marc A. Rozner, PhD, MD

*Department of Anesthesiology and  
Perioperative Medicine  
Department of Cardiology  
University of Texas M. D. Anderson  
Cancer Center  
Houston, Texas  
mrozner@mdanderson.org*

### REFERENCES

1. Ibinson JW, Oravitz TM, Ezaru CS, Mangione MP. Clarification of issues regarding manometry for central venous catheterization. *Anesth Analg* 2009;109:2028
2. Ellison N, Jobes DR, Schwartz AJ. Primum non nocere. *Anesth Analg* 2009;109:2028–9
3. Sandberg WS. Just do it. *Anesth Analg* 2009;109:2029–30
4. Bowdle A, Kharasch E, Schwid H. Pressure waveform monitoring during central venous catheterization. *Anesth Analg* 2009;109:2030–1
5. Mittnacht AJC. Ultrasound guided central venous cannulation: false sense of security. *Anesth Analg* 2009;109:2029
6. Parsons AJ, Alfa J. Carotid dissection: a complication of internal jugular vein cannulation with the use of ultrasound. *Anesth Analg* 2009;109:135–136

DOI: 10.1213/ANE.0b013e3181bc4755

### Is a Different Dose of Anesthesia the Real Problem?

#### To the Editor:

There are several important limitations to the study by Meierhenrich et al.,<sup>1</sup> which shows a decrease in hepatic blood flow after thoracic epidural anesthesia in patients also receiving general anesthesia. First

and from a technical aspect, the use of a single, unblinded investigator to analyze data could introduce bias. The normal practice for echocardiography studies would be to have 2 blinded observers and to report interobserver variability. Second, it is also advisable to have good alignment of the Doppler beam with flow. Even in the image shown, the angle of insonation is much greater than the maximal recommended 20°. The use of proprietary angle correction introduces substantial error into the measurement, and, although it is perhaps useful for observing trend changes, it could introduce bias when attempting to perform quantitative measurements. The hepatic vein diameter is variable, and it is difficult to ascertain from the study how reliable it was to replicate the same measurement point each time. Because the area calculation is proportional to the square of the radius, small errors can lead to a large change in flow estimation. Finally, perhaps the most important problem with the study is that the desflurane component of the general anesthetic was the same in both the epidural and control groups. Because the amount of anesthesia required to produce the same anesthetic depth is reduced in the presence of a working epidural<sup>2,3</sup> because of a reduction in sensory stimuli reaching the brain, it is possible that the differences observed in this study were attributable to the relatively greater depth of anesthesia in the epidural group.

Colin F. Royse, MBBS, MD, FANZCA

*Department of Pharmacology  
Anaesthesia and Pain Management Research  
Unit  
University of Melbourne  
Carlton, Victoria  
Australia  
colin.royse@unimelb.edu.au*

### REFERENCES

1. Meierhenrich R, Wagner F, Schutz W, Rockemann M, Steffen P, Sentleblen U, Gauss A. The effects of thoracic epidural anesthesia on hepatic blood flow in patients under general anesthesia. *Anesth Analg* 2009;108:1331–7