

## CLINICAL PRACTICE

# Deep-Vein Thrombosis of the Upper Extremities

Nils Kucher, M.D.

*This Journal feature begins with a case vignette highlighting a common clinical problem. Evidence supporting various strategies is then presented, followed by a review of formal guidelines, when they exist. The article ends with the author's clinical recommendations.*

**A 58-year-old woman presents with a 3-day history of pain, heaviness, and functional impairment in her left arm. She has received chemotherapy for ovarian cancer through an implanted port and catheter (Port-a-Cath) on the left side. Physical examination reveals a swollen and erythematous left arm and visible venous collaterals at the neck, shoulder, and chest. Compression ultrasonography reveals a patent left distal subclavian vein, but there is an abnormal Doppler-flow pattern suggestive of a more proximal thrombosis. How should this case be further evaluated and managed?**

## THE CLINICAL PROBLEM

Approximately 10% of all cases of deep-vein thrombosis involve the upper extremities, resulting in an annual incidence of 0.4 to 1 case per 10,000 people.<sup>1-3</sup> Cases have become more common because of the increased use of central venous catheters and of cardiac pacemakers and defibrillators. Axillary subclavian veins are often involved, and secondary forms are more common than primary forms (Table 1).<sup>15</sup> As compared with patients who have thrombosis of a lower extremity, patients with deep-vein thrombosis of an upper extremity are typically younger, leaner, more likely to have a diagnosis of cancer,<sup>1,2</sup> and less likely to have acquired or hereditary thrombophilia.<sup>4</sup>

In patients with primary deep-vein thrombosis of an upper extremity, repetitive microtrauma to the subclavian vein and its surrounding structures, the result of anatomical abnormalities within the costoclavicular junction, may cause inflammation, venous intima hyperplasia, and fibrosis, all of which characterize the venous thoracic outlet syndrome.<sup>16</sup> Approximately two thirds of patients with primary deep-vein thrombosis of an upper extremity, most of whom are young and male, report strenuous activity involving force or abduction of the dominant arm before the development of thrombosis, known as the Paget-Schroetter syndrome.<sup>17</sup>

Complications of deep-vein thrombosis, which are less common in the upper extremities than in the lower extremities, include pulmonary embolism (6% for upper extremities<sup>2,18</sup> vs. 15 to 32% for lower extremities<sup>19,20</sup>), recurrence at 12 months (2 to 5% for upper extremities<sup>2,21,22</sup> vs. 10% for lower extremities<sup>23</sup>), and the post-thrombotic syndrome (5% for upper extremities<sup>24</sup> vs. up to 56% for lower extremities<sup>25</sup>). Thrombosis of the axillary subclavian veins (as compared with thrombosis at other locations) and residual thrombosis at 6 months are associated with an increased risk of the post-thrombotic syndrome; the risk is lower for catheter-associated thrombosis.<sup>24</sup> In a prospective study of 512 patients with deep-vein thrombosis of an upper extremity, 38% of whom had cancer, the 3-month

From the Departments of Angiology and Cardiology, Cardiovascular Division, Inselspital, University Hospital Bern, Bern, Switzerland. Address reprint requests to Dr. Kucher at the Departments of Angiology and Cardiology, Cardiovascular Division, Inselspital, University Hospital Bern, 3010 Bern, Switzerland, or at nils.kucher@insel.ch.

N Engl J Med 2011;364:861-9.

Copyright © 2011 Massachusetts Medical Society.



**An audio version of this article is available at NEJM.org**

mortality rate was 11%, and only 1 death was attributed to pulmonary embolism.<sup>2</sup>

## STRATEGIES AND EVIDENCE

### EVALUATION

Symptoms of deep-vein thrombosis of an upper extremity include discomfort, pain, paresthesias, and weakness in the arm. Swelling, edema, discoloration, and visible venous collaterals are typical signs. The superior vena cava syndrome is manifested as facial swelling, headache, nausea, and dyspnea and is usually caused by caval tumor infiltration. Routine screening has revealed thrombosis in up to two thirds of patients with central venous catheters<sup>26</sup>; the majority of patients with catheter-associated thrombosis<sup>27</sup> or with venous obstructions caused by pacemaker leads<sup>28</sup> have no suggestive symptoms or signs. Patient charac-

teristics, the type of treatment administered, and factors related to catheter use affect the risk of catheter-associated thrombosis (Table 1).

One study investigated the use of a pretest clinical prediction score for the diagnosis of deep-vein thrombosis of an upper extremity. Catheter or pacemaker use, pain, and edema each added 1 point to a patient's score, and a likelihood of an alternative diagnosis subtracted 1 point.<sup>29</sup> In the validation sample of 214 patients, deep-vein thrombosis of an upper extremity was found in 13% of patients with a score of 0 or less, 38%, of patients with a score of 1, and 69% of patients with a score of 2 or more.

A negative result on a D-dimer test is an accurate means of ruling out thrombosis of the lower extremities when the clinical pretest probability is low or intermediate, but a D-dimer test cannot be recommended for use in screening

**Table 1. Pathogenesis of Deep-Vein Thrombosis of an Upper Extremity.**

Type of Deep-Vein Thrombosis	Mechanisms or Risk Factors
<b>Primary (20% of cases)</b>	
Venous thoracic outlet syndrome	Compression of the subclavian vein resulting from abnormalities of one or more structures at the costoclavicular junction: first rib, clavicle, subclavius muscle, costoclavicular ligament, or anterior scalene muscle
Effort-related thrombosis (Paget-Schroetter syndrome)	Microtrauma to the subclavian vein from repetitive arm movements during overhead activities (e.g., painting or doing car repairs) or vigorous exercise (e.g., pitching a baseball, playing badminton, swimming, lifting weights, rowing, or wrestling); abnormalities of the costoclavicular junction may be present
Idiopathic	No relation to the thoracic outlet syndrome or to exertion; hereditary or acquired thrombophilia may be present <sup>4</sup>
<b>Secondary (80% of cases)</b>	
Catheter-associated thrombosis (indwelling central venous catheter, pacemaker, or defibrillator leads)	Patient-related risk factors: ovarian cancer (vs. other types of cancer), <sup>5</sup> lung adenocarcinoma (vs. squamous-cell carcinoma of the lung, head, neck, or esophagus), <sup>6</sup> metastatic (vs. localized) cancer, <sup>7</sup> history of thrombosis <sup>8</sup> Treatment-related risk factors: radiation therapy of the chest, <sup>7</sup> bolus (vs. diluted) chemotherapy infusions, <sup>9</sup> parenteral nutrition <sup>10</sup> Catheter-related risk factors: malplacement of catheter tip (not at atrio-caval junction), <sup>7</sup> left-sided catheter placement, <sup>7</sup> large number of catheter lumens, <sup>11</sup> several attempts to place catheter, <sup>5</sup> prior central venous catheterization, <sup>5</sup> open-ended (vs. closed) catheter, <sup>12</sup> catheter infection, <sup>13</sup> polyvinylchloride or polyethylene (vs. silicone or polyurethane) catheter material <sup>14</sup>
Cancer-associated thrombosis	Cancer-related coagulation abnormalities, chemotherapy-induced coagulation abnormalities, vein compression or infiltration from mediastinal tumor mass
Surgery or trauma of the arm or shoulder	Injury or compression of arm veins, stasis from immobilization or plaster cast
Pregnancy, use of oral contraceptives, ovarian hyperstimulation syndrome	Hormone-induced coagulation abnormalities; hereditary or acquired thrombophilia may increase risk

patients with suspected deep-vein thrombosis of an upper extremity, since many of these patients have coexisting conditions that are associated with an elevated D-dimer level. For example, in a study of 52 patients with suspected deep-vein thrombosis of an upper extremity (23 of whom had a diagnosis of cancer and 18 of whom had an implanted catheter), D-dimer levels were measured with the use of an enzyme-linked immunosorbent assay (VIDAS, BioMérieux). The cutoff value of 500  $\mu$ g per liter had a sensitivity of 100% but a specificity of only 14% for diagnosis; only 5 patients (10%) had D-dimer levels below this cutoff point.<sup>30</sup>

#### *Compression Ultrasonography and Duplex Ultrasonography*

Compression ultrasonography, which relies on the finding that a thrombosed vein cannot be compressed, is the clinical standard for diagnosing thrombosis of a lower extremity and is also the preferred imaging test for patients with suspected deep-vein thrombosis of an upper extremity. However, the proximal subclavian and brachiocephalic veins are difficult to visualize because of overlying bony structures. In a review of nine studies, compression ultrasonography had a sensitivity of 97% (95% confidence interval [CI], 90 to 100%) and a specificity of 96% (95% CI, 87 to 100%) for deep-vein thrombosis of an upper extremity.<sup>31</sup> For cases in which distal arm veins appear patent and thrombosis of the proximal arm veins (subclavian or brachiocephalic) is suspected, duplex ultrasonography may reveal an abnormal Doppler pattern with reduced variability or no variability in flow velocity during a Valsalva maneuver. However, in one study, the addition of color Doppler to compression ultrasonography did not improve diagnostic accuracy as compared with the use of compression ultrasonography alone. Additional testing may be required if an abnormal Doppler signal is present.<sup>31</sup> Whereas serial ultrasonography has been recommended when deep-vein thrombosis of a lower extremity is suspected, data are lacking to support this approach for the upper extremities.

#### *Conventional Phlebography and Other Imaging Tests*

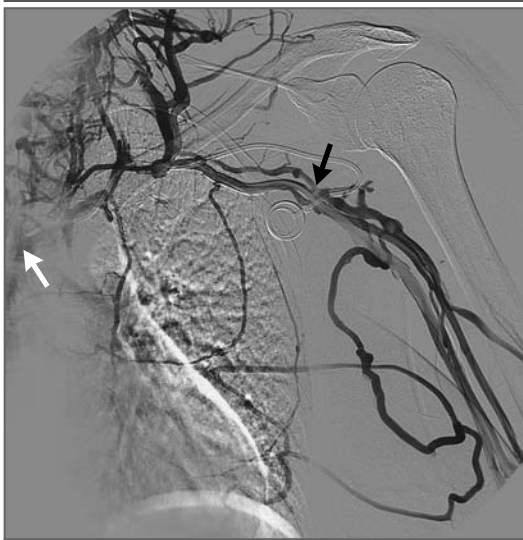Although ultrasonography has virtually replaced conventional phlebography in diagnosing deep-

vein thrombosis of an upper extremity, the latter is occasionally performed in patients with indeterminate ultrasonographic results or before catheter-directed thrombolysis or surgical decompression of the venous thoracic outlet (Fig. 1). Positional phlebography is performed during arm abduction and is useful for diagnosing residual vein stenosis within the costoclavicular junction after an episode of deep-vein thrombosis. Disadvantages of phlebography include the use of contrast agents, radiation exposure similar to that of computed tomography (CT), and difficulties in accessing peripheral arm veins. Severe renal dysfunction and allergy to contrast agents containing iodine are relative contraindications.

Data on the diagnostic accuracy of CT angiography<sup>32</sup> or magnetic resonance angiography<sup>33</sup> are limited. Either test may be useful for imaging the proximal arm veins if the findings on ultrasonography are indeterminate and for diagnosing suspected concomitant conditions, including neoplasm or associated adenopathy and abnormalities at the venous thoracic outlet.

#### **MANAGEMENT**

In patients with catheter-associated thrombosis, routine catheter removal is not recommended. In deciding whether to remove the catheter, several factors should be considered, including the need for further intravenous administration of medications or blood sampling, expected difficulties in obtaining venous access, and the patient's preference. Removal is generally warranted when there is catheter malfunction or infection or a contraindication to anticoagulation therapy, when there are persistent symptoms or signs of deep-vein thrombosis of an upper extremity during initial anticoagulation therapy, or when the catheter is no longer needed. For cases in which removal is considered appropriate, data are lacking on the optimal timing (e.g., immediately vs. 3 to 5 days after initiation of anticoagulation therapy). In a cohort study of 74 patients with cancer and symptomatic catheter-associated thrombosis (77% of whom had peripherally inserted central catheters, 19% implanted ports, and 4% Hickman catheters), the catheters were left in place while the patients received anticoagulation therapy.<sup>34</sup> At 3 months, 57% of the patients had functional catheters, and 43% had had the catheters removed for reasons other than thrombosis or



**Figure 1. Conventional Digital Subtraction Phlebogram in a Patient with Catheter-Associated Deep-Vein Thrombosis of the Left Arm.**

Obstructive filling defects are visible in the left brachiocephalic vein (white arrow indicates the tip of an implanted catheter) and continue as partial filling defects in the left subclavian and axillary veins (black arrow points to the distal thrombus extension). Extensive jugular collaterals can also be seen. (Image courtesy of Dr. Hanno Hoppe, Department of Radiology, University Hospital Bern, Bern, Switzerland.)

catheter failure; none had recurrence or progression of thrombosis.

The aims of treatment are to alleviate the symptoms of deep-vein thrombosis of an upper extremity and to prevent thrombus progression, early recurrence, pulmonary embolism, and the post-thrombotic syndrome. Strategies include anticoagulation therapy, thrombolysis, mechanical catheter interventions, and surgical procedures.

#### Anticoagulation Therapy

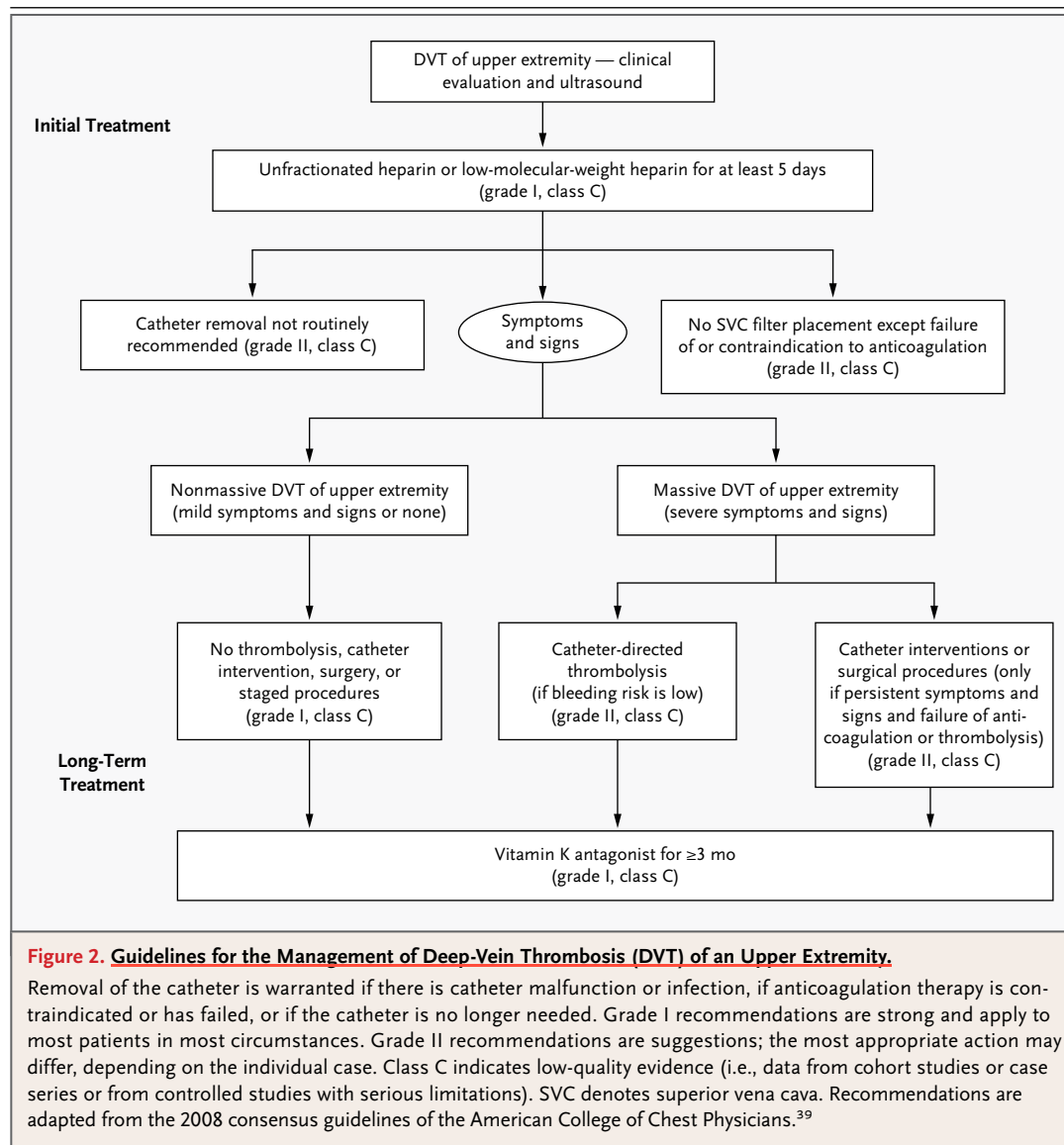
Randomized, controlled trials of unfractionated heparin or low-molecular-weight heparin have not been performed in patients with deep-vein thrombosis of an upper extremity; data from trials involving patients with thrombosis of a lower extremity are used to guide management. In a meta-analysis of 22 trials (8867 patients) comparing low-molecular-weight heparin with unfractionated heparin in the treatment of thrombosis in a lower extremity, low-molecular-weight hepa-

rin was associated with a lower rate of recurrent venous thromboembolism at 6 months (3.6% vs. 5.4%; odds ratio, 0.68; 95% CI, 0.55 to 0.84) and a lower rate of death (4.5% vs. 6.0%; odds ratio, 0.76; 95% CI, 0.62 to 0.92); during the initial treatment period, low-molecular-weight heparin also resulted in a lower rate of major bleeding (1.2% vs. 2.0%; odds ratio, 0.57; 95% CI, 0.39 to 0.83).<sup>35</sup> In four observational studies involving a total of 209 patients with deep-vein thrombosis of an upper extremity, who were mainly treated with low-molecular-weight heparin, the rate of recurrence was 1.9%, and there were no cases of pulmonary embolism during follow-up<sup>34,36-38</sup>; rates of major bleeding were 2 to 4%.<sup>34,38</sup> Initial anticoagulation treatment thus usually involves low-molecular-weight heparin (Fig. 2); unfractionated heparin is preferred in patients with severe renal dysfunction. The effects of once-daily versus twice-daily dosing have not been compared in patients with deep-vein thrombosis of an upper extremity.

Data from controlled studies of the optimal duration of anticoagulation treatment in patients with deep-vein thrombosis of an upper extremity are also unavailable. On the basis of cohort studies showing low recurrence rates with the use of vitamin K antagonists for 3 to 6 months,<sup>22,38,40</sup> this duration is generally recommended for all types of anticoagulation therapy in patients with deep-vein thrombosis of an upper extremity, including those in whom a central venous catheter has been removed. Vitamin K antagonists are generally used except in patients with cancer, for whom low-molecular-weight heparin is preferred.<sup>39</sup> In the absence of compelling data to support their use, mechanical therapies, including compression bandages or sleeves, are not routinely recommended.

#### Thrombolysis

Catheter-directed thrombolysis should be considered in patients with deep-vein thrombosis of an upper extremity of recent onset who present with extensive swelling and functional impairment of the arm and who are at low risk for bleeding complications. As with anticoagulation therapy, evidence to support thrombolysis is mainly derived from patients with thrombosis of a lower extremity. In a multicenter registry of 473 such patients, catheter-directed thrombolysis was most effica-



cious if the symptom duration was less than 10 days.<sup>41</sup> In a randomized trial comparing catheter-directed thrombolysis with anticoagulation alone in 35 patients with iliofemoral thrombosis, thrombolysis resulted in a higher frequency of venous patency (72% vs. 12%) and a lower frequency of venous reflux (11% vs. 41%).<sup>42</sup> Observational data from patients with thrombosis of a lower extremity have pointed to higher rates of primary patency and lower rates of bleeding complications or the post-thrombotic syndrome among patients treated with catheter-directed thrombolysis as compared with those treated with systemic thrombolysis.<sup>43</sup>

Limited data are available regarding the outcome of thrombolysis in patients with deep-vein thrombosis of an upper extremity. Among 30 such patients who underwent catheter-directed thrombolysis with recombinant-tissue plasminogen activator (median total dose, 52 mg), the rate of partial or complete recanalization was 97%, the rate of major bleeding complications was 9%, and the rate of mild post-thrombotic syndrome was 21%.<sup>44</sup> Although the recanalization rate appears to be satisfactory, it remains unclear whether thrombolysis as compared with anticoagulation alone reduces the risk of recur-



rent thrombosis, pulmonary embolism, or the post-thrombotic syndrome among patients with deep-vein thrombosis of an upper extremity.

#### Mechanical Catheter Interventions

Mechanical catheter interventions (aspiration, fragmentation, thrombectomy, balloon angioplasty, or stenting) should be considered only in patients who have persistent, severe symptoms or signs of deep-vein thrombosis after anticoagulant therapy or thrombolysis and only when sufficient expertise and resources are available. In a case series of 49 patients, venous stents provided a temporary clinical benefit in most patients, but 62% required repeat intervention at 2 years.<sup>45</sup> Stents should not be used to treat residual subclavian-vein stenosis within the costoclavicular junction because they are associated with unacceptably high rates of stent deformation, stent fractures, and recurrent thrombosis.<sup>46,47</sup> The major risks of catheter interventions include recurrent thrombosis, pulmonary embolism, and bleeding complications.

Pharmacomechanical thrombolysis refers to the combination of catheter-directed thrombolysis and mechanical intervention. In an observational study of 93 patients with thrombosis in a lower extremity, pharmacomechanical thrombolysis and catheter-directed thrombolysis had similar efficacy, but the former was associated with a shorter duration of thrombolytic administration, a shorter hospital stay, and lower costs.<sup>48</sup> More data are needed to assess the benefits and risks of this approach.

#### Surgical Procedures

As is the case with mechanical catheter interventions, surgical procedures should be reserved for patients who have persistent, severe manifestations of deep-vein thrombosis despite the administration of anticoagulant or thrombolytic therapy and should be limited to centers with relevant expertise. Data from randomized trials are lacking to assess the benefits and risks of surgical treatment for deep-vein thrombosis of an upper extremity (e.g., thrombectomy, venoplasty, venous bypass, or decompression at the venous thoracic outlet). However, a randomized trial that compared surgical thrombectomy with anticoagulation alone in patients with iliofemoral thrombosis showed that at 6 months, the surgical group

had a higher rate of venous patency (76% vs. 35%) and a lower rate of the post-thrombotic syndrome (7% vs. 42%).<sup>49</sup>

Adequate surgical decompression of the venous thoracic outlet requires resection of the first rib by the transaxillary route or the use of supraclavicular or infraclavicular incisions. Some surgeons also advocate resection of the costoclavicular ligament, anterior scalenectomy, and venolysis.<sup>17</sup> In two case series with a total of 240 patients, venous patency rates after decompression of the thoracic outlet were reported as excellent, and up to 85% of patients had no evidence of the post-thrombotic syndrome at follow-up.<sup>50,51</sup> Postoperative complications include hemopneumothorax, injury of the long thoracic nerve or the phrenic nerve, wound hematoma requiring reoperation, and recurrent subclavian thrombosis.<sup>52</sup>

#### Staged Multidisciplinary Management

Some institutions have introduced a multidisciplinary approach to the treatment of patients with deep-vein thrombosis of an upper extremity, wherein patients with no symptoms or mild symptoms are treated with anticoagulation alone and patients with extensive swelling or functional impairment of the arm are generally treated with both catheter-directed thrombolysis and anticoagulation therapy. Patients are reassessed between 1 and 3 months after diagnosis of deep-vein thrombosis, and surgical decompression of the thoracic outlet with optional percutaneous balloon angioplasty is usually performed if the post-thrombotic syndrome is present (as evidenced by symptoms such as tenderness, pain, heaviness, or weakness or by signs such as edema, venous collaterals, erythema, or skin induration) and if residual vein stenosis at the venous thoracic outlet has been confirmed with the use of positional phlebography. In a study of 50 patients with primary deep-vein thrombosis of an upper extremity who received multidisciplinary care (of whom 46% underwent catheter-directed thrombolysis, 72% subsequent surgical decompression of the venous thoracic outlet, and 18% postoperative balloon angioplasty of residual vein stenosis), there were no cases of recurrent thrombosis, and 80% of patients had no evidence of the post-thrombotic syndrome at a 3-year follow-up assessment.<sup>53</sup> A case series of 22 patients showed similar outcomes with this strategy.<sup>54</sup>

### Prevention

There is currently no convincing evidence to support thromboprophylaxis in patients with central venous catheters, and routine pharmacologic prophylaxis is therefore not recommended. A meta-analysis of seven randomized trials involving patients with cancer and central venous catheters showed nonsignificant reductions in symptomatic thrombosis with the use of low-molecular-weight heparin or unfractionated heparin as compared with placebo in four trials (hazard ratio, 0.43; 95% CI, 0.18 to 1.16) or with the use of minidose warfarin (in most cases 1 mg daily) as compared with placebo in three trials (hazard ratio, 0.62; 95% CI, 0.30 to 1.27). However, an analysis that included all seven trials showed a significantly reduced risk of symptomatic thrombosis with the use of any anticoagulant (hazard ratio, 0.56; 95% CI, 0.34 to 0.92).<sup>27</sup> In this overall analysis, anticoagulation did not significantly affect the risk of major bleeding complications (hazard ratio, 1.83; 95% CI, 0.34 to 9.87) or death (hazard ratio, 0.74; 95% CI, 0.40 to 1.36).

Data are lacking to support the use of superior vena cava (SVC) filters for the prevention of pulmonary embolism in patients with deep-vein thrombosis of an upper extremity. In a review that included 209 patients treated with SVC filters, 3.8% had severe complications, including cardiac tamponade (4 patients), aortic perforation (2 patients), and recurrent pneumothorax (1 patient).<sup>18</sup> Consideration of SVC filter placement should generally be limited to patients with a contraindication to anticoagulation therapy and to those with thrombus progression or symptomatic pulmonary embolism despite adequate treatment with anticoagulants.

### AREAS OF UNCERTAINTY

There is no validated diagnostic algorithm for deep-vein thrombosis of an upper extremity that combines clinical probability, laboratory testing, and imaging. Randomized trials assessing the relative efficacy and safety of pharmacologic, catheter-based, and surgical approaches to treatment (alone or in combination) have been limited to patients with deep-vein thrombosis of a lower extremity. The role of novel oral anticoagulants

(e.g., direct thrombin inhibitors and factor Xa antagonists), the optimal duration of anticoagulation therapy for secondary prevention, and the role of thromboprophylaxis in patients at increased risk for deep-vein thrombosis of an upper extremity all warrant investigation.

### GUIDELINES FROM PROFESSIONAL SOCIETIES

Consensus guidelines from the American College of Chest Physicians provide detailed recommendations for the management of deep-vein thrombosis of an upper extremity.<sup>39</sup> The recommendations presented here are largely consistent with these guidelines.

### CONCLUSIONS AND RECOMMENDATIONS

In patients with acute discomfort, swelling of the arm, and risk factors such as vigorous arm exercise, an implanted central venous catheter or pacemaker, or a history of deep-vein thrombosis or cancer, the diagnosis of deep-vein thrombosis of an upper extremity is likely. Anticoagulation therapy should be promptly initiated; for acute cases, I generally recommend the administration of low-molecular-weight heparin once daily. Catheter-directed thrombolysis should be considered in cases of clinically massive deep-vein thrombosis, manifested by extensive swelling and functional impairment of recent onset, as in the patient described in the vignette. After the treatment recommended for acute cases has been completed, anticoagulation therapy is recommended for the next 3 to 6 months. Although vitamin K antagonists are generally used, low-molecular-weight heparin is preferable for this patient, given her underlying cancer.

Dr. Kucher reports receiving grant support from EKOS and honoraria from Sanofi-Aventis, GlaxoSmithKline, Boehringer Ingelheim, and EKOS and being named as coinventor of a method used to determine whether to issue an alert to consider prophylaxis in a patient at risk for venous thromboembolism (patented by Brigham and Women's Hospital) and as coinventor of a method to detect neointimal coverage of a coronary stent (patented by SIS Medical). No other potential conflict of interest relevant to this article was reported.

Disclosure forms provided by the author are available with the full text of this article at NEJM.org.

## REFERENCES

- Joffe HV, Kucher N, Tapson VF, Goldhaber SZ. Upper-extremity deep vein thrombosis: a prospective registry of 592 patients. *Circulation* 2004;110:1605-11.
- Muñoz FJ, Mismetti P, Poggio R, et al. Clinical outcome of patients with upper-extremity deep vein thrombosis: results from the RIETE Registry. *Chest* 2008;133:143-8.
- Isma N, Svensson PJ, Gottsäter A, Lindblad B. Upper extremity deep venous thrombosis in the population-based Malmö Thrombophilia Study (MATS): epidemiology, risk factors, recurrence risk, and mortality. *Thromb Res* 2010;125(6):e335-e338.
- Linnemann B, Meister F, Schwonberg J, Schindewolf M, Zgouras D, Lindhoff-Last E. Hereditary and acquired thrombophilia in patients with upper extremity deep-vein thrombosis: results from the MAISTHRO registry. *Thromb Haemost* 2008;100:440-6.
- Lee AY, Levine MN, Butler G, et al. Incidence, risk factors, and outcomes of catheter-related thrombosis in adult patients with cancer. *J Clin Oncol* 2006;24:1404-8.
- Anderson AJ, Krasnow SH, Boyer MW, et al. Thrombosis: the major Hickman catheter complication in patients with solid tumor. *Chest* 1989;95:71-5.
- Verso M, Agnelli G, Kamphuisen PW, et al. Risk factors for upper limb deep vein thrombosis associated with the use of central vein catheter in cancer patients. *Intern Emerg Med* 2008;3:117-22.
- Lobo BL, Vaidean G, Broyles J, Reeves AB, Shorr RI. Risk of venous thromboembolism in hospitalized patients with peripherally inserted central catheters. *J Hosp Med* 2009;4:417-22.
- Baglin TP, Boughton BJ. Central venous thrombosis due to bolus injections of antileukaemic chemotherapy. *Br J Haematol* 1986;63:606-7.
- Fabri PJ, Mirtallo JM, Ebbert ML, Kudsk KA, Powell C, Ruberg RL. Clinical effect of nonthrombotic total parenteral nutrition catheters. *J Parenter Enteral Nutr* 1984;8:705-7.
- Eastridge BJ, Lefor AT. Complications of indwelling venous access devices in cancer patients. *J Clin Oncol* 1995;13:233-8.
- Hsieh CC, Weng HH, Huang WS, et al. Analysis of risk factors for central venous port failure in cancer patients. *World J Gastroenterol* 2009;15:4709-14.
- van Rooden CJ, Schippers EF, Barge RM, et al. Infectious complications of central venous catheters increase the risk of catheter-related thrombosis in hematology patients: a prospective study. *J Clin Oncol* 2005;23:2655-60.
- Gallieni M, Pittiruti M, Biffi R. Vascular access in oncology patients. *CA Cancer J Clin* 2008;58:323-46.
- Sajid MS, Ahmed N, Desai M, Baker D, Hamilton G. Upper limb deep vein thrombosis: a literature review to streamline the protocol for management. *Acta Haematol* 2007;118:10-8.
- Aziz S, Straehley CJ, Whelan TJ Jr. Effort-related axillosubclavian vein thrombosis: a new theory of pathogenesis and a plea for direct surgical intervention. *Am J Surg* 1986;152:57-61.
- Illig KA, Doyle AJ. A comprehensive review of Paget-Schroetter syndrome. *J Vasc Surg* 2010;51:1538-47.
- Owens CA, Bui JT, Knutinen MG, Gaba RC, Carrillo TC. Pulmonary embolism from upper extremity deep vein thrombosis and the role of superior vena cava filters: a review of the literature. *J Vasc Interv Radiol* 2010;21:779-87.
- Kucher N, Tapson VF, Goldhaber SZ. Risk factors associated with symptomatic pulmonary embolism in a large cohort of deep vein thrombosis patients. *Thromb Haemost* 2005;93:494-8.
- Stein PD, Matta F, Musani MH, Diazczok B. Silent pulmonary embolism in patients with deep venous thrombosis: a systematic review. *Am J Med* 2010;123:426-31.
- Flinterman LE, van Hylckama Vlieg A, Rosendaal FR, Doggen CJ. Recurrent thrombosis and survival after a first venous thrombosis of the upper extremity. *Circulation* 2008;118:1366-72.
- Martinelli I, Battaglioli T, Bucciarelli P, Passamonti SM, Mannucci PM. Risk factors and recurrence rate of primary deep vein thrombosis of the upper extremities. *Circulation* 2004;110:566-70.
- Heit JA, Mohr DN, Silverstein MD, Petterson TM, O'Fallon WM, Melton LJ III. Predictors of recurrence after deep vein thrombosis and pulmonary embolism: a population-based cohort study. *Arch Intern Med* 2000;160:761-8.
- Elman EE, Kahn SR. The post-thrombotic syndrome after upper extremity deep venous thrombosis in adults: a systematic review. *Thromb Res* 2006;117:609-14.
- Schulman S, Lindmarker P, Holmstrom M, et al. Post-thrombotic syndrome, recurrence, and death 10 years after the first episode of venous thromboembolism treated with warfarin for 6 weeks or 6 months. *J Thromb Haemost* 2006;4:734-42.
- Verso M, Agnelli G. Venous thromboembolism associated with long-term use of central venous catheters in cancer patients. *J Clin Oncol* 2003;21:3665-75.
- Akl EA, Kamath G, Yosuico V, et al. Thromboprophylaxis for patients with cancer and central venous catheters: a systematic review and a meta-analysis. *Cancer* 2008;112:2483-92.
- van Rooden CJ, Molhoek SG, Rosendaal FR, Schali J, Meinders AE, Huisman MV. Incidence and risk factors of early venous thrombosis associated with permanent pacemaker leads. *J Cardiovasc Electrophysiol* 2004;15:1258-62.
- Constans J, Salmi LR, Sevestre-Pietri MA, et al. A clinical prediction score for upper extremity deep venous thrombosis. *Thromb Haemost* 2008;99:202-7.
- Merminod T, Pellicciotti S, Bounameaux H. Limited usefulness of D-dimer in suspected deep vein thrombosis of the upper extremities. *Blood Coagul Fibrinolysis* 2006;17:225-6.
- Di Nisio M, Van Sluis GL, Bossuyt PM, Buller HR, Porreca E, Rutjes AW. Accuracy of diagnostic tests for clinically suspected upper extremity deep vein thrombosis: a systematic review. *J Thromb Haemost* 2010;8:684-92.
- Kim H, Chung JW, Park JH, et al. Role of CT venography in the diagnosis and treatment of benign thoracic central venous obstruction. *Korean J Radiol* 2003;4:146-52.
- Baarslag HJ, Van Beek EJ, Reekers JA. Magnetic resonance venography in consecutive patients with suspected deep vein thrombosis of the upper extremity: initial experience. *Acta Radiol* 2004;45:38-43.
- Kovacs MJ, Kahn SR, Rodger M, et al. A pilot study of central venous catheter survival in cancer patients using low-molecular-weight heparin (dalteparin) and warfarin without catheter removal for the treatment of upper extremity deep vein thrombosis (The Catheter Study). *J Thromb Haemost* 2007;5:1650-3.
- van Dongen CJ, van den Belt AG, Prins MH, Lensing AW. Fixed dose subcutaneous low molecular weight heparins versus adjusted dose unfractionated heparin for venous thromboembolism. *Cochrane Database Syst Rev* 2004;4:CD001100.
- Karabay O, Yetkin U, Onol H. Upper extremity deep vein thrombosis: clinical and treatment characteristics. *J Int Med Res* 2004;32:429-35.
- Prandoni P, Bernardi E, Marchiori A, et al. The long term clinical course of acute deep vein thrombosis of the arm: prospective cohort study. *BMJ* 2004;329:484-5.
- Savage KJ, Wells PS, Schulz V, et al. Outpatient use of low molecular weight heparin (Dalteparin) for the treatment of deep vein thrombosis of the upper extremity. *Thromb Haemost* 1999;82:1008-10.
- Kearon C, Kahn SR, Agnelli G, Goldhaber S, Raskob GE, Comerota AJ. Antithrombotic therapy for venous thromboembolic disease: American College of Chest Physicians Evidence-Based Clinical Practice Guidelines (8th Edition). *Chest* 2008;133:Suppl:454S-545S. [Erratum, *Chest* 2008;134:892.]
- Hingorani A, Ascher E, Ward M, et al. Combined upper and lower extremity deep venous thrombosis. *Cardiovasc Surg* 2001;9:472-7.
- Mewissen MW, Seabrook GR, Meiss-



- ner MH, Cynamon J, Labropoulos N, Haughton SH. Catheter-directed thrombolysis for lower extremity deep venous thrombosis: report of a national multi-center registry. *Radiology* 1999;211:39-49. [Erratum, *Radiology* 1999;213:930.]
42. Elsharawy M, Elzayat E. Early results of thrombolysis vs anticoagulation in iliofemoral venous thrombosis: a randomised clinical trial. *Eur J Vasc Endovasc Surg* 2002;24:209-14.
43. Alesh I, Kayali F, Stein PD. Catheter-directed thrombolysis (intrathrombus injection) in treatment of deep venous thrombosis: a systematic review. *Catheter Cardiovasc Interv* 2007;70:143-8.
44. Vik A, Holme PA, Singh K, et al. Catheter-directed thrombolysis for treatment of deep venous thrombosis in the upper extremities. *Cardiovasc Interv Radiol* 2009;32:980-7.
45. Oderich GS, Treiman GS, Schneider P, Bhirangi K. Stent placement for treatment of central and peripheral venous obstruction: a long-term multi-institutional experience. *J Vasc Surg* 2000;32:760-9.
46. Meier GH, Pollak JS, Rosenblatt M, Dickey KW, Gusberg RJ. Initial experience with venous stents in exertional axillary-subclavian vein thrombosis. *J Vasc Surg* 1996;24:974-81, discussion 81-3.
47. Urschel HC Jr, Patel AN. Paget-Schroetter syndrome therapy: failure of intravenous stents. *Ann Thorac Surg* 2003;75:1693-6.
48. Lin PH, Zhou W, Dardik A, et al. Catheter-direct thrombolysis versus pharmacomechanical thrombectomy for treatment of symptomatic lower extremity deep venous thrombosis. *Am J Surg* 2006;192:782-8.
49. Plate G, Einarsson E, Ohlin P, Jensen R, Qvarfordt P, Eklöf B. Thrombectomy with temporary arteriovenous fistula: the treatment of choice in acute iliofemoral venous thrombosis. *J Vasc Surg* 1984;1:867-76.
50. Lee JT, Karwowski JK, Harris EJ, Haukoos JS, Olcott C IV. Long-term thrombotic recurrence after nonoperative management of Paget-Schroetter syndrome. *J Vasc Surg* 2006;43:1236-43.
51. Urschel HC Jr, Razzuk MA. Neurovascular compression in the thoracic outlet: changing management over 50 years. *Ann Surg* 1998;228:609-17.
52. Schneider DB, Dimuzio PJ, Martin ND, et al. Combination treatment of venous thoracic outlet syndrome: open surgical decompression and intraoperative angioplasty. *J Vasc Surg* 2004;40:599-603.
53. Machleder HI. Evaluation of a new treatment strategy for Paget-Schroetter syndrome: spontaneous thrombosis of the axillary-subclavian vein. *J Vasc Surg* 1993;17:305-15.
54. Lee WA, Hill BB, Harris EJ Jr, Semba CP, Olcott CI. Surgical intervention is not required for all patients with subclavian vein thrombosis. *J Vasc Surg* 2000;32:57-67.

Copyright © 2011 Massachusetts Medical Society.

#### MY NEJM IN THE JOURNAL ONLINE

Individual subscribers can store articles and searches using a feature on the *Journal's* Web site (**NEJM.org**) called "My NEJM."

Each article and search result links to this feature. Users can create personal folders and move articles into them for convenient retrieval later.