

Arterial Cannulation During Central Line Placement: Mechanisms of Injury, Prevention, and Treatment

T. Andrew Bowdle MD, PhD

Professor of Anesthesiology and Pharmaceutics

Chief of the Division of Cardiothoracic Anesthesiology

Department of Anesthesiology

University of Washington

Contents

INTRODUCTION	3
CENTRAL LINE COMPLICATIONS: TRENDS	3
AMERICAN SOCIETY OF ANESTHESIOLOGISTS CLOSED CLAIMS PROJECT DATABASE	3
ARTERIAL CANNULATION.....	4
INCIDENCE.....	4
PREVENTION.....	4
<i>Ultrasound Guidance</i>	<i>5</i>
<i>Pressure Monitoring</i>	<i>7</i>
<i>Challenges with Current Techniques: A Case Study.....</i>	<i>11</i>
<i>A Novel Digital Pressure Transducer With Integrated Display.....</i>	<i>13</i>
MANAGEMENT	13
PRACTICE GUIDELINES	16

Introduction

Approximately six million central venous catheters are inserted every year in the US^{1,2}. Central lines have long been regarded as dangerous by practitioners, manufacturers of central lines, and the Food and Drug Administration (FDA). Complications from central lines have been reviewed³⁻⁶. Hall and Russell have authored an editorial that provides a concise description of safe practices for placing central lines⁷.

Central Line Complications: Trends

American Society of Anesthesiologists Closed Claims Project Database

The American Society of Anesthesiologists Closed Claims Project database is a standardized collection of case summaries of adverse anesthesia-related outcomes derived from closed liability claims collected from 35 insurance organizations. While it is impossible to know the true incidence of the adverse events that appear in the Closed Claims Project database (there is no “denominator” for the database), this relatively large set of cases may reveal patterns of events that contribute to patient injury and subsequent legal action, that would not be possible to discern by looking at individual cases.

A review of the Closed Claims Project database confirmed the hazards previously associated with central lines⁸. Among the 6449 claims reported through December 2002, there were 110 claims for injuries related to central lines (1.7%). Claims related to central lines had a high severity of patient injury with an increased proportion of death (47%) compared to other claims in the database (29%, $P<0.01$).

The main results of the review are shown in Table 1. Inspection of this table reveals that the most important injuries both in terms of numbers and death rate were cardiac tamponade and injuries to major arteries and veins (combining “carotid artery puncture/cannulation”, “hemothorax” and “miscellaneous other vessel injury”), representing 15/110 and 35/110 cases respectively, not including pulmonary artery injuries.

Type of complication	number	Death n (%)
Wire/catheter embolus	20	1 (5) [†]
Cardiac tamponade	15	12 (80) [†]
Carotid artery injury	14	5 (36)
Hemothorax	14	12 (92) [†]
Pneumothorax	12	2 (15) [†]
Miscellaneous vessel injury	7	2 (29)
Pulmonary artery rupture	6	6 (100)
Hydrothorax	5	2 (40)
Air embolism	4	3 (75)
Fluid extravasation in neck	4	2 (50)
Cardiac arrhythmia	1	0(0)

Table 1: Central line-related injuries from the ASA Closed Claims Project database

[†] $p<0.05$ compared with other complications

This impression is reinforced when the injuries reported after 1990 are compared to those reported before 1990 (Figure 1).

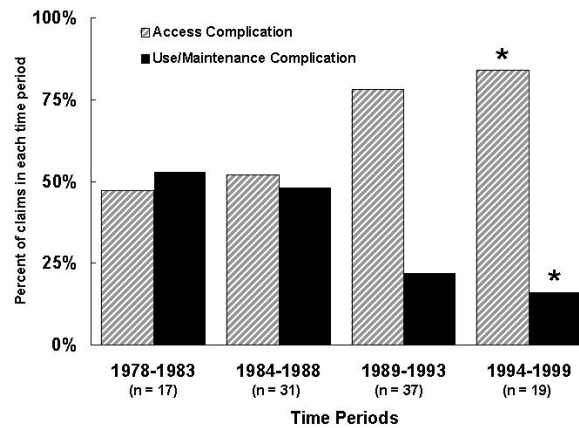


Figure 1: Central line-related claims or injuries from the ASA Closed Claims Project database. A greater proportion of claims from 1989 to 1999 involved complications related to access (i.e. mostly vascular injuries).
 * $P < 0.05$ 1994-1999 compared to other periods.

Since 1990, the vast majority of injuries have been accounted for by vascular injuries. Given this trend, the focus of this review will therefore be the mechanisms of injury, prevention, and treatment of inadvertent arterial cannulation, perhaps the most significant vascular injury in terms of frequency and severity⁹.

Arterial Cannulation

Incidence

Several studies have reported the incidence of arterial cannulation to be between 0.1-1.0%¹⁰⁻¹². Table 2 summarizes this primary data, and adds more recent data from Pikwer et al¹³.

Author	Year	Catheterizations	Arterial Cannulations		Estimated Annual Errors in US
			n	%	
Schwartz ¹⁴	1979	1,021	5	0.5%	29,400
Shah ¹⁵	1984	5,924	4	0.07%	4,200
Kron ¹⁶	1985	903	7	0.8%	46,800
Golden ¹⁷	1995	4,022	4	0.1%	6,000
Wicky ¹⁸	2002	3,300	11	0.3%	19,800
Pikwer ¹³	2009	1,079	11	1.0%	60,000

Table 2: Incidence of arterial cannulation and estimated annual errors based on six (6) million procedures in the US^{1,2}

Prevention

The most common injury to arteries is related to puncture or cannulation of the carotid artery. Puncturing the carotid artery with a small needle occurs in about 6% of all procedures and, although undesirable, does not generally produce any harm⁹. However if the arterial puncture is not recognized and a guidewire is placed into the artery and followed with a CVC or a pulmonary artery catheter introducer sheath there is the possibility of

a major problem. Ultrasound and pressure waveform measurement are two commonly used methods to reduce the chances of injury to the carotid artery.

ULTRASOUND GUIDANCE

The availability of relatively inexpensive, portable ultrasound equipment led to the application of 2D ultrasound imaging to guide central line placement. Ultrasound imaging allows the presence of the internal jugular vein (IJ) to be confirmed, its patency can be demonstrated, and its anatomical relationship to the carotid artery can be defined. Real-time (or dynamic) ultrasound can guide needle placement into the vein and confirm the presence of a wire in the vein. Troianos et al. first reported the use of ultrasound guided central vascular access in the anesthesia literature in 1991¹⁹. Their prospective, randomized study of ultrasound guidance versus the traditional landmark method found a higher overall success rate, a higher success rate on the first attempt, and a reduced rate of arterial puncture with ultrasound guidance. Numerous studies of ultrasound guidance and major meta-analyses have appeared subsequently. The meta-analyses of ultrasound guidance concluded that ultrasound guidance was superior to landmarks for overall success rate, a higher success rate on the first attempt, and reduced complications from arterial puncture for the internal jugular vein approach^{20,21}. The advantage of ultrasound guidance for the subclavian approach was less clear; a study of 821 patients compared ultrasound guidance to standard insertion procedures for cannulation of the subclavian vein, and concluded that ultrasound had no effect on the rate of complications²². A review commissioned by the Agency for Healthcare Research and Quality (AHRQ) strongly advocated the use of ultrasound guidance during central line placement⁵. In the United Kingdom, the National Institute of Clinical Excellence (NICE) recommend routine use of ultrasound for central venous catheterization²³.

Given the abundance of data in favor of the use of ultrasound guidance, it is not unreasonable to consider the use of ultrasound guidance to be the “preferred method of insertion²⁴.” However, a recent survey of the Society of Cardiovascular Anesthesiologists members revealed that only 15% always or almost always use ultrasound²⁵. Interestingly, most of those surveyed had experienced vascular complications during central venous catheterization, including carotid puncture (75%), carotid injury (3%), stroke (1%), and hemothorax (4%). A shortage of suitable ultrasound equipment is sometimes a reason for not using ultrasound guidance. A study in the UK found that 86% of anesthetic departments had ultrasound equipment for central line placement²⁶, however Bailey et al. found that 33% of anesthesiologists in their survey of members of the Society of Cardiovascular Anesthesiologists never or almost never had ultrasound equipment available²⁵.

An important caveat for the use of ultrasound guidance, and particularly relevant to a discussion of arterial cannulation, is that the **needle and/or wire may not always be visualized** in the vein, depending upon the type of ultrasound equipment used and the skill of the operator. Although it may be possible to visualize the tip of the needle with ultrasound²⁷, because of the **tomographic nature** of an ultrasound beam, it may be **difficult to distinguish the shaft** of the needle from the **tip**. **Confusion** between the **tip** and the **shaft** of the needle in the ultrasound image can lead to **inadvertent arterial cannulation** when the needle passes through the intended vein and into the underlying artery, but is **not recognized**, as illustrated in the cases below.

A recent series reported by Blaivas²⁸ presented **six inadvertent arterial cannulations** during dynamic ultrasound. The author presented the data, in part, because, “few reports of accidental arterial cannulation are present in the literature, and **the casual reviewer may assume that serious complications no longer arise when ultrasound is used.**” The physicians who either personally placed or supervised

residents placing the CVC in each of the six cases were **credentialed** by their hospital in emergency ultrasound based on American College of Emergency Physicians **ultrasound criteria**. All residents received a 2-day introductory ultrasound course, which included 3 hours of didactic and hands-on education in ultrasound-guided vascular access. Table 3 summarizes each of the six cases, including as analysis of the error based on a video review of the ultrasound-guided arterial cannulation.

Age	Mechanism of injury	Outcome
67	Needle went through IJ into Carotid artery	Patient Died
75	Needle went though femoral vein into femoral artery	Vascular surgery for AV fistula
48	Needle went though IJ and entered carotid artery sitting underneath the IJ	Surgery for tear and focal dissection of carotid artery
67	Guidewire traveled through IJ and its posterior wall and into carotid artery	Hematoma with respiratory distress requiring emergent intubation.
69	Needle penetrated the carotid artery which was very close to the IJ	Emergency carotid artery repair; Patient died of complications
14	Needle penetrated rear wall of IJ and entered carotid artery	Central line removed and bleeding eventually stopped

Table 3: Analysis of six accidental arterial cannulations with dynamic ultrasound guidance

The mechanism of injury in 5 of the 6 cases involved passage of the needle **through** the vein, out its posterior wall, and into the artery. This highlights the importance of confirming the location of the tip of the needle prior to inserting the guidewire. The author concluded, “**In summary, the short-axis approach, as seen in this series, can provide a false sense of security** to the practitioner and allows for potentially dangerous accidental arterial cannulation...it may be prudent to not only visualize the entire path of the needle with the long-axis approach but also **confirm correct cannulation by tracing the guidewire in the long axis before line placement.**” However, it is important to realize that even with multiple ultrasound views of needles or wires, **misdiagnosis remains a possibility**. For example, as noted in the case below (see Figure 6), it is possible for a needle and wire to pass through the internal jugular vein and into the subclavian artery, which may **not be possible to visualize with ultrasound** because of interference from the clavicle.

Parsons and Alfa reported a case of inadvertent arterial cannulation **despite the use of ultrasound guidance** in a 34-year old with chronic renal failure undergoing renal transplantation²⁹. The arterial cannulation was eventually discovered by transducing the pressure in the lumen of a 7 Fr catheter. The authors proposed that the introducer needle was correctly placed in the internal jugular vein under ultrasound guidance, but later shifted during guidewire insertion, at which point ultrasound had been discontinued (Figure 2). The authors noted, “Movement may still occur with migration of the needle outside the vein during the Seldinger technique, resulting in wire malposition. We suggest that re-imaging the vein and confirming the presence of the guidewire in the internal jugular vein prior to dilation might prevent catheter placement into the carotid artery. We should be aware that US techniques do not remove all risks associated with CVC insertion.” **Other case reports of arterial cannulation during attempted cannulation of the internal jugular vein under ultrasound guidance have described similar errors** (passage of the introducer needle though a vein and into the underlying artery) and reached similar conclusions (confirm that the needle tip and/or guidewire are in a vein prior to placing the catheter)^{30,31}.

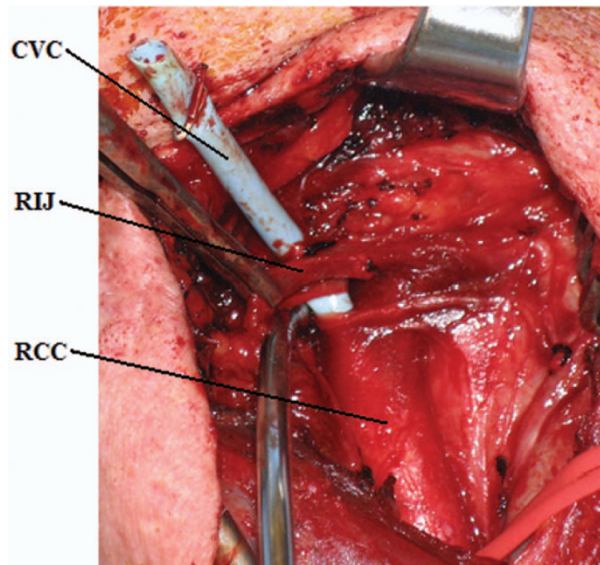


Figure 2: Open surgical repair following arterial cannulation reveals a central venous catheter traversing through the right internal jugular vein into the right common carotid artery.

From Parsons, A.J. and J. Alfa, Carotid dissection: a complication of internal jugular vein cannulation with the use of ultrasound. *Anesth Analg*, 2009. 109(1): p. 135-6.

While ultrasound has clearly reduced overall errors associated with central line insertion, its use has not eliminated the risk of arterial cannulation, especially when the insertion site is the subclavian vein. Moreover, the adoption of ultrasound has been somewhat limited, despite the existence of multiple guidelines recommending its routine use. Consequently, many physicians additionally perform pressure monitoring (with or without ultrasound) to avoid arterial cannulation.

PRESSURE MONITORING

Over 25 years ago Jobes et al. performed a retrospective study of 1,021 attempts at internal jugular venous access in which there were 43 arterial punctures³². Five of the 43 arterial punctures were unrecognized resulting in the placement of 8 Fr introducer sheaths into an artery (0.5% arterial cannulation rate), resulting in one fatality from hemothorax. Subsequently these investigators performed a prospective trial of 1,284 attempts at internal jugular venous access in which they measured a pressure waveform from the vessel before inserting the guidewire. Prior to measuring the pressure waveform a clinical assessment was made as to whether the needle was in an artery or vein, based on the usual criteria of color and pulsatility. There were 51 arterial punctures, 10 of which were incorrectly identified as being venous based on color and pulsatility, but were determined to be arterial from the pressure waveform. Thus, 10 inadvertent arterial cannulations (representing a 0.78% error rate) were avoided by pressure waveform monitoring.

In 1997 Oliver et al. reported the results of placing 1,172 central venous catheters into the internal jugular, subclavian, or femoral veins using pressure transduction through the introducer needle to confirm venous access prior to guidewire insertion³³. The incidence of arterial puncture was 9.3% (defined as entry of the introducer needle into an artery) but pressure transduction correctly identified all the arterial punctures and there were no cases of inadvertent arterial cannulation.

In 2009 Ezaru et al. published a retrospective analysis of 9,348 central venous catheter placements over a 15 year period in a single institution requiring mandatory use of tube manometry to verify venous access (Figure 3)¹⁰. There were no cases of arterial cannulation. During the final year of the study 511 catheters were placed. Arterial puncture (defined as placement of an 18 gauge introducer needle or catheter into an artery) occurred in 28 patients (5%). Arterial puncture was correctly recognized from color and pulsatility in 24 cases, without manometry, but in 4 cases (0.8%), the arterial placement was only recognized with manometry.

Both Jobes et al. and Ezaru et al. recorded the incidence of failure to correctly identify arterial puncture using the criteria of color and pulsatility alone; however the artery was successfully identified by measuring the pressure in all cases. The incidence of arterial cannulation prevented by pressure measurement can be calculated from this data (see Table 4 below). The rate of arterial cannulation prevented by pressure measurement (0.8%) is in good agreement with arterial cannulation frequencies reported by others (0.1-1.0% -- see Table 2 above).

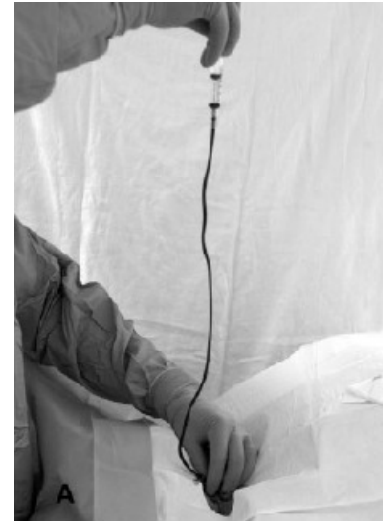

Figure 3: Tube manometer used in the Ezaru et al. study demonstrating that pressure measurement can prevent arterial cannulation¹⁰

Author	Year	Catheterizations	Arterial Cannulations		Arterial Cannulations prevented by pressure measurement		Estimated annual errors prevented by pressure measurement
			n	%	n	%	
Jobes ³²	1983	1,284	0	0%	10	0.8%	48,000
Ezaru ¹⁰	2009	511	0	0%	4	0.8%	48,000

Table 4: Arterial cannulation prevented by pressure measurement (color and pulsatility failed to identify the artery, and only pressure measurement correctly identified arterial puncture)

This evidence has been noted by catheter manufacturers, whose central line kit package inserts suggest confirming venous access by pressure waveform monitoring to avoid inadvertent arterial cannulation(Figure 4).

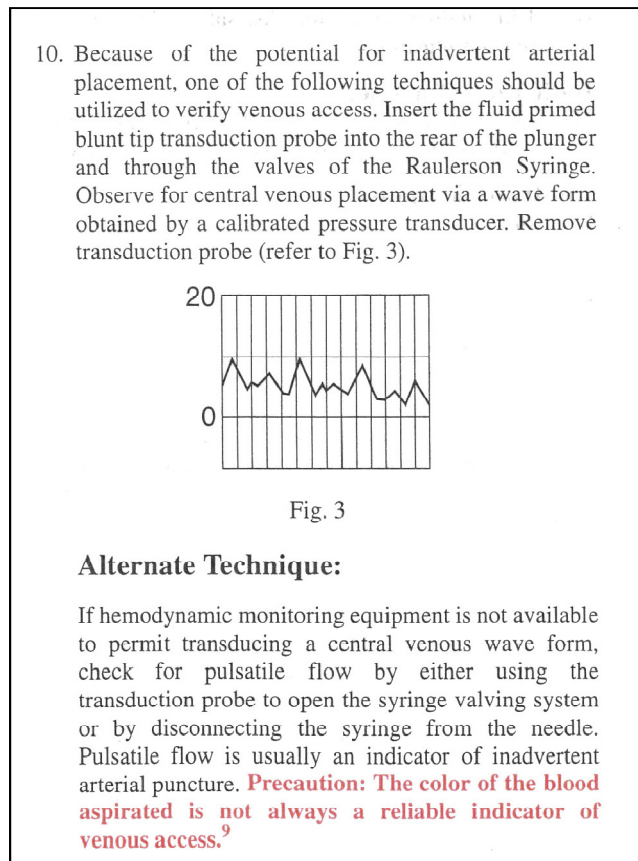


Figure 4: A catheter manufacturer's instructions for use that suggest pressure transduction to prevent inadvertent arterial cannulation

The three articles summarized above (Jobes, Oliver, and Ezaru) present data in 11,804 patients and they indicate that measuring the pressure can prevent inadvertent arterial cannulation. Importantly, both Ezaru et al. and Jobes et al. note that without pressure monitoring, **reliance upon the blood color and pulsatility alone would have resulted in an arterial cannulation rate of 0.8%.**

Domino et al. examined central line complications from the ASA Closed Claims Project database in an attempt to determine whether the use of pressure waveform monitoring or ultrasound guidance would have prevented the complications (see Table 5). This is clearly inferential, nevertheless it is interesting that nearly half (48/110) of the complications were judged to be possibly preventable by the use of either pressure waveform monitoring or ultrasound guidance, or only by ultrasound guidance, or only by pressure waveform monitoring, or by chest x ray⁸.

Possibly preventable by either ultrasound guidance or pressure waveform monitoring (n=19)	
↓	
Carotid artery puncture/cannulation	16
Hemothorax	1
Wire/catheter embolus	1
Miscellaneous other vessel injury	1
Possibly preventable by pressure waveform monitoring only (n=6)	
↓	
Miscellaneous other artery injury	5
Hemothorax	1
Possibly preventable by ultrasound guidance only (n=9)	
↓	
Hemothorax	4
Pneumothorax	4
Miscellaneous other vessel injury	1
Possibly preventable by chest radiograph (n=14)	
↓	
<i>No chest radiograph taken</i>	
Carotid tamponade	2
Wire/catheter embolus	1
Pneumothorax	4
<i>Misread, not read or inappropriate action taken</i>	
Cardiac tamponade	4
Wire/catheter embolus	3

Table 5: Potential effect of ultrasound guidance or pressure waveform monitoring on central line-related injuries from the ASA Closed Claims Project database

Unfortunately, the pressure measurement techniques described previously have not been widely adopted. In part this may be due to a **lack of awareness of the problem**, and perhaps because of a **perception that ultrasound has eliminated the risk**. However, as discussed previously, **inadvertent arterial cannulation** has **not been completely eliminated by ultrasound**. Another possible explanation for the poor adoption rate of pressure monitoring is that the technique is viewed as cumbersome by some. For example, an editorial article stated the following regarding tube-based manometry, "In manipulating the 18-gauge cannula to affix the extension tubing and then aspirating or manipulating the cannula tubing to obtain a sufficient column of blood, one could envision many other mishaps: air embolization, dislodgement of the cannula, infection and violation of the sterile field are very real possibilities³⁴."

A convenient alternative to tube-based manometry is the setup shown in **Figure 5**³⁵. This setup is most suited to settings (e.g. operating rooms) where pressure transduction equipment, monitors, and non-sterile assistants to handle the pressure tubing are readily available. Additionally, it has the advantage of giving the pressure waveform without the need to disconnect the syringe and connect monitoring tubing to the needle (as in manometry), with the risk of dislodging the needle from the vein. There are no data

comparing these alternative methods of pressure measurement; however the manometry technique requires an additional step to connect the manometry tubing.

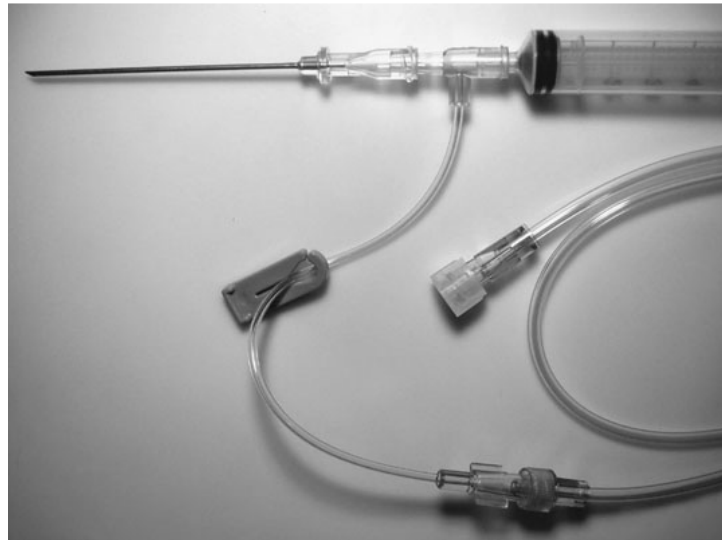


Figure 5: This setup is used by the author for obtaining a pressure waveform during central line placement in the operating room. The T-shaped adapter and a length of pressure tubing are added to a standard central line kit, and the device is assembled as shown using the needle and syringe found in the kit. The pressure tubing is handed off to the assistant who connects it to a transducer and flushes the system. When blood is aspirated into the syringe indicating entry into the blood vessel, inspection of the waveform on the monitor immediately allows differentiation between artery and vein. Once the presence of a venous waveform is confirmed, the syringe or T-adapter is removed and the wire is inserted

Although most discussions of inadvertent arterial cannulation focus on the carotid artery, it is worth briefly mentioning some of the advantages of pressure measurement for avoiding inadvertent cannulation of the subclavian artery during attempted cannulation of the internal jugular vein. Kulvatunyou reviewed a collection of cases of injury to the right subclavian artery during attempted right internal jugular cannulation³⁶. The right subclavian artery is in close proximity when the right internal jugular vein is approached low in the neck. Due to interference from the clavicle, puncture of the subclavian artery may not be seen with ultrasound, but will be detected by pressure waveform monitoring. The author has seen several instances of presumed subclavian artery puncture during attempted internal jugular vein cannulation low in the neck, in which ultrasound guidance was used, and the needle shaft was visualized in the vein but arterial puncture was detected with pressure waveform monitoring. An example of inadvertent cannulation of the subclavian artery is illustrated below (Figure 6).

CHALLENGES WITH CURRENT TECHNIQUES: A CASE STUDY

While the use of ultrasound guidance and pressure waveform monitoring, used individually or in conjunction, are likely to significantly reduce the likelihood of inadvertent arterial cannulation, under rare circumstances these methods may fail to prevent arterial cannulation. For example the needle can be inadvertently moved following confirmation of venous puncture by ultrasound or pressure waveform, and subsequently enter an artery, which may result in cannulation of the artery. This mechanism of injury may be missed despite the use of either ultrasound or pressure waveform monitoring. A case serves to illustrate this point. During an ultrasound guided internal jugular vein catheterization using a low

approach in the neck, a venous pressure waveform was transduced through the introducer needle. The transducer was disconnected and a guidewire inserted. Ultrasound was then used to verify venous placement of the guidewire, which was visualized in the internal jugular vein to the level of the clavicle. After inserting the catheter, it was discovered that the catheter had been inserted into an artery. Subsequent angiography (Figure 6) showed that the catheter had been placed into the internal jugular vein, but exited its posterior wall at the level of the clavicle, and subsequently entered the subclavian artery. Presumably the introducer needle migrated from the internal jugular vein to the subclavian artery after pressure transduction but before the guidewire was fully inserted. Ultrasound confirmation of the guidewire demonstrated a portion of the guidewire in the internal jugular vein, but due to the overlying clavicle, the end of the wire exiting the posterior vessel wall and entering the subclavian artery could not be visualized.

The problem illustrated in this case might have been avoided by puncturing the vessel with a small (i.e. 18 gauge) angiocatheter instead of a needle prior to measuring a pressure waveform, since the angiocatheter once inserted is less likely to be dislodged. Other methods of avoiding inadvertent arterial cannulation are also possible. These include the use of fluoroscopy and the use of transesophageal echocardiography to identify the wire in the right atrium. A novel pressure monitoring device capable of continuous pressure monitoring during guidewire insertion could also have prevented this type of injury. A brief discussion of this device is presented in the next section.

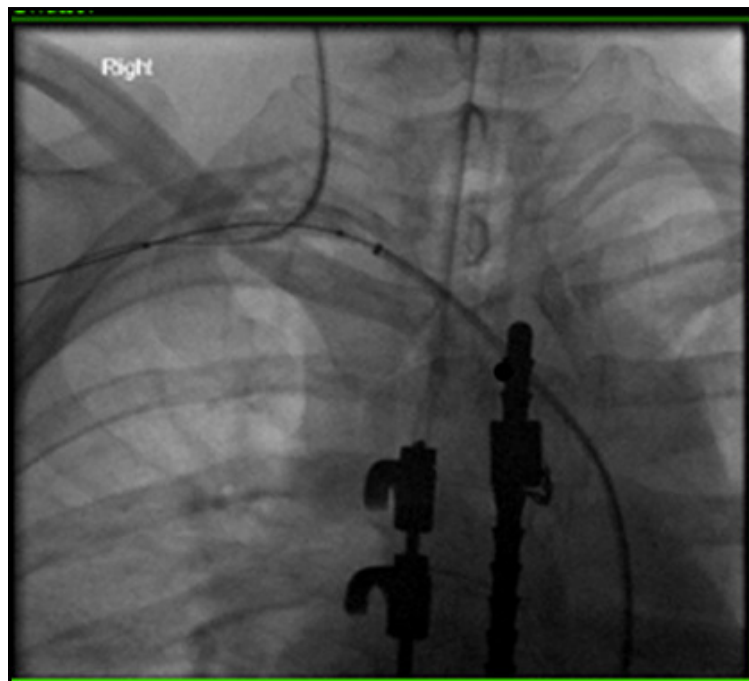


Figure 6: Inadvertent subclavian artery cannulation. The catheter from above is a double lumen CVP catheter in the SC artery. The catheter from below is the interventional catheter inserted via the femoral artery--a balloon from the interventional catheter was inflated and the CVP catheter removed, using the balloon to temporarily occlude the SC artery puncture site.

A NOVEL DIGITAL PRESSURE TRANSDUCER WITH INTEGRATED DISPLAY

The review of the literature concerning the use of ultrasound and pressure waveform measurement during CVC placement has revealed several important points:

- To minimize the risk of arterial cannulation, it is critical to confirm venous placement of the guidewire (visualizing only the introducer needle can lead to errors).
- The use of the traditional Seldinger technique in which a wire is placed through a bare needle can result in inadvertent arterial cannulation if the needle is moved into the artery after a pressure waveform is measured.
- The use of ultrasound and pressure transduction has not been widely adopted, despite evidence that their use can prevent central line complications. In part, this can be explained by operator difficulty with executing the techniques and/or the lack of readily available tools.

These considerations led to the development of “Compass Vascular Access” device (Figure 7). This single-use device is provided sterile and connects to standard needles and syringes, allowing measurement of intravascular pressure during central line placement without adding additional steps to the procedure. The compact, self-contained design may overcome some of the technical challenges that have limited adoption of other pressure measuring techniques. Importantly, the device allows for continuous pressure measurement during guidewire insertion, helping to confirm that the wire is being inserted into a vein rather than an artery.

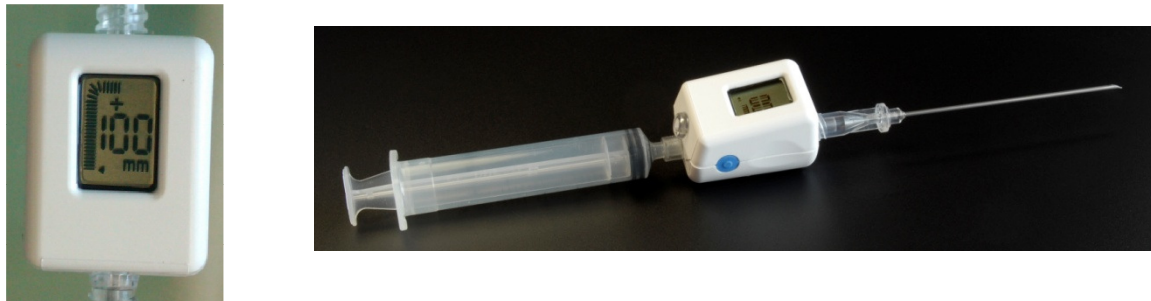

Figure 7: The “Compass™ Vascular Access” Device manufactured by Mirador Biomedical, Inc. This single-use device measures the intravascular pressure, which is displayed digitally and also as an analog representation of the pressure waveform. A guidewire may be passed through a separate valved port allowing continuous pressure measurement during the placement of the wire.

Management

While prevention of inadvertent arterial cannulation with large bore central venous catheters is paramount, an approach to treating inadvertent arterial cannulation may be needed in rare circumstances. There have been no guidelines in the literature for the treatment of accidental cannulation of arteries with large-bore catheters, but two recently published case series document better outcomes with surgical or endovascular intervention when compared with removal and compression (“pull/pressure”)^{9,37}. Guilbert et al. recently published a proposed algorithm for dealing with inadvertent arterial cannulation based on a review of cases from their own institutions (summarized in Table 6 below) and a more extensive review of the literature³⁷.

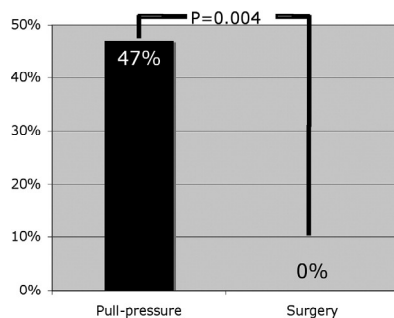
Management	Complications
Catheter removal and compression	Patient had massive stroke and died
Catheter removal and compression	Arteriovenous fistula requiring surgical repair
Catheter removal and compression	Left hemothorax requiring blood transfusion
Catheter removal and compression	Pleural effusion, lung collapse, thoracic surgery to repair arterial hole and lung decortication
Catheter removal and compression	Hematoma and uncontrolled bleeding requiring open surgery to repair jugular vein and carotid artery
Open surgical repair	No complications
Open surgical repair	No complications
Open surgical repair	No complications
Open surgical repair	No complications
Open surgical repair	No complications
Open surgical repair	No complications
Endovascular repair	No complications
Endovascular repair	No complications

Table 6: Summary of management and subsequent outcome in 13 cases of arterial cannulation

From Guilbert M-C, Elkouri S, Bracco D et al.:Arterial trauma during central venous catheter insertion: Case series, review and proposed algorithm. J Vasc Surg 48:918-985, 2008

During their literature review, the group found that the “pull/pressure” method was associated with a large incidence of serious complications (47%), including death, while the surgical or endovascular approach was not (Figure 8A) Based on their own experience and this review of the literature, they proposed the management algorithm in Figure 8B.

A



B

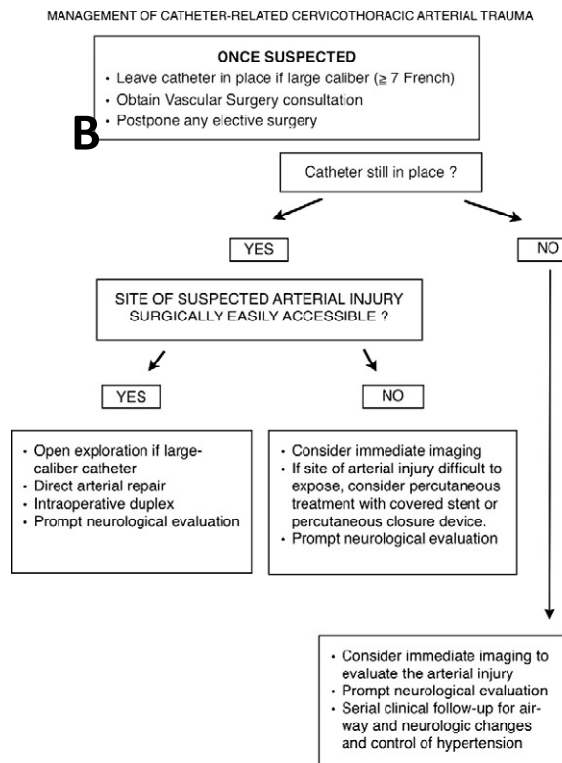


Figure 8(A): Complications from the “pull/pressure” technique of removing a large bore cannula in an artery were significantly higher than surgical removal with direct repair of the artery or endovascular repair. (B): A proposed algorithm for management of inadvertent cannulation of a cervical or thoracic artery with a large bore catheter during attempted central venous catheter placement.

From Guilbert M-C, Elkouri S, Bracco D et al.:Arterial trauma during central venous catheter insertion: Case series, review and proposed algorithm. J Vasc Surg 48:918-985, 2008.

Interestingly, a survey of vascular surgeons presented with a hypothetical case of an 8.5Fr catheter in a carotid artery, found that the respondents saw this complication 1-5 times per year and half would simply pull the catheter and apply pressure. However, when vascular surgeons were shown the data from the study by Guilbert et al., most of them changed their management to the surgical or endovascular approach as judged by pre- and post-test questions (Figure 9).

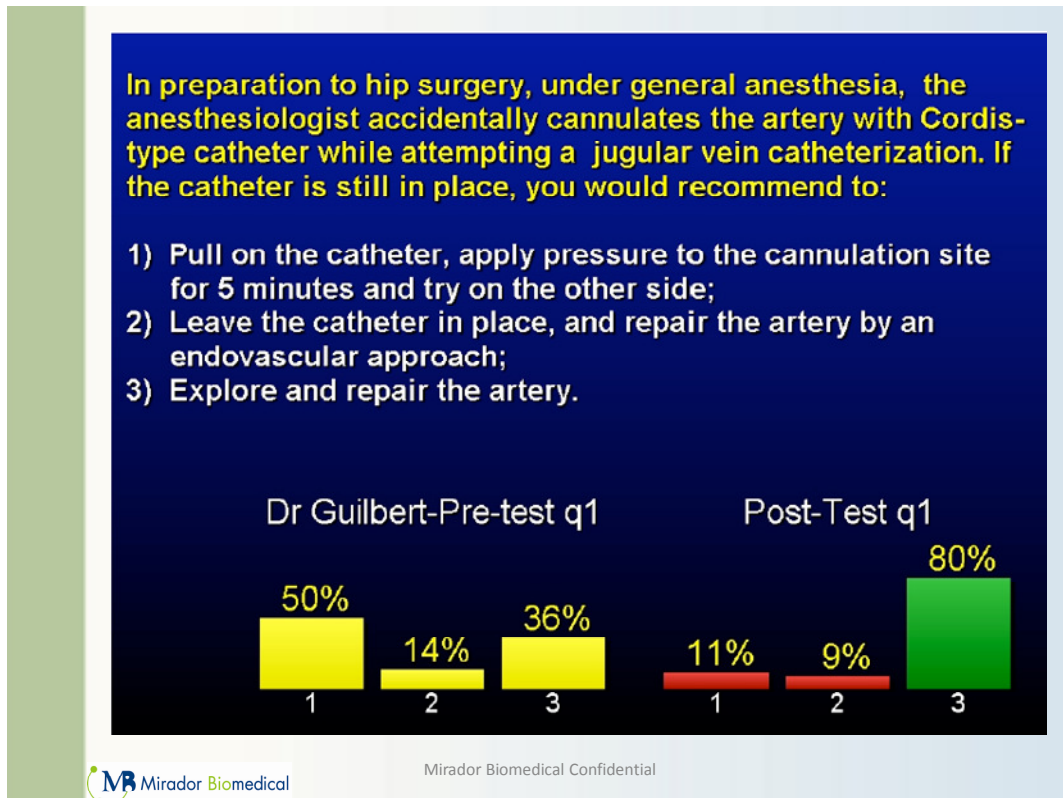


Figure 9: A question posed to vascular surgeons and answered before (pre-test) and again after (post-test) a presentation of the arterial cannulation complications from the Guilbert study

Appendix from Guilbert M-C, Elkouri S, Bracco D et al.: Arterial trauma during central venous catheter insertion: Case series, review and proposed algorithm. J Vasc Surg 48:918-985, 2008 (Appendix available online).

Several of the specific findings of the Guilbert et al. study are worth noting:

1. Arterial cannulation can occur despite the use of ultrasound guidance.
2. The low internal jugular approach can injure the subclavian or innominate arteries or even the aorta. Arterial injury below the sternoclavicular joint cannot be repaired through a cervical approach. Clinical suspicion of an intrathoracic injury should prompt imaging to locate the site of injury and plan surgical or endovascular treatment (see Figure 6 for an example of endovascular treatment).
3. Prolonged arterial cannulation can result in thrombus formation and stroke.
4. A normal carotid duplex exam following removal of a catheter from the carotid does not rule out the possibility of a stroke. Because of this, postponing elective surgery has been recommended to avoid unrecognized stroke in an anesthetized patient.
5. False aneurysms or arteriovenous fistulas can occur late following the pull/pressure technique, so close follow-up is needed.

Practice Guidelines

While ultrasound has long been recommended for central line procedures^{19,21,23,29,38,39}, it is only recently that institutions and professional organizations have begun to appreciate the importance of including pressure measurement during the placement of central venous catheters. For example:

- Many hospitals have added mandatory pressure measurement for all central line procedures (e.g. see hospital checklist in Figure 10).
- The Institute for Healthcare Improvement (www.ihl.org) has provided to members a central line checklist that includes pressure measurement as part of the standard central line insertion protocol⁴⁰.
- In June 2010, the American Society of Anesthesiologists published draft central line insertion recommendations that include pressure transduction as one method to confirm venous access of the introducer needle and the catheter⁴¹, based in part on evidence provided in the paper by Ezaru et al.¹⁰ showing that pressure measurement can prevent inadvertent arterial cannulation.

The Agency for Healthcare Research and Quality (AHRQ) is an agency of the Public Health Service of the federal Department of Health and Human Services. The mission of the AHRQ is “to support research designed to improve the quality, safety, efficiency, and effectiveness of health care for all Americans.” In 2001 AHRQ published a document entitled, “Making Health Care Safer: A Critical Analysis of Patient Safety Practices”, an evidence-based review of practices intended to improve patient safety⁴². There were 11 practices that were most highly rated of 79 practices that were reviewed in detail based on the strength of evidence supporting their widespread implementation. These included 3 practices related to the management of central venous lines:

1. Use of maximum sterile barriers while placing central intravenous catheters to prevent infections.
2. Use of real-time ultrasound guidance during central line insertion to prevent complications.
3. Use of antibiotic-impregnated central venous catheters to prevent catheter-related infections.

In May 2009, the AHRQ added a Central Line Insertion Checklist from Johns Hopkins University to its website⁴³. The checklist includes mandatory pressure transduction in all procedures not done under fluoroscopic guidance:

“During the procedure, did the operator transduce CVP or estimate CVP by fluid column (to avoid arterial placement)?”

Given recent reports demonstrating that measuring the pressure can prevent arterial cannulation¹⁰, and the increasing use of central line checklists that include pressure measurement, perhaps it is time to include pressure measurement as a recommended practice during every central line insertion.

ICU Safe Care – Eliminating Central Line Infections Toolkit

Central Line Insertion Checklist (Virginia Mason Medical Center)

Central Line Insertion Standard Work and Safety Checklist

Date: ____/____/____ Start time: _____

Location: _____

Catheter Type: ☐ Dialysis ☐ Central Venous ☐ PICC ☐ Pulmonary Artery

Number of Lumens: ☐ 1 ☐ 2 ☐ 3 ☐ 4

Insertion Site: Jugular: ☐ R ☐ L Upper Arm: ☐ R ☐ L

Subclavian: ☐ R ☐ L Femoral: ☐ R ☐ L

Reason for Insertion: ☐ New Indication ☐ Elective ☐ Emergent ☐ Replace Malfunctioning

Catheter

Procedure Provider: _____ Procedure Assistant: _____

☐ Attending MD ☐ Housestaff ☐ IV Therapist ☐ IV Therapist ☐ RN

Standard Work Before, During, and After Procedure		YES Or True	YES (After Reminder)	NA
P R O C E D U R E	> Patient has NO allergy to Heparin	<input type="checkbox"/>		
	> Patient's latex allergy assessed & procedure plan modified PRN	<input type="checkbox"/>		
	> Consent form completed & in chart (exception Code 4)	<input type="checkbox"/>		
	> Perform Procedural Pause	<input type="checkbox"/>	<input type="checkbox"/>	
	Perform patient ID X 2	<input type="checkbox"/>	<input type="checkbox"/>	
	Announce the procedure to be performed	<input type="checkbox"/>	<input type="checkbox"/>	
P R E P	Mark / assess site	<input type="checkbox"/>	<input type="checkbox"/>	
	Position patient correctly for procedure	<input type="checkbox"/>	<input type="checkbox"/>	
	Assemble equipment/verify supplies (including ultrasound, unless insertion is subclavian)	<input type="checkbox"/>	<input type="checkbox"/>	
	Verify all medication & syringes are labeled	<input type="checkbox"/>	<input type="checkbox"/>	
	> Confirm that all persons in room cleanse hands? (ASK, if unsure)	<input type="checkbox"/>	<input type="checkbox"/>	
	> Central line cart utilized?	<input type="checkbox"/>	<input type="checkbox"/>	
D U R I N G	> Prep Procedure site	<input type="checkbox"/>	<input type="checkbox"/>	
	Chloraprep 10.5 ml applicator used	<input type="checkbox"/>	<input type="checkbox"/>	
	Dry: 30 second scrub + 30 second dry time OR	<input type="checkbox"/>	<input type="checkbox"/>	<input type="checkbox"/>
	Wet: 2 minute scrub + 1 minute dry time	<input type="checkbox"/>	<input type="checkbox"/>	<input type="checkbox"/>
	> Used large drape to cover patient?	<input type="checkbox"/>	<input type="checkbox"/>	
	> Transducer set-up for all jugular and subclavian line insertions	<input type="checkbox"/>	<input type="checkbox"/>	<input type="checkbox"/>
	> Wear sterile gloves, hat, mask with eyeshield, and sterile gown? (all must be worn)	<input type="checkbox"/>	<input type="checkbox"/>	
	Procedure provider	<input type="checkbox"/>	<input type="checkbox"/>	
	Procedure assistant	<input type="checkbox"/>	<input type="checkbox"/>	
	> Did patient and all other persons in the room wear a mask?	<input type="checkbox"/>	<input type="checkbox"/>	
	> Maintain sterile field?	<input type="checkbox"/>	<input type="checkbox"/>	
	> Was ultrasound guidance used for all jugular & femoral insertions?	<input type="checkbox"/>	<input type="checkbox"/>	<input type="checkbox"/>
> Venous placement confirmation via:	<input type="checkbox"/>	<input type="checkbox"/>	<input type="checkbox"/>	
pressure transducer w/ monitor OR	<input type="checkbox"/>	<input type="checkbox"/>	<input type="checkbox"/>	
manometry	<input type="checkbox"/>	<input type="checkbox"/>	<input type="checkbox"/>	
> Type of solution used to flush/dosage:				
> Catheter caps placed on lumens?	<input type="checkbox"/>	<input type="checkbox"/>		
> Catheter sutured in place?	<input type="checkbox"/>	<input type="checkbox"/>		
> Position confirmation	<input type="checkbox"/>	<input type="checkbox"/>	<input type="checkbox"/>	
Fluoroscopy OR	<input type="checkbox"/>	<input type="checkbox"/>	<input type="checkbox"/>	
Chest X-ray ordered	<input type="checkbox"/>	<input type="checkbox"/>	<input type="checkbox"/>	

Washington State Hospital Association - Patient Safety Program

Appendix L

<http://www.wsha.org/page.cfm?ID=0281>

Source: IHI How-to-Guide: Prevent Central Line Infections

Figure 10 : A central line checklist developed at Virginia Mason Medical Center in Seattle, WA. The checklist is also available through the Washington State Hospital Association (www.wsha.org) and the Institute for Healthcare Improvement (<http://www.ihl.org/IHI/Topics/CriticalCare/IntensiveCare/Tools/CentralLineInsertionChecklist.htm>)

1. Fletcher, S.J. & Bodenham, A.R. Safe placement of central venous catheters: where should the tip of the catheter lie? *Br J Anaesth* **85**, 188-91 (2000).
2. Collier, P.E., Blocker, S.H., Graff, D.M. & Doyle, P. Cardiac tamponade from central venous catheters. *Am J Surg* **176**, 212-4 (1998).
3. McGee, D.C. & Gould, M.K. Preventing complications of central venous catheterization. *N Engl J Med* **348**, 1123-33 (2003).
4. Polderman, K.H. & Girbes, A.R. Central venous catheter use. Part 2: infectious complications. *Intensive Care Med* **28**, 18-28 (2002).
5. Polderman, K.H. & Girbes, A.J. Central venous catheter use. Part 1: mechanical complications. *Intensive Care Med* **28**, 1-17 (2002).
6. Bowdle, T.A. Complications of invasive monitoring. *Anesthesiol Clin North America* **20**, 571-588 (2002).
7. Hall, A.P. & Russell, W.C. Toward safer central venous access: ultrasound guidance and sound advice. *Anaesthesia* **60**, 1-4 (2005).
8. Domino, K.B. et al. Injuries and liability related to central vascular catheters: a closed claims analysis. *Anesthesiology* **100**, 1411-8 (2004).
9. Shah, P.M., Babu, S.C., Goyal, A., Mateo, R.B. & Madden, R.E. Arterial misplacement of large-caliber cannulas during jugular vein catheterization: case for surgical management. *J Am Coll Surg* **198**, 939-44 (2004).
10. Ezaru, C.S., Mangione, M.P., Oravitz, T.M., Ibinson, J.W. & Bjerke, R.J. Eliminating arterial injury during central venous catheterization using manometry. *Anesth Analg* **109**, 130-4 (2009).
11. Kusminsky, R.E. Complications of central venous catheterization. *J Am Coll Surg* **204**, 681-96 (2007).
12. Cayne, N.S. et al. Experience and technique for the endovascular management of iatrogenic subclavian artery injury. *Ann Vasc Surg* **24**, 44-7.
13. Pikwer, A. et al. Management of inadvertent arterial catheterisation associated with central venous access procedures. *Eur J Vasc Endovasc Surg* **38**, 707-14 (2009).
14. Schwartz, A., Jobes, D. & Greenholo, D. Carotid artery puncture with internal jugular cannulation. *Anesthesiology* **51**, S160 (1979).
15. Shah, K.B., Rao, T.L., Laughlin, S. & El-Etr, A.A. A review of pulmonary artery catheterization in 6,245 patients. *Anesthesiology* **61**, 271-5 (1984).
16. Kron, I.L., Joob, A.W., Lake, C.L. & Nolan, S.P. Arch vessel injury during pulmonary artery catheter placement. *Ann Thorac Surg* **39**, 223-4 (1985).
17. Golden, L.R. Incidence and management of large-bore introducer sheath puncture of the carotid artery. *J Cardiothorac Vasc Anesth* **9**, 425-8 (1995).
18. Wicky, S. et al. Life-threatening vascular complications after central venous catheter placement. *Eur Radiol* **12**, 901-7 (2002).
19. Troianos, C.A., Jobes, D.R. & Ellison, N. Ultrasound-guided cannulation of the internal jugular vein. A prospective, randomized study. *Anesth Analg* **72**, 823-6 (1991).
20. Randolph, A.G., Cook, D.J., Gonzales, C.A. & Pribble, C.G. Ultrasound guidance for placement of central venous catheters: a meta-analysis of the literature. *Crit Care Med* **24**, 2053-8 (1996).
21. Hind, D. et al. Ultrasonic locating devices for central venous cannulation: meta-analysis. *Bmj* **327**, 361 (2003).
22. Mansfield, P.F., Hohn, D.C., Fornage, B.D., Gregurich, M.A. & Ota, D.M. Complications and failures of subclavian-vein catheterization. *N Engl J Med* **331**, 1735-8 (1994).
23. National Institute for Clinical Excellence. Technology Appraisal No. 49. Guidance on the use of ultrasound locating devices for placing central venous catheters. National Institute for Clinical Excellence, 2002. Available at <http://guidance.nice.org.uk/TA49>.
24. Guidance on the use of ultrasound locating devices for placing central venous catheters. in *London, National Institute for Clinical Excellence, 2002* Vol 2005.

25. Bailey, P.L., Glance, L.G., Eaton, M.P., Parshall, B. & McIntosh, S. A survey of the use of ultrasound during central venous catheterization. *Anesth Analg* **104**, 491-7 (2007).
26. Harris, N., Hodzovic, I. & Latto, P. A national survey of the use of ultrasound during central venous catheterization. *Anaesthesia* **62**, 306-307 (2007).
27. Chapman, G.A., Johnson, D. & Bodenham, A.R. Visualisation of needle position using ultrasonography. *Anaesthesia* **61**, 148-58 (2006).
28. Blaivas, M. Video analysis of accidental arterial cannulation with dynamic ultrasound guidance for central venous access. *J Ultrasound Med* **28**, 1239-44 (2009).
29. Thompson, C. & Barrows, T. Carotid arterial cannulation: removing the risk with ultrasound? *Can J Anaesth* **56**, 471-2 (2009).
30. Parsons, A.J. & Alfa, J. Carotid dissection: a complication of internal jugular vein cannulation with the use of ultrasound. *Anesth Analg* **109**, 135-6 (2009).
31. Adachi, Y.U. & Sato, S. Four cases of inadvertent arterial cannulation despite of ultrasound guidance. *Am J Emerg Med* **28**, 533.
32. Jobs, D.R., Schwartz, A.J., Greenhow, D.E., Stephenson, L.W. & Ellison, N. Safer jugular vein cannulation: recognition of arterial puncture and preferential use of the external jugular route. *Anesthesiology* **59**, 353-5 (1983).
33. Oliver, W.C., Jr. et al. The incidence of artery puncture with central venous cannulation using a modified technique for detection and prevention of arterial cannulation. *J Cardiothorac Vasc Anesth* **11**, 851-5 (1997).
34. Leone, B.J. Con: manometry during internal jugular cannulation: case not proven. *Anesth Analg* **109**, 6-7 (2009).
35. Bowdle, A., Kharasch, E. & Schwid, H. Pressure waveform monitoring during central venous catheterization. *Anesth Analg* **109**, 2030-1; author reply 2031 (2009).
36. Kulvatunyou, N., Heard, S.O. & Bankey, P.E. A subclavian artery injury, secondary to internal jugular vein cannulation, is a predictable right-sided phenomenon. *Anesth Analg* **95**, 564-6, table of contents (2002).
37. Guilbert, M.C. et al. Arterial trauma during central venous catheter insertion: Case series, review and proposed algorithm. *J Vasc Surg* **48**, 918-25; discussion 925 (2008).
38. Feller-Kopman, D. Ultrasound-guided central venous catheter placement: the new standard of care? *Crit Care Med* **33**, 1875-7 (2005).
39. Mallory, D.L. et al. Ultrasound guidance improves the success rate of internal jugular vein cannulation. A prospective, randomized trial. *Chest* **98**, 157-60 (1990).
40. <http://www.ihl.org/IHI/Topics/CriticalCare/IntensiveCare/Tools/CentralLineInsertionChecklist.htm>.
41. <http://www.asahq.org/clinical/CentralVenous.htm>.
42. Making health care safer: A critical analysis of patient safety practices. Evidence report/technology assessment: Number 43. AHRQ Publication No. 01-E058, 2001.
43. Central Line Insertion Care Team Checklist. May 2009. Agency for Healthcare Research and Quality, Rockville, MD. <http://www.ahrq.gov/qual/clicklist.htm>.