


The Complex Surgical Abdomen: What the Nonsurgeon Intensivist Needs to Know

Journal of Intensive Care Medicine
2016, Vol. 31(4) 237-242
© The Author(s) 2015
Reprints and permission:
sagepub.com/journalsPermissions.nav
DOI: 10.1177/0885066615569974
jic.sagepub.com


Wess A. Cohen, MD¹, Joel H. Horovitz, MD¹, Yizhak Kupfer, MD²,
and Richard H. Savel, MD, FCCM^{1,2}

Abstract

Intensivists are often called upon to help care for patients who develop severe sepsis syndrome and septic shock where the primary source is an enterocutaneous fistula (ECF). The purpose of this article is to describe to the nonsurgeon intensivist how these complex surgical situations arise in the first place and provide the reader with a detailed understanding of the potentially devastating complications of ECF. In addition, we will describe a structured algorithm regarding the management of this often highly challenging surgical situation.

Keywords

fistula, severe sepsis, septic shock, malnutrition, enteral nutrition, parenteral nutrition, abdominal abscess, abdominal surgery, general surgery, surgical critical care, enterocutaneous fistula, open abdomen

Introduction

Intensivists are often called upon to help care for patients who develop severe sepsis syndrome and septic shock where the primary source is an enterocutaneous fistula (ECF). Yet the reasons behind how these extremely complex surgical problems may have developed in the first place can be obtuse to the nonsurgical intensivist. In addition, it is of the utmost importance for the intensivist to be able to understand the structured approach that the surgeon will be taking toward the short- and long-term management of these patients.

The purpose of this article is to describe to the nonsurgeon intensivist how these complex surgical situations arise in the first place and provide the reader with a detailed understanding of the potentially devastating complications of ECF. In addition, we will describe a structured algorithm regarding the management of this often highly challenging surgical situation.

Definitions

A fistula is defined as an abnormal connection between 2 epithelial lined organs. Fistulas can be internal—with abnormal openings between hollow viscera—or external—with a connection between hollow viscera and the skin (ie, ECF).¹ There are various ways of classifying a fistula and its tract. Anatomical classification uses the names of the organs involved with the highest pressure system named first (eg, gastrocutaneous). There are complex or simple fistulas, with simple fistulas having a single tract. In addition, they can also be organized by fistula length, with long fistulas being greater than 2 cm.² Volume of output is also important to define, as a high-output fistula

(more than 500 mL/d) carries a mortality risk 5 times greater than a low-output fistula.³ Finally, a fistula is considered controlled if there are no signs of sepsis, intraabdominal infection, or skin breakdown (Table 1).

Etiology

Seventy-five percent of enteric fistulas are iatrogenic, with the remainder being spontaneous in origin.^{1,2} Spontaneous fistulas are most likely to occur secondary to Crohn disease and complicated diverticular disease.⁴ Any intraabdominal procedure can result in an ECF; patients who have undergone procedures where the bowel wall was damaged or were managed with an open abdomen for any amount of time carry the greatest risk. An unrecognized enterotomy is the source of half of the iatrogenic causes, with the other half being from an anastomotic leak or dehiscence. Postoperative enteric fistulas often become clinically evident by way of peritonitis, sepsis, or effluent cutaneous drainage, with the peak occurrence being between the fifth and tenth postoperative day.⁵ Although there are no

¹ Department of Surgery, Maimonides Medical Center, Brooklyn, NY, USA

² Division of Critical Care Medicine, Maimonides Medical Center, Brooklyn, NY, USA

Received August 1, 2014, and in revised form October 16, 2014. Accepted for publication November 5, 2014.

Corresponding Author:

Richard H. Savel, Division of Critical Care Medicine, Maimonides Medical Center, 4802 10th Ave, Brooklyn, NY 11219, USA.

Email: rhsavel@gmail.com

Table 1. Classification of ECF.

Classification	Description
Anatomical	<ol style="list-style-type: none"> 1. Gastric 2. Small bowel 3. Colon 4. Rectum
Number of tracts	<ol style="list-style-type: none"> 1. Simple: 1 tract 2. Complex: > 1 tract
Length	<ol style="list-style-type: none"> 1. Short: ≤2 cm 2. Long: >2 cm
Daily output volume	<ol style="list-style-type: none"> 1. Low: ≤200 mL 2. Intermediate: 200-500 mL 3. High: >500 mL
Control	<ol style="list-style-type: none"> 1. Controlled: no signs of sepsis, intra-abdominal infection, or skin breakdown 2. Uncontrolled: signs of sepsis, intra-abdominal infection or skin breakdown

Abbreviation: ECF, enterocutaneous fistula.

studies confirming the cellular events that lead to the development of enteric fistulas, it is theorized that intestinal contents outside the intestinal lumen break down surrounding tissue layers, and a fistula tract is then formed by local inflammatory processes.

There are several techniques to minimize the risk of developing an ECF. The most important principles are meticulous operative technique, with recognition and treatment of enterotomies and serosal tears at the time of the index operation. The operations with the highest rate of fistula formation involve lysis of adhesions, resection of malignancy, and abdominal surgery for inflammatory bowel disease.⁶ Any abdominal infection can predispose to anastomotic and wound breakdown with subsequent potential fistula formation. Avoiding infection with the use of preincisional antibiotics, appropriate skin prep, and sterile technique can help to reduce risk. Intraoperatively, it is important to have a tension-free anastomosis, well-perfused bowel, adequate hemostasis, and an operative time of less than 2 hours, as all of these factors have been associated with decreased postoperative complications.²

Although the placement of a surgical drain cannot always be avoided, it is important to remember that they are foreign bodies with the potential to erode into anastomoses and predispose to ECFs. Routine drain usage in this setting is actively debated by surgeons. The clinical utility of a surgical drain varies widely and is based upon the specific procedure performed as well as the overall clinical status of the patient. Importantly, routine drain placement is not indicated for all intra-abdominal operations, and the surgeon must balance any potential benefit that a drain may offer with the risk of introducing a foreign body.

There are also many patient factors that contribute to the development of an ECF. Modifiable patient-related risk factors include malnutrition, obesity, alcohol abuse, and smoking. Nonmodifiable patient risk factors include cardiovascular disease, chronic obstructive pulmonary disease, high American Society of Anesthesiologists physical status classification, 2

Table 2. Complications of ECF.

Infectious Complications	Noninfectious complications
<ol style="list-style-type: none"> 1. Abdominal collections 2. Soft tissue infections 3. Line infections 4. Sepsis 5. Death 	<ol style="list-style-type: none"> 1. Fluid and electrolyte abnormalities 2. Malnutrition 3. Skin excoriation

Abbreviation: ECF, enterocutaneous fistula.

or more systemic diseases, advanced age, prior abdominopelvic radiation therapy, and corticosteroid use.⁷ It is extremely important for the surgeon to take into account the above-mentioned risks before operating on a patient.

Diagnosis

Although visualizing drainage of intestinal contents from an operative incision or drain site clearly establishes a diagnosis of an ECF, an ECF can manifest in other more subtle ways as well. For example, there may be persistent ileus, leukocytosis, or unexplained abdominal pain, fever, or sepsis.² When one is entertaining the diagnosis of an ECF, it is extremely important to obtain proper imaging to define the fistula tract as well as to rule out any drainable collections and to determine bowel continuity or distal obstruction.⁶ The methylene blue dye test gives information about the site and origin of the fistula, with the agent being administered orally or via a nasogastric tube. Appearance of blue dye on the skin confirms the presence of an ECF.

To ascertain the extent of the fistula and the patency of the gastrointestinal (GI) tract distally from the origin of the fistula, a water-soluble contrast x-ray is helpful. In this test, the contrast can be administered orally or rectally. Fistulograms can also provide an abundance of information. With the use of contrast dye and fluoroscopy, a fistulogram can provide detailed information regarding the location of the fistula, integrity of the intestines, as well as determine the presence of any associated abscess cavities, or distal obstruction. All of these factors will contribute to the likelihood of the fistula closing spontaneously, with proximal fistulas being especially difficult to manage due to their tendency for high output. Computed tomography (CT) is particularly useful given its ability to not only identify intra-abdominal fluid collections but also delineate the fistula tract. With the current ubiquity and high quality of CT scans, this imaging modality has largely supplanted other diagnostic methods in the setting of ECF.⁸

Complications

The untoward sequelae of ECFs can be organized into infectious and noninfectious categories (Table 2). Infectious complications include sepsis, multiorgan failure, and even death for a minority of patients. Historically, up to 39% of ECFs were lethal.^{1,3,9,10} However, more recent data suggest that the overall mortality rate is closer to 10%, and that there is a 4% 30-day

mortality after an operation for an ECF.^{4,11} Noninfectious complications are comprised of electrolyte imbalances, malnutrition, and skin excoriation.

Patients with ECF are at high risk of infectious complications. Although a fistulous tract may be present from the bowel to the abdominal wall, there are often other fistulae present with frequent stool spillage into the intraperitoneal cavity. Septic complications need to be treated aggressively and occur in approximately one-third of patients after an operation for an ECF.¹¹ Sepsis can arise from a localized abscess, soft tissue infection, or generalized peritonitis.¹⁰ Many of these patients have central venous catheters for long-term parenteral nutrition, with a risk of developing catheter-related bloodstream infection as high as 63%.¹¹ It is important to note that adequate, definitive source control can often be very difficult to obtain: percutaneous drainage of abscess cavities is often challenging to localize, and surgeons are often unable to reoperate in the short term due to edematous, inflamed, infected, and friable tissue with poor or no likelihood of adequate wound healing (ie, “hostile abdomen”).

Noninfectious complications of ECFs are mainly related to massive daily fluid and electrolyte losses. Patients can lose up to 7 liters from proximal high-output fistulas.¹ In addition to serious electrolyte and acid-base abnormalities, these patients can also develop intestinal failure, defined as the reduction in functioning gut mass below the minimal amount necessary for adequate digestion and absorption of nutrients and fluids.¹² Intestinal failure can arise from the fistula itself, as nutrients bypass the absorptive capabilities of the intestine, or from short bowel syndrome, defined as less than 200 cm of residual small bowel after surgical resection.¹⁰ It is important to note that malnutrition arises not only from GI losses but also from a hypercatabolic state secondary to sepsis coupled with inadequate calorie intake. Further complications from electrolyte abnormalities and malnutrition include postoperative ileus, loss of bowel integrity, and absorptive surface area and continuing external loss of protein-rich enteric contents that can lead to hypoalbuminemia, hypoproteinemia, and edema/anasarca.

Providing adequate nutrition becomes a significant challenge in the majority of patients with ECF, with malnutrition occurring in up to 90%.¹³ One of the primary reasons for this is that the mainstay of treatment for ECFs is to keep these patients nil per os for an extended period of time until the fistula tract closes on its own. Malnutrition in patients with ECF is also complicated by loss of protein-rich GI secretions, ongoing sepsis, and hypercatabolism. Even if the patient is able to tolerate enteral nutrition, they are often unable to absorb an adequate quantity of nutrients. Adequate nutrition is closely associated with decreased mortality and an increased rate of fistula closure. As such, consideration should be given to biochemical monitoring of nutritional status with the use of determining serum albumin, prealbumin, and/or transferrin levels, although the evidence behind this practice is not particularly strong.¹

Skin excoriation can occur within 3 hours of stasis on the skin of either alkaline or acidic fluid (dependent on the origin

of the fistula) and can be severely debilitating. The intestinal enzymes can further digest the skin creating large, complicated, and painful wounds. Meticulous wound care should be a priority as soon as an ECF is realized, as once skin damage occurs, it can be extremely difficult to reverse. Ostomy devices are difficult to fit and seal on raw painful skin; early involvement of a wound care specialist can help to decrease the incidence of this debilitating complication (Table 2).

Management

Initial Conservative Management

Given the aforementioned numerous complications of ECFs, one might imagine that it would behoove the surgeon to repair these as soon as possible. It is very important for the nonsurgeon intensivist to know that this reasonable supposition is, in fact, false.

Routinely, patients must be well enough to not require critical care services before a surgeon will consider primary repair of an ECF, as early operative intervention is associated with increased morbidity and mortality (Figure 1).¹⁴

Management of ECFs involves patience. In patients with isolated, simple ECF, 75% will close spontaneously, 90% within 4 weeks.¹ Unfortunately, 80% of patients with ECF have complicating factors, and, in the majority of those patients, spontaneous closure does not routinely occur.^{1,11} Complicating factors can be remembered by the commonly taught mnemonic “FRIEND”: Foreign body, Radiation, Infection/Inflammation, Epithelialization, Neoplasm, and Distal obstruction.

If the fistula has not closed after 6 weeks of medical management, then surgical closure should be considered. There is no optimal time to undertake surgical closure, however, and the surgeon must weigh many factors before making this decision. Some surgeons advocate waiting 3 to 12 months before proceeding with an operation in order to not only optimize the patient's overall physiologic and nutritional status but also to allow peritoneal inflammation to subside. After an abdominal operation, a dense fibroadhesive reaction takes place from week 1 to 6, which makes the operative dissection extremely difficult; there is an associated increased risk of enterotomies, recurrent fistulas, as well as an increased likelihood that surgery will require excision of large amounts of small bowel. Although there is no definitive way of knowing when the reaction has subsided, the abdominal examination should be soft and nontender, and the abdominal scar should be pliable—indicating that the abdominal wall is free of inflammation.¹⁵

The longer the patient and surgeon can wait to undertake an elective operation, the lower the risk of fistula recurrence.² However, operative intervals longer than 36 weeks are associated with an increased risk of recurrence.¹¹ Risk of recurrence is 4 times greater with high-output fistulas as compared to low and also increases in patients with a history of an open abdomen, ongoing abdominal sepsis, or preoperative short bowel syndrome.^{4,11} Many surgeons advocate waiting at least 3 months after the last laparotomy in order for the adhesions and

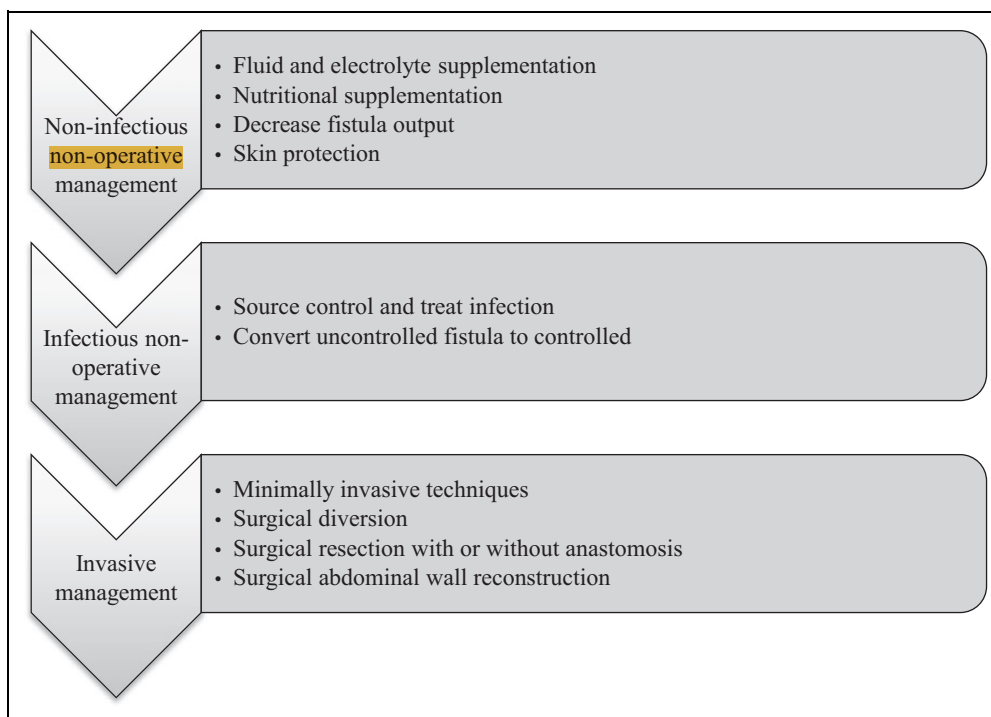


Figure 1. Management of enterocutaneous fistula.

inflammatory reactions to resolve.¹⁶ It has been shown that multiple variables were significantly associated with mortality after ECF resection including age >55, sepsis at admission, malnutrition, fluid and electrolyte imbalance, and ECF closure attempt in <20 weeks from diagnosis.⁴ It is extremely important that the patient's modifiable risk factors be optimized such as glycemic control for diabetics, tobacco cessation, weight loss for obese patients, and nutritional optimization to give the patient the best chance of preventing wound infection or anastomotic breakdown.

These patients will often require frequent, sometimes prolonged hospitalization for nutritional support and electrolyte abnormalities. In patients with ECF, adequate nutrition is associated with an increased likelihood of spontaneous fistula closure.^{6,15} In an analogous fashion, patients with ECF who do not receive adequate nutritional support have a significantly elevated mortality risk.⁶ Total parenteral nutrition (TPN) is often necessary for these patients as they are nil per os for a prolonged period of time. Although parenteral nutrition alone has not been proven to reduce overall mortality in patients with an ECF, it does assist with spontaneous closure. Importantly, however, it has not been proven that parenteral nutrition is superior to enteral nutrition in accelerating spontaneous closure. If a patient can tolerate enteral nutrition and maintain a low-output fistula, then enteral nutrition is the best option for this patient. However, if the patient develops a high-output ECF while receiving enteral nutrition, then nil per os and TPN become necessary.

Fistuloclysis (ie, direct feeding into the fistula) is another option to maintain nutritional status in select patients and obviates the need of a central catheter and its inherent risks and

complications. Although this technique is more efficacious in the patient with a proximal fistula where there is more intestine available for nutrient absorption compared to the distal fistula, further studies must be performed to clarify its effectiveness in providing nutritional support.¹⁷

Various pharmacological agents have been used to control ECFs. When paired with TPN, somatostatin has been shown to have synergistic effects in spontaneous closure of ECF.¹ Octreotide (somatostatin analog) has proven properties of decreasing intestinal transit time, decreasing endogenous fluid secretions, and increasing absorption of water and electrolytes.^{1,18} Also, histamine 2 receptor antagonists and proton pump inhibitors have been used to decrease GI output, decrease acid production, reduce electrolyte loss, and prevent stress ulcers, although their efficacy with regard to spontaneous closure of ECF has not been proven.

Patients with an uncontrolled ECF often develop severe sepsis syndrome, accounting for at least 80% of deaths in patients with intestinal fistulas.¹⁶ It is beyond the scope of this manuscript to discuss the current recommended approach to managing patients with severe sepsis syndrome and septic shock. As in all patients with this disease, early, aggressive management is associated with the best outcomes. In terms of surgical source control, abscess cavities can be detected in up to 50% of patients with ECFs, and more than 80% of these are amenable to percutaneous drainage.¹⁹ If a fistula is uncontrolled, the goal is to make it controlled by draining any abscess cavities, removing distal obstructions, and providing adequate nutrition.

Skin excoriation is a very painful and difficult complication of ECFs. Intestinal enzymes, either acidic or alkaline, depending on the fistula origin, work to break down the epidermis and

dermal layers. Not only is this extremely painful for the patient, but it makes control of the fistula and definitive closure more difficult. If these intestinal enzymes remain in direct contact with skin surfaces for a prolonged period, they can broaden the fistula tract and increase the skin defect.

There are various techniques to protect the skin which include, but are not limited to: (1) placement of negative pressure wound therapy dressing either with a salem sump drain attached to wall suction or a negative pressure commercially available dressing; (2) creation of a floating stoma, which involves the surgeon diverting the fistula contents into an externally placed plastic collection bag²⁰; or (3) placement of an ostomy appliance. Early involvement of a wound care team can be very helpful in managing these complex defects.

Description of More Invasive Therapy

Although there are various techniques for more invasive, non-surgical approaches for fistulae closure, none have been proven to be clearly effective in a randomized prospective trial. Fibrin glue injection is done either endoscopically or with fluoroscopy. After the fistula is located (either endoscopically or from an external opening), a mixture of bovine thrombin, human fibrinogen, and fibrin is injected. There are many case reports describing the utility of fibrin glue in low-output, short, uncomplicated, uninfected fistulas without evidence of neoplasia or IBD.^{21,22} The risks of this procedure include contamination with prions or allergic reactions, both of which are extremely rare.²

Similarly, histoacryl glue is another injectable product. This formula is not from animal products; therefore, there is no risk of allergic reactions or infectious complications. Also, histoacryl glue resists enzymatic breakdown, which makes its use more amenable to high-output fistulas.²³ Porcine small intestinal submucosa has been used for perianal fistulae, and there are reports of its use in small bowel fistulae as well.²⁴ This product, a naturally derived extracellular matrix that acts as a scaffold for host tissue ingrowth, works to decrease the diameter of the fistula.²

How to Close

Source control and definitive closure of the ECF are the common goals of surgical intervention. If the patient fails to improve with conservative therapy or there is evidence of an undrainable abscess, the surgeon may be forced to take the patient to the operating department for an abdominal washout and creation of a proximal diverting ostomy. This operation cleans the abdomen of infectious contents as well as works to decrease the amount of intestinal content soilage to the peritoneal cavity. The decision to operate on these patients should not be taken lightly. Operations within 1 week of a laparotomy are likely to involve dense adhesions and friable edematous bowel, which makes reoperation extremely difficult and increases the risk of further complications, such as inadvertent enterotomies.² Also, it is not always possible to locate the fistula tract,

and if located, to be able to resect the diseased portion of bowel to obtain adequate source control. Even after definitive surgical resection of an ECF, one-third of the patients have a recurrence.⁴

The surgical technique, like the management of ECFs, involves much patience. The operations are technically challenging and often time consuming. The abdomen should be reopened away from any areas of possible contamination and either above or below the old laparotomy incision to avoid creating an enterotomy. Inadvertent enterotomies increase the subsequent development of postoperative complications.²⁵

The small intestine must be completely freed from the ligation of Treitz to the cecum. This facilitates examination of the entire small bowel to assess for strictures, masses, internal fistulas, and walled off leaks that may have been overlooked in earlier radiographic assessments. Importantly, it also allows for full thickness resection of the portion of bowel that contains the fistula and reanastomosis without tension. Although resection with primary anastomosis is the operative procedure of choice, it should be noted that—even if this procedure can technically be performed successfully—the fistula recurrence rate is almost 20%.²⁶ Other operative steps that the surgeon will use to decrease complications include examining the entire bowel to identify and repair serosal or full thickness injuries or placing the omentum between the bowel and midline to seal any microscopic defects. Closure of the abdominal wall primarily may not be possible. If this is the case, a component separation or use of a prosthetic mesh may be employed. Of note, patients with Crohn disease, cancer, or radiation enteritis are at significant risk to recur and any attempt at operative closure should be well thought out.²

When and How to Involve Palliative Care

A certain subgroup of these patients will not respond to any form of therapy. These patients are at very high risk for recurrent bouts of severe sepsis syndrome and multiorgan failure. As the patient may have become chronically critically ill and has been in and out of the ICU setting numerous times, it may be difficult to determine exactly when a “goals of care discussion” needs to be had. Nevertheless, it cannot be overemphasized that these discussions need to be had so that patients and families understand the true gravity of the situation they are in. This is an excellent example where a multispecialty meeting of surgeon, intensivist, and palliative care attending should occur between with patient and family members to clarify and optimize goals of care.^{27,28}

Conclusions and Recommendations

We have attempted to clarify what can often be a somewhat nebulous and confusing area for the nonsurgeon intensivist. Patients who develop the unfortunate complication of an ECF often require significant resources, with hospitalizations that are often measured in terms of months. Regardless, it is felt that

these resources are appropriately applied as they can make a full recovery.

As these patients often will require multiple stays in an ICU if they develop severe sepsis syndrome/septic shock, it is crucial for the intensivist to understand the “big picture” plan from the perspective of the general surgeon who will be managing the patient throughout the course of their hospitalization. Examples of this include (1) a fuller understanding of the etiology of ECF; (2) describing some of the important infectious and noninfectious complications of ECF; and (3) providing the intensivist with a consensus, evidence-based approach toward the surgical and nonsurgical approaches toward complete recovery from ECF. Although there are a multitude of retrospective studies that investigate this topic, the paucity of prospective studies provides an opportunity for further research.

Declaration of Conflicting Interests

The author(s) declared no potential conflicts of interest with respect to the research, authorship, and/or publication of this article.

Funding

The author(s) received no financial support for the research, authorship, and/or publication of this article.

References

- Makhdoom ZA, Komar MJ, Still CD. Nutrition and enterocutaneous fistulas. *J Clin Gastroenterol*. 2000;31(3):195-204.
- Galie KL, Whitlow CB. Postoperative enterocutaneous fistula: when to reoperate and how to succeed. *Clin Colon Rectal Surg*. 2006;19(4):237-246.
- Campos AC, Andrade DF, Campos GM, Matias JE, Coelho JC. A multivariate model to determine prognostic factors in gastrointestinal fistulas. *J Am Coll Surg*. 1999;188(5):483-490.
- Martinez JL, Luque-de-Leon E, Ballinas-Oseguera G, Mendez JD, Juarez-Oropeza MA, Roman-Ramos R. Factors predictive of recurrence and mortality after surgical repair of enterocutaneous fistula. *J Gastrointest Surg*. 2012;16(1):156-163; discussion 163-154.
- Masoomi H, Carmichael JC, Mills S, Pigazzi A, Stamos MJ. Predictive risk factors of early postoperative enteric fistula in colon and rectal surgery. *Am Surg*. 2013;79(10):1058-1063.
- Lundy JB, Fischer JE. Historical perspectives in the care of patients with enterocutaneous fistula. *Clin Colon Rectal Surg*. 2010;23(3):133-141.
- Chambers WM, Mortensen NJ. Postoperative leakage and abscess formation after colorectal surgery. *Best Pract Res Clin Gastroenterol*. 2004;18(5):865-880.
- Schechter WP, Hirshberg A, Chang DS, et al. Enteric fistulas: principles of management. *J Am Coll Surg*. 2009;209(4):484-491.
- Memon AS, Siddiqui FG. Causes and management of postoperative enterocutaneous fistulas. *J Coll Physicians Surg Pak*. 2004;14(1):25-28.
- Williams LJ, Zolfaghari S, Boushey RP. Complications of enterocutaneous fistulas and their management. *Clin Colon Rectal Surg*. 2010;23(3):209-220.
- Owen RM, Love TP, Perez SD, et al. Definitive surgical treatment of enterocutaneous fistula: outcomes of a 23-year experience. *JAMA Surg*. 2013;148(2):118-126.
- Goulet O, Ruemmele F. Causes and management of intestinal failure in children. *Gastroenterology*. 2006;130(2 Suppl 1):S16-28.
- Berry SM, Fischer JE. Classification and pathophysiology of enterocutaneous fistulas. *Surg Clin North Am*. 1996;76(5):1009-1018.
- Evenson AR, Fischer JE. Current management of enterocutaneous fistula. *J Gastrointest Surg*. 2006;10(3):455-464.
- Davis KG, Johnson EK. Controversies in the care of the enterocutaneous fistula. *Surg Clin North Am*. 2013;93(1):231-250.
- Kaushal M, Carlson GL. Management of enterocutaneous fistulas. *Clin Colon Rectal Surg*. 2004;17(2):79-88.
- Teubner A, Morrison K, Ravishankar HR, Anderson ID, Scott NA, Carlson GL. Fistuloclysis can successfully replace parenteral feeding in the nutritional support of patients with enterocutaneous fistula. *Br J Surg*. 2004;91(5):625-631.
- Sitges-Serra A, Jaurrieta E, Sitges-Creus A. Management of postoperative enterocutaneous fistulas: the roles of parenteral nutrition and surgery. *Br J Surg*. 1982;69(3):147-150.
- Thomas HA. Radiologic investigation and treatment of gastrointestinal fistulas. *Surg Clin North Am*. 1996;76(5):1081-1094.
- Subramaniam MH, Liscum KR, Hirshberg A. The floating stoma: a new technique for controlling exposed fistulae in abdominal trauma. *J Trauma*. 2002;53(2):386-388.
- Meister T, Kuhlitz J, Floer M. Over-the-Scope Clip (OTSC) application as rescue therapy for postoperative enterocutaneous fistula closure. *Acta Chir Belg*. 2014;114(1):87-89.
- Ren J, Wu X, Wang G, Chen J, Gu G, Li J. Fistula fiberscope-assisted percutaneous glue sealing for enterocutaneous fistulas: a case report. *Surg Laparosc Endosc Percutan Tech*. 2013;23(6):e235-236.
- Cambj Sapunar L, Sekovski B, Matic D, Tripkovic A, Grandic L, Druzijanic N. Percutaneous embolization of persistent low-output enterocutaneous fistulas. *Eur Radiol*. 2012;22(9):1991-1997.
- Cintron JR, Abcarian H, Chaudhry V, et al. Treatment of fistula-in-ano using a porcine small intestinal submucosa anal fistula plug. *Tech Coloproctol*. 2013;17(2):187-191.
- Van Der Krabben AA, Dijkstra FR, Nieuwenhuijzen M, Reijnen MM, Schaapveld M, Van Goor H. Morbidity and mortality of inadvertent enterotomy during adhesiotomy. *Br J Surg*. 2000;87(4):467-471.
- Lynch AC, Delaney CP, Senagore AJ, Connor JT, Remzi FH, Fazio VW. Clinical outcome and factors predictive of recurrence after enterocutaneous fistula surgery. *Ann Surg*. 2004;240(5):825-831.
- Savel RH, Munro CL. How much care is too much care? *Am J Crit Care*. 2013;22(2):86-88.
- Toevs CC. Palliative medicine in the surgical intensive care unit and trauma. *Surg Clin North Am*. 2011;91(2):325-331, viii.