

# Necrotizing soft tissue infections in the intensive care unit

Ho H. Phan, MD; Christine S. Cocanour, MD, FACS, FCCM

**Necrotizing soft tissue infection** is a severe illness that is associated with significant morbidity and mortality. It is often caused by a wide spectrum of pathogens and is most frequently polymicrobial. Care for patients with necrotizing soft tissue infection requires a team approach with expertise from critical care, surgery, reconstructive surgery, and rehabilitation specialists. The early diagnosis of necrotizing soft tissue infection is challenging, but the keys to successful management of patients with necrotizing soft tissue infection are early recognition and complete surgical debridement. Early initiation of appropriate broad-spectrum antibiotic therapy must take into consideration the

potential pathogens. Critical care management components such as the initial fluid resuscitation, end-organ support, pain management, nutrition support, and wound care are all important aspects of the care of patients with necrotizing soft tissue infection. Soft tissue reconstruction should take into account both functional and cosmetic outcome. (Crit Care Med 2010; 38[Suppl.]:S460–S468)

**KEY WORDS:** necrotizing soft tissue infection; fasciitis; methicillin-resistant *Staphylococcus aureus*; intensive care unit; hyperbaric oxygenation; Laboratory Risk Indicator for Necrotizing Fasciitis

**N**ecrotizing soft tissue infections (NSTIs) were first described by Hippocrates: "...when the exciting cause was a trivial accident or a very small wound ... the erysipelas would quickly spread widely in all directions. Flesh, sinews, and bones fell away in large quantities .... There were many deaths" (1). This is not dissimilar to what we see today.

NSTIs are rare. There are approximately 1000 cases per year in the United States or 0.04 cases per 1000 person-years (2). Trends in the prevalence of NSTI are unclear as the Centers for Disease Control and Prevention stopped surveillance for these infections in 1991 and now tracks only group A *Streptococcus* infections. But recent literature (3) suggested that they are increasing. NSTI patients require extensive intensive care unit resources. In the **United Kingdom** between 1995 and 2006, **0.24% of intensive care unit admissions** were due to **necrotizing fasciitis** (4). The mean intensive **care unit stay** for patients with NSTI is **21 days** with mean hospital stays of 32 days for survivors and 12 days for non-

survivors (4). The total cost of care is significant and ranges from \$71,000 to \$83,000 (4). The majority of NSTIs are treated by surgeons in the community, but increasingly these patients are being referred to tertiary care hospitals and **burn centers** for specialized wound and critical care management.

**Mortality** from NSTI has **decreased little over the last 30 yrs** despite improvements in medical care. In the **United Kingdom** between 1995 and 2006, patients with NSTIs had a **mortality of 41.6%** (5). In 67 studies that included 3302 patients from 1980 through 2008, overall mortality was 23.5% (6). There was only a slight downward trend, from 27.8% to 21.7%, for those studies published from 1980 through 1999 and the studies from 1999 through 2008, respectively (6). However, a recent review (7) of NSTI from the National Surgical Quality Improvement Program database found a mortality rate of only 12%. Whether this decreased mortality reflects the continued improvements in treatment at tertiary hospitals, which are the primary contributors to the National Surgical Quality Improvement Program database, is unclear. Improvements in outcome continue to require **early diagnosis, early and aggressive surgical debridement, administration of appropriate antibiotics, and optimization of underlying medical comorbidities.**

**NSTIs are known by many different names.** A brief review of the history of NSTI illustrates how this **confusing** no-

menclature occurred. Naming was based on clinical features instead of a surgical or pathologic diagnosis. Necrotizing infection of the **genital and perineal region** was first reported in 1764 by Baurienne (8). It began being referred to as **Fournier's gangrene** after a series of five male patients were presented in 1883 and 1884 by the **French dermatologist and venereologist Jean Alfred Fournier** (9, 10). The first large-scale description of **necrotizing infections** came during the **American Civil War** when a **Confederate Army** surgeon, Dr. Joseph Jones, reported 2,642 cases with a **mortality rate of 46%** (11). In 1926, Brewer and **Meleney** (12) described a **rare postoperative infection** that was a slowly progressive, superficial, necrotizing process that they attributed to microaerophilic, nonhemolytic *Streptococcus* and a hemolytic *Staphylococcus aureus*. Subsequently, in 1988, Davson et al (13) suggested that cutaneous amebiasis may be the correct cause of Brewer and Meleney's synergistic gangrene. **Numerous other terms** have been used throughout the years, including **hospital gangrene, necrotizing erysipelas, suppurative fasciitis, clostridial gangrene, and gas gangrene.** Wilson (14) introduced the term **necrotizing fasciitis** in 1951 to refer to both gas-forming and non-gas-forming necrotizing infections. Because diagnosis and **management require a similar approach, regardless of the anatomical location or depth of involvement, NSTI is now supplanting necrotizing fasciitis** as the **preferred name,** because it encom-

From the Department of Surgery, University of California Davis Medical Center, Sacramento, CA.

Dr. Cocanour is the DSMP for a study of the drug Octaplast by Octapharma. Dr. Phan has not disclosed any potential conflicts of interest.

For information regarding this article, E-mail: ho.phan@ucdmc.ucdavis.edu

Copyright © 2010 by the Society of Critical Care Medicine and Lippincott Williams & Wilkins

DOI: 10.1097/CCM.0b013e3181ec667f

passes all forms of this potentially devastating infection.

## Classification

Skin and soft tissue infections are classified in numerous ways and often for specific reasons. For purposes of evaluating new therapeutics for the treatment of soft tissue infections, the Food and Drug Administration classifies soft tissue infections into two broad categories: uncomplicated and complicated. Uncomplicated soft tissue infections include superficial infections, such as cellulitis, impetiginous lesions, furuncles, and simple abscesses, that can be treated with surgical incision alone. Complicated soft tissue infections, such as infected ulcers, infected burns, and major abscesses, require significant surgical interventions. Interestingly, NSTI is generally an exclusion criterion for clinical therapeutic trials, so new antibiotics are not usually tested on NSTI. A more useful classification divides soft tissue infections into either nonnecrotizing or necrotizing infections. It is important to differentiate necrotizing infections from nonnecrotizing infections, as necrotizing infections require aggressive surgical management. Necrotizing infections can further be divided into specific types based on anatomy (e.g., Fournier's, Ludwig's angina), depth of involvement (e.g., necrotizing adipositis, fasciitis, or myositis), microbial source of infection (types 1/2/3), or even a combination of microbial source and depth (i.e., clostridial cellulitis, non-clostridial anaerobic cellulitis).

## Microbiology

Three basic microbial subtypes have been described. Type 1 infections are polymicrobial in nature and are the most prevalent form of NSTI, occurring in 55% to 75% of NSTIs. Type 2 infections are monomicrobial and are caused by group A *Streptococcus*. Some authors also consider monomicrobial infections due to community-associated methicillin-resistant *Staphylococcus aureus* (MRSA) as type 2 (3). Type 3 infections are also monomicrobial and are attributed to *Clostridium* species or rare virulent microbes, such as *Vibrio vulnificus* or *Aeromonas* species (3, 15).

Type 1 infections are a mix of aerobic and anaerobic bacteria and average 4.4 isolates per specimen (16). The predominant aerobic isolates are *Streptococcus*

spp., *Staphylococcus* spp., *Enterococcus* spp., and Enterobacteriaceae family (*Escherichia coli*, *Acinetobacter* spp., *Pseudomonas* spp., and *Klebsiella* spp.). *Bacteroides* spp. are the most common anaerobic organisms. *Clostridium* spp. are common participants in polymicrobial infections but are not necessarily causative of myonecrosis. Fungal species are occasional pathogens (16, 17).

Polymicrobial NSTIs tend to occur on the perineum and trunks of immunocompromised patients. Fournier's gangrene is a classic example of polymicrobial NSTI. Diabetes and peripheral vascular disease are common predisposing factors in polymicrobial NSTI (18). Other predisposing factors include obesity, chronic renal failure, human immunodeficiency virus infection, alcohol abuse, abscess, intravenous (IV) drug use, insect bites, recent surgical incisions, and perforation of the gastrointestinal tract (3, 19, 20). Interestingly, an inciting event is never identified in 20% to 50% of the patients (17, 21, 22).

Another example of type 1 NSTI is cervical necrotizing fasciitis. Bacterial penetration into the fascial compartments of the head and neck results in a rapidly progressive gangrenous cellulitis with life-threatening airway obstruction. It is most often associated with an odontogenic infection (78% to 90%), but other causes include trauma, tongue piercing, neoplasm, and other parapharyngeal infections (23–26). Both Ludwig's angina (submandibular space infection) and cervical necrotizing fasciitis are usually caused by mouth anaerobes, such as *Fusobacterium* spp., anaerobic *Streptococcus* spp., *Peptostreptococcus* spp., *Bacteroides* spp., and spirochetes, which are usually susceptible to penicillin and clindamycin.

Type 2 NSTIs are caused by group A *Streptococcus* (*Streptococcus pyogenes*) either alone or in association with *S. aureus*. In up to half of cases, type 2 infections may be accompanied by toxic shock syndrome (27, 28). In contrast to type 1 NSTI, type 2 NSTI can occur in any age group and without predisposing medical conditions (17). Predisposing factors include a history of trauma, IV drug use, surgical procedures, childbirth, burns, exposure to a case, and, potentially, nonsteroidal anti-inflammatory drugs (NSAIDs) (29, 30).

Over the last 10 yrs, MRSA has been increasingly seen as a monomicrobial cause of NSTI. The community-associ-

ated MRSA that is overwhelmingly associated with NSTI is clone USA300 containing the Panton-Valentine leukocidin cytotoxin (31). In some communities, this community-associated MRSA is responsible for >15% of NSTI (30). Although community-associated MRSA most commonly causes necrotizing infection of the subcutaneous tissue and skin, more severe invasive diseases, such as necrotizing fasciitis and pyomyositis, are increasingly being reported (31, 32).

Clostridial infections have been classified by some as type 3 NSTIs (15). *Clostridium* spp. are Gram-positive, spore-forming anaerobic rods normally found in soil and the gastrointestinal tract. Clostridial infections are classically associated with trauma or surgery. As surgical technique and wound care have improved, clostridial infections have decreased and are more likely now to be associated with wounds from IV drug abuse (21, 33, 34). *Clostridium perfringens* is the cause of 70% to 80% of clostridial infections (35). Its local and systemic manifestations are due to the production of potent extracellular toxins. Alpha toxin (a phospholipase C) and theta toxin (perfringolysin) are the two most potent proteins causing hemolysis, microvascular thrombosis, and myonecrosis (35). Alpha toxin directly inhibits myocardial contractility and indirectly induces systemic cytokine expression, which may contribute to the circulatory collapse commonly seen with this infection (35).

Spontaneous gas gangrene is a rare clostridial infection caused by the hematogenous spread of *Clostridium septicum* from the gastrointestinal tract in patients with a perforation from colon cancer or diverticulitis (36).

Members of the Vibrionaceae family, *V. vulnificus* and *Aeromonas* spp., are rare but potentially lethal causes of NSTI. *Vibrio vulnificus* is endemic to warm coastal waters and raw seafood, whereas *Aeromonas* spp. are found in fresh or brackish water, soil, or wood (37–39). Patients at greatest risk seem to be those with underlying hepatic dysfunction, diabetes, and other immunocompromised conditions (39–42).

The clinical signs and symptoms of *Vibrio vulnificus* and *Aeromonas* NSTIs are similar. Patients with hemorrhagic bullae, subcutaneous bleeding, purpura, necrosis, and gangrene who present with a fulminating course should raise suspicion of these entities. Clinical history

should help differentiate the potential source, as exposure to seawater or shellfish would suggest *Vibrio* species, whereas exposure to fresh or brackish water, soil, or wood would point to *Aeromonas* spp. Treatment usually requires aggressive debridement, especially in those patients with hypotensive shock, leukopenia, severe hypoalbuminemia, and underlying chronic illness, especially a combination of hepatic dysfunction and diabetes mellitus (37). These infections are aggressive, resulting in a high rate of amputation and mortality.

Zygomycosis (most familiar as mucormycosis) is an uncommon but potentially devastating cause of NSTI. The zygomycete fungi are ubiquitous and found in soil, manure, plants, and decaying material (43). The genera most commonly found in human infections are *Mucor*, *Rhizopus*, and *Cunninghamella* (44). Cutaneous zygomycosis is associated with trauma and burn wounds and has mortality rates ranging from 38% to 80% (45, 46). Patients who develop cutaneous zygomycosis from minor breaks in the skin almost always have an underlying disease, causing immunosuppression (43, 47, 48). Treatment of cutaneous zygomycosis requires aggressive debride-

ment, antifungal therapy, and elimination of predisposing factors for infection, such as hyperglycemia, metabolic acidosis, deferoxamine administration, and neutropenia. Deferoxamine, which chelates both iron and aluminum, stimulates fungal growth and promotes tissue invasion (49, 50).

### Clinical presentation

The presentation of NSTI varies widely, ranging from skin and subcutaneous necrosis to life-threatening sepsis with muscle and fascial involvement. Although necrotizing infection leads to massive destruction of tissues, the initial presentation is not always obvious, because it may involve only the deep tissues in the early phases, leaving the overlying skin appearing normal. This makes the diagnosis of NSTI very difficult. It is important to recognize NSTI early, because delay in the diagnosis and treatment is associated with extensive tissue destruction, limb loss, and mortality (28, 51–55).

Localized pain may be the earliest symptom of NSTI (53, 54). Pain out of proportion to the physical appearance should raise the suspicion of NSTI. Other clinical manifestations may be edema be-

yond the area of erythema, skin anesthesia, epidermolysis, and bronzing of the skin (Table 1, Fig. 1A). Hemorrhagic bullae, crepitus, foul odor, “dishwater” drainage, and dermal gangrene are late manifestations and are usually associated with systemic sepsis and organ dysfunction (56). An apparent superficial cellulitis that progresses rapidly, fails to respond to standard therapy, or is associated with evolving systemic signs of sepsis must raise the suspicion of a more extensive underlying infection.

There are multiple risk factors associated with NSTI (Table 2). These include advanced age (>60 yrs), IV drug use, diabetes mellitus, obesity, malnutrition, congestive heart disease, chronic pulmonary disease, peripheral vascular disease, chronic alcoholism, and immunocompromised states, such as malignancy, steroid use, transplantation, and human immunodeficiency virus infection (56–58). Several studies (57, 59, 60) have demonstrated that IV and subcutaneous injection of illicit drugs is the greatest risk factor for NSTI in the urban setting. Thus, soft tissue infection in a patient with a recent history of injection should raise the suspicion of more extensive underlying necrotizing infection. It is also important to note that NSTI do occur in healthy individuals as much as 30% of the time (61).

The reported sites of soft tissue infections vary depending on the series (56, 57, 61). The most common site of infection is the extremity, followed by perineum and buttocks, trunk, and head and neck. The cause of NSTI is not always obvious and usually involves tissue damage. The reported etiologies are injection of illicit substances, cutaneous infection or ulceration, postoperative infection, perirectal abscesses, soft tissue trauma, strangul-

Table 1. Clinical findings of necrotizing soft tissue infections

Early Physical Findings	Late Physical Findings
Pain out of proportion to examination	Hemorrhagic bullae
Erythema	Foul odor
Hyperthermia	Brownish-tan “dishwater” drainage
Edema beyond the area of erythema	Dermal gangrene
Skin anesthesia	Crepitus
Epidermolysis	Severe pain out of proportion to exam
Bronzing of the skin	Rapid progression of erythema, edema, pain
Tachycardia	Systemic inflammatory response syndrome
Fever	Sepsis
	Shock and organ failure

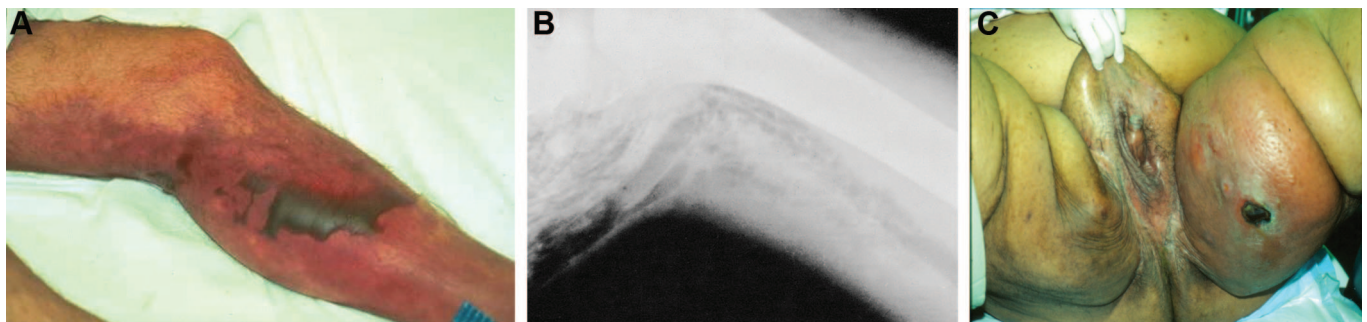


Figure 1. A, Skin changes associated with necrotizing infection of the lower extremity. The presence of cellulitis, bronzing of the skin, and hemorrhagic bullae, as well as extreme pain and tenderness, is highly suggestive of necrotizing soft tissue infection. B, Subcutaneous air is sometimes present in necrotizing soft tissue infection. The presence of gas together with the suspicious clinical picture is diagnostic. C, Fournier's gangrene. Courtesy of Dr. Lewis Kaplan.



Table 2. Risk factors for necrotizing soft tissue infections

Risk Factors
Advanced age (>60 yrs)
Intravenous drug use
Diabetes mellitus
Obesity
Malnutrition
Congestive heart disease
Chronic pulmonary disease
Peripheral vascular disease
Chronic alcoholism
Immunocompromised states
Malignancy
Steroid use
HIV infection/AIDS
Transplantation

HIV, human immunodeficiency virus; AIDS, acquired immunodeficiency syndrome.

Table 3. The Laboratory Risk Indicator for Necrotizing Fasciitis score

Variables, Units	Score
C-reactive protein, mg/L	
<150	0
≥150	4
Total white cell count, per mm <sup>3</sup>	
<15	0
15–25	1
>25	2
Hemoglobin, g/dL	
>13.5	0
11–13.5	1
<11	2
Sodium, mmol/L	
≥135	0
<135	2
Creatinine, μmol/L	
≤141	0
>141	2
Glucose, mmol/L	
≤10	0
>10	1

lated hernias, perforated viscus, colostomy site infection, and idiopathic causes (57, 62, 63). The association between NSAIDs and NSTI has also been shown (64–66). However, it is unclear whether this link is attributable to the immunomodulatory effect of NSAIDs or is related to the fact that NSAIDs are used by patients with NSTI to suppress fever and pain. Nevertheless, NSAIDs may mask the usual signs of inflammation and thereby delay the diagnosis.

## Diagnosis

Early diagnosis of NSTI is difficult because early clinical cutaneous manifestations may not be distinguishable from simple superficial infection. There are

several methods proposed for the early diagnosis of NSTI. One such method is the Laboratory Risk Indicator for Necrotizing Fasciitis (LRINEC) score by Wong et al (67). The score was retrospectively devised based on six common clinical parameters: serum C-reactive protein, white blood cell count, hemoglobin concentration, serum sodium measurement, serum creatinine level, and serum glucose level (Table 3). According to the authors, a minimum score of 6 is associated with necrotizing fasciitis, with a positive predictive value of 92% and negative predictive value of 96%. Since the development of the LRINEC score, a few cohort studies attempted to validate its clinical use for the diagnosis of NSTI. In one study, Su et al (68) retrospectively reviewed 209 patients with a confirmed diagnosis of necrotizing fasciitis and showed that only 100 (48%) of 209 had an LRINEC score of ≥6. However, these authors also demonstrated that the group of patients with LRINEC scores of ≥6 had a higher rate of amputation and mortality compared with the group with LRINEC scores of <6. This study suggests that the LRINEC score is helpful in prognosticating, but not diagnosing, NSTI. In a more recent cohort study of a much smaller scale (n = 28 patients), the LRINEC score was found to have a sensitivity of 80%, specificity of 67%, a positive predictive value of 57%, and a negative predictive value of 86% (69). The sensitivity and specificity reported here are much smaller than those proposed by Wong et al. Mills et al (7) recently reported that leukocytosis and hyponatremia occur simultaneously in only 22% of patients with NSTI entered in the National Surgical Quality Improvement Program database, suggesting that the sensitivity of these parameters for the detection of NSTI is low. The major drawback of the LRINEC scoring system is that it is derived from retrospective data and is therefore predisposed to selection bias. To date, the LRINEC score has not been prospectively validated and should not be recommended for routine application.

Imaging studies, such as conventional radiographs and computed tomography, are helpful only if there is gas in the tissue (Fig. 1B). The presence of gas in the tissue, together with a suspicious clinical presentation, is diagnostic of NSTI. However, radiographic detection of subcutaneous emphysema is seen in only 39% of patients with NSTI (70). A computed tomography scan is very sensitive

in detecting inflammatory changes but is not necessarily specific for necrotizing infection. However, a computed tomography scan is helpful in the diagnosis of deep abscesses, especially intramuscular abscesses that otherwise cannot be diagnosed with physical examination. Magnetic resonance imaging with gadolinium contrast enhancement can accurately differentiate between necrotizing infection and nonnecrotizing infection (71). Unfortunately, the time it takes to obtain a magnetic resonance imaging scan, especially in an unstable septic patient who may be undergoing aggressive resuscitation, cannot be justified. A magnetic resonance imaging scan is not always readily accessible in many facilities. Furthermore, a magnetic resonance imaging scan requires patient compliance and any movement by the patient during the study may render a very time-consuming study noninterpretable, thus delaying the diagnosis and treatment even further.

There has been some suggestion of bedside tissue biopsy for frozen section for the diagnosis of NSTI (72). The diagnosis is made based on histologic changes that include tissue necrosis, polymorphonuclear infiltration, fibrinous vascular thrombosis, and sometimes microorganisms within the destroyed tissue. Although the reported series shows this method to be reliable, the experience is limited. Furthermore, a pathologist is not always readily available at night for the interpretation of the frozen section, and waiting until the next day is not a viable option.

Aspiration of the fluid for the detection of organisms by Gram-negative stain and cultures has also been suggested (73). However, the presence of organisms does not necessarily equate to a necrotizing infection and is not as reliable as taking deep tissue samples at the time of surgical exploration. Likewise, failure to obtain fluid is nondiagnostic and does not rule out necrotizing infection. Cultures take too long to make a timely diagnosis of NSTI.

The diagnosis of NSTI, therefore, must be made clinically. The clinical history and a meticulous physical examination are essential to establish an early diagnosis. A clinical history and physical features that fit the above description should raise the suspicion of NSTI and prompt surgical exploration for a more definitive diagnosis and subsequent treatment.

## Management

The management of NSTI requires aggressive resuscitation, IV antibiotics, complete surgical debridement, and supportive care. All aspects of treatment should be started promptly and simultaneously. The single most important aspect of managing NSTI is complete debridement of necrotic and infected tissues. Early operative debridement is the major determinant of outcome (51, 52). Surgical debridement should never be delayed in hope of restoration of hemodynamic stability before anesthesia induction, because correction of the septic state will not occur until all of the infected and necrotic tissues have been removed.

## Surgical management

When NSTI is suspected, surgical exploration is indicated. This involves making an incision over the inflamed and tender area down toward the fascia. A change in the fascia from a tough and shiny white appearance to a dull gray fascia that can be easily separated from the fat with blunt dissection is indicative of necrotizing infection. The classically described brownish-tan "dishwater" fluid weeping from the tissues, if present, is also highly suggestive of NSTI. The underlying muscles should also be closely examined by making an incision in the fascia, whether or not the fascia appears normal. All necrotic fascia and muscles, as well as the overlying skin, should be excised. The excision margin should be healthy bleeding tissue with a normal appearance. The patient's ultimate outcome depends on the completeness of surgical debridement. This sometimes means amputation of the affected limb, if there is extensive soft tissue loss for any reasonable functional recovery or if there is destruction of the major nerves and blood vessels. Under no circumstance should the wounds be closed at the time of surgical debridement. The wound should be left open and packed for open drainage and ease of re-exploration.

Perineal gangrene often involves the scrotum and perianal skin. Surgical debridement usually involves excision of the scrotal skin and perineal skin extending to the gluteal region. The testicles are usually spared and orchiectomy is rarely required.

After adequate surgical debridement, the patient's hemodynamic status should

improve significantly. The patient's wound should be re-explored in the operating room within 24 hrs to evaluate whether the spread of infection has been stopped and if further debridement is required. All newly identified necrotic tissue should be aggressively debrided. In patients whose clinical condition continues to deteriorate, re-exploration should be considered sooner, because there is a very high likelihood that the initial debridement is inadequate or the infection has spread even further. The goal of surgical therapy is complete debridement with the initial operation. However, it is not at all uncommon that multiple debridements are required. In one study (57), 64% of the patients required at least one other debridement.

Surgical debridement is usually extensive and involves significant blood loss. Therefore, part of the preoperative work-up should include type and cross for red blood cells. Many of these patients are coagulopathic, and efforts should be made to correct the coagulopathy with plasma infusion during surgery to minimize blood loss. Hypothermia should also be avoided, because a large surface area is usually exposed and large areas of skin are excised.

## Critical care management

As soon as the diagnosis of NSTI is suspected, immediate fluid resuscitation should begin. Many of these patients are intravascularly depleted and are often in acute renal failure. Aggressive initial fluid resuscitation will help restore intravascular volume, maintain adequate end-organ perfusion and tissue oxygenation, and limit the adverse effects of end-organ failure. The magnitude of resuscitation is dependent on the individual patient's physiologic status and should be targeted to provide adequate perfusion to the organs. For patients who are in shock or who have underlying cardiac or pulmonary disease, consider the use of a central venous catheter or pulmonary arterial catheter to guide fluid management.

The initial IV antibiotic therapy should be broad enough to cover the diverse and various causative agents. High-dose penicillin G or ampicillin should be used to cover for potential *Clostridium*, *Streptococcus*, and *Peptostreptococcus* infections. Penicillin G, if chosen, should be given as 18–24 million units per day for an adult. Anaerobes such as *Bacteroides*, *Fusobacterium*, and *Peptostrepto-*

*coccus* should also be covered with clindamycin or metronidazole. Clindamycin is also effective in treating group A  $\beta$ -hemolytic *Streptococcus* by suppressing the production of exotoxins (74). Clindamycin is also the drug of choice for patients allergic to penicillin. Gram-negative coverage can be achieved by adding an aminoglycoside, a third- or fourth-generation cephalosporin, a fluoroquinolone, or a carbapenem. Alternatively, penicillin or ampicillin can be replaced by piperacillin-tazobactam or ticarcillin-clavulanate to include Gram-negative coverage.

Selection of antimicrobials that inhibit toxin production should be considered in patients with streptococcal, clostridial, and staphylococcal infections, especially those with evidence of rapidly progressive or severe infections. Clindamycin, erythromycin, and linezolid are potential inhibitory agents, provided that the pathogen is sensitive to the antibiotic. Protein cytotoxins play a significant role in the pathogenesis of staphylococcal infections (75). Phenol-soluble modulins peptides are *Staphylococcus*-secreted peptides that recruit, activate, and lyse human neutrophils, thus eliminating a main cellular defense against staphylococcal infection (76).  $\beta$ -Lactams actually enhance toxin production, whereas both clindamycin and linezolid inhibit toxin production by suppressing translation but not transcription of *S. aureus* toxin genes and directly inhibiting synthesis of group A *Streptococcus* toxins (75). When patients exhibit signs and symptoms of shock, coagulopathy, and organ failure, antitoxin antimicrobials should be promptly initiated.

Because of the recent increase in the prevalence of community-associated MRSA necrotizing infection, vancomycin or clindamycin should be considered for use in the initial antibiotic regimen in suspected cases. Clinicians should also be aware that there is not only an increase in frequency of MRSA isolates but also a shift of the vancomycin minimum inhibitory concentration. In a study from Houston over a 6-yr period, over a third of MRSA isolates had a minimum inhibitory concentration of  $\geq 1$   $\mu$ g/mL, and nearly a third of isolates had a minimum inhibitory concentration of 2  $\mu$ g/mL (77). Treatment failure rates for MRSA infections with increased minimum inhibitory concentration are increasingly being reported (78, 79).

The antibiotic recommendation for *Vibrio* and *Aeromonas* infections is high-

dose combination therapy that includes a cell wall active agent (third-generation cephalosporins, carbapenems, fluoroquinolones) plus either tetracycline or minocycline (protein synthesis inhibitor) (80).

When **invasive zygomycosis** has been demonstrated, **amphotericin B** or equivalent liposomal formulation should be started. The liposomal formulation allows higher dosing with less nephrotoxicity. **Echinocandins** have **no *in vitro* activity** against the **zygomycetes** (81–83). Posaconazole, which is a broad-spectrum oral azole agent with *in vitro* activity against the zygomycetes, may be considered for combination therapy with amphotericin B or can be used as step-down therapy for patients who have responded to amphotericin B. It is rarely used as salvage therapy for those who do not respond to or cannot tolerate amphotericin B (84–86).

**Antibiotics** should be **adjusted** as **early** as possible to **only cover** the **causative agents** once they have been identified. The identification of causative agents and their antibiotic susceptibilities is key information obtained at the time of surgical debridement that will guide antimicrobial therapy.

The use of **IV immunoglobulin (IVIG)** for the treatment of NSTI has also been advocated by some authors. The rationale is that **IVIG provides antibodies** that can **neutralize the circulating streptococcal exotoxins**, thus reducing the toxin-induced tissue necrosis (87, 88). In addition, IVIG **may also** have an **effect** on the **circulating cytokines**, thereby controlling the systemic inflammatory response. Although there are some retrospective as well as prospective studies showing a potential benefit in the use of IVIG in NSTI, additional studies are required before it can be recommended for routine use in NSTI (89–91).

**Hyperbaric oxygen (HBO)** therapy has also been proposed as an adjunctive therapy for NSTI. This treatment modality remains **controversial**, as many studies evaluating the benefit of HBO as an adjunctive therapy in NSTI show **conflicting results**. A number of small series (92–96) evaluated the role of HBO as an adjunctive therapy for severe, life- or limb-threatening necrotizing infection. They showed a potential mortality benefit and a decrease in the extent of debridement in patients treated with HBO. In contrast, **other similar series (97, 98) reported higher mortality with HBO therapy**. In a

more recent series, a total of 78 patients with NSTI were reviewed: 48 patients received adjunctive HBO compared with 30 patients who received conventional therapy. These authors **did not identify any statistically significant differences** in mortality between the two groups. The hospital lengths of stay and durations of antibiotic use were also similar between the two groups. **Interestingly, the number of debridements was greater in the HBO group**. These authors concluded that adjunctive use of HBO to treat NSTI did not reduce the mortality rate, number of debridements, hospital length of stay, or duration of antibiotic use (99). **To date, there is no randomized, controlled trial evaluating the effect of HBO therapy as an adjunct in the treatment of NSTI in humans**.

Supportive care of the patient is extremely important. Nutritional support should be started as soon as the patient can tolerate nourishment. If the patient can take food by mouth, it is the preferred route. If the patient is intubated or is unable to obtain adequate caloric intake orally, enteral feedings *via* nasogastric or nasoduodenal feeding tube is preferred over parenteral nutrition. When calculating total caloric requirement, a consideration should be given to the fact that **these patients will have an increase in caloric and protein demands due to the large protein loss through the open wounds** and the **hypermetabolic state**. Appropriate vitamins, such as **vitamins A and C**, and minerals like **zinc** should be given to patients with large open wounds to facilitate wound healing. Rehabilitation should be started as soon as the patient is stable and able to participate. Early mobilization will help minimize pulmonary complications and deconditioning.

### Wound management

Once surgical debridement is no longer required, **wound care can be done at the patient's bedside**. Because these wounds are so extensive, the patients usually require large doses of narcotics for dressing changes. Wound dressing is best done with **moist saline gauze**. **Topical antimicrobial therapy is not necessary** and is never a substitute for adequate surgical debridement. Agents like silver nitrate and **silver sulfadiazine** will **alter the appearance** of the wound, making it difficult to be examined. **Betadine should not be used** on an **open** wound, as it will

**cause cell damage and inhibit wound healing**. **Perineal wounds** are especially **difficult to manage**, because **soilage of the wound** is frequent. However, **stool diversion by colostomy is rarely required**. Meticulous wound care is all that is required even with the most difficult wounds. When the wound is **clean**, use of a **vacuum wound dressing** is an option to facilitate wound granulation.

For the majority of the wounds, closure is achieved with **simple split-thickness skin grafts**. More complex wounds should be managed in conjunction with the **plastic surgery team**. **Wound coverage** should be done when the patient is medically stable and the wound is **free from infection**. It is **not necessary** to **wait for granulation tissue** to fill the entire wound bed for split-thickness skin **grafts**, as the **grafts will take as long as there is a clean and vascularized bed** that is free from infection. **Early coverage** of the wound is advantageous in that it will help **decrease pain** associated with dressing changes and **decrease metabolic demands**.

For **perineal wounds** that involve the scrotum, the best cosmetic result can be achieved by **delayed primary closure** of the wound, if it is small. If the wound is **too large** for primary closure, it should **not be allowed to heal by secondary intention**, as this will lead to **contracture deformity of the scrotum**. Several scrotal reconstruction methods have been described, including **musculocutaneous flap** and **fasciocutaneous flaps** from the **thigh** and the **abdomen** (100–102). Direct split-thickness skin grafts over the denuded testicles have also been described to provide good cosmetic and functional outcome, with the additional advantage of being a single-stage operation (103, 104). A simple and widely used method is **placement of the testicles in subcutaneous pockets in the thigh**. It is functionally acceptable, but cosmetically suboptimal. Many surgeons use this technique for **temporary coverage**, which can be **revised later** with other reconstructive methods (103).

### CONCLUSION

NSTI is an aggressive disease and is associated with significant morbidity and mortality. It is **very important** to **differentiate necrotizing infection from nonnecrotizing infection** early, so that necrotizing infection can be **aggressively treated** to minimize tissue loss, and loss



of limb and life. **Complete surgical debridement is the key to success.** The initial empirical antibiotic therapy should be broad to include coverage for all potential causative agents, and subsequently narrowed once the offending organisms are identified. Adjunctive therapies, such as **IVIG and HBO, are not currently recommended for routine use.**

## REFERENCES

- Descamps V, Aitken J, Lee MG: Hippocrates on necrotising fasciitis. *Lancet* 1994; 344: 556
- Ellis Simonsen SM, van Orman ER, Hatch BE, et al: Cellulitis incidence in a defined population. *Epidemiol Infect* 2006; 134: 293–299
- Sarani B, Strong M, Pascual J, et al: Necrotizing fasciitis: Current concepts of the literature. *J Am Coll Surg* 2009; 208:279–288
- Endorf FW, Klein MB, Mack CD, et al: Necrotizing soft-tissue infections: Differences in patients treated at burn centers and non-burn centers. *J Burn Care Res* 2008; 29: 933–938
- George SMC, Harrison DA, Welch CA, et al: Dermatological conditions in intensive care: A secondary analysis of the Intensive Care National Audit & Research Centre (IC-NARC) Case Mix Programme Database. *Crit Care* 2008; 12:S1
- May AK: Skin and soft tissue infections. *Surg Clin North Am* 2009; 89:403–420
- Mills MK, Faraklas I, Davis C, et al: Outcomes from treatment of necrotizing soft-tissue infections: Results from the national surgical quality improvement (NSQIP) database. Presented, in part, at the 62nd annual meeting of the Southwestern Surgical Congress, Tucson, AZ, March 22, 2010
- Baurienne H: Sur une plaie contuse qui s'est terminée par la sphacèle de la scrotum. *J Med Chir Pharm* 1764; 20:251–256
- Fournier JA: Gangrène foudroyante de la verge. *Med Pract* 1883; 4:589–597
- Fournier JA: Etude clinique de la gangrène foudroyante de la verge. *Semaine Med* 1884; 4:69
- Jones J: Surgical memoirs of the war of the rebellion: Investigation upon the nature, causes, and treatment of hospital gangrene as prevailed in the Confederate armies 1861–1865. New York, U.S. Sanitary Commission, 1871
- Brewer GE, Meleney FL: Progressive gangrenous infection of the skin and subcutaneous tissues, following operation for acute perforative appendicitis: A study in symbiosis. *Am Surg* 1926; 84:438–450
- Davson J, Jones DM, Turner L: Diagnosis of Meleney's synergistic gangrene. *Br J Surg* 1988; 75:267–271
- Wilson B: Necrotizing fasciitis. *Am Surg* 1952; 18:416–431
- Napolitano LM: Severe soft tissue infections. *Infect Dis Clin North Am* 2009; 23: 571–591
- Elliott D, Kufera JA, Myers RA: The microbiology of necrotizing soft tissue infections. *Am J Surg* 2000; 179:361–366
- Wong CH, Chang HC, Pasupathy S, et al: Necrotizing fasciitis: Clinical presentation, microbiology, and determinants of mortality. *J Bone Joint Surg Am* 2003; 85-A: 1454–1460
- Freischlag JA, Ajalat G, Busuttill RW: Treatment of necrotizing soft tissue infections. The need for a new approach. *Am J Surg* 1985; 149:751–755
- Piedra T, Martín-Cuesta L, Arnáiz J, et al: Necrotizing fasciitis secondary to diverticulitis. *Emerg Radiol* 2007; 13:345–348
- Liu SY, Ng SS, Lee JF: Multi-limb necrotizing fasciitis in a patient with rectal cancer. *World J Gastroenterol* 2006; 12:5256–5258
- Anaya DA, McMahon K, Nathens AB, et al: Predictors of mortality and limb loss in necrotizing soft tissue infections. *Arch Surg* 2005; 140:151–158
- Childers BJ, Potyondy LD, Nachreiner R, et al: Necrotizing fasciitis: A fourteen-year retrospective study of 163 consecutive patients. *Am Surg* 2002; 68:109–116
- Bansal A, Miskoff J, Lis RJ: Otolaryngologic critical care. *Crit Care Clin* 2003; 19:55–72
- Saifeldien K, Evans R: Ludwig's angina. *Emerg Med J* 2004; 21:242–243
- Spitalnic SJ, Sucov A: Ludwig's angina: Case report and review. *J Emerg Med* 1995; 13:499–503
- Quinn FB Jr: Ludwig angina. *Arch Otolaryngol Head Neck Surg* 1999; 125:599
- Darenberg J, Luca-Harari B, Jasir A, et al: Molecular and clinical characteristics of invasive group A streptococcal infection in Sweden. *Clin Infect Dis* 2007; 45:450–458
- Chelsom J, Halstensen A, Haga T, et al: Necrotising fasciitis due to group A streptococci in western Norway: Incidence and clinical features. *Lancet* 1994; 344: 1111–1115
- Hasham S, Matteucci P, Stanley PR, et al: Necrotising fasciitis. *BMJ* 2005; 330: 830–833
- Eneli I, Davies HD: Epidemiology and outcome of necrotizing fasciitis in children: An active surveillance study of the Canadian Paediatric Surveillance Program. *J Pediatr* 2007; 151:79–84, 84.e.1
- Young LM, Price CS: Community-acquired methicillin-resistant *Staphylococcus aureus* emerging as an important cause of necrotizing fasciitis. *Surg Infect* 2008; 9:469–474
- Wallin TR, Hern HG, Frazee BW: Community-associated methicillin-resistant *Staphylococcus aureus*. *Emerg Med Clin North Am* 2008; 26:431–455
- Brett MM, Hood J, Brazier JS, et al: Soft tissue infections caused by spore-forming bacteria in injecting drug users in the United Kingdom. *Epidemiol Infect* 2005; 133:575–582
- Kimura AC, Higa JI, Levin RM, et al: Outbreak of necrotizing fasciitis due to *Clostridium sordellii* among black-tar heroin users. *Clin Infect Dis* 2004; 38:e87–e91
- Stevens DL, Bryant AE: Pathogenesis of *Clostridium perfringens* infection: Mechanisms and mediators of shock. *Clin Infect Dis* 1997; 25(Suppl 2):S160–S164
- Chew SS, Lubowski DZ: *Clostridium septicum* and malignancy. *Aust N Z J Surg* 2001; 71:647–649
- Tsai YH, Hsu RWW, Huang TJ, et al: Necrotizing soft tissue infections and sepsis caused by *Vibrio vulnificus* compared with those caused by *Aeromonas* species. *J Bone Joint Surg Am* 2007; 89:631–636
- Chiang SR, Chuang YC: *Vibrio vulnificus* infection: Clinical manifestations, pathogenesis, and antimicrobial therapy. *J Microbiol Immunol Infect* 2003; 36:81–88
- Ko WC, Lee HC, Chuang YC, et al: Clinical features and therapeutic implications of 104 episodes of monomicrobial *Aeromonas* bacteraemia. *J Infect* 2000; 40:267–273
- Gold WL, Salit IE: *Aeromonas* hydrophilia infections of skin and soft tissue: Report of 11 cases and review. *Clin Infect Dis* 1993; 16:69–74
- Tsai YH, Hsu RW, Hung KC, et al: Systemic *Vibrio* infection presenting as necrotizing fasciitis and sepsis. A series of thirteen cases. *J Bone Joint Surg Am* 2004; 86-A: 2497–2502
- Ko WC, Chuang YC: *Aeromonas* bacteraemia: Review of 59 episodes. *Clin Infect Dis* 1995; 20:1298–1304
- Eucker J, Sezer O, Graf B, et al: Mucormycosis. *Mycoses* 2001; 44:253–260
- Roden MM, Zaoutis TE, Buchanan WL, et al: Epidemiology and outcome of zygomycosis: A review of 929 reported cases. *Clin Infect Dis* 2005; 41:634–653
- Cocanour CS, Miller-Crotchett P, Reed RL 2nd, et al: Mucormycosis in trauma patients. *J Trauma* 1992; 32:12–15
- Patiño JF, Castro D, Valencia A, et al: Necrotizing soft tissue lesions after a volcanic cataclysm. *World J Surg* 1991; 15:240–247
- Adam RD, Hunter G, DiTomasso J, et al: Mucormycosis: Emerging prominence of cutaneous infections. *Clin Infect Dis* 1994; 19:67–76
- Loose JE, Selber J, Vega S, et al: Primary cutaneous mucormycosis: Guide to surgical management. *Ann Plast Surg* 2002; 49: 385–390
- Greenberg RN, Scott LJ, Vaughn HH, et al: Zygomycosis (mucormycosis): Emerging clinical importance and new treatments. *Curr Opin Infect Dis* 2004; 17:517–525
- Boelaert JR, de Locht M, Van Cutsem J, et al: Mucormycosis during deferoxamine therapy is a siderophore-mediated infection. *In vitro and in vivo* animal studies. *J Clin Invest* 1993; 91:1979–1986
- Majeski JA, Alexander JW: Early diagnosis, nutritional support, and immediate extensive debridement improve survival in necro-

- tizing fasciitis. *Am J Surg* 1983; 145: 784–787
52. McHenry CR, Piotrowski JJ, Petrinic D, et al: Determinants of mortality for necrotizing soft-tissue infections. *Ann Surg* 1995; 221:558–565
53. Stevens DL, Tanner MH, Winship J, et al: Severe group A streptococcal infections associated with a toxic shock-like syndrome and scarlet fever toxin A. *N Engl J Med* 1989; 321:1–7
54. Stone HH, Martin JD Jr: Synergistic necrotizing cellulitis. *Ann Surg* 1972; 175: 702–711
55. Stevens DL: Streptococcal toxic-shock syndrome: Spectrum of disease, pathogenesis, and new concepts in treatment. *Emerg Infect Dis* 1995; 1:69–78
56. Majeski JA, John JF Jr: Necrotizing soft tissue infections: A guide to early diagnosis and initial therapy. *South Med J* 2003; 96: 900–925
57. Bosshardt TL, Henderson VJ, Organ CH Jr: Necrotizing soft-tissue infections. *Arch Surg* 1996; 131:846–854
58. Elliott DC, Kufera JA, Myers RA: Necrotizing soft tissue infections. Risk factors for mortality and strategies for management. *Ann Surg* 1996; 224:672–683
59. Bangsberg DR, Rosen JI, Aragón T, et al: Clostridial myonecrosis cluster among injection drug users: A molecular epidemiology investigation. *Arch Intern Med* 2002; 162:517–522
60. McGuigan CC, Penrice GM, Gruer L, et al: Lethal outbreak of infection with *Clostridium novyi* type A and other spore-forming organisms in Scottish injecting drug users. *J Med Microbiol* 2002; 51:971–977
61. Ben-Abraham R, Keller N, Vered R, et al: Invasive group A streptococcal infections in a large tertiary center: Epidemiology, characteristics and outcome. *Infection* 2002; 30: 81–85
62. Chapnick EK, Abter EI: Necrotizing soft-tissue infections. *Infect Dis Clin North Am* 1996; 10:835–855
63. Lille ST, Sato TT, Engrav LH, et al: Necrotizing soft tissue infections: Obstacles in diagnosis. *J Am Coll Surg* 1996; 182:7–11
64. Forbes N, Rankin AP: Necrotizing fasciitis and non steroidal anti-inflammatory drugs: A case series and review of the literature. *N Z Med J* 2001; 114:3–6
65. Kahn LH, Styrt BA: Necrotizing soft tissue infections reported with nonsteroidal anti-inflammatory drugs. *Ann Pharmacother* 1997; 31:1034–1039
66. Stevens DL: Could nonsteroidal antiinflammatory drugs (NSAIDs) enhance the progression of bacterial infections to toxic shock syndrome? *Clin Infect Dis* 1995; 21: 977–980
67. Wong CH, Khin LW, Heng KS, et al: The LRINEC (Laboratory Risk Indicator for Necrotizing Fasciitis) score: A tool for distinguishing necrotizing fasciitis from other soft tissue infections. *Crit Care Med* 2004; 32:1535–1541
68. Su YC, Chen HW, Hong YC, et al: Laboratory risk indicator for necrotizing fasciitis score and the outcomes. *Aust N Z J Surg* 2008; 78:968–972
69. Holland MJ: Application of the Laboratory Risk Indicator in Necrotising Fasciitis (LRINEC) score to patients in a tropical tertiary referral center. *Anaesth Intensive Care* 2009; 37:588–592
70. Wall DB, de Virgilio C, Black S, et al: Objective criteria may assist in distinguishing necrotizing fasciitis from nonnecrotizing soft tissue infection. *Am J Surg* 2000; 179: 17–21
71. Brothers TE, Tagge DU, Stutley JE, et al: Magnetic resonance imaging differentiates between necrotizing and non-necrotizing fasciitis of the lower extremity. *J Am Coll Surg* 1998; 187:416–421
72. Majeski J, Majeski E: Necrotizing fasciitis: improved survival with early recognition by tissue biopsy and aggressive surgical treatment. *South Med J* 1997; 90:1065–1068
73. Lee PC, Turnidge J, McDonald PJ: Fine-needle aspiration biopsy in diagnosis of soft tissue infections. *J Clin Microbiol* 1985; 22: 80–83
74. Stevens DL, Bryant AE, Yan S: Invasive group A streptococcal infection: New concepts in antibiotic treatment. *Int J Antimicrob Agents* 1994; 4:297–301
75. Stevens DL, Ma Y, Salmi DB, et al: Impact of antibiotics on expression of virulence-associated exotoxin genes in methicillin-sensitive and methicillin-resistant *Staphylococcus aureus*. *J Infect Dis* 2007; 195: 202–211
76. Wang R, Braughton KR, Kretschmer D, et al: Identification of novel cytolytic peptides as key virulence determinants for community-associated MRSA. *Nat Med* 2007; 13: 1510–1514
77. Awad SS, Elhabash SI, Lee L, et al: Increasing incidence of methicillin-resistant *Staphylococcus aureus* skin and soft tissue infections: Reconsideration of empiric antimicrobial therapy. *Am J Surg* 2007; 194: 606–610
78. Hidayat LK, Hsu DI, Quist R, et al: High-dose vancomycin for methicillin-resistant *Staphylococcus aureus* infections: efficacy and toxicity. *Arch Intern Med* 2006; 166: 2138–2144
79. Howden BP, Ward PB, Charles PG, et al: Treatment outcomes for serious infections caused by methicillin-resistant *Staphylococcus aureus* with reduced vancomycin susceptibility. *Clin Infect Dis* 2004; 38: 521–528
80. May AK, Stafford RE, Bulger EM, et al: Treatment of complicated skin and soft tissue infections. *Surg Infect (Larchmt)* 2009; 10:467–499
81. Espinel-Ingroff A: Comparison of in vitro activities of the new triazole SCH56592 and the echinocandins MK-0991 (L-743,872) and LY303366 against opportunistic filamentous and dimorphic fungi and yeasts. *J Clin Microbiol* 1998; 36:2950–2956
82. Pfaller MA, Marco F, Messer SA, et al: In vitro activity of two echinocandin derivatives, LY303366 and MK-0991 (L-743,792), against clinical isolates of *Aspergillus*, *Fusarium*, *Rhizopus*, and other filamentous fungi. *Diagn Microbiol Infect Dis* 1998; 30: 251–255
83. Del Poeta M, Schell WA, Perfect JR: In vitro antifungal activity of pneumocandin L-743,872 against a variety of clinically important molds. *Antimicrob Agents Chemother* 1997; 41:1835–1836
84. Sun QN, Fothergill AW, McCarthy DI, et al: In vitro activities of posaconazole, itraconazole, voriconazole, amphotericin B, and fluconazole against 37 clinical isolates of zygomycetes. *Antimicrob Agents Chemother* 2002; 46:1581–1582
85. Spanakis EK, Aperis G, Mylonakis E: New agents for the treatment of fungal infections: Clinical efficacy and gaps in coverage. *Clin Infect Dis* 2006; 43:1060–1068
86. van Burik JA, Hare RS, Solomon HF, et al: Posaconazole is effective as salvage therapy in zygomycosis: A retrospective summary of 91 cases. *Clin Infect Dis* 2006; 42:e61–e65
87. Norrby-Teglund A, Basma H, Andersson J, et al: Varying titers of neutralizing antibodies to streptococcal superantigens in different preparations of normal polyspecific immunoglobulin G: Implications for therapeutic efficacy. *Clin Infect Dis* 1998; 26:631–638
88. Norrby-Teglund A, Kaul R, Low DE, et al: Plasma from patients with severe invasive group A streptococcal infections treated with normal polyspecific IgG inhibits streptococcal superantigen-induced T cell proliferation and cytokine production. *J Immunol* 1996; 156:3057–3064
89. Darenberg J, Ihendyane N, Sjolín J, et al: Intravenous immunoglobulin G therapy in streptococcal toxic shock syndrome: A European randomized, double-blind, placebo-controlled trial. *Clin Infect Dis* 2003; 37: 333–340
90. Kaul R, McGeer A, Norrby-Teglund A, et al: Intravenous immunoglobulin therapy for streptococcal toxic shock syndrome—A comparative observational study. The Canadian Streptococcal Study Group. *Clin Infect Dis* 1999; 28:800–807
91. Norrby-Teglund A, Muller MP, McGeer A, et al: Successful management of severe group A streptococcal soft tissue infections using an aggressive medical regimen including intravenous polyspecific immunoglobulin together with a conservative surgical approach. *Scand J Infect Dis* 2005; 37: 166–172
92. Brown DR, Davis NL, Lepawsky M, et al: A multicenter review of the treatment of major truncal necrotizing infections with and without hyperbaric oxygen therapy. *Am J Surg* 1994; 167:485–489



93. Green RJ, Dafoe DC, Raffin TA: Necrotizing fasciitis. *Chest* 1996; 110:219–229
94. Hollabaugh RS Jr, Dmochowski RR, Hickerson WL, et al: Fournier's gangrene: Therapeutic impact of hyperbaric oxygen. *Plast Reconstr Surg* 1998; 101:94–100
95. Pizzorno R, Bonini F, Donelli A, et al: Hyperbaric oxygen therapy in the treatment of Fournier's disease in 11 male patients. *J Urol* 1997; 158:837–840
96. Riseman JA, Zamboni WA, Curtis A, et al: Hyperbaric oxygen therapy for necrotizing fasciitis reduces mortality and the need for debridements. *Surgery* 1990; 108:847–850
97. Mindrup SR, Kealey GP, Fallon B: Hyperbaric oxygen for the treatment of Fournier's gangrene. *J Urol* 2005; 173:1975–1977
98. Shupak A, Shoshani O, Goldenberg I, et al: Necrotizing fasciitis: An indication for hyperbaric oxygenation therapy? *Surgery* 1995; 118:873–878
99. George ME, Rueth NM, Skarda DE, et al: Hyperbaric oxygen does not improve outcome in patients with necrotizing soft tissue infection. *Surg Infect (Larchmt)* 2009; 10:21–28
100. Parkash S, Gajendran V: Surgical reconstruction of the sequelae of penile and scrotal gangrene: A plea for simplicity. *Br J Plast Surg* 1984; 37:354–357
101. Banks DW, O'Brien DP 3rd, Amerson JR, et al: Gracilis musculocutaneous flap scrotal reconstruction after Fournier gangrene. *Urology* 1986; 28:275–276
102. Taguchi H: More than 10 years of experience with reconstructed scrotums. *J Urol* 1976; 116:469–471
103. Maguñiña P, Palmieri TL, Greenhalgh DG: Split thickness skin grafting for recreation of the scrotum following Fournier's gangrene. *Burns* 2003; 29:857–862
104. Vincent MP, Horton CE, Devine CJ Jr: An evaluation of skin grafts for reconstruction of the penis and scrotum. *Clin Plast Surg* 1988; 15:411–424