

*David S. Warner, M.D., Editor*

# Aerosolized Antibiotics for Ventilator-associated Pneumonia

## *Lessons from Experimental Studies*

Jean-Jacques Rouby, M.D, Ph.D.,\* Belaid Bouhemad, M.D, Ph.D.,† Antoine Monsel, M.D.,‡  
Hélène Brisson, M.D.,§ Charlotte Arbelot, M.D.,§ Qin Lu, M.D, Ph.D.§; and the Nebulized  
Antibiotics Study Group||

### ABSTRACT

The aim of this review is to perform a critical analysis of experimental studies on aerosolized antibiotics and draw lessons for clinical use in patients with ventilator-associated pneumonia. Ultrasonic or vibrating plate nebulizers should be preferred to jet nebulizers. During the nebulization period, specific ventilator settings aimed at decreasing flow turbulence should be used, and discoordination with the ventilator should be avoided. The appropriate dose of aerosolized antibiotic can be determined as the intravenous dose plus extrapulmonary deposition. If these conditions are strictly respected, then high lung tissue deposition associated with rapid and efficient bacterial killing can be expected. For aerosolized aminoglycosides and cephalosporins, a decrease in systemic exposure leading to reduced toxicity is not proven

by experimental studies. Aerosolized colistin, however, does not easily cross the alveolar–capillary membrane even in the presence of severe lung infection, and high doses can be delivered by nebulization without significant systemic exposure.

**V**ENTILATOR-ASSOCIATED pneumonia frequently complicates the clinical course of patients admitted to intensive care units for multiorgan failure.<sup>1,2</sup> Its incidence may be as high as 28% in patients on mechanical ventilation for more than 48 h and 70% in patients with acute lung injury or acute respiratory distress syndrome.<sup>3</sup> It prolongs the duration of stay in the intensive care unit, increases costs,<sup>4</sup> and represents the main reason for the prescription of antibiotics in critically ill patients.<sup>5</sup> Associated mortality ranges between 20 and 80% and seem far greater than the mortality resulting from other nosocomial infections.<sup>6,7</sup> Causative microorganisms such as *Pseudomonas aeruginosa* or *Acinetobacter baumannii* specifically increase mortality.<sup>8</sup> Early intravenous administration of appropriate antibiotics is considered as a prerequisite for an efficient treatment of ventilator-associated pneumonia, and bacteriological identification of causative microorganisms is the only way to limit the unnecessary use of antibiotics in the intensive care unit.<sup>7</sup> Lung penetration of intravenous antibiotics is, however, often limited; despite appropriate initial antibiotics administration, treatment failure is not infrequent, leading to increased dosage, risk of systemic toxicity, and prolongation of administration. Inappropriate antibiotic concentration at the site of infection and increased antibiotic exposure within the intensive care unit represent important risk factors for development of ventilator-associated pneumonia with resistant organisms.<sup>9,10</sup>

Aerosolized antibiotics could represent an attractive alternative to intravenous antibiotics with numerous potential advantages. Reaching the deep lung through the tracheobronchial tree should allow a better control of the main source of parenchymal infection, bronchial colonization.

\* Professor of Anesthesiology and Critical Care Medicine, Medical Director of the Multidisciplinary Intensive Care Unit, § Praticien Hospitalier, ‡ Chef de Clinique Assistant, Multidisciplinary Critical Care Unit, Pitié-Salpêtrière Hospital, University Pierre and Marie Curie Paris, France. † Director of Surgical Intensive Care Unit, Department of Anesthesiology, Groupe Hospitalier Paris-Saint-Joseph, Paris, France. || See appendix for members of the Nebulized Antibiotics Study Group.

Received from the Multidisciplinary Critical Care Unit, Department of Anesthesiology and Critical Care Medicine, Assistance Publique - Hôpitaux de Paris, Pitié-Salpêtrière Hospital, University Pierre and Marie Curie Paris-6, Paris, France. Submitted for publication February 17, 2012. Accepted for publication July 12, 2012. Support was provided solely from institutional and/or departmental sources. Jeanine P. Wiener-Kronish, M.D., served as Handling Editor for this article.

Address correspondence to Dr. Rouby: Réanimation Polyvalente Pierre Viars, Hôpital Pitié-Salpêtrière, 47–83 Boulevard de l'Hôpital, 75013 Paris, France (<http://www.reapitie-univparis6.aphp.fr>). [jjrouby@invo.edu](mailto:jjrouby@invo.edu). This article may be accessed for personal use at no charge through the Journal Web site, [www.anesthesiology.org](http://www.anesthesiology.org).

Copyright © 2012, the American Society of Anesthesiologists, Inc. Lippincott Williams & Wilkins. Anesthesiology 2012; 117:1364–80

Bypassing the alveolar–capillary barrier should provide high antibiotic concentrations at the site of infection if enough aerosolized particles are delivered to the deep lung. A reduction of the risk of systemic toxicity should be expected because antibiotic diffusion from bronchial and alveolar compartments to the systemic circulation is restricted by the presence of difficult-to-cross physiologic barriers (bronchial wall and alveolar–capillary barrier). The aim of this review is to perform a critical analysis of experimental studies on aerosolized antibiotics, draw lessons for clinical use, and identify issues that should be resolved before nebulization of antibiotics can be used as a complement or an alternative to intravenous anti-infectious therapy for ventilator-associated pneumonia. It extends and supplements a previous review published in 2012.<sup>11</sup>

## Experimental Models of Lung Infection

Understanding factors promoting distal lung deposition and pharmacokinetics of aerosolized antibiotics is a prerequisite for safe and efficient clinical use. It requires experimental models relevant to human ventilator-associated pneumonia.<sup>12</sup>

### Experimental Pneumonia in Spontaneously Breathing Animals

The first experimental models of pneumonia were set up in spontaneously breathing rodents or monkeys.<sup>13–16</sup> Recent reviews have summarized the specificities and advantages and limits of mouse, rats, and rabbit model of experimental pneumonia based on the intratracheal or intranasal inoculation of various bacterial species, including *Streptococcus pneumoniae*.<sup>17,18</sup> Parenchymal lung infection is induced by exposure to aerosolized microorganisms, intranasal instillation, or direct endobronchial instillation. Immediate postmortem quantitative culture of homogenized and serially diluted infected lung remains the reference technique for assessing initial bacterial burden and the effect of antimicrobial therapy. Because of the small size of animals, such a technique does not permit to differentiate bronchial from lung infection. Other methods such as detection of nucleic acids by real-time polymerase chain reaction and bioluminescence<sup>19</sup> seem attractive options. The accumulation of leukocytes within infected lung can be assessed in bronchoalveolar fluid lavage or, more accurately, using histological morphometric analysis. As far as antibiotic nebulization is concerned, the greatest limitation of mice models comes from marked differences in the anatomy of the murine compared with the human respiratory tract: The tracheobronchial tree is considerably smaller, has fewer and less symmetrical branches, and airways terminate abruptly into alveolar ducts without intervening respiratory bronchioles,<sup>20</sup> thereby facilitating lung deposition of aerosolized antibiotics.

### Experimental Ventilator-associated Pneumonia

In the early 1980s, an experimental intensive care unit for baboons was initiated by Johanson *et al.*<sup>21</sup> to study mechanisms of lung repair after oleic acid–induced lung injury. After a few days of mechanical ventilation, histological evidence of

lung superinfection modified the initial investigator's target, and finally, the model served for studying and understanding the pathophysiology of ventilator-associated pneumonia.<sup>22</sup> After completion of oleic acid–induced lung injury, anesthetized animals were ventilated during 7–10 days, a period during which they developed ventilator-associated pneumonia. Bacteriological investigations provided compelling evidence that the source of lung parenchymal infection was bacterial colonization of the tracheobronchial tree originating from the oropharynx.<sup>23</sup> Antimicrobial agents applied topically in the oropharynx and trachea combined with intravenous antibiotics were efficient for preventing pneumonia in a series of anesthetized baboons ventilated for 7–10 days.<sup>24</sup>

In the mid 1990s, Marquette *et al.*<sup>25</sup> created an experimental model of tracheobronchial stenoses for studying the efficacy of airway stents. In healthy anesthetized piglets, cartilaginous arches were resected and a caustic agent was bronchoscopically applied to create a tracheobronchial stenosis after 4 days of mechanical ventilation. Again, histological evidence of lung infection after a few days of mechanical ventilation interfered with initial investigators' aims and served for setting up and describing an experimental model of ventilator-associated pneumonia.<sup>26</sup> In a series of 23 anesthetized healthy piglets ventilated for 4 days in the prone position, histological pneumonia was evidenced in 22, extending to less than 30% of the lung, involving predominantly dependent lung segments and made essentially of foci of pneumonia. After 4 days of mechanical ventilation, ventilator-associated pneumonia was not severe, with a mild impairment in arterial oxygenation, a limited increase in lung weight, and the absence of large lung areas with confluent bronchopneumonia.<sup>26</sup> Similar lesions were observed after 60 h of mechanical ventilation.<sup>27</sup>

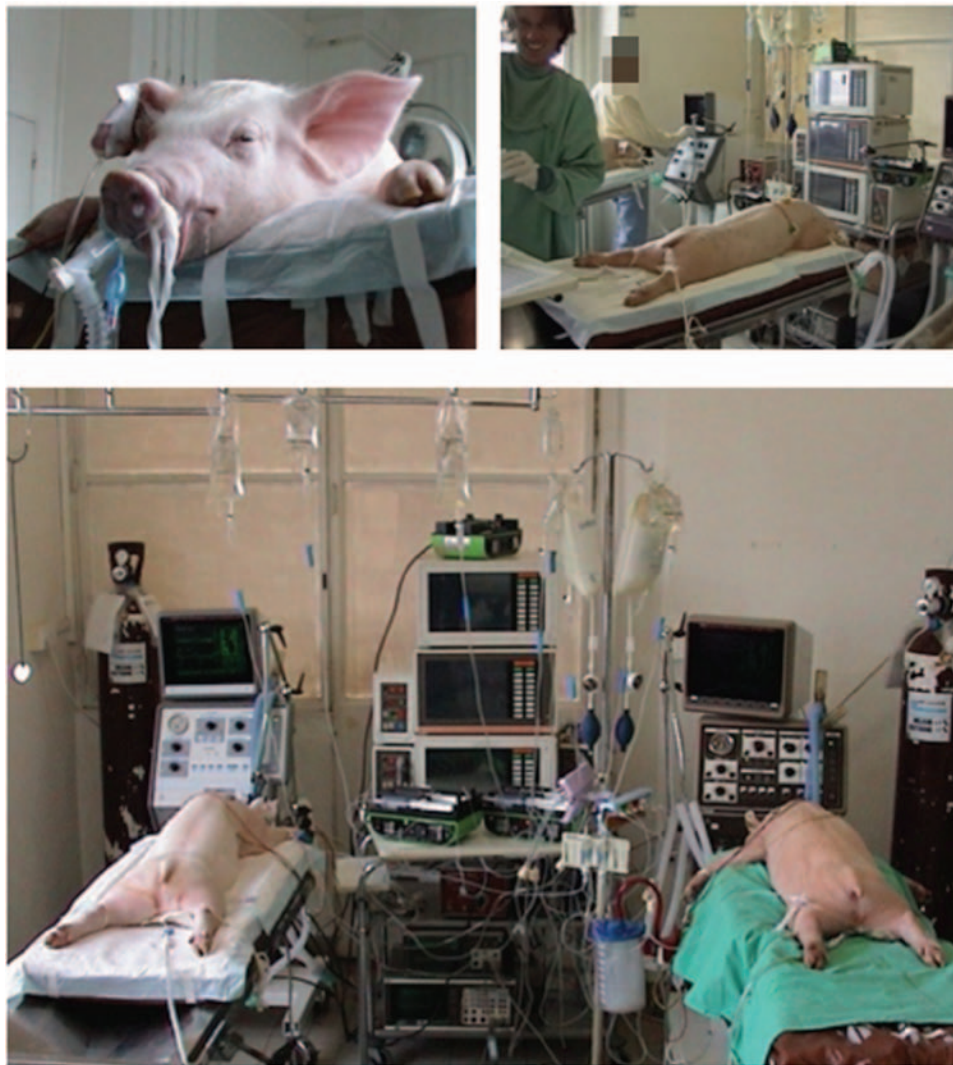### Specific Requirements for Studies on Aerosolized Antibiotics

Four experimental conditions seem to be of peculiar importance as far as antibiotic nebulization is concerned. First, animal size should be large enough to approach human tracheobronchial tree anatomical complexity. Distances between proximal trachea and alveolar compartments, airway diameters, and the number of bronchial divisions are critical factors affecting lung deposition of aerosolized particles. Therefore, experiments on large animals whose respiratory system is close to human respiratory system seem highly justified. Experiments on small animals, although easier to perform, would tend to underestimate the difficulty for aerosolized antibiotics to reach the deep lung. Second, severity and extension of lung infection should be reproducible enough to produce different histological grades of pneumonia within the same lung and to assess the influence of aeration loss on antibiotic lung deposition. Third, animals should be anesthetized and ventilated in their physiologic prone position for several days in experimental conditions reproducing intensive care unit environment. Fourth, specific ventilator settings used in experimental

animals during nebulization phases should be close to those used in ventilated critically ill patients.

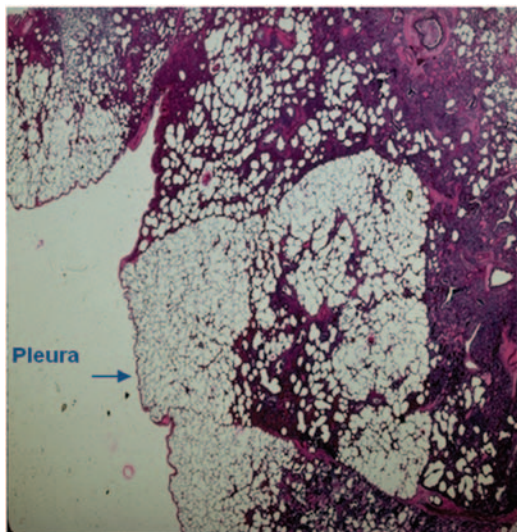
**Experimental Environment Required for Prolonged Mechanical Ventilation.** In the last 15 yr, a new experimental model derived from Marquette's model was set up to specifically study lung deposition and efficiency of intravenous and aerosolized antibiotics.<sup>28,29</sup> The model combines prolonged mechanical ventilation with massive bronchial inoculation of highly concentrated pathogens in anesthetized piglets. It produces severe bronchopneumonia resulting not only from the initial massive bacterial inoculation but also from the aggravating role of mechanical ventilation.<sup>30</sup> The model opens the possibility of assessing how aeration loss and severity of parenchymal infection influence lung deposition

of aerosolized antibiotics. It requires an experimental intensive care unit with the corresponding equipment and the presence on a 24-h period shift of trained physicians and technicians. Such a structure was set up in the late 1990s by the groups of Marquette and Rouby<sup>28</sup> and in the late 2000s by the groups of Luna<sup>31</sup> and Torres.<sup>29,32</sup> Healthy bred domestic Large White-Landrace piglets, aged 3–4 months and weighing  $20 \pm 2$  kg, are anesthetized using propofol and orotracheally intubated in the supine position. Catheters are inserted in the ear vein, femoral artery, and bladder. After anesthetic induction, piglets are placed in the prone position and anesthesia is maintained with a continuous infusion of midazolam, pancuronium, and fentanyl (fig. 1). Animals are mechanically ventilated in a volume-controlled mode for



**Fig. 1.** The Experimental Intensive Care Unit (Département Hospitalo-Universitaire de Recherche Expérimentale, University of Lille). Two anesthetized piglets were mechanically ventilated in prone position for periods ranging between 2 and 4 days. Two physicians were permanently present throughout experiments on a 24-h period shift, and two technicians were present from 9 AM to 5 PM each day. Equipment included: mechanical ventilators, continuous cardiorespiratory monitoring, strip-chart recorder, electrical infusers for continuous administration of intravenous treatments, material for endotracheal suctioning and thoracic drainage, material for bronchoscopy, material for antibiotic nebulization (ultrasonic and vibrating plate nebulizers), and surgical material for postmortem pulmonary biopsies. Dr. Ivan Goldstein, an investigator of the Nebulized Antibiotics Study Group, is present.





**Fig. 2.** Heterogeneous histological distribution of lung infection in a piglet whose lungs were inoculated with *Escherichia coli*. A normally aerated and noninfected pulmonary lobule (center of the figure) coexists with adjacent infected pulmonary lobules with various degrees of aeration loss. In non-aerated infected areas, many pseudocysts are visible, attesting of mechanical ventilation-induced airspace enlargement. Original magnification: 10. (From Ref. 37. Reprinted with permission of the American Thoracic Society. Copyright © 2012 American Thoracic Society.)

several days and inspired gases humidified using a conventional humidifier. Tidal volume, respiratory rate, positive end-expiratory pressure, and fraction of inspired oxygen are adjusted throughout the experiments to provide  $\text{PaO}_2 \geq 80$  mmHg and  $\text{PaCO}_2 \leq 50$  mmHg.

**Bronchial Inoculation of Microorganisms.** Massive lung infection is produced by the inoculation of 40 ml of a suspension containing  $10^6$  colony-forming units per milliliter (CFU/ml) of different bacterial species—*P. aeruginosa*, *Escherichia coli*, *Klebsiella pneumoniae*, methicillin-resistant *Staphylococcus aureus*—in different parts of the respiratory tract using bronchoscopy. As shown in figure 2, the bronchial inoculation is aimed at reproducing the heterogeneous distribution of lung infection characterizing ventilator-associated pneumonia.<sup>30,33</sup> Superimposed lung infection, essentially caused by *Pasteurella multocida* and *Streptococcus suis* is constantly observed, resulting from prolonged mechanical ventilation.<sup>26,30</sup>

**Measurement of Lung Bacterial Burden and Lung Tissue Antibiotic Concentrations.** At the end of experiments, heart and lungs are exposed through a cervicothoracic incision, and animals are killed either by exsanguination performed through direct cardiac puncture<sup>28</sup> or by intravenous overdose of potassium chloride.<sup>34</sup> Multiple subpleural and juxtahilar 3–4 cm<sup>3</sup> lung specimens are excised from apical and middle lobes and from apical, anterior, and posterior segments of lower lobes. Each specimen is cut into three parts: the first block for quantitative bacterial culture, the second

block for histological analysis and quantification of lung aeration,<sup>28</sup> and the third block for measurement of antibiotic tissue concentrations. The latter measurement can be performed using high-performance liquid chromatography on tissue samples that are cryomixed in nitrogen, weighed, and homogenized in buffer solution.<sup>35</sup>

Although reduced by premortem exsanguination, blood contamination of the lung tissue sample may induce an artifactual increase in antibiotic tissue concentration. The overestimation of antibiotic lung tissue concentration should be corrected as follows. Each lung specimen is cryomixed and centrifuged (2,000g) to obtain a lung supernatant. The amount of hemoglobin (Hb) present in the lung specimen ( $Q_{\text{hb}}$ ) is defined as  $Q_{\text{hb}} = \text{Hb}_{\text{lung}} V_{\text{supern}}$ , where  $V_{\text{supern}}$  is the supernatant volume and  $\text{Hb}_{\text{lung}}$  is the Hb supernatant concentration. Blood ( $V_{\text{blood lung}}$ ) and plasma ( $V_{\text{plasma lung}}$ ) volumes present in the supernatant volumes are calculated as  $V_{\text{blood lung}} = Q_{\text{hb}}/\text{Hb}$  and  $V_{\text{plasma lung}} = V_{\text{blood lung}}/\text{Ht}$ , where Ht is hematocrit. The amount of antibiotic present in  $V_{\text{plasma lung}}$  ( $Q_{\text{Ab plasma lung}}$ ) is then calculated as  $Q_{\text{Ab plasma lung}} = C_{\text{Ab plasma}} V_{\text{plasma lung}}$ , where  $C_{\text{Ab plasma}}$  is the antibiotic concentration measured in  $V_{\text{plasma lung}}$ . Finally, the “effective” antibiotic concentration present in the lung tissue specimen ( $C_{\text{Ablung}}$ ) is calculated as:

$$C_{\text{Ablung}} = (Q_{\text{Ablung}} - Q_{\text{Ab plasma lung}})/V_{\text{supern}}$$

The peak plasma level ( $C_{\text{max}}$ ), the time of the  $C_{\text{max}}$  ( $T_{\text{max}}$ ), and trough plasma concentrations ( $C_{\text{min}}$ ) were obtained by direct observation of the individual kinetic profiles. The lack of exsanguination at the time of death<sup>34</sup> may lead to marked overestimation of antibiotic lung tissue concentrations in piglets with methicillin-resistant *S. aureus* pneumonia treated by continuous intravenous administration of vancomycin.<sup>36</sup>

**Histological Assessment of Pneumonia Severity and Quantification of Lung Aeration.** Histological grade of bronchopneumonia can be divided into five categories of increasing severity<sup>33</sup>: (1) bronchiolitis, defined as the proliferation of leukocytes within the bronchial lumen leading to the formation of purulent plugs and associated with necrosis and disruption of bronchial mucosa; (2) interstitial bronchopneumonia, defined as the presence of scattered neutrophilic infiltrates localized to alveolar septa and terminal bronchioles; (3) focal bronchopneumonia, defined as an intense proliferation of leukocytes localized to terminal bronchioles and surrounding alveoli; (4) confluent bronchopneumonia, defined as an extension of these elementary lesions to one or several adjacent pulmonary lobules; and (5) purulent bronchopneumonia and lung abscess, defined as confluent bronchopneumonia associated with tissue necrosis and disruption of normal lung architecture. Classification of a given pulmonary lobule is based on the worst category observed. Final classification of a lung segment is defined as the most frequently observed lesion in all secondary pulmonary lobules present in the histological sections cut from the tissue block representative of the lung segment.

To quantify lung aeration, an image analyzer computerized system is coupled to a high-resolution color camera and an optical microscope objective. Each histological section is analyzed on a screen of a personal computer connected to the optical microscope and the color camera. Each optical field is analyzed as an automatically delineated rectangular elementary unit with an area of  $2.289 \text{ mm}^2$ . Within the elementary unit, aerated lung structures are automatically identified by a color encoding system included in a computerized program specially created for this experimental model. Pulmonary vessels and interlobular septa are visually detected and manually deselected to include as lung aeration air-filled structures only. Lung aeration of the elementary unit, expressed as a percentage, is computed as the area of alveolar and bronchial air-filled structures divided by the difference between  $2.289 \text{ mm}^2$  and the area of pulmonary vessels and interlobular septa. For a given histological section, representative of a lung segment in a given animal, lung aeration is computed as the mean lung aeration of all elementary units present in the histological section.<sup>37</sup>

**Determination of the Appropriate Dose of Inhaled Antibiotics.** As shown in figure 3, one possible and strong rationale for comparing bactericidal efficiency of aerosolized and intravenous antibiotics is to deliver an equivalent amount of antibiotics to the respiratory system by the tracheal route and the pulmonary circulation.<sup>28,38–42</sup> Therefore, to determine the appropriate aerosol dose, assessment of extrapulmonary deposition of aerosolized antibiotics, defined as the sum of nebulizer retention and deposition within respiratory circuits (inspiratory limb, Y piece, endotracheal tube, expiratory limb, and expiratory filter), should be performed. Extrapulmonary deposition of antibiotics can be measured

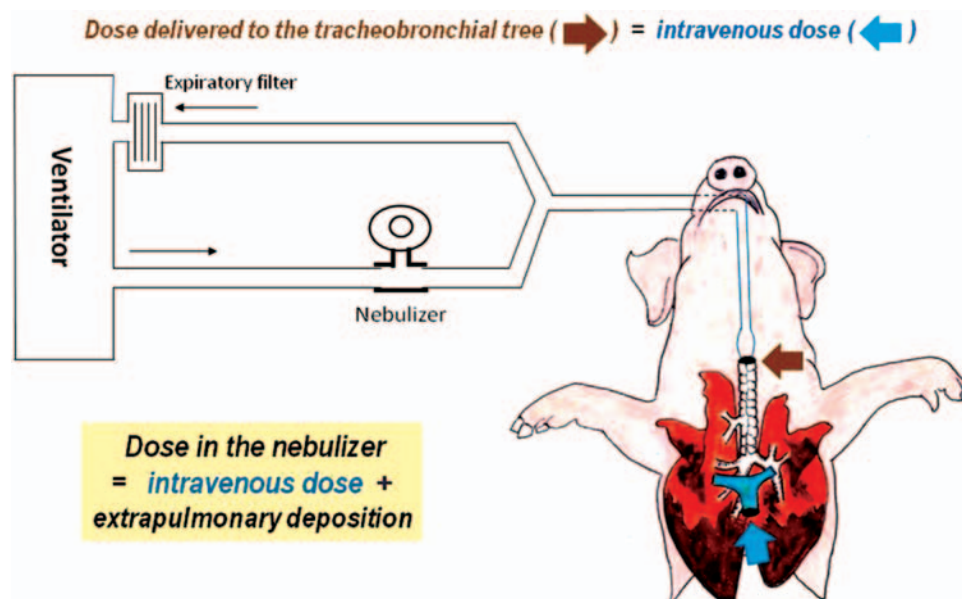
by washing out with a known volume of water the different parts of ventilator circuits and measuring the mean retrieved antibiotic concentration. Pulmonary deposition of inhaled antibiotics is then computed as the total amount of antibiotic administered in the nebulizer chamber minus the extrapulmonary deposition. The appropriate dose of aerosolized antibiotics can be defined as follows:

$$\text{Dose inserted in the nebulizer} = \text{intravenous dose} + \text{extrapulmonary deposition}$$

Another possible rationale for comparing aerosolized and intravenous antibiotics would be to deliver the highest aerosolized antibiotic dose that does not produce systemic and lung toxicity. Such determination is difficult to assess and requires repetitive systemic dosages before adjusting the optimal dose for a given animal. Because of its complexity, assessment of such a rationale has not yet been reported in experimental studies.

#### Limitations of Animal Models

Anatomy of the tracheobronchial tree of piglets differs from the human anatomy in several ways: the origin of segmental bronchi,<sup>42</sup> number and orientation of bronchial divisions, and bronchial diameter and size. As a consequence, lung deposition of nebulized antibiotics reported in experimental studies may not be automatically extrapolated to humans. Massive and unique bronchial inoculation of high concentrations of bacteria induces severe lung infection involving pulmonary lobes and segments. Such histological pattern may be different from human ventilator-associated pneumonia, characterized by repetitive bacterial seeding of the tracheobronchial tree through microaspiration



**Fig. 3.** Rationale for determining nebulized dose. Extrapulmonary deposition is determined by washing out the different parts of ventilatory circuits by a known volume of saline: Nebulizer chamber, inspiratory limb between the nebulizer and the Y piece, Y piece, endotracheal tube, expiratory limb, and expiratory filter.

of oropharyngeal secretions<sup>43</sup> and disseminated foci of pneumonia.<sup>33,44</sup> Last, but not least, the frequent infection of lung parenchyma after a few days of mechanical ventilation with microorganisms colonizing piglet's oropharyngeal cavity such as *P. multocida*, *S. suis*, or *Bordetella bronchiseptica*<sup>26</sup> complicates the evaluation of clinical outcome of animals treated with nebulized antibiotics.

### Factors Influencing Lung Deposition of Aerosolized Antibiotics

In the 1980s, mechanical ventilation was considered as a factor limiting aerosol lung deposition to less than 5% of the dose deposited into the nebulizer.<sup>45</sup> Currently, the understanding of technical conditions regulating lung deposition<sup>46</sup> and numerous technological innovations<sup>47</sup> have increased lung deposition up to 30–60% of the antibiotic dose deposited in the nebulizer.<sup>28,38,41,42,48</sup> Mechanisms by which the antibiotic dose delivered to the distal lung is lower than the dose of antibiotic deposited in the nebulizer are summarized in figure 4. Six critical factors influence lung deposition of nebulized antibiotics during mechanical ventilation: aerosol particle size, type of nebulizer, physical characteristics of the carrying gas, respiratory settings, bronchopneumonia severity, and lung aeration.

#### Mass Median Aerodynamic Diameter

Only aerosolized particles with mass median aerodynamic diameter ranges between 1 and 5  $\mu\text{m}$  can reach distal bronchioles and alveolar space.<sup>49</sup> Larger particles do not reach distal respiratory tract because they impact artificial and natural airways (ventilator circuits, endotracheal tube, trachea, and proximal bronchi).<sup>50,51</sup> Most commercially available nebulizers, such as dry powder inhalers, metered-dose

inhalers, jet nebulizers, ultrasonic nebulizers, and vibrating plate nebulizers, produce aerosol particles whose mass median aerodynamic diameter is less than 5  $\mu\text{m}$ . One should keep in mind, however, that the smaller the particle size, the longer the time to deliver a standard antibiotic dose.<sup>48</sup>

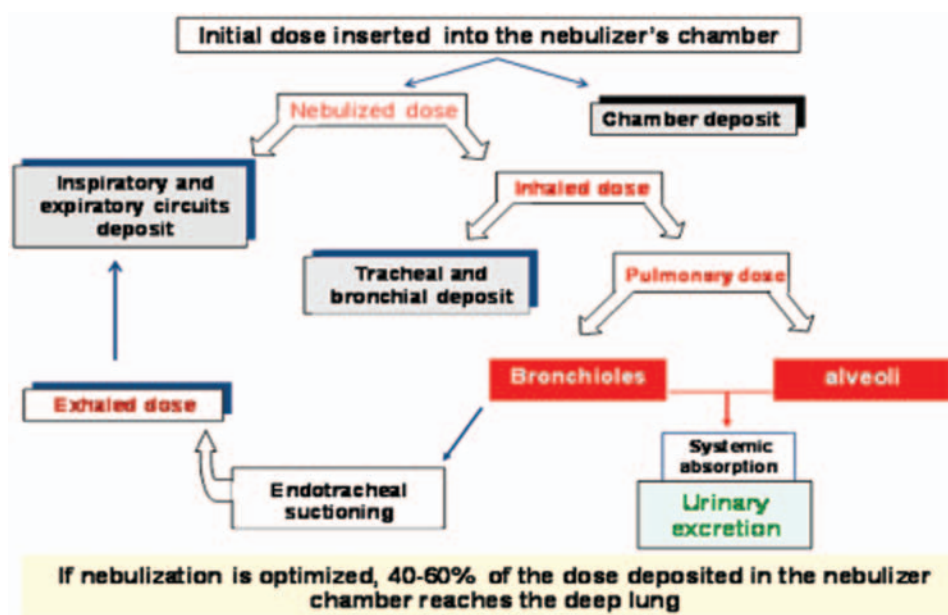
#### Type of Nebulizers and Positioning

Nebulizers with large enough reservoir are required for delivering sufficient amounts of antibiotics to the respiratory system. Therefore, metered-dose inhalers are more appropriate for aerosol delivery of bronchodilators and corticosteroids than for antibiotics inhalation.<sup>52</sup> In fact, particles impaction on ventilator circuits and proximal airways resulting from flow turbulences seems to be the main critical factor reducing distal lung deposition.

Jet nebulizers, which generate the aerosol by superimposing a highly turbulent flow to the inspiratory flow coming from the ventilator, are less efficient in terms of lung deposition than ultrasonic nebulizers<sup>53,54</sup>; they deliver less than 15% of the initial dose because of high residual volume, massive impaction of aerosol particles in ventilator circuits and endotracheal tube, and loss to atmosphere by the expiratory limb.<sup>55</sup>

Ultrasonic nebulizers are equipped with a large reservoir and generate aerosol particles through quartz vibrations, a technique which increases the temperature of the antibiotic solution and may alter the chemical structure of antibiotic molecules. Aerosolized particles are entrained into ventilatory circuits and tracheobronchial tree by a low flow independent of the flow coming from the ventilator. They increased the efficiency of aerosol delivery to 30–40%.<sup>28,38</sup>

Vibrating plate nebulizers are equipped with a reservoir placed above a domed aperture plate, which has about 1,000



**Fig. 4.** Mechanisms by which the dose of antibiotic inserted into the nebulizer differs from the dose delivered to the infected lung parenchyma.



tapered holes that are electroformed in a sheet. They include a ceramic vibrational element with alternating current–induced expansion and contraction move upward and downward the domed aperture plate, causing a micro-pump effect that produces the aerosol.<sup>56,57</sup> Particle size depends on the diameter of tapered holes, which can be changed by the manufacturer. Although they seem to be slightly inferior to ultrasonic nebulizers,<sup>41</sup> vibrating plate nebulizers have several potential advantages over ultrasonic nebulizers<sup>46,47</sup>: retention in the nebulizer is negligible; the temperature in the reservoir does not increase, minimizing the risk of oxygen desaturation; aerosol generation can be synchronized with inspiration<sup>48</sup>; and the aerosol can be delivered through an intratracheal catheter inserted in a flexible bronchoscope.<sup>58</sup> They increased the efficiency of aerosol delivery to 40–60%.<sup>41,42</sup>

During experiments in ventilated animals, nebulizers are placed before the Y piece, in parallel to the inspiratory limb. During continuous aerosolization, a bolus of antibiotic is delivered; during inspiration, particles are entrained into the tracheobronchial tree from the tubing between the nebulizer and the Y piece, where aerosolized drug has been collected. During aerosol generation synchronized to the inspiratory phase, the nebulizer is positioned between the Y piece and the proximal tip of the endotracheal tube and the bolus effect is not anymore present. For a given dose of antibiotic, synchronizing aerosol generation with the inspiratory phase significantly increases the duration of nebulization.<sup>11</sup> Voluminous ultrasonic nebulizers are placed on a fixed support, 40–50 cm before the Y piece, whereas less bulky vibrating plate nebulizers can be directly inserted into the inspiratory limb.

### Ventilatory Modes and Settings

Laminar inspiratory flow provides better distal lung deposition of aerosol particles than turbulent flow.<sup>59</sup> Turbulence, caused by decelerating flow and angular geometry in the conducting airways, causes aerosolized particles to impact the tubing, trachea, and proximal bronchioles and leads to extrapulmonary deposition and decreased antibiotic deposition in the distal lung. In spontaneously breathing animals, inspiratory flow is highly turbulent and most aerosolized particles impact oropharynx and proximal airways, precluding any significant distal lung deposition. In mechanically ventilated animals, specific ventilator settings should be adopted to limit inspiratory turbulence during the nebulization phase<sup>11,46,60</sup>: Volume-controlled mode using a constant inspiratory flow,<sup>61</sup> minute ventilation  $\leq 6$  l/min, respiratory frequency of 12/min, inspiratory to expiratory ratio  $\leq 50\%$ , and end-inspiratory pause representing 20% of the duty cycle. Decelerating flows should be avoided,<sup>62</sup> and animal's triggering and discoordination with the ventilator should also be avoided.<sup>62</sup> End-inspiratory pause representing 20% of the duty cycle should be used to provide enough time for aerosol sedimentation in the alveolar space.<sup>63</sup> Because these ventilator settings may not meet physiologic requirements in


conscious and awake animals with inoculation pneumonia, deep anesthesia and muscle paralysis are required throughout the experiments to provide full adaptation to the ventilator and optimum distal lung deposition of aerosolized antibiotics.

In most mechanically ventilated patients with ventilator-associated pneumonia, the continuous administration of propofol is required during the nebulization period to allow full adaptation to the ventilator using these specific ventilator settings.<sup>64</sup> Muscle paralysis is not indispensable, and the short duration of action of propofol allows rapid awakening at the end of the nebulization period. Respecting this rule is a key point of efficiency. To guarantee appropriate antibiotic administration, the nurse in charge of the patient should complete a checklist form ensuring that adequate ventilator settings are used and full adaptation of the patient with the ventilator is obtained with or without propofol administration.<sup>64</sup>

### Heat, Humidity, and Density of the Carrying Gas

Heated and humidified inspiratory gas coming from the ventilator increases mass median aerodynamic diameter of aerosol particles,<sup>65</sup> increases deposition in ventilator circuits,<sup>46</sup> and markedly reduces distal lung deposition.<sup>48,51</sup> The filter of the heat and moisture exchanger offers a barrier to aerosol delivery and should be removed during the nebulization period. If the period of nebulization does not exceed 30 min, the aerosol provides a partial humidification of inspired gas coming from the ventilator and no additional humidification is required. For nebulization longer than 30 min, a conventional humidifier should be inserted on the inspiratory limb to avoid damage of tracheal and bronchial mucosa resulting from the prolonged administration of cold and incompletely humidified inspiratory gas. As a result, the aerosol deposition might be reduced by 40%.<sup>46</sup>

Replacing nitrogen/oxygen by helium/oxygen (heliox) reduces density of the inspired gas and increases lung deposition of aerosol particles.<sup>66,67</sup> Heliox reduces flow turbulence and reduces tracheobronchial wall impaction of aerosol particles. In bench experiments, operating the nebulizer with heliox reduces drug output and disposable mass.<sup>68</sup> Therefore, to maximize lung deposition, it was initially suggested to generate the aerosol with a nitrogen–oxygen mixture and to entrain aerosol particles with heliox. These *in vitro* experiments were confirmed in mechanically ventilated piglets with healthy lungs: Lung deposition of ceftazidime increased by 33% when the ventilator was operated with heliox compared with the classical 65%/35% nitrogen–oxygen mixture.<sup>40</sup> This beneficial effect, however, was not observed in animals with massive inoculation pneumonia, suggesting that bronchiolitis-induced purulent obstructions were predominant over heliox reduction of flow turbulence.<sup>40</sup> Therefore, there are not enough experimental data to suggest the use of heliox as the carrying gas for nebulizing antibiotics in animals with inoculation pneumonia.



**Fig. 5.** Specific artificial airways recommended for nebulization of antibiotics. The Y piece is specifically designed for limiting impaction of aerosolized particles.

### Artificial Airways


Ventilator tubings and circuit connections by which aerosol particles are delivered to the tracheobronchial tree should be optimized to limit extrapulmonary deposition. Their inner surface should be smooth and their junctions should avoid acute or right angles. As shown in figure 5, using a special Y piece with obtuse angles reduces the number of aerosol particles hitting the walls of the ventilator circuit. The direct connection of the Y piece to the proximal tip of the endotracheal tube may also decrease impaction within respiratory circuits.

### Animal-related Factors

Studies performed in anesthetized piglets on prolonged mechanical ventilation have demonstrated that lung deposition of nebulized amikacin is significantly greater in animals with healthy lungs than in animals with inoculation pneumonia.<sup>28,38</sup> As shown in figure 6, amikacin lung tissue concentrations are homogeneously distributed in healthy animals and heterogeneously distributed in infected animals. The loss of lung aeration, the severity and extension of parenchymal infection, and the injury to the alveolar–capillary barrier are factors that influence the lung deposition of nebulized antibiotics.

**Lung Aeration.** By analogy with histological characteristics of ventilator-associated pneumonia,<sup>33</sup> the obstruction of distal bronchioles by purulent plugs is a limiting factor for alveolar deposition of aerosolized antibiotics in animals with massive bronchial inoculation pneumonia. In anesthetized and mechanically ventilated piglets whose lungs were infected by bronchial inoculation of *E. coli*, lung aeration loss had opposite effects in animals receiving intravenous amikacin and in animals receiving aerosolized amikacin.<sup>39</sup> As shown in figure 7, the loss of lung aeration tended to increase amikacin tissue concentrations in the intravenous group, whereas an opposite effect was observed in the aerosol group. Very likely, the increased permeability of the alveolar–capillary barrier resulting from severe lung infection tends to promote intravenous amikacin penetration into the lung, whereas the multiple purulent plugs obstructing distal bronchioles tend to impair lung deposition of nebulized amikacin.

It should be pointed out that despite the increased permeability of the alveolar–capillary barrier, amikacin lung



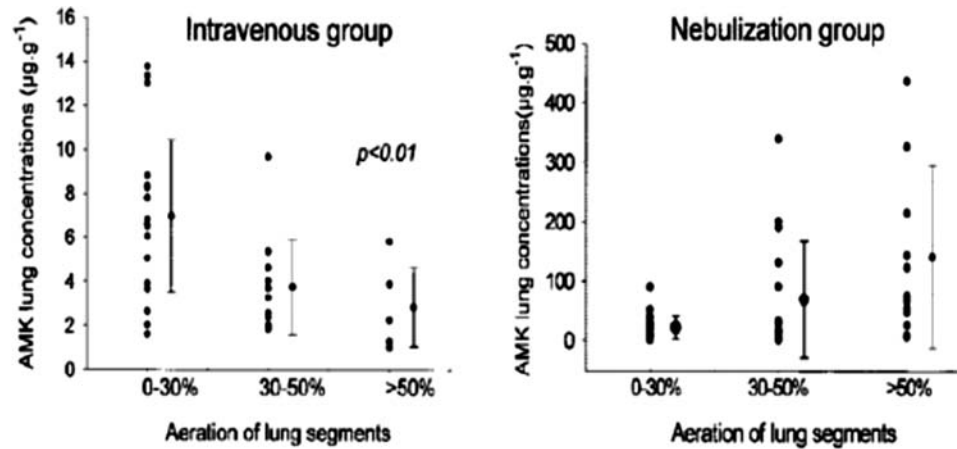
**Fig. 6.** Distribution of amikacin lung tissue concentrations in healthy piglets and piglets with inoculation pneumonia. Pneumonia was caused by bronchial instillation of *Escherichia coli*, and amikacin was administered by ultrasonic nebulizer at a dose of 45 mg/kg. In healthy piglets, tissue concentrations were higher and homogeneously distributed between lobes and segments 6, 8, and 10. In animals with infected lung, tissue concentrations were lower and heterogeneously distributed. (From Ref. 28. Reprinted with permission of the American Thoracic Society. Copyright © 2012 American Thoracic Society.) AMK = amikacin.

tissue concentrations remained significantly low after the intravenous injection. Conversely, lung tissue concentrations were always found above minimal inhibitory concentrations within consolidated infected lung regions raising the question how aerosolized antibiotics reach infected lung parenchyma despite the lack of any pulmonary aeration. In fact, as shown in figure 2, intraparenchymal pseudocysts and severe bronchiolar distension are frequently observed in condensed lung areas of ventilated animals with inoculation pneumonia.<sup>28,30,37</sup> Such lesions of air-space enlargement characterizing ventilator-induced lung injury likely represent one of the routes by which aerosolized antibiotics reach condensed infected lung regions devoid of alveolar aeration. From these experimental data, it can be reasonably hypothesized that ventilator settings aimed at recruiting nonaerated lung areas such as positive end-expiratory pressure or recruitment maneuver may help to increase lung deposition of nebulized antibiotics.

**Severity and Extension of Pneumonia.** The extension and severity of experimental lung infection can be quantified according to the histological classification proposed in the early 1990s for human ventilator-associated pneumonia and described above.<sup>33,69</sup>

In anesthetized piglets on prolonged mechanical ventilation for inoculation pneumonia, lung tissue concentrations of various aerosolized antibiotics were markedly higher in pulmonary segments with early stages of lung infection than in segments with confluent pneumonia and lung abscess.<sup>28,39,41,42</sup> As shown in figure 8, such differences were not observed when antibiotics were intravenously



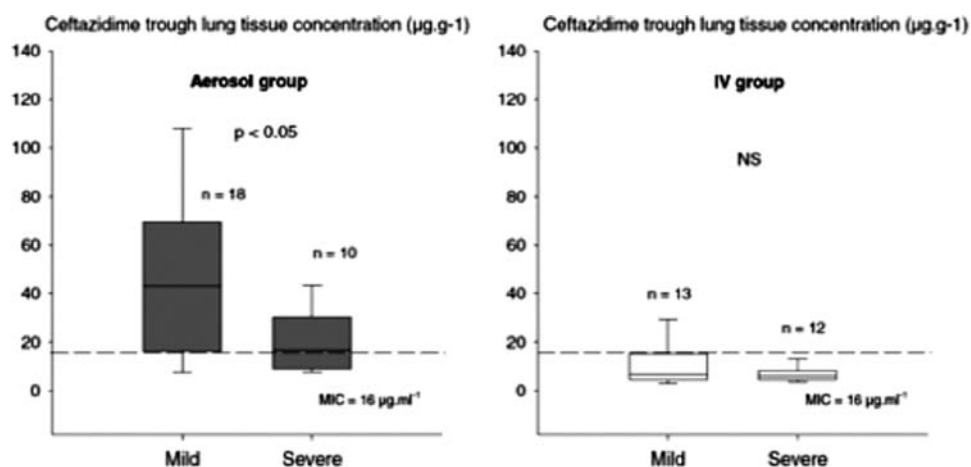


**Fig. 7.** AMK lung tissue concentrations in piglets with infected lung according to aeration of lung segments. Pneumonia was caused by bronchial instillation of *Escherichia coli* and AMK was administered by ultrasonic nebulizer at a dose of 45 mg/kg or intravenously at a dose of 15 mg/kg. Lung aeration was quantified on postmortem histological pulmonary samples representative of lung segments (black dots). After nebulization, AMK lung tissue concentrations decreased with lung aeration loss. After intravenous administration, AMK lung tissue concentrations increased with lung aeration loss. Independently of lung aeration, AMK lung tissue concentrations were always much higher after nebulization than after intravenous administration. (From Ref. 39. Reprinted with permission of the American Society of Anesthesiologists. © 2012 American Society of Anesthesiologists.) AMK = Amikacin.

administered. These experimental data clearly support the administration of aerosolized antibiotics at early stages of ventilator-associated pneumonia.

**Injury of the Alveolar–Capillary Barrier.** Antibiotic diffusion through respiratory epithelium (bronchial and alveolar) and pulmonary vascular endothelium markedly influences antibiotics' lung tissue deposition. Bronchiolar epithelium and normal alveolar–capillary barrier offer a high resistance to lung penetration of intravenous antibiotics and to systemic diffusion of nebulized antibiotics.<sup>28</sup> As any type of acute lung

injury, lung infection results in an increased permeability of the alveolar–capillary barrier,<sup>70</sup> which in turn facilitates the diffusion of nebulized antibiotics into the pulmonary blood stream and increases systemic bioavailability.<sup>38</sup> In presence of severe experimental lung infection, amikacin and ceftazidime plasma concentrations were found in the same range after nebulization and intravenous administration.<sup>38,41</sup> In other words, damage of the alveolar–capillary barrier resulting from the infectious process facilitates leakage of nebulized antibiotics toward the systemic compartment, thereby



**Fig. 8.** Ceftazidime lung tissue concentrations in piglets with infected lungs according to aeration of lung segments. Pneumonia was caused by bronchial instillation of *Pseudomonas aeruginosa* with a decreased sensitivity to ceftazidime. Ceftazidime was administered by vibrating plate nebulizer at a dose of 25 mg/kg every 3 h or intravenously, using a continuous infusion of 90 mg·kg<sup>-1</sup>·day<sup>-1</sup>. Histological severity of pneumonia characterizing lung segments (n number) was classified as mild (bronchiolitis, small foci of pneumonia, interstitial pneumonia) or severe (confluent pneumonia, necrotizing pneumonia). The dashed lines indicate minimal inhibitory concentrations of inoculated *P. aeruginosa*. After ceftazidime nebulization, ceftazidime trough tissue concentrations were significantly lower in pulmonary segments with severe pneumonia. (Reprinted from Ref. 41 with the permission of the publisher.)

decreasing the tissue concentrations and increasing the risk of systemic toxicity.

## Efficiency of Aerosolized Antibiotics for Treating Experimental Lung Infection

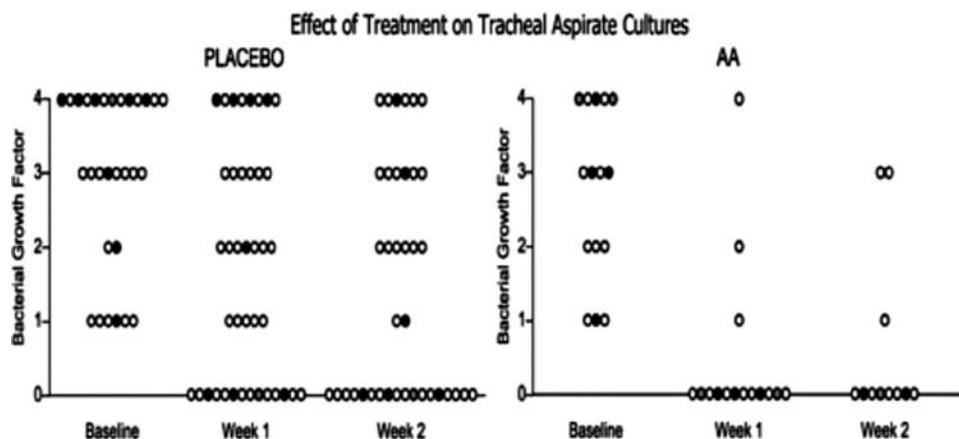
In mammals, the aerodigestive tract above the vocal cords is normally heavily colonized by bacteria, whereas the lower airways and pulmonary parenchyma are sterile. Several mechanisms are involved in removing particulate matter and eliminate microbes that have gained access to the bronchial tree: mucociliary clearance, cough, and cellular and humoral immune systems present along the tracheobronchial tree. Tracheal intubation, deep sedation, and mechanical ventilation weaken host defenses in several ways: cough reflex is depressed or abolished, mucociliary clearance is impaired when inflating endotracheal cuff,<sup>71</sup> and endotracheal tube injures the tracheal epithelial surface and provides a direct conduit for rapid access of bacteria into the lower respiratory tract. In addition, the antibiotic-resistant bacterial biofilm present on the inner surface of the endotracheal tube is fragmented and disseminated into the deep lung during tracheal suctioning or fiberoptic procedures.<sup>72</sup> The combination of impaired host defenses and continuous bacterial seeding of the lower respiratory tract by pathogens present in the aerodigestive reservoir produces favorable conditions to the development of deep lung infection. As a consequence, antimicrobial therapy directed against ventilator-associated pneumonia should be efficient not only on lung parenchymal infection but also on bacterial reservoir and tracheobronchial inoculum.

### Effects of Aerosolized Antibiotics on Tracheobronchial Inoculum

In baboons with acute lung injury resulting from intravenous injection of oleic acid, prolonged exposure to 100% oxygen or endobronchial inoculation of *P. aeruginosa*, antimicrobial

agents applied topically in the oropharynx and trachea can prevent bacterial pneumonia complicating the course of prolonged mechanical ventilation.<sup>23,24</sup> Polymyxin B and/or gentamicin instilled daily in the posterior oropharynx and in the endotracheal tube significantly reduced oropharyngeal colonization by Gram-negative bacilli, bacterial inoculum in the trachea, and ventilator-associated pneumonia caused by Gram-negative bacilli.<sup>24</sup> It has to be pointed out that intravenous prophylaxis with gentamicin was ineffective in preventing tracheal colonization and ventilator-associated pneumonia, outlining the limited diffusion of intravenous antibiotics through oropharyngeal mucosa and tracheal epithelium.<sup>73</sup> Clinical studies have also suggested that endotracheal administration of antimicrobial agents, either as direct bolus administration or nebulization, significantly reduce the incidence of ventilator-associated pneumonia,<sup>74,75</sup> likely *via* a marked reduction of tracheobronchial inoculums.<sup>76</sup> As shown in figure 9, critically ill patients with ventilator-associated tracheobronchitis had a significant decrease in tracheobronchial bacterial burden after being treated by several days of inhaled vancomycin or gentamicin when compared with the sole intravenous administration of these antibiotics during the same period.<sup>76</sup> Experimental and clinical data strongly suggest that inhaled antibiotics significantly decrease tracheobronchial bacterial inoculum.

One particular form of bronchial inoculum consists of bacteria growing within the biofilm present on the inner surface of endotracheal tubes. During tracheal suctioning, microbial aggregates are detached from the biofilm and disseminated toward the lung parenchyma by the inspiratory flow coming from the ventilator.<sup>77</sup> This reservoir of infecting microorganisms cannot be prevented or eradicated by intravenous antibiotics that do not reach the endotracheal tube. It can be prevented by the early nebulization of 80 mg of gentamicin every 8 h.<sup>78</sup> However, the impact of such a



**Fig. 9.** Bacterial burden in tracheal aspirates obtained in critically ill patients with ventilator-associated tracheobronchitis at baseline and 1 and 2 weeks later. Twenty-four patients received intravenous antibiotics plus nebulization of saline (placebo) until extubated. Nineteen received intravenous antibiotics plus nebulization of either vancomycin or gentamicin (AA) until extubated. The quantity of bacterial growth was assessed on a graded scale of 0–4 from semiquantitative cultures. Decrease in tracheal colonization was exclusively observed in patients receiving aerosolized antibiotics. (Reprinted from Ref. 76 with the permission of the publisher.) AA = aerosolized antibiotics.

preventive therapy on bacterial ecology of intensive care units has not been assessed, and therefore, it cannot be recommended as a routine therapy. Although not evaluated, it is highly likely that nebulized antibiotics cannot eradicate a preexisting biofilm: microorganisms present within the biofilm are likely protected from nebulized antibiotics by accretion of a protective glycocalyx.<sup>79</sup> The only way to efficiently remove the endotracheal biofilm is to suction ventilated animals with a catheter equipped with a balloon that is inflated during catheter retrieval.<sup>80</sup> The lack of evaluation of such a procedure on ventilator-associated pneumonia prevention does not permit to make recommendations concerning its use.

### Effects of Antibiotic Nebulization on Lung Tissue Concentrations and Bactericidal Activity

Bactericidal efficiency of aerosolized antibiotics requires obtaining appropriate lung tissue concentrations that kill pathogens infecting the lung parenchyma. It is directly assessed in experimental animals by measuring antibiotic lung tissue concentrations and assessing quantitative bacteriology of postmortem lung tissue samples. Bactericidal activity depends on the pharmacokinetic profile of antibiotics. When concentration-dependent antibiotics are administered, the higher the peak tissue concentration, the greater the bactericidal activity. When time-dependent antibiotics are administered, lung tissue concentrations should remain permanently 10 times greater than minimal inhibitory concentrations.

Antibiotic concentrations measured from homogenized lung represent the total amount of antibiotic present in interstitial and cell compartments. Most pathogens and particularly Gram-negative bacilli do not penetrate into cells and remain in the interstitial space where antibiotics exert their bactericidal activity by binding to bacterial cell membrane. Therefore, antibiotic concentrations measured from homogenized lung biopsies tend to underestimate "effective" interstitial concentrations because of a dilution factor caused by intracellular components.<sup>81</sup>

### Microbiologic Response

**In Spontaneously Breathing Animals with Inoculation Pneumonia.** More than 30 yr ago, it was reported that aerosolized kanamycin provided higher bacterial killing and survival rates in spontaneously breathing mice and squirrel monkeys with *K. pneumoniae* inoculation pneumonia, compared with intramuscular administration.<sup>82,83</sup> In the same model, the authors demonstrated that aerosolized kanamycin administered before intratracheal instillation of *K. pneumoniae* prevented the onset of bronchopneumonia, whereas the intramuscular administration was not protective.<sup>84</sup> Pharmacokinetic data demonstrated that nebulized kanamycin remained in the lungs longer and at higher concentrations compared with an intramuscular administration. Similar results were later on obtained in spontaneously breathing

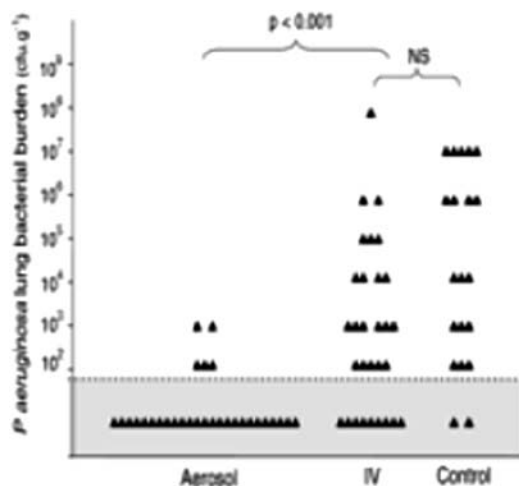
guinea pigs with *P. aeruginosa* inoculation pneumonia: a combination of aerosolized and intramuscular tobramycin achieved higher rates of survival and total eradication of *P. aeruginosa* from lungs compared with nebulized or intramuscular tobramycin alone.<sup>85</sup>

**In Mechanically Ventilated Animals with Inoculation Pneumonia.** The first experimental study looking at the antibacterial efficiency of nebulized antibiotics was performed in anesthetized piglets ventilated for a severe *E. coli* inoculation pneumonia.<sup>28</sup> Twenty-four hours after massive bacterial inoculation, ventilated animals were treated either by aerosolized or intravenous amikacin, a concentration-dependent antibiotic. To deliver equivalent doses to the respiratory system (extrapulmonary deposition represented 60% of the dose inserted into the nebulizer chamber), 45 mg/kg were nebulized and 15 mg/kg intravenously administered in a single dose. Animals received a second dose and were killed 1 h after the second dose, and five subpleural specimens were sampled from upper, middle, and lower lobes. After nebulization, amikacin lung tissue peak concentrations were 3–30 folds higher than after intravenous administration. After two doses (25-h treatment), 71% of lung segments were sterile, whereas cultures of lung segments were comparable in nontreated and intravenously treated animals.

Two studies looked at the bactericidal activity of ceftazidime, a time-dependent antibiotic, administered to anesthetized piglets ventilated for *P. aeruginosa* inoculation pneumonia.<sup>40,41</sup> In the first study, 24 h after intrabronchial bacterial inoculation, ventilated animals received either aerosolized or intravenous ceftazidime.<sup>40</sup> To deliver comparable doses to the respiratory system (extrapulmonary deposition represented 30% of the dose inserted into the nebulizer chamber), 50 mg/kg was nebulized and 33 mg/kg intravenously administered in a single dose and animals were killed 1 h later. Five subpleural specimens sampled from upper, middle, and lower lobes served for assessing ceftazidime tissue concentrations. After nebulization, ceftazidime lung tissue concentrations were 5–30 fold higher than after intravenous administration.<sup>40</sup> In the second study performed in the same experimental conditions, ceftazidime was administered for 24 h using either repetitive aerosols each 3 h or continuous intravenous administration.<sup>41</sup> After eight aerosols of 25 mg/kg or a continuous intravenous administration during 24 h, animals were killed and five subpleural specimens were sampled from upper, middle, and lower lobes for assessing ceftazidime tissue concentrations and lung bacterial burden. After nebulization, ceftazidime lung tissue trough concentrations were three to six folds higher than after intravenous administration. As shown in figure 10, after eight ceftazidime aerosols (24-h treatment), 83% of lung segments were sterile, whereas cultures of lung segments were comparable in nontreated and intravenously treated animals.

A fourth study was performed to compare bactericidal activity of aerosolized and intravenous colistin, a concentration- and time-dependent antibiotic for Gram-negative





**Fig. 10.** Lung bacterial burden of *Pseudomonas aeruginosa* after 24 h of ceftazidime nebulization. Lung segments (triangles) were sampled 3 h after the eighth aerosol in the aerosol group, 24 h after the start of continuous infusion in the intravenous group (IV), and 48 h after the bacterial inoculation in the untreated control group. Lung bacterial burden was significantly lower in the aerosol group compared with the intravenous and control groups. The difference was not statistically significant between intravenous and control groups. The grey area indicates the lower limit of quantitation for bacterial counts. Lung segments in this area are characterized by bacterial counts ranging between 0 colony-forming unit (CFU/g) (sterile) and 10<sup>2</sup> CFU/g. (Reprinted from Ref. 76 with the permission of the publisher.) NS = not significant.

bacteria, in anesthetized piglets ventilated for *P. aeruginosa* inoculation pneumonia.<sup>42</sup> Twenty-four hours after intrabronchial bacterial inoculation, ventilated animals received either intravenous or aerosolized colistin using vibrating plate nebulizers. To deliver comparable amount of colistin to the respiratory system (extrapulmonary deposition represented 40% of the dose inserted into the nebulizer chamber), 16 mg·kg<sup>-1</sup>·day<sup>-1</sup> were administered *via* two aerosols and 9 mg·kg<sup>-1</sup>·day<sup>-1</sup> were intravenously administered in three daily doses. Animals were killed 1 h after the third aerosol and 1 h after the fourth intravenous administration, and five subpleural specimens were sampled from upper, middle, and lower lobes for assessing colistin tissue concentrations and lung bacterial burden. After intravenous administration, colistin remained undetectable in the infected lung parenchyma. After nebulization, colistin lung tissue peak concentrations were one to seven folds higher than minimal inhibitory concentrations. After four colistin aerosols (24-h treatment), 67% of lung segments were sterile, whereas more than 70% of lung segments were massively infected in nontreated and intravenously treated animals.<sup>42</sup> This result confirms the lack of efficiency of parenteral colistin for treating experimental pneumonia, as previously demonstrated in spontaneously breathing mice whose lungs had been massively infected by intratracheal inoculation of multidrug resistant *P. aeruginosa* and *A. baumannii*.<sup>86,87</sup>

These experimental studies, performed in different animal species with inoculation pneumonia caused by various Gram-negative bacteria, clearly suggest that concentration-dependent antibiotics, such as aminoglycosides or colistin, and time-dependent antibiotics, such as cephalosporins, have a higher bactericidal efficiency when administered by nebulization than by the intravenous route.

## Pharmacokinetics of Nebulized Antibiotics and Risk of Systemic Toxicity

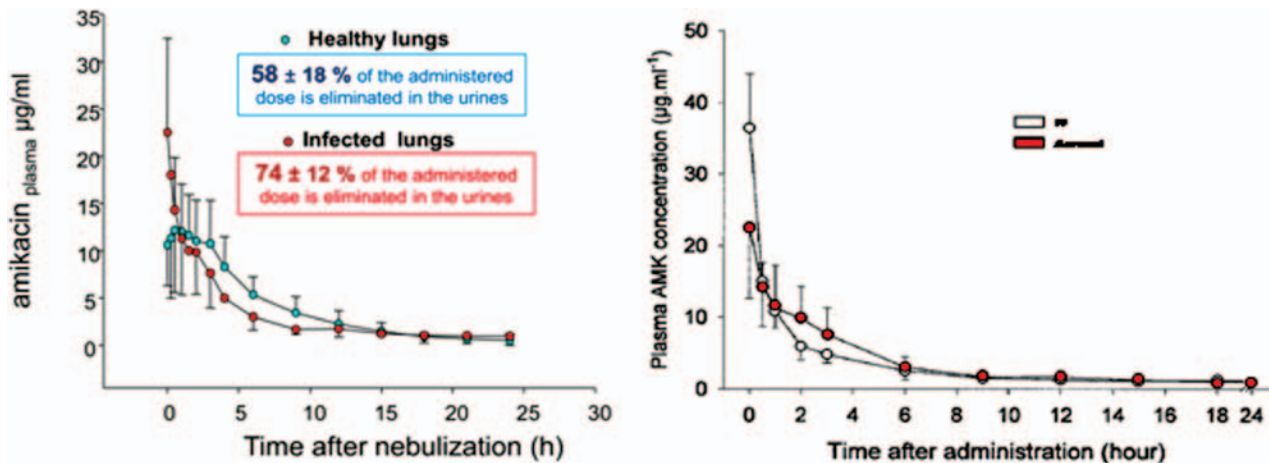
### Aminoglycosides and Cephalosporins

The alveolar–capillary barrier offers a difficult-to-cross obstacle for drugs reaching the pulmonary circulation. After intravenous administration, many antibiotics have a limited diffusion, resulting in insufficient lung tissue penetration. A recent experimental study performed in ventilated piglets with *P. aeruginosa* inoculation pneumonia documented the absence of any lung deposition of intravenously administered colistin.<sup>42</sup> Experimental studies have shown that antibiotic lung tissue concentrations are much lower after intravenous than after aerosol administration.<sup>28,38,40–42</sup> Acute experimental pneumonia is characterized by pulmonary vasoconstriction and regional thrombosis, two vascular injuries reducing lung perfusion and impairing pulmonary penetration of circulating antibiotics.

Bypassing the alveolar–capillary membrane by reaching alveoli *via* the bronchial tree is the basic rationale for delivering aerosolized antibiotics. By analogy with the difficulty of crossing the alveolar–capillary membrane from the pulmonary circulation, it was initially believed that systemic diffusion from the alveolar space of aerosolized antibiotics would be reduced, thereby limiting their toxicity. Unfortunately, for most antibiotics, experimental data did not confirm such a benefit. As shown in figure 11, the intact alveolar–capillary membrane is a limiting factor for the systemic diffusion of antibiotics present in the alveolar space.<sup>38</sup> Lung infection, however, markedly increases the permeability of the alveolar–capillary membrane and promotes systemic diffusion of aminoglycosides and cephalosporins.<sup>28,40,41</sup> As a consequence, expecting less systemic toxicity for these antibiotics by using the aerosol route is likely unwarranted. This prediction, however, will have to be confirmed by prospective studies including a large number of patients.

### Colistin

A recent experimental study performed in ventilated piglets with *P. aeruginosa* inoculation pneumonia has clearly shown that intravenous colistin does not cross the alveolar–capillary membrane, whereas aerosolized colistin has a limited systemic diffusion.<sup>42</sup> After colistin nebulization, the high lung deposition was associated with rapid and efficient bacterial killing, although systemic exposure was reduced. After intravenous colistin, the lack of lung deposition was associated with lack of bacterial killing, confirming a recent



**Fig. 11.** Amikacin plasma concentrations after a single nebulization of amikacin (45 mg/kg) in ventilated piglets with healthy lungs (blue circle) or inoculation *Escherichia coli* pneumonia (red circle). Amikacin plasma concentrations after a single intravenous dose of amikacin (15 mg/kg) in ventilated piglets with inoculation *E. coli* pneumonia (white circles) are also represented. (From Ref. 28. Reprinted with permission of the American Thoracic Society. Copyright © 2012 American Thoracic Society.)

study performed in mice with pneumonia caused by multidrug resistant *P. aeruginosa* where intravenous colistin did not confer any survival protection.<sup>87</sup> Aerosolized or intravenous colistin, which is negatively charged at body pH, is confronted with alveolar and endothelial membranes also characterized by negative charges.<sup>88</sup> The alveolar basement membrane is well known to inhibit the systemic passage of anionic molecules present in alveolar space, thus explaining why aerosolized colistin has a limited systemic diffusion and intravenous colistin a weak lung penetration.<sup>42,89</sup> As a consequence, a dosage exceeding threefold the dose commonly reported in the literature<sup>90</sup> can be used for treating pneumonia caused by sensitive *P. aeruginosa* without increasing the risk of toxicity.

#### Rationale for Combining Intravenous and Nebulized Antibiotics

One generally believes that aerosol as adjunctive to intravenous therapy offers an attractive alternative to intravenous or nebulized therapy alone. The hypothesis that a combination of nebulized and intravenous antibiotics could increase lung tissue concentrations and accelerate bacterial killing was previously tested in four experimental piglets whose lungs were infected by a massive bronchial inoculation of *E. coli* and who received a combination of nebulized and intravenous amikacin (data were part of a previously published study).<sup>28</sup> Unfortunately, no additional increase in lung tissue concentrations was measured, whereas increased trough systemic concentrations were observed, increasing the risk of systemic toxicity. In this experimental study, high amikacin concentrations were found in lymphatic vessels, suggesting a large absorption of amikacin into lymphatic vessels of lung interstitial space. It has to be pointed out that intravenous amikacin, in contrast to colistin, diffuses into the alveolar space and that

nebulized amikacin diffuses into the systemic circulation in presence of lung infection. As described above, there is solid evidence that lung deposition of intravenous colistin is extremely reduced, if not null. Therefore, it is hazardous to expect that combining nebulized and intravenous colistin might increase colistin tissue concentrations. In contrast, increased systemic concentrations resulting from intravenous administration may increase the risk of renal toxicity. Colistin, unlike aminoglycosides and  $\beta$ -lactams, does not cross the alveolar–capillary barrier of the infected lung parenchyma. Therefore, the rationale for combining nebulized and intravenous colistin as a treatment of ventilator-associated pneumonia seems weak. In fact, there is a strong rationale for treating bacteremic ventilator-associated pneumonia caused by resistant *P. aeruginosa* or *A. baumannii* with a combination of nebulized and intravenous colistin. Such a combination remains the only therapeutic option. Unfortunately, our model of inoculation pneumonia is extremely rarely associated with positive blood cultures and does not allow the assessment of this specific issue.

#### Side Effects of Nebulized Antibiotics

Few complications have been described in experimental animals receiving aerosolized antibiotics. Bronchoconstriction and hypoxemia may result from the aerosol nebulization of any drug, particularly in animals with pneumonia. Another serious potential complication of nebulized antibiotics could be the emergence of multiresistant pathogens. Experimental studies did not find any increase in the incidence of resistant pathogens when polymyxin B or colistin were endotracheally administered to prevent ventilator-associated pneumonia.<sup>24</sup> When aminoglycosides are nebulized into the tracheobronchial tree, significant

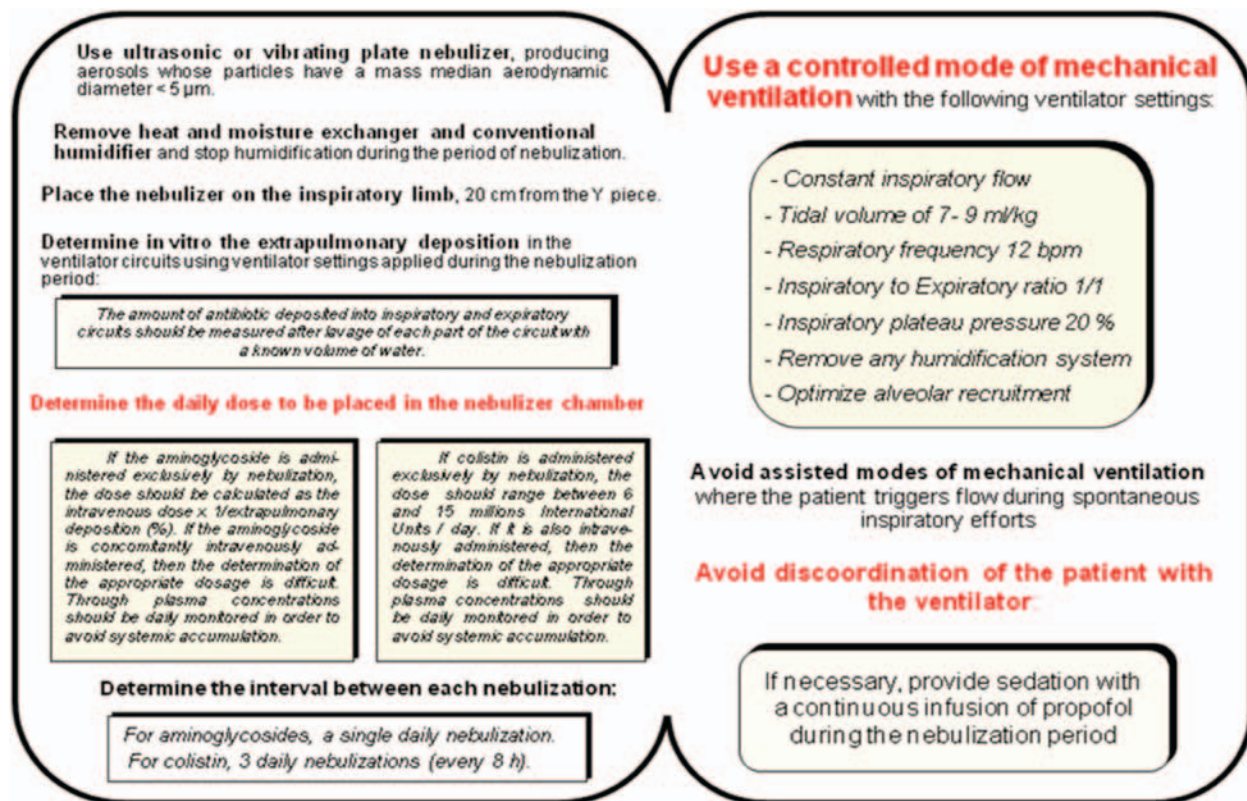


Fig. 12. Flowchart summarizing technical conditions required for efficient antibiotic nebulization aimed at treating pneumonia.

concentrations are found in the serum.<sup>28,38</sup> Most often, these concentrations are below minimal inhibitory concentrations of Gram-negative bacteria, a fact which may promote the emergence of aminoglycoside-resistant strains if an extrapulmonary infection is present. As a consequence, it seems reasonable to limit the administration of nebulized antibiotics to isolated and nonbacteremic ventilator-associated pneumonia.

### Lessons from Experimental Studies

Experimental studies have shown that aerosolized antibiotics for treating ventilator-associated pneumonia differ in several ways from inhaled bronchodilator therapy for treating bronchospasm or severe asthma. Aerosolized antibiotics must penetrate into the distal lung, whereas bronchodilators should reach exclusively the bronchial tree. Because antibiotic tissue concentrations in the infected lung parenchyma should markedly exceed minimal inhibitory concentrations of pathogens, optimizing dosage is a more critical issue for inhaled antibiotic therapy than for inhaled bronchodilator therapy.

As shown in figure 12, it is of critical importance to use adequate nebulizers and appropriate circuit connections and modify ventilator settings during the nebulization period for providing laminar inspiratory flow. The appropriate dose of aerosolized antibiotic should be determined according to

extrapulmonary deposition and the interval between two aerosols. Last, but not least, any discoordination with the ventilator should be avoided to prevent inspiratory turbulence and impaction of aerosolized antibiotics on circuit walls and upper airways. If these conditions are strictly respected, then high lung tissue deposition associated with rapid and efficient bacterial killing can be expected. For aerosolized aminoglycosides and cephalosporins, a decrease in systemic exposure leading to reduced toxicity is not proven by experimental studies likely because the permeability of the alveolar-capillary membrane markedly increases with lung parenchymal infection. Aerosolized colistin, however, does not cross the alveolar-capillary membrane even in the presence of severe lung infection, and high doses can be delivered by nebulization without significant systemic exposure and risk of toxicity.

### References

1. Rouby JJ: Nosocomial infection in the critically ill: The lung as a target organ. *ANESTHESIOLOGY* 1996; 84:757-9
2. Vincent JL, Bihari DJ, Suter PM, Bruining HA, White J, Nicolas-Chanoin MH, Wolff M, Spencer RC, Hemmer M: The prevalence of nosocomial infection in intensive care units in Europe. Results of the European Prevalence of Infection in Intensive Care (EPIC) Study. EPIC International Advisory Committee. *JAMA* 1995; 274:639-44
3. Chastre J, Fagon JY: Ventilator-associated pneumonia. *Am J Respir Crit Care Med* 2002; 165:867-903



4. Warren DK, Shukla SJ, Olsen MA, Kollef MH, Hollenbeak CS, Cox MJ, Cohen MM, Fraser VJ: Outcome and attributable cost of ventilator-associated pneumonia among intensive care unit patients in a suburban medical center. *Crit Care Med* 2003; 31:1312-7
5. Bergmans DC, Bonten MJ, Gaillard CA, van Tiel FH, van der Geest S, de Leeuw PW, Stobberingh EE: Indications for antibiotic use in ICU patients: A one-year prospective surveillance. *J Antimicrob Chemother* 1997; 39:527-35
6. American Thoracic Society; Infectious Diseases Society of America: Guidelines for the management of adults with hospital-acquired, ventilator-associated, and healthcare-associated pneumonia. *Am J Respir Crit Care Med* 2005; 171:388-416
7. Fagon JY, Chastre J, Rouby JJ: Is bronchoalveolar lavage with quantitative cultures a useful tool for diagnosing ventilator-associated pneumonia? *Crit Care* 2007; 11:123
8. Chastre J: Infections due to *Acinetobacter baumannii* in the ICU. *Semin Respir Crit Care Med* 2003; 24:69-78
9. Neuhauser MM, Weinstein RA, Rydman R, Danziger LH, Karam G, Quinn JP: Antibiotic resistance among gram-negative bacilli in US intensive care units: Implications for fluoroquinolone use. *JAMA* 2003; 289:885-8
10. Rello J, Diaz E: Pneumonia in the intensive care unit. *Crit Care Med* 2003; 31:2544-51
11. Rouby JJ, Goldstein I, Lu Q: Inhaled Antibiotic Therapy. In *Principles and Practice of Mechanical Ventilation* (third edition). Edited by Tobin MJ. New York, McGraw-Hill Medical Publishing Division, 2006;1447-58
12. Luna CM, Sibila O, Agustí C, Torres A: Animal models of ventilator-associated pneumonia. *Eur Respir J* 2009; 33:182-8
13. Berendt RF, Knutsen GL, Powanda MC: Nonhuman primate model for the study of respiratory *Klebsiella pneumoniae* infection. *Infect Immun* 1978; 22:275-81
14. Berendt RF, Long GG, Abeles FB, Canonico PG, Elwell MR, Powanda MC: Pathogenesis of respiratory *Klebsiella pneumoniae* infection in rats: Bacteriological and histological findings and metabolic alterations. *Infect Immun* 1977; 15:586-93
15. Berendt RF, Long GG, Walker JS: Influenza alone and in sequence with pneumonia due to *Streptococcus pneumoniae* in the squirrel monkey. *J Infect Dis* 1975; 132:689-93
16. Esposito AL, Pennington JE: Effects of aging on antibacterial mechanisms in experimental pneumonia. *Am Rev Respir Dis* 1983; 128:662-7
17. Chiavolini D, Pozzi G, Ricci S: Animal models of *Streptococcus pneumoniae* disease. *Clin Microbiol Rev* 2008; 21:666-85
18. Mizgerd JP, Skerrett SJ: Animal models of human pneumonia. *Am J Physiol Lung Cell Mol Physiol* 2008; 294:L387-98
19. Hutchens M, Luker GD: Applications of bioluminescence imaging to the study of infectious diseases. *Cell Microbiol* 2007; 9:2315-22
20. Bal HS, Ghoshal NG: Morphology of the terminal bronchiolar region of common laboratory mammals. *Lab Anim* 1988; 22:76-82
21. Johanson WG Jr, Holcomb JR, Coalson JJ: Experimental diffuse alveolar damage in baboons. *Am Rev Respir Dis* 1982; 126:142-51
22. Johanson WG Jr, Seidenfeld JJ, Gomez P, de los Santos R, Coalson JJ: Bacteriologic diagnosis of nosocomial pneumonia following prolonged mechanical ventilation. *Am Rev Respir Dis* 1988; 137:259-64
23. Crouch TW, Higuchi JH, Coalson JJ, Johanson WG Jr: Pathogenesis and prevention of nosocomial pneumonia in a nonhuman primate model of acute respiratory failure. *Am Rev Respir Dis* 1984; 130:502-4
24. Johanson WG Jr, Seidenfeld JJ, de los Santos R, Coalson JJ, Gomez P: Prevention of nosocomial pneumonia using topical and parenteral antimicrobial agents. *Am Rev Respir Dis* 1988; 137:265-72
25. Marquette CH, Mensier E, Copin MC, Desmidt A, Freitag L, Witt C, Petyt L, Ramon P: Experimental models of tracheo-bronchial stenoses: A useful tool for evaluating airway stents. *Ann Thorac Surg* 1995; 60:651-6
26. Marquette CH, Wermert D, Wallet F, Copin MC, Tonnel AB: Characterization of an animal model of ventilator-acquired pneumonia. *Chest* 1999; 115:200-9
27. Rios Vieira SR, Goldstein I, Lenaour G, Marquette CH, Rouby JJ; Experimental ICU Study Group: Experimental ventilator-associated pneumonia: Distribution of lung infection and consequences for lung aeration. *Braz J Infect Dis* 2003; 7:216-23
28. Goldstein I, Wallet F, Nicolas-Robin A, Ferrari F, Marquette CH, Rouby JJ: Lung deposition and efficiency of nebulized amikacin during *Escherichia coli* pneumonia in ventilated piglets. *Am J Respir Crit Care Med* 2002; 166:1375-81
29. Martínez-Olondris P, Rigol M, Torres A: What lessons have been learnt from animal models of MRSA in the lung? *Eur Respir J* 2010; 35:198-201
30. Sartorius A, Lu Q, Vieira S, Tonnellier M, Lenaour G, Goldstein I, Rouby JJ: Mechanical ventilation and lung infection in the genesis of air-space enlargement. *Crit Care* 2007; 11:R14
31. Luna CM, Bruno DA, García-Morato J, Mann KC, Risso Patrón J, Sagardía J, Absi R, García Bottino M, Marchetti D, Famiglietti A, Baleztena M, Biancolini C: Effect of linezolid compared with glycopeptides in methicillin-resistant *Staphylococcus aureus* severe pneumonia in piglets. *Chest* 2009; 135:1564-71
32. Sibila O, Agustí C, Torres A, Baquero S, Gando S, Patrón JR, Morato JG, Goffredo DH, Bassi N, Luna CM: Experimental *Pseudomonas aeruginosa* pneumonia: Evaluation of the associated inflammatory response. *Eur Respir J* 2007; 30:1167-72
33. Rouby JJ, Martin De Lassale E, Poete P, Nicolas MH, Bodin L, Jarlier V, Le Charpentier Y, Grosset J, Viars P: Nosocomial bronchopneumonia in the critically ill. Histologic and bacteriologic aspects. *Am Rev Respir Dis* 1992; 146:1059-66
34. Martínez-Olondris P, Sibila O, Agustí C, Rigol M, Soy D, Esquinas C, Piñer R, Luque N, Guerrero L, Quera MÁ, Marco F, de la Bellacasa JP, Ramirez J, Torres A: An experimental model of pneumonia induced by methicillin-resistant *Staphylococcus aureus* in ventilated piglets. *Eur Respir J* 2010; 36:901-6
35. Guerrero L, Martínez-Olondris P, Rigol M, Esperatti M, Esquinas C, Luque N, Piñer R, Torres A, Soy D: Development and validation of a high performance liquid chromatography method to determine linezolid concentrations in pig pulmonary tissue. *Clin Chem Lab Med* 2010; 48:391-8
36. Martínez-Olondris P, Rigol M, Soy D, Guerrero L, Agustí C, Quera MA, Li Bassi G, Esperatti M, Luque N, Liapikou M, Filella X, Marco F, de la Bellacasa JP, Torres A: Efficacy of linezolid compared to vancomycin in an experimental model of pneumonia induced by methicillin-resistant *Staphylococcus aureus* in ventilated pigs. *Crit Care Med* 2012; 40:162-8
37. Goldstein I, Bughalo MT, Marquette CH, Lenaour G, Lu Q, Rouby JJ; Experimental ICU Study Group: Mechanical ventilation-induced air-space enlargement during experimental pneumonia in piglets. *Am J Respir Crit Care Med* 2001; 163:958-64
38. Goldstein I, Wallet F, Robert J, Becquemin MH, Marquette CH, Rouby JJ: Lung tissue concentrations of nebulized amikacin during mechanical ventilation in piglets with healthy lungs. *Am J Respir Crit Care Med* 2002; 165:171-5
39. Elman M, Goldstein I, Marquette CH, Wallet F, Lenaour G, Rouby JJ; Experimental ICU Study Group: Influence of lung aeration on pulmonary concentrations of nebulized and intravenous amikacin in ventilated piglets with severe bronchopneumonia. *ANESTHESIOLOGY* 2002; 97:199-206
40. Tonnellier M, Ferrari F, Goldstein I, Sartorius A, Marquette CH, Rouby JJ: Intravenous versus nebulized ceftazidime in ventilated piglets with and without experimental bronchopneumonia: Comparative effects of helium and nitrogen. *ANESTHESIOLOGY* 2005; 102:995-1000
41. Ferrari F, Lu Q, Girardi C, Petitjean O, Marquette CH, Wallet F, Rouby JJ; Experimental ICU Study Group: Nebulized

- ceftazidime in experimental pneumonia caused by partially resistant *Pseudomonas aeruginosa*. *Intensive Care Med* 2009; 35:1792–800
42. Lu Q, Girardi C, Zhang M, Bouhemad B, Louchahi K, Petitjean O, Wallet F, Becquemin MH, Le Naour G, Marquette CH, Rouby JJ: Nebulized and intravenous colistin in experimental pneumonia caused by *Pseudomonas aeruginosa*. *Intensive Care Med* 2010; 36:1147–55
  43. Safdar N, Crnich CJ, Maki DG: The pathogenesis of ventilator-associated pneumonia: Its relevance to developing effective strategies for prevention. *Respir Care* 2005; 50:725–39; discussion 739–41
  44. Bouhemad B, Liu ZH, Arbelot C, Zhang M, Ferarri F, Le-Guen M, Girard M, Lu Q, Rouby JJ: Ultrasound assessment of antibiotic-induced pulmonary re-aeration in ventilator-associated pneumonia. *Crit Care Med* 2010; 38:84–92
  45. Fuller HD, Dolovich MB, Posmituck G, Pack WW, Newhouse MT: Pressurized aerosol *versus* jet aerosol delivery to mechanically ventilated patients. Comparison of dose to the lungs. *Am Rev Respir Dis* 1990; 141:440–4
  46. Dhand R, Guntur VP: How best to deliver aerosol medications to mechanically ventilated patients. *Clin Chest Med* 2008; 29:277–96, vi
  47. Dhand R: Aerosol delivery during mechanical ventilation: From basic techniques to new devices. *J Aerosol Med Pulm Drug Deliv* 2008; 21:45–60
  48. Miller DD, Amin MM, Palmer LB, Shah AR, Smaldone GC: Aerosol delivery and modern mechanical ventilation: *In vitro/in vivo* evaluation. *Am J Respir Crit Care Med* 2003; 168:1205–9
  49. Brain JD, Valberg PA: Deposition of aerosol in the respiratory tract. *Am Rev Respir Dis* 1979; 120:1325–73
  50. Crogan SJ, Bishop MJ: Delivery efficiency of metered dose aerosols given *via* endotracheal tubes. *ANESTHESIOLOGY* 1989; 70:1008–10
  51. O'Riordan TG, Palmer LB, Smaldone GC: Aerosol deposition in mechanically ventilated patients. Optimizing nebulizer delivery. *Am J Respir Crit Care Med* 1994; 149:214–9
  52. Dhand R, Tobin MJ: Inhaled bronchodilator therapy in mechanically ventilated patients. *Am J Respir Crit Care Med* 1997; 156:3–10
  53. Harvey CJ, O'Doherty MJ, Page CJ, Thomas SH, Nunan TO, Treacher DF: Comparison of jet and ultrasonic nebulizer pulmonary aerosol deposition during mechanical ventilation. *Eur Respir J* 1997; 10:905–9
  54. Dubus JC, Vecellio L, De Monte M, Fink JB, Grimbert D, Montharu J, Valat C, Behan N, Diot P: Aerosol deposition in neonatal ventilation. *Pediatr Res* 2005; 58:10–4
  55. Duarte AG, Fink JB, Dhand R: Inhalation therapy during mechanical ventilation. *Respir Care Clin N Am* 2001; 7:233–60, vi
  56. Dhand R: Nebulizers that use a vibrating mesh or plate with multiple apertures to generate aerosol. *Respir Care* 2002; 47:1406–16; discussion 1416–8
  57. Dhand R: New frontiers in aerosol delivery during mechanical ventilation. *Respir Care* 2004; 49:666–77
  58. Tronde A, Baran G, Eirefelt S, Lennernäs H, Bengtsson UH: Miniaturized nebulization catheters: A new approach for delivery of defined aerosol doses to the rat lung. *J Aerosol Med* 2002; 15:283–96
  59. Dolovich MA: Influence of inspiratory flow rate, particle size, and airway caliber on aerosolized drug delivery to the lung. *Respir Care* 2000; 45:597–608
  60. O'Doherty MJ, Thomas SH, Page CJ, Treacher DF, Nunan TO: Delivery of a nebulized aerosol to a lung model during mechanical ventilation. Effect of ventilator settings and nebulizer type, position, and volume of fill. *Am Rev Respir Dis* 1992; 146:383–8
  61. Dhand R: Maximizing aerosol delivery during mechanical ventilation: Go with the flow and go slow. *Intensive Care Med* 2003; 29:1041–2
  62. Hess DR, Dillman C, Kacmarek RM: *In vitro* evaluation of aerosol bronchodilator delivery during mechanical ventilation: Pressure-control *vs.* volume control ventilation. *Intensive Care Med* 2003; 29:1145–50
  63. Fink JB, Dhand R, Grychowski J, Fahey PJ, Tobin MJ: Reconciling *in vitro* and *in vivo* measurements of aerosol delivery from a metered-dose inhaler during mechanical ventilation and defining efficiency-enhancing factors. *Am J Respir Crit Care Med* 1999; 159:63–8
  64. Lu Q, Yang J, Liu Z, Gutierrez C, Aymard G, Rouby JJ: Nebulized Antibiotics Study Group: Nebulized ceftazidime and amikacin in ventilator-associated pneumonia caused by *Pseudomonas aeruginosa*. *Am J Respir Crit Care Med* 2011; 184:106–15
  65. Ferron GA, Kerrebijn KF, Weber J: Properties of aerosols produced with three nebulizers. *Am Rev Respir Dis* 1976; 114:899–908
  66. Habib DM, Garner SS, Brandeburg S: Effect of helium-oxygen on delivery of albuterol in a pediatric, volume-cycled, ventilated lung model. *Pharmacotherapy* 1999; 19:143–9
  67. Goode ML, Fink JB, Dhand R, Tobin MJ: Improvement in aerosol delivery with helium-oxygen mixtures during mechanical ventilation. *Am J Respir Crit Care Med* 2001; 163:109–14
  68. Hess DR, Acosta FL, Ritz RH, Kacmarek RM, Camargo CA Jr: The effect of heliox on nebulizer function using a beta-agonist bronchodilator. *Chest* 1999; 115:184–9
  69. Fàbregas N, Torres A, El-Ebiary M, Ramírez J, Hernández C, González J, de la Bellacasa JP, de Anta J, Rodríguez-Roisin R: Histopathologic and microbiologic aspects of ventilator-associated pneumonia. *ANESTHESIOLOGY* 1996; 84:760–71
  70. Matthay MA: Function of the alveolar epithelial barrier under pathologic conditions. *Chest* 1994; 105(3 Suppl):67S–74S
  71. Wanner A, Salathé M, O'Riordan TG: Mucociliary clearance in the airways. *Am J Respir Crit Care Med* 1996; 154(6 Pt 1):1868–902
  72. Bauer TT, Torres A, Ferrer R, Heyer CM, Schultze-Werninghaus G, Rasche K: Biofilm formation in endotracheal tubes. Association between pneumonia and the persistence of pathogens. *Monaldi Arch Chest Dis* 2002; 57:84–7
  73. Smith BR, LeFrock JL: Bronchial tree penetration of antibiotics. *Chest* 1983; 83:904–8
  74. Feeley TW, Du Moulin GC, Hedley-Whyte J, Bushnell LS, Gilbert JP, Feingold DS: Aerosol polymyxin and pneumonia in seriously ill patients. *N Engl J Med* 1975; 293:471–5
  75. Rouby JJ, Poète P, Martin de Lassale E, Nicolas MH, Bodin L, Jarlier V, Korinek AM, Viars P: Prevention of gram negative nosocomial bronchopneumonia by intratracheal colistin in critically ill patients. Histologic and bacteriologic study. *Intensive Care Med* 1994; 20:187–92
  76. Palmer LB, Smaldone GC, Chen JJ, Baram D, Duan T, Monteforte M, Varela M, Tempone AK, O'Riordan T, Daroowalla F, Richman P: Aerosolized antibiotics and ventilator-associated tracheobronchitis in the intensive care unit. *Crit Care Med* 2008; 36:2008–13
  77. Pneumatikos IA, Dragoumanis CK, Bouros DE: Ventilator-associated pneumonia or endotracheal tube-associated pneumonia? An approach to the pathogenesis and preventive strategies emphasizing the importance of endotracheal tube. *ANESTHESIOLOGY* 2009; 110:673–80
  78. Adair CG, Gorman SP, Byers LM, Jones DS, Feron B, Crowe M, Webb HC, McCarthy GJ, Milligan KR: Eradication of endotracheal tube biofilm by nebulized gentamicin. *Intensive Care Med* 2002; 28:426–31
  79. Donlan RM, Costerton JW: Biofilms: Survival mechanisms of clinically relevant microorganisms. *Clin Microbiol Rev* 2002; 15:167–93

80. Lorente L, Blot S, Rello J: New issues and controversies in the prevention of ventilator-associated pneumonia. *Am J Respir Crit Care Med* 2010; 182:870–6
81. Nix DE, Goodwin SD, Peloquin CA, Rotella DL, Schentag JJ: Antibiotic tissue penetration and its relevance: Impact of tissue penetration on infection response. *Antimicrob Agents Chemother* 1991; 35:1953–9
82. Berendt RF, Long GG, Walker JS: Treatment of respiratory *Klebsiella pneumoniae* infection in mice with aerosols of kanamycin. *Antimicrob Agents Chemother* 1975; 8: 585–90
83. Berendt RF, Magruder RD, Frola FR: Treatment of *Klebsiella pneumoniae* respiratory tract infection of squirrel monkeys with aerosol administration of kanamycin. *Am J Vet Res* 1980; 41:1492–4
84. Berendt RF, Schneider MA, Young HW, Frola FR: Protection against *Klebsiella pneumoniae* respiratory tract infection of mice and squirrel monkeys given kanamycin by aerosol and injection. *Am J Vet Res* 1979; 40:1231–5
85. Makhoul IR, Merzbach D, Lichtig C, Berant M: Antibiotic treatment of experimental *Pseudomonas aeruginosa* pneumonia in guinea pigs: Comparison of aerosol and systemic administration. *J Infect Dis* 1993; 168:1296–9
86. Montero A, Ariza J, Corbella X, Doménech A, Cabellos C, Ayats J, Tubau F, Ardanuy C, Gudiol F: Efficacy of colistin *versus* beta-lactams, aminoglycosides, and rifampin as monotherapy in a mouse model of pneumonia caused by multiresistant *Acinetobacter baumannii*. *Antimicrob Agents Chemother* 2002; 46:1946–52
87. Aoki N, Tateda K, Kikuchi Y, Kimura S, Miyazaki C, Ishii Y, Tanabe Y, Gejyo F, Yamaguchi K: Efficacy of colistin combination therapy in a mouse model of pneumonia caused by multidrug-resistant *Pseudomonas aeruginosa*. *J Antimicrob Chemother* 2009; 63:534–42
88. Barrowcliffe MP, Jones JG: Solute permeability of the alveolar capillary barrier. *Thorax* 1987; 42:1–10
89. Ratjen F, Rietschel E, Kasel D, Schwietz R, Starke K, Beier H, van Koningsbruggen S, Grasemann H: Pharmacokinetics of inhaled colistin in patients with cystic fibrosis. *J Antimicrob Chemother* 2006; 57:306–11
90. Michalopoulos A, Kasiakou SK, Mastora Z, Rellos K, Kapaskelis AM, Falagas ME: Aerosolized colistin for the treatment of nosocomial pneumonia due to multidrug-resistant Gram-negative bacteria in patients without cystic fibrosis. *Crit Care* 2005; 9:R53–9

## Appendix: Members of the Nebulized Antibiotics Study Group

Rubin Luo, M.D., Research Fellow, Mao Zhang, M.D., Ph.D., Medical Director (Department of Emergency Medicine, Second Affiliated Hospital, Zhejiang University, School of Medicine, Hangzhou, China); Marine Lecorre, M.D., Fabio Ferrari, M.D., Ph.D., Corinne Vezinet, M.D., Liliane Bodin, M.D. (Multidisciplinary Intensive Care Unit, Department of Anesthesiology and Critical Care Medicine, La Pitié-Salpêtrière Hospital, Assistance-Publique-Hôpitaux-de-Paris, UPMC Univ Paris 06, France); Charles-Hugo Marquette, M.D., Ph.D. Medical Director of the Department of Respiratory Diseases, Pasteur Hospital, University of Nice-Sophia Antipolis, Nice, France; Olivier Petit-Jean, Ph.D., Director of the Department of Pharmacology, Avicenne Hospital, Assistance Publique-Hôpitaux de Paris, Bobigny, France; Alexandra Aubry, M.D., Ph.D., Jérôme Robert, M.D., Ph.D. (Department of Bacteriology, La Pitié-Salpêtrière Hospital, Assistance-Publique-Hôpitaux-de-Paris, UPMC Univ Paris 06); Noël Zahr, Pharm.D., Ph.D., Christian Funck-Brentano, M.D., Ph.D., Medical Director, Department of Pharmacology, La Pitié-Salpêtrière Hospital, UPMC Univ Paris 06, France.