

2015 Advances in Alcoholic liver disease

Advances in alcoholic liver disease: An update on alcoholic hepatitis

Randy Liang, Andy Liu, Ryan B Perumpail, Robert J Wong, Aijaz Ahmed

Randy Liang, Department of Medicine, Santa Clara Valley Medical Center, San Jose, CA 95128, United States

Andy Liu, Albert Einstein College of Medicine, Bronx, NY 10461, United States

Ryan B Perumpail, Aijaz Ahmed, Division of Gastroenterology and Hepatology, Stanford University School of Medicine, Stanford, CA 94305, United States

Robert J Wong, Division of Gastroenterology and Hepatology, Alameda Health System - Highland Hospital Campus, Oakland, CA 94602, United States

Author contributions: Liang R, Liu A, Perumpail RB, Wong RJ and Ahmed A designed research; Liang R, Liu A, Perumpail RB, Wong RJ and Ahmed A performed research; Liang R, Liu A, Perumpail RB, Wong RJ and Ahmed A contributed new reagents or analytic tools; Liang R, Liu A, Perumpail RB, Wong RJ and Ahmed A analyzed data; Liang R wrote the paper.

Conflict-of-interest statement: We declare that we have no conflicts of interest.

Open-Access: This article is an open-access article which was selected by an in-house editor and fully peer-reviewed by external reviewers. It is distributed in accordance with the Creative Commons Attribution Non Commercial (CC BY-NC 4.0) license, which permits others to distribute, remix, adapt, build upon this work non-commercially, and license their derivative works on different terms, provided the original work is properly cited and the use is non-commercial. See: <http://creativecommons.org/licenses/by-nc/4.0/>

Correspondence to: Aijaz Ahmed, MD, Associate Professor, Medical Director, Division of Gastroenterology and Hepatology, Stanford University School of Medicine, 750 Welch Road, Suite 210, Palo Alto, CA 94305, United States. aijazahmed@stanford.edu
Telephone: +1-650-4986091
Fax: +1-650-4985692

Received: May 26, 2015
Peer-review started: May 27, 2015

First decision: June 23, 2015

Revised: July 8, 2015

Accepted: September 30, 2015

Article in press: September 30, 2015

Published online: November 14, 2015

Abstract

Alcoholic hepatitis is a pro-inflammatory chronic liver disease that is associated with high short-term morbidity and mortality (25%-35% in one month) in the setting of chronic alcohol use. Histopathology is notable for micro- and macrovesicular steatosis, acute inflammation with neutrophil infiltration, hepatocellular necrosis, perivenular and perisinusoidal fibrosis, and Mallory hyaline bodies found in ballooned hepatocytes. Other findings include the characteristic eosinophilic fibrillar material (Mallory's hyaline bodies) found in ballooned hepatocytes. The presence of focal intense lobular infiltration of neutrophils is what typically distinguishes alcoholic hepatitis from other forms of hepatitis, in which the inflammatory infiltrate is primarily composed of mononuclear cells. Management consists of a multidisciplinary approach including alcohol cessation, fluid and electrolyte correction, treatment of alcohol withdrawal, and pharmacological therapy based on the severity of the disease. Pharmacological treatment for severe alcoholic hepatitis, as defined by Maddrey's discriminant factor ≥ 32 , consists of either prednisolone or pentoxifylline for a period of four weeks. The body of evidence for corticosteroids has been greater than pentoxifylline, although there are higher risks of complications. Recently head-to-head trials between corticosteroids and pentoxifylline have been performed, which again suggests that corticosteroids should strongly be considered over pentoxifylline.

Key words: Alcoholic Hepatitis; Maddrey discriminant function; Corticosteroids; Pentoxifylline; Alcoholic liver

disease

© **The Author(s) 2015.** Published by Baishideng Publishing Group Inc. All rights reserved.

Core tip: Alcoholic hepatitis is a **pro-inflammatory chronic liver disease** that is associated with high short-term morbidity and mortality in the setting of chronic alcohol use. Management consists of a multidisciplinary approach including alcohol cessation, fluid and electrolyte correction, treatment of alcohol withdrawal, and pharmacological therapy based on the severity of the disease. Pharmacological treatment for severe alcoholic hepatitis, as defined by Maddrey's discriminant function ≥ 32 , consists of either prednisolone or pentoxifylline for a period of four weeks. The body of evidence in favor of corticosteroids has been greater than pentoxifylline, although there are higher risks of complications.

Liang R, Liu A, Perumpail RB, Wong RJ, Ahmed A. Advances in alcoholic liver disease: An update on alcoholic hepatitis. *World J Gastroenterol* 2015; 21(42): 11893-11903 Available from: URL: <http://www.wjgnet.com/1007-9327/full/v21/i42/11893.htm> DOI: <http://dx.doi.org/10.3748/wjg.v21.i42.11893>

INTRODUCTION

Alcoholic hepatitis (AH) is a life threatening complication of alcoholic liver disease and presents with a mortality rate of up to 25%^[1-6]. AH was first described in 1961 by Dr. Gordon Beckett, who noted several patients with constitutional symptoms followed by worsening jaundice, death in the setting of significant alcohol intake. In general, patients with a diagnosis of AH present in their fifth to sixth decade of life^[2-4]. Amount of alcohol intake is the single most important predictor of severity of AH. While reports vary, current consensus is that patients with AH typically ingest over 100 to 120 g of ethanol on a daily basis for 10 to 20 years, with a standard drink equal to 14 g of pure alcohol, which is equivalent to 12 ounces (354.88 mL) of beer, 5 ounces (147.87 mL) of wine, 1.5 ounces (44.36 mL) or a "shot" of 80-proof liquor^[2-5]. A study by Bellentani *et al*^[5] demonstrated an odds ratio of 13.7 for cirrhosis and 23.6 for non-cirrhotic liver disease in patients with an alcohol intake greater than 30 g per day compared to nondrinkers. Other risk factors for the development of AH include gender and genetic factors. For instance, women have a higher risk of developing alcoholic liver disease relative to men^[6]. In addition, an elevated body mass index with or without other components of metabolic syndrome and complicated by non-alcoholic fatty liver disease can lead to synergistic hepatic dysfunction in patients with coexisting alcoholic liver disease^[4]. Abstinence from alcohol use is the most fundamental step to

successfully treat AH, as demonstrated by a marked reduction in liver-related deaths during the alcohol prohibition era from 1920 to 1933 in the United States. Besides alcohol cessation, the management of AH includes treatment of alcohol withdrawal, correcting electrolyte and fluid abnormalities, optimizing nutritional status and assessing candidacy for pharmacological interventions. Severe AH, as defined by Maddrey's discriminant function ≥ 32 has been associated with poor prognosis with one-month mortality ranging between 25% to 35%. Despite clinical evaluation of numerous pharmacologic agents, only two, corticosteroids and pentoxifylline have been recommended by practice guidelines^[3]. There is no consensus regarding the preferred, first-line treatment option for AH. Nonetheless, early recognition leading to prompt diagnosis, presence or absence of cirrhosis and severity of AH are the key determinants of outcome.

PATHOPHYSIOLOGY OF ALCOHOLIC HEPATITIS

The alcohol-induced hepatic steatosis can largely be attributed to impairment of fatty acid oxidation through the expression of cytokines, reactive oxygen species, oxidative stress, and increased activity of lipogenic enzyme regulators including sterol regulatory element binding proteins (SREBPs) and SREBP-1^[7]. The most distinctive histologic feature of AH compared with other forms of hepatitis is predominantly neutrophilic inflammation. This has led to a wide spectrum of proposed theories regarding the pathophysiology of AH. The increased number of neutrophils may be reflective of the increased presence of cytokines, reactive oxygen species, and proteases within the hepatocytes. It has been suggested that pro-inflammatory cytokines including tumor necrosis factor alpha (TNF- α), interleukin-1 (IL-1), IL-6, and IL-8 are activated and secreted by Kupffer cells and other inflammatory cells (neutrophils and macrophages) following chronic alcohol exposure^[8,9]. In particular, IL-8 is well known for its chemotaxis activity, which may explain the increased presence of neutrophils. Other inflammatory cytokines including TNF- α , IL-1 and IL-6 are activated by the release of free radicals and oxygen reactive species induced by oxidative stress within hepatocytes and Kupffer cells. These inflammatory cytokines likely contribute to the pathophysiology of alcoholic liver disease as suggested by several studies^[8,9]. Imuro *et al*^[8] treated ethanol-fed mice with TNF- α antibodies. A reduction in the degree of hepatic inflammation and necrosis was noted in mice treated with TNF- α antibodies. In addition to TNF- α , cyclooxygenase 2 (COX-2) has also been shown to be elevated in mice fed with ethanol^[9]. COX-2 is an enzyme involved in the production of prostaglandins and thromboxane. Thus, raising the possibility of COX-2 inhibitors as a potential therapeutic

target^[9]. Other potential markers associated with AH include leukotriene B4 and lipopolysaccharides^[10,11].

The importance of an alcohol-induced increase in gut permeability as a mechanism underlying endotoxemia leading to activation of inflammatory cytokines is increasingly being recognized^[12]. Whether the increase in gut permeability is primarily gastroduodenal or intestinal remains under debate. However, evidence suggests that the increase in gut permeability following acute alcohol ingestion is longer lasting among patients with advanced liver disease, compared to normal controls^[12].

Alcohol is normally metabolized to aldehyde by the enzyme alcohol dehydrogenase (ADH), which is located in hepatocytes and gastric mucosa. ADH is a dimeric molecule composed of different subunits, which may explain the variations in blood alcohol levels in individuals who consume similar amount of alcohol. Aldehyde is further oxidized to acetate through the enzymatic activity of aldehyde dehydrogenase (ALDH) within the mitochondria. ALDH is also composed of multiple isoforms, which may explain the flushing phenomenon noted in 75% of Asians and is associated with the accumulation of aldehyde^[13]. In chronic alcoholics, the overabundance of ethanol leads to high enzymatic activity of ADH and ALDH, along with induction of the microsomal enzyme oxidation system, in particular the cytochrome CYP2E1^[14]. Both enzymes are predominantly located along the centrilobular portion of the hepatocytes, which is often the initial area of inflammation and fibrosis. The high enzymatic activity of cytochrome CYP2E1 causes increased production of reactive oxygen species, leading to chronic inflammatory changes as a result of oxidative stress. Aldehyde itself can also act as a highly reactive molecule, forming covalent bonds with amino acids attached to hepatocellular membrane, forming adducts that can be antigenic^[15]. Presence of adducts can trigger a cell-mediated cytotoxic reaction that can lead to hepatocellular damage. In addition to its immunologic effects, formation of adducts can disrupt epithelial tight junctions leading to increased permeability within hepatocytes and gastrointestinal tract.

HISTOPATHOLOGY OF ALCOHOLIC HEPATITIS

The histological features associated with alcohol-induced hepatocellular injury can be categorized into three distinct findings: alcoholic fatty liver (steatosis), alcoholic hepatitis and alcoholic cirrhosis^[16-21]. Hepatic steatosis, or fatty liver as a result of alcohol consumption is typically benign and reversible, but can rarely lead to lobular or perivenular fibrosis and death^[17-19].

Several factors including cytokines and alcohol byproducts as noted in the previous section contribute

to the development of AH-related steatosis, inflammation and fibrosis. It is important to note that hepatic steatosis, inflammation and fibrosis can often coexist in patients with AH. Histologically, AH is characterized by a wide spectrum of changes including micro- and macrovesicular steatosis, acute inflammation with predominantly neutrophilic infiltration, hepatocellular necrosis, perivenular and perisinusoidal fibrosis, and characteristic eosinophilic fibrillar material (Mallory's hyaline bodies) noted in ballooned hepatocytes. Although, traditionally Mallory's bodies have been associated with AH, these findings are not specific and can be seen in other forms of chronic liver disease. As noted earlier, the presence of focal intense lobular infiltration of neutrophils is what typically distinguishes AH from other forms of hepatitis, in which the inflammatory infiltrate is primarily composed of mononuclear cells. Typically, neutrophilic infiltration of perivenular region (zone 3) is noted during the early stages of AH. As the disease progresses, the histological changes expand towards the portal tracts. Alcoholic cirrhosis develops as a result of longstanding alcohol use and is characterized by collagen deposition around the central hepatic vein and along the sinusoids, resulting in a characteristic "chicken-wire" pattern of fibrosis and micronodular cirrhosis. On the other hand, patients with alcoholic cirrhosis who become abstinent develop macronodular cirrhosis due to the absence of alcohol and its anti-proliferative effect.

CLINICAL MANIFESTATIONS OF ALCOHOLIC HEPATITIS

Alcoholic hepatitis is a pro-inflammatory clinical syndrome resulting in a wide range of clinical manifestations. Patients with AH often present with long-standing history of alcohol use (> 100 g per day for 10 to 20 years). Typically, patients with AH present with an acute onset of symptomatic hepatitis with nonspecific symptoms such as anorexia, nausea, vomiting, right upper quadrant pain, proximal muscle wasting, and fever. In particular, excessive alcohol consumption is associated with the highest risk of developing AH. Some patients report drastic increase in their alcohol consumption secondary to recent life stressors such as a divorce, death of a loved one, and loss of employment. Once clinical symptoms develop, many patients develop aversion to alcohol and may discontinue alcohol use even up to several weeks prior to presentation, commonly resulting in misdiagnosis. Therefore, it is important to have an understanding of these salient clinical features of AH and to obtain a thorough history with a focus on timing of signs and symptoms of AH^[22-25]. The most common symptoms that lead patients to seek medical care include acute onset of worsening abdominal distension and icterus. Physical examination is notable for jaundice, hepatic encephalopathy, ascites, and

tender hepatomegaly. The tender hepatomegaly is due to the combined effects of hepatocyte swelling in setting of steatosis and stretching of hepatic capsule with subsequent stimulation of nociceptors resulting in painful sensation. Additionally, a **bruit** can occasionally be appreciated over the liver as a result of **increased hepatic blood flow**^[22]. Other nonspecific symptoms of AH include **fever** and **leukocytosis** with neutrophil predominance, which **may reflect** a potential infection, such as **spontaneous bacterial peritonitis** especially in the setting of ascites, can occur solely due to AH. While it is worthwhile to **rule out infectious sources** given degree of immunosuppression from **malnutrition**, it is also important to understand that **fever** and **leukocytosis** may be **commonly** seen in the presentation of **alcoholic hepatitis**. Nevertheless, the **importance of evaluating for infection** among patients with AH cannot be understated as at least a **quarter of patients have coexistent infections**^[26]. Specifically, **nonresponse to steroids is most predictive of infection** and worse survival in this patient population^[26].

Neutrophil predominance has also been noted in liver **biopsies** of patients with alcoholic hepatitis. Extremely high leukocyte counts (leukemoid reactions) have rarely been seen with alcoholic hepatitis and is associated with high mortalities^[25]. Other clinical features include ascites that may be due to transient **elevation in portal pressure from hepatocyte swelling** or from portal hypertension secondary to cirrhosis. In addition, hepatic **encephalopathy** and **hepatorenal syndrome**, both of which are poor prognostic indicators and **can still occur** in patients with AH in the **absence of cirrhosis**. Many patients with AH develop noticeable malnutrition. According to one study, **malnutrition is noted in greater than 90% of patients with AH**^[23]. Malnutrition may manifest clinically as **temporal muscle wasting**, **proximal muscle atrophy**, and generalized weakness. **Malnourishment** can be evident through laboratory findings including **macrocytosis**, which is suggestive of longstanding **folic acid** and **cobalamin deficiency** triggered by **alcohol** consumption.

The most **commonly** noted laboratory abnormality associated with AH is an **elevated bilirubin level**. Other abnormalities in laboratory tests include **moderately elevated transaminases** (usually less than 300 IU/mL) with an **AST to ALT ratio > 2**; elevated gamma-glutamyl transpeptidase (GGT); **leukocytosis** (with neutrophil predominance); **macrocytosis** (due to primary bone marrow hypoplasia from **folic acid/cobalamin deficiency** and **alcohol toxicity**); **thrombocytopenia** (due to primary bone marrow hypoplasia and **splenic sequestration**); and **coagulopathy** due to impaired production of coagulation factors and **malnutrition** resulting in **poor vitamin K intake**. The **ratio of ALT to AST** is more **specific for alcoholic liver disease** due to hepatic **deficiency of pyridoxal 5'-phosphate** in **alcoholic liver disease**, which serves as a **cofactor for ALT**^[23]. ALT plays a key **role** in the intermediate metabolism of **glucose** and **amino acids**. The lack of

pyridoxal 5'-phosphate or activated vitamin B6 leads to a **decreased expression of ALT**. In other words, the **AST to ALT ratio is primarily due to inappropriate increase in ALT rather than an increase in AST**.

DIAGNOSIS OF ALCOHOLIC HEPATITIS

The diagnosis of AH is made by comprehensive evaluation of clinical manifestations and laboratory data in a patient with history of alcohol consumption. A dedicated and thorough history-taking may provide the earliest clinical clues of underlying alcoholic liver disease. Most patients with AH may not be forthcoming due to the social stigma associated with the diagnosis of alcoholic liver disease. Therefore, patients may deemphasize the duration and amount of alcohol intake. Occasionally, discussions with family members and friends may provide a more accurate history and details regarding alcohol consumption. Due to the **nonspecific nature of clinical and laboratory findings in alcoholic liver disease**, **appropriate serological, virological, immunological and genetic tests should be performed to exclude other known etiologies of liver disease**. Acetaminophen toxicity, acute **viral hepatitis**, **ischemic hepatitis**, **Budd-Chiari syndrome**, **autoimmune hepatitis**, or **drug-related liver injury** can be **ruled out** by carefully reviewing the past medical history (medications, allergies, social history, travel history, family history, etc.), chronology of clinical manifestations, pattern of abnormalities in liver function tests (liver enzymes, total bilirubin and hepatic synthetic function), toxicology screen and diagnostic studies^[27]. In patients with coexisting liver disease or unclear history of alcohol consumption, it is **may be helpful to confirm the diagnosis of AH with a liver biopsy**. Up to **20%** patients who are **initially suspected of alcoholic liver disease** demonstrate evidence of **nonalcoholic causes of liver disease on liver biopsy**^[28]. These clinical scenarios may underscore the **importance of a liver biopsy** in this patient population to **confirm the diagnosis** of AH before starting therapy with immunosuppressive agent, such as corticosteroids. Due to the **increased risk of bleeding in patients with coagulopathy**, a **transjugular liver biopsy may provide the safest approach**. Finally, a liver biopsy can provide **prognostic information** regarding the **reversibility** of alcoholic liver disease by characterizing the extent and severity of underlying histologic damage^[28,29].

TREATMENT OF ALCOHOLIC HEPATITIS

Early recognition and diagnosis is crucial in optimizing the management of AH. The treatment of AH requires a multidisciplinary approach that focuses on alcohol cessation, psychosocial evaluation, pharmacologic therapy of AH and treatment of other complications of alcoholic liver disease including withdrawal and nutritional support. Patients should also be considered

for referral to an alcohol and drug rehabilitation center prior to discharge from the hospital.

BEHAVIORAL TREATMENT

Abstinence

Alcohol abstinence is the most essential step towards optimizing the management of patients with AH. Alcohol-induced liver damage without evidence of cirrhosis may actually be reversible with alcohol abstinence^[30]. However, the rate at which the liver enzymes return to normal has been variable, typically ranging from a few weeks to several months. Data from nonrandomized trials and retrospective analyses have supported the role of abstinence in patients with alcoholic liver damage^[31-34]. It was noted that the five-year survival rate for patients with compensated cirrhosis who abstained from alcohol was 63% to 90% vs 41% to 70% in those with continued alcohol use^[32,33]. Most liver transplant centers require a 6-month period of documented alcohol cessation prior to initiating an evaluation for liver transplantation.

Interventions including motivational interviewing, cognitive behavioral therapy, and peer support groups have been employed in an effort to maintain compliance. Studies have suggested that there is a small but significant beneficial effect; the actual benefit of these interventions is unclear as data on abstinence maintenance from alcohol use are poor^[35]. Therefore, several agents have been studied in order to help maintain abstinence, including naltrexone, nalmefene, acamprosate, and baclofen. Chronic alcohol use results in a change of baseline balance between neuro-excitatory and inhibitory pathways leading to a net neuronal hyperexcitability^[36]. Acamprosate (*n*-acetyl-homotaurine), a structurally similar molecule to excitatory amino acids, blocks the neuronal hyperexcitability pathway by acting as a competitive inhibitor^[37-39]. The opioid antagonist, naltrexone, exerts an inhibitory effect on the center for alcohol craving in the central nervous system resulting in reduction in alcohol consumption^[40]. Nalmefene is another opioid antagonist that has been shown to reduce the amount of alcohol intake^[41]. Nalmefene has demonstrated several favorable properties compared to naltrexone including longer duration of action, absence of dose-dependent liver injury, and broader action on central nervous system opiate receptors^[41-44]. Baclofen, a gamma-aminobutyric acid agonist acts on the central nervous system and inhibits alcohol craving^[45]. Baclofen is the only anti-craving medication to date that has been studied in the context of advanced liver disease^[46]. Larger clinical trials are needed to reproduce and confirm the efficacy of these medications.

NUTRITIONAL TREATMENT

Nutrition replacement therapy

As noted above, over 90% of patients with alcoholic hepatitis are also found to have significant malnutrition^[47]. Chronic alcohol use induces a profound catabolic state by suppression of appetite, leading to poor oral intake of essential micro- and macronutrients. Additionally, the risk of death from alcoholic hepatitis has been shown to be closely associated with degree of malnutrition^[47,48]. Significant protein-calorie malnutrition (PCM) can be commonly seen in these patients, particularly those with jaundice and hepatic encephalopathy^[2,49]. Despite the theoretical risk of worsening hepatic encephalopathy, the benefits of an increased protein diet outweigh the risk of hepatic encephalopathy given the degree of malnutrition.

Numerous clinical trials have been performed to further evaluate the impact of nutritional replacement therapy^[2,50-54]. One randomized, and controlled trial compared enteral tube feedings to prednisolone therapy for four weeks in patients with severe alcoholic hepatitis. The survival rate between the two groups was similar after 28 d and after one year^[55]. However there have been other studies which showed a high variability of results, likely due to the high variability with severity of hepatic decompensation and malnutrition^[51-53]. In general, the degree of malnutrition is clearly associated with the response to nutritional replacement therapy. Hence, an aggressive nutritional replacement therapy should be considered for patients with PCM and evidence of severe hepatic decompensation^[2]. It is worth noting that although some of these studies have shown improvement in biochemical tests and nutritional status, only a few of them have actually demonstrated any survival benefit^[53,54].

Branched-chain amino acids

Many patients require significant protein nutritional support. However, protein ingestion may theoretically increase the risk of hepatic encephalopathy. Despite this risk, the use of specific supplements, in particular the branched-chain amino acids (BCCA), has produced some promising results^[56-58]. The rationale for using BCCA as supplementation in patients with alcoholic cirrhosis is to provide protein calories that can be metabolized without the use of the liver. In patients with alcoholic hepatitis, hepatic enzymatic activity may be compromised, leading to an inability to extract maximal calories for the human body. The use of BCCA allows for improved utilization of protein calories. Thus BCCA may improve nutritional status, fulfill metabolic needs, and decrease the risk of hepatic encephalopathy^[56]. Despite the rationale for BCCA, there appears to be no advantage in most patients^[57,58].

Table 1 Scoring systems for evaluating severity of alcoholic hepatitis

Scoring system	
Maddrey DF	The DF, based on the prothrombin time and total bilirubin, is most commonly used in the decision to treat AH. The DF is a prognostic model at baseline, or static model, similar to MELD and GAHS
MELD	The MELD score, calculated from creatinine, total bilirubin, and international normalized ratio, is classically used for liver transplantation waitlist prioritization but can also be applied as a prognostic indicator in AH
GAHS	The GAHS is calculated based on age, white blood cell count, blood urea nitrogen, total bilirubin, and prothrombin time. The GAHS is another static model that can identify patients at high risk for short-term mortality
Lille score	The Lille model is a dynamic model, which includes the baseline total bilirubin level and the total bilirubin seven days into treatment. Other variables included in the model are age, albumin, creatinine, and prothrombin time. The Lille model is most accurate among these scoring systems in identifying the degree of response to therapy in AH ^[97]

AH: Alcoholic hepatitis; DF: Discriminant function; MELD: Model for end-stage liver disease; GAHS: Glasgow alcoholic hepatitis score.

Furthermore, clinicians should not restrict protein intake in patients with alcoholic hepatitis even in the setting of hepatic encephalopathy^[59]. **BCCA** supplementation should **only** be **considered** in the setting of **worsening encephalopathy** while on a **protein** rich diet **despite lactulose** treatment^[59].

PHARMACOLOGICAL TREATMENT

Corticosteroids

There have been numerous studies published that have analyzed the effects of corticosteroid treatment on patients with alcoholic hepatitis. The purpose for corticosteroid therapy is to **suppress the inflammatory cytokine cycle**^[60,61] that predisposes the propagation of liver disease through chronic inflammation. Corticosteroids have been shown to **suppress cytokine production**, interfere with adduct formation, and inhibit collagen production, thereby reducing hepatocellular injury^[62,63]. **Corticosteroid** therapy, primarily prednisolone, is one of the therapies **recommended** by the American Association for the Study of Liver Disease and the European Association for the Study of the Liver. Regarding treatment, **prednisolone** is typically **preferred over prednisone** as **prednisone requires hepatic conversion** to the **active** form **prednisolone**. This conversion process may be impaired in patients with alcoholic hepatitis. Treatment course typically consists of **prednisolone 40 mg per day for 28 d, followed by a taper for 2 to 4 wk.**

Numerous clinical trials including randomized and meta-analyses have addressed the role of corticosteroid use in alcoholic hepatitis^[49,64-76]. These

include studies that demonstrated no improvement in outcomes compared to the control group^[49,69], along with those that showed corticosteroid therapy conferred an improvement in short-term mortality in those with severe alcoholic hepatitis. However, the studies that revealed no difference in mortality compared to placebo included patients with differing severities of alcoholic hepatitis. A 2008 Cochrane meta-analysis was performed on 15 randomized trials that compared glucocorticoid therapy with placebo, which revealed a trend towards mortality benefit that did not reach statistical significance. However subgroup analyses involving severe alcoholic hepatitis [Maddrey's discriminant function (DF) ≥ 32] (Table 1) revealed that there was a reduction in 28-d mortality compared to those treated with placebo (20% vs 34%)^[77]. Additional meta-analyses have also examined mortality benefit with treatment of severe alcoholic hepatitis, including using other models to assess disease severity including Lille score. This meta-analysis demonstrated that treatment with corticosteroids showed mortality benefit in those with Lille score < 0.56 after one week of treatment. Concerns over corticosteroid use center around the risks of complications, including infection, gastrointestinal bleed, encephalopathy, pancreatitis, glucose intolerance, and psychoses.

In summary, multiple practical guidelines suggest the use of corticosteroids in the setting of severe alcoholic hepatitis, provided that there are no contraindications. **In particular patients with severe alcoholic hepatitis as defined by Maddrey's DF ≥ 32 are candidates for corticosteroid therapy.** It is also important to ensure **reversible causes** of hepatic encephalopathy such as **infections, fluid and electrolyte abnormalities, sedatives, or gastrointestinal bleeding** should be **ruled out** and treated appropriately. In situations in which the patient has concomitant chronic liver disease or when the **diagnosis** is in **doubt**, it may be reasonable to **confirm** the diagnosis of alcoholic hepatitis with a **liver biopsy** before committing a patient to corticosteroid therapy. A few studies have suggested that **up to one-fifth of patients with an initial clinical suspicion for alcoholic hepatitis lacked histologic evidence of alcoholic hepatitis on liver biopsy.** This stresses the importance of establishing a correct diagnosis as certain studies have suggested a **25% reduction in mortality with treatment.** It is also important to recognize that even in the setting of an accurate diagnosis, there is **still a high mortality in patients receiving steroids**^[76]. The balance between maximizing the benefits and minimizing the risks associated with corticosteroid use depends on accurate diagnosis and effective patient selection for treatment. Patients with active infections or other comorbidities may have to be managed conservatively as many of these patients were excluded from the studies. With regards to alcoholic cirrhosis, retrospective data from two clinical trials were unable to establish a clinical benefit with corticosteroid use^[69].

Pentoxifylline

Pentoxifylline has been considered an alternative treatment for patients with severe alcoholic hepatitis, largely due to its good safety profile along with the lack of other alternative medications to corticosteroids. However, the evidence supporting use of pentoxifylline is much weaker. Pentoxifylline exhibits its effect by inhibiting the production of TNF- α (increased in alcoholic hepatitis) by altering its gene transcription^[78]. Initial studies occurred in the early 1990's in which a randomized, double-blind, placebo-controlled trial of pentoxifylline vs placebo was performed. Pentoxifylline 400 mg orally three times a day vs placebo was compared in 101 patients with severe alcoholic hepatitis. This study revealed a survival benefit in those treated with pentoxifylline compared to placebo (25% mortality vs 46% mortality) during the initial hospitalization^[22]. Further subgroup analysis suggested that the root of its survival benefit occurred within the population that developed hepatorenal syndrome (50% deaths in treatment group and 92% deaths in placebo group). This study suggested that pentoxifylline may help to decrease risk of hepatorenal syndrome in patients with severe acute alcoholic hepatitis. A follow-up meta-analysis and systematic review also examined whether such a benefit could be duplicated but these studies failed to show a significant effect on survival benefit^[79-81]. Nevertheless, there has been an increasing trend for physicians to treat alcoholic hepatitis with pentoxifylline given its good safety profile and concern with prescribing long-term glucocorticoids in patients with alcohol abuse and dependence.

Corticosteroids vs pentoxifylline

Studies have also examined the combination use of corticosteroids with pentoxifylline. To date, the evidence suggests that there is no additive benefit to pentoxifylline comparing glucocorticoids and pentoxifylline with glucocorticoid therapy alone. Studies fail to demonstrate a difference in survival at six months or occurrence of hepatorenal syndrome^[82]. However, up until 2014, there have been no significant head-to-head trials between corticosteroids and pentoxifylline. A recent study from Korea directly compared the efficacy of short-term mortality between prednisolone and pentoxifylline. This was an open-labeled non-inferiority study performed at multiple centers. At one month, the survival rate for corticosteroids was greater than the pentoxifylline (88.1% vs 75.8%). Other interesting findings included an improved response to therapy with corticosteroids compared to pentoxifylline as assessed by the Lille model, suggesting a non-equivalent treatment efficacy of pentoxifylline compared to corticosteroid use^[82]. The Steroids or Pentoxifylline for Alcoholic Hepatitis (STOPAH) trial is a large multi-center, double-blind, randomized trial conducted in the United Kingdom that compared the different treatment arms of corticosteroid, pentoxifylline, and corticosteroid with pentoxifylline in

patients with severe alcoholic hepatitis^[83]. The primary end point was mortality at 28 d. The mortality at 28 d was 17% in the placebo-placebo group, 14% in the prednisolone-placebo group, 19% in the pentoxifylline-placebo group, and 13% in the prednisolone-pentoxifylline group. Serious infections were noted in 13% of patients treated with prednisolone vs 7% in those treated without prednisolone. This study found prednisolone to be associated with a reduction in 28-d mortality; however, the reduction did not reach significance. Another notable finding was that pentoxifylline did not improve survival in patients with severe alcoholic hepatitis compared to the placebo group. Neither treatment arms reflected improvement in 90-d and one year mortality. This study reaffirms that corticosteroids should still be considered over pentoxifylline for the initial course of treatment for severe alcoholic hepatitis as it has only shown benefit for short-term mortality (Figure 1). This also stresses the difficulties involved with treatment of severe alcoholic hepatitis, and reiterates the high morbidity of this disease.

Other pharmacologic agents

Multiple pharmacologic agents have also been studied to determine if there is any improvement with morbidity and mortality to patients with alcoholic hepatitis. These agents include anabolic steroids, propylthiouracil, colchicine, insulin and glucagon, phosphatidylcholine, infliximab and etanercept. Altogether, no strong, conclusive results are available that have prompted a change in the recommended therapies by the American Association for the Study of Liver Disease and the European Association for the Study of the Liver.

Anti-TNF- α antibodies

Anti-TNF- α antibodies were considered among the most promising potential therapies for alcoholic hepatitis. Levels of the cytokine correlated strongly with severity of disease in AH and low levels were associated with liver regeneration^[84]. Based on a feasibility study in 20 patients with biopsy-proven severe AH, anti-TNF- α therapy in addition to prednisone was associated with significant reduction in Maddrey's DF at day 28 compared to prednisone alone^[85]. However, two larger randomized controlled trials evaluating anti-TNF- α therapy failed to demonstrate benefit and even suggested harm^[86,87]. Therefore, use of anti-TNF- α therapy in AH to date remains investigational.

SURGICAL TREATMENT

Liver transplantation

For patients with end-stage liver disease secondary to alcoholic cirrhosis, including those who fail to respond to medical treatment, liver transplantation is the treatment of choice^[88,89]. Patients with alcoholic cirrhosis can be considered for liver transplantation

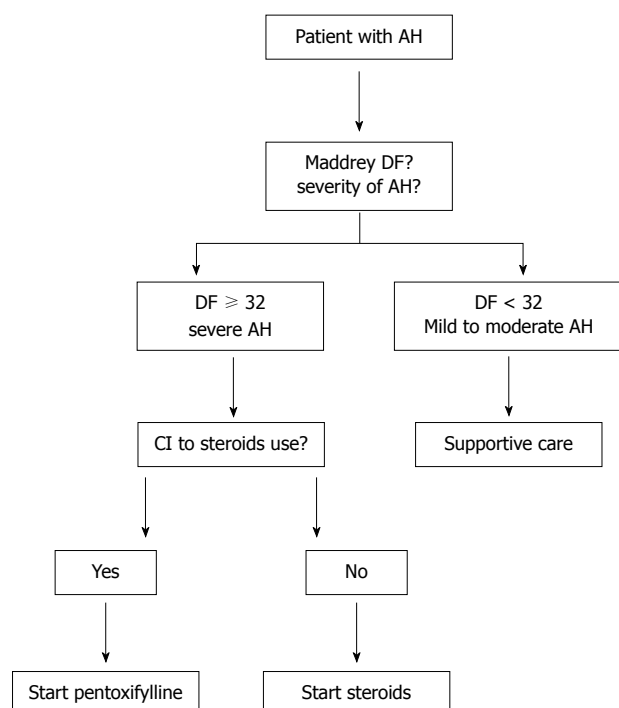


Figure 1 Algorithm to optimize the management of alcoholic hepatitis. $DF = 4.6 \times [\text{prothrombin time (s)} - \text{control prothrombin time}] + \text{serum total bilirubin (mg/dL)}$. AH: Alcoholic hepatitis; DF: Discriminant function; CI: Contraindications.

if required listing criteria is met. Multiple factors are evaluated including maintenance of sobriety for at least 6 months, as well as no medical and/or psychosocial contraindications. One issue to consider is whether post-transplant patients are more likely to experience severe recurrent disease. This was noted in a study in which alcohol relapse after liver transplantation was associated with advanced allograft fibrosis and decreased graft survival^[90]. Other studies have shown that the duration of pre-transplant abstinence has been a poor predictor for post-transplant sobriety^[91-93]. Recurrence of alcohol intake is relatively high following liver transplantation for alcoholic cirrhosis, with some studies suggesting up to 15% patients resume heavy alcohol use, while about 20% to 50% undergo occasional alcohol use^[41,50]. Of those patients who underwent liver transplantation, studies show that short-term survival at 1 year was greater than 70%. For highly selective patients, liver transplantation can be life-saving and more cost effective than prolonged medical management of alcoholic cirrhosis^[94,95].

FUTURE TREATMENT

In addition to enteral feeds for nutritional support, there are other potential treatments for alcoholic hepatitis. N-acetylcysteine (NAC) has been theorized to exhibit its hepatoprotective effects by acting as an antioxidant. A randomized trial was conducted with 174 patients studying combination of prednisolone with NAC vs prednisolone alone^[96]. Although the one-

month mortality for prednisolone alone was higher compared to prednisolone with NAC (38% vs 27%), it did not reach statistical significance. The primary end point for the study looked at six-month mortality, which did not reveal any additional advantage to the addition of NAC to prednisolone vs prednisolone alone. Given the finding of improved survival at one-month, additional studies in this direction may be worthwhile.

REFERENCES

- American Psychiatric Association. Diagnostic and statistical manual of mental disorders. 4th ed. Washington: DC, 2000
- Mendenhall CL, Moritz TE, Roselle GA, Morgan TR, Nemchausky BA, Tamburro CH, Schiff ER, McClain CJ, Marsano LS, Allen JI. A study of oral nutritional support with oxandrolone in malnourished patients with alcoholic hepatitis: results of a Department of Veterans Affairs cooperative study. *Hepatology* 1993; **17**: 564-576 [PMID: 8477961]
- European Association for the Study of Liver. EASL clinical practical guidelines: management of alcoholic liver disease. *J Hepatol* 2012; **57**: 399-420 [PMID: 22633836]
- Naveau S, Giraud V, Borotto E, Aubert A, Capron F, Chaput JC. Excess weight risk factor for alcoholic liver disease. *Hepatology* 1997; **25**: 108-111 [PMID: 8985274]
- Bellentani S, Saccoccio G, Costa G, Tiribelli C, Manenti F, Sodde M, Saveria Crocè L, Sasso F, Pozzato G, Cristianini G, Brandi G. Drinking habits as cofactors of risk for alcohol induced liver damage. The Dionysos Study Group. *Gut* 1997; **41**: 845-850 [PMID: 9462221]
- Becker U, Deis A, Sørensen TI, Grønbaek M, Borch-Johnsen K, Müller CF, Schnohr P, Jensen G. Prediction of risk of liver disease by alcohol intake, sex, and age: a prospective population study. *Hepatology* 1996; **23**: 1025-1029 [PMID: 8621128]
- You M, Fischer M, Deeg MA, Crabb DW. Ethanol induces fatty acid synthesis pathways by activation of sterol regulatory element-binding protein (SREBP). *J Biol Chem* 2002; **277**: 29342-29347 [PMID: 12036955]
- Iimuro Y, Gallucci RM, Luster MI, Kono H, Thurman RG. Antibodies to tumor necrosis factor α attenuate hepatic necrosis and inflammation caused by chronic exposure to ethanol in the rat. *Hepatology* 1997; **26**: 1530-1537 [PMID: 9397994]
- Nanji AA, Zakim D, Rahemtulla A, Daly T, Miao L, Zhao S, Khwaja S, Tahan SR, Dannenberg AJ. Dietary saturated fatty acids down-regulate cyclooxygenase-2 and tumor necrosis factor α and reverse fibrosis in alcohol-induced liver disease in the rat. *Hepatology* 1997; **26**: 1538-1545 [PMID: 9397995]
- Roll FJ, Perez HD, Serhan CN. Characterization of a novel arachidonic acid-derived neutrophil chemoattractant. *Biochem Biophys Res Commun* 1992; **186**: 269-276 [PMID: 1632770]
- Bode C, Kugler V, Bode JC. Endotoxemia in patients with alcoholic and non-alcoholic cirrhosis and in subjects with no evidence of chronic liver disease following acute alcohol excess. *J Hepatol* 1987; **4**: 8-14 [PMID: 3571935]
- Rao R. Endotoxemia and gut barrier dysfunction in alcoholic liver disease. *Hepatology* 2009; **50**: 638-644 [PMID: 19575462]
- Bosron WF, Ehrig T, Li TK. Genetic factors in alcohol metabolism and alcoholism. *Semin Liver Dis* 1993; **13**: 126-135 [PMID: 8337601]
- Tsutsumi M, Lasker JM, Takahashi T, Lieber CS. In vivo induction of hepatic P4502E1 by ethanol: role of increased enzyme synthesis. *Arch Biochem Biophys* 1993; **304**: 209-218 [PMID: 8323286]
- Tuma DJ. Role of malondialdehyde-acetaldehyde adducts in liver injury. *Free Radic Biol Med* 2002; **32**: 303-308 [PMID: 11841919]
- Lieber CS, DeCarli LM. Metabolic effects of alcohol on the liver. In: Lieber CS, editors. *Metabolic Aspects of Alcoholism*. Baltimore: University Park Press, 1977: 31-80
- Caulet S, Fabre M, Schoevaert D, Lesty C, Meduri G, Martin E.

- Quantitative study of centrilobular hepatic fibrosis in alcoholic disease before cirrhosis. *Virchows Arch A Pathol Anat Histopathol* 1989; **416**: 11-17 [PMID: 2510397]
- 18 **Sørensen TI**, Orholm M, Bentsen KD, Høybye G, Eghøj K, Christoffersen P. Prospective evaluation of alcohol abuse and alcoholic liver injury in men as predictors of development of cirrhosis. *Lancet* 1984; **2**: 241-244 [PMID: 6146805]
 - 19 **Nakano M**, Worner TM, Lieber CS. Perivenular fibrosis in alcoholic liver injury: ultrastructure and histologic progression. *Gastroenterology* 1982; **83**: 777-785 [PMID: 7106508]
 - 20 **Deaciuc IV**, Fortunato F, D'Souza NB, Hill DB, McClain CJ. Chronic alcohol exposure of rats exacerbates apoptosis in hepatocytes and sinusoidal endothelial cells. *Hepatol Res* 2001; **19**: 306-324 [PMID: 11251313]
 - 21 **McClain CJ**, Hill DB, Song Z, Deaciuc I, Barve S. Monocyte activation in alcoholic liver disease. *Alcohol* 2002; **27**: 53-61 [PMID: 12062638]
 - 22 **Akriviadis E**, Botla R, Briggs W, Han S, Reynolds T, Shakil O. Pentoxifylline improves short-term survival in severe acute alcoholic hepatitis: a double-blind, placebo-controlled trial. *Gastroenterology* 2000; **119**: 1637-1648 [PMID: 11113085]
 - 23 **Sass DA**, Shaikh OS. Alcoholic hepatitis. *Clin Liver Dis* 2006; **10**: 219-237, vii [PMID: 16971259]
 - 24 **Diehl AM**, Potter J, Boitnott J, Van Duyn MA, Herlong HF, Mezey E. Relationship between pyridoxal 5'-phosphate deficiency and aminotransferase levels in alcoholic hepatitis. *Gastroenterology* 1984; **86**: 632-636 [PMID: 6698365]
 - 25 **Mitchell RG**, Michael M, Sandidge D. High mortality among patients with the leukemoid reaction and alcoholic hepatitis. *South Med J* 1991; **84**: 281-282 [PMID: 1990473]
 - 26 **Louvet A**, Wartel F, Castel H, Dharancy S, Hollebecque A, Canva-Delcambre V, Deltenre P, Mathurin P. Infection in patients with severe alcoholic hepatitis treated with steroids: early response to therapy is the key factor. *Gastroenterology* 2009; **137**: 541-548 [PMID: 19445945]
 - 27 **Christoffersen P**, Nielsen K. Histological changes in human liver biopsies from chronic alcoholics. *Acta Pathol Microbiol Scand A* 1972; **80**: 557-565 [PMID: 5056834]
 - 28 **Levin DM**, Baker AL, Riddell RH, Rochman H, Boyer JL. Nonalcoholic liver disease. Overlooked causes of liver injury in patients with heavy alcohol consumption. *Am J Med* 1979; **66**: 429-434 [PMID: 433949]
 - 29 **Talley NJ**, Roth A, Woods J, Hench V. Diagnostic value of liver biopsy in alcoholic liver disease. *J Clin Gastroenterol* 1988; **10**: 647-650 [PMID: 3068303]
 - 30 **Teli MR**, Day CP, Burt AD, Bennett MK, James OF. Determinants of progression to cirrhosis or fibrosis in pure alcoholic fatty liver. *Lancet* 1995; **346**: 987-990 [PMID: 7475591]
 - 31 **Brunt PW**, Kew MC, Scheuer PJ, Sherlock S. Studies in alcoholic liver disease in Britain. I. Clinical and pathological patterns related to natural history. *Gut* 1974; **15**: 52-58 [PMID: 4362373]
 - 32 **Powell WJ**, Klatzkin G. Duration of survival in patients with Laennec's cirrhosis. Influence of alcohol withdrawal, and possible effects of recent changes in general management of the disease. *Am J Med* 1968; **44**: 406-420 [PMID: 5641303]
 - 33 **Alexander JF**, Lischner MW, Galambos JT. Natural history of alcoholic hepatitis. II. The long-term prognosis. *Am J Gastroenterol* 1971; **56**: 515-525 [PMID: 5134879]
 - 34 **Galambos JT**. Natural history of alcoholic hepatitis. 3. Histological changes. *Gastroenterology* 1972; **63**: 1026-1035 [PMID: 4639358]
 - 35 **Karman JF**, Sileri P, Kamuda D, Cicalese L, Rastellini C, Wiley TE, Layden TJ, Benedetti E. Risk factors for failure to meet listing requirements in liver transplant candidates with alcoholic cirrhosis. *Transplantation* 2001; **71**: 1210-1213 [PMID: 11397951]
 - 36 **Zeise ML**, Kasparov S, Capogna M, Zieglgänsberger W. Acamprosate (calciumacetylhomotaurinate) decreases postsynaptic potentials in the rat neocortex: possible involvement of excitatory amino acid receptors. *Eur J Pharmacol* 1993; **231**: 47-52 [PMID: 8444281]
 - 37 **Lhuintre JP**, Moore N, Tran G, Steru L, Langrenon S, Daoust M, Parot P, Ladure P, Libert C, Boismare F. Acamprosate appears to decrease alcohol intake in weaned alcoholics. *Alcohol Alcohol* 1990; **25**: 613-622 [PMID: 2085344]
 - 38 **Brasser SM**, McCaul ME, Houtsmuller EJ. Alcohol effects during acamprosate treatment: a dose-response study in humans. *Alcohol Clin Exp Res* 2004; **28**: 1074-1083 [PMID: 15252294]
 - 39 **Paille FM**, Guelfi JD, Perkins AC, Royer RJ, Steru L, Parot P. Double-blind randomized multicentre trial of acamprosate in maintaining abstinence from alcohol. *Alcohol Alcohol* 1995; **30**: 239-247 [PMID: 7662044]
 - 40 **Volpicelli JR**, Clay KL, Watson NT, O'Brien CP. Naltrexone in the treatment of alcoholism: predicting response to naltrexone. *J Clin Psychiatry* 1995; **56** Suppl 7: 39-44 [PMID: 7673104]
 - 41 **Gual A**, He Y, Torup L, van den Brink W, Mann K. A randomised, double-blind, placebo-controlled, efficacy study of nalmefene, as-needed use, in patients with alcohol dependence. *Eur Neuropsychopharmacol* 2013; **23**: 1432-1442 [PMID: 23562264]
 - 42 **Jonas DE**, Amick HR, Feltner C, Bobashev G, Thomas K, Wines R, Kim MM, Shanahan E, Gass CE, Rowe CJ, Garbutt JC. Pharmacotherapy for adults with alcohol use disorders in outpatient settings: a systematic review and meta-analysis. *JAMA* 2014; **311**: 1889-1900 [PMID: 24825644]
 - 43 **Mann K**, Bladström A, Torup L, Gual A, van den Brink W. Extending the treatment options in alcohol dependence: a randomized controlled study of as-needed nalmefene. *Biol Psychiatry* 2013; **73**: 706-713 [PMID: 23237314]
 - 44 **Karhuvaara S**, Simojoki K, Virta A, Rosberg M, Löyttyntiemi E, Nurminen T, Kallio A, Mäkelä R. Targeted nalmefene with simple medical management in the treatment of heavy drinkers: a randomized double-blind placebo-controlled multicenter study. *Alcohol Clin Exp Res* 2007; **31**: 1179-1187 [PMID: 17451401]
 - 45 **Addolorato G**, Caputo F, Capristo E, Domenicali M, Bernardi M, Janiri L, Agabio R, Colombo G, Gessa GL, Gasbarrini G. Baclofen efficacy in reducing alcohol craving and intake: a preliminary double-blind randomized controlled study. *Alcohol Alcohol* 2002; **37**: 504-508 [PMID: 12217947]
 - 46 **Addolorato G**, Leggio L, Ferrulli A, Cardone S, Vonghia L, Mirijello A, Abenavoli L, D'Angelo C, Caputo F, Zamboni A, Haber PS, Gasbarrini G. Effectiveness and safety of baclofen for maintenance of alcohol abstinence in alcohol-dependent patients with liver cirrhosis: randomised, double-blind controlled study. *Lancet* 2007; **370**: 1915-1922 [PMID: 18068515]
 - 47 **Mendenhall CL**, Tosch T, Weesner RE, Garcia-Pont P, Goldberg SJ, Kiernan T, Seeff LB, Sorell M, Tamburro C, Zetterman R. VA cooperative study on alcoholic hepatitis. II: Prognostic significance of protein-calorie malnutrition. *Am J Clin Nutr* 1986; **43**: 213-218 [PMID: 3080866]
 - 48 **Mendenhall CL**, Anderson S, Weesner RE, Goldberg SJ, Crolic KA. Protein-calorie malnutrition associated with alcoholic hepatitis. Veterans Administration Cooperative Study Group on Alcoholic Hepatitis. *Am J Med* 1984; **76**: 211-222 [PMID: 6421159]
 - 49 **Mendenhall CL**, Anderson S, Garcia-Pont P, Goldberg S, Kiernan T, Seeff LB, Sorell M, Tamburro C, Weesner R, Zetterman R. Short-term and long-term survival in patients with alcoholic hepatitis treated with oxandrolone and prednisolone. *N Engl J Med* 1984; **311**: 1464-1470 [PMID: 6390194]
 - 50 **Bonkovsky HL**, Singh RH, Jafri IH, Fiellin DA, Smith GS, Simon D, Cotsonis GA, Slaker DP. A randomized, controlled trial of treatment of alcoholic hepatitis with parenteral nutrition and oxandrolone. II. Short-term effects on nitrogen metabolism, metabolic balance, and nutrition. *Am J Gastroenterol* 1991; **86**: 1209-1218 [PMID: 1909086]
 - 51 **Naveau S**, Pelletier G, Poynard T, Attali P, Poirine A, Buffet C, Etienne JP, Chaput JC. A randomized clinical trial of supplementary parenteral nutrition in jaundiced alcoholic cirrhotic patients. *Hepatology* 1986; **6**: 270-274 [PMID: 3082733]
 - 52 **Diehl AM**, Boitnott JK, Herlong HF, Potter JJ, Van Duyn MA, Chandler E, Mezey E. Effect of parenteral amino acid

- supplementation in alcoholic hepatitis. *Hepatology* 1985; **5**: 57-63 [PMID: 3917968]
- 53 **Cabre E**, Gonzalez-Huix F, Abad-Lacruz A, Esteve M, Acero D, Fernandez-Bañares F, Xiol X, Gassull MA. Effect of total enteral nutrition on the short-term outcome of severely malnourished cirrhotics. A randomized controlled trial. *Gastroenterology* 1990; **98**: 715-720 [PMID: 2105256]
- 54 **Mendenhall C**, Roselle GA, Gartside P, Moritz T. Relationship of protein calorie malnutrition to alcoholic liver disease: a reexamination of data from two Veterans Administration Cooperative Studies. *Alcohol Clin Exp Res* 1995; **19**: 635-641 [PMID: 7573786]
- 55 **Cabr   E**, Rodr  guez-Iglesias P, Caballer   J, Quer JC, S  nchez-Lombr  a JL, Par  s A, Papo M, Planas R, Gassull MA. Short- and long-term outcome of severe alcohol-induced hepatitis treated with steroids or enteral nutrition: a multicenter randomized trial. *Hepatology* 2000; **32**: 36-42 [PMID: 10869286]
- 56 **Fabbri A**, Magrini N, Bianchi G, Zoli M, Marchesini G. Overview of randomized clinical trials of oral branched-chain amino acid treatment in chronic hepatic encephalopathy. *JPEN J Parenter Enteral Nutr* 1996; **20**: 159-164 [PMID: 8676537]
- 57 **Marchesini G**, Dioguardi FS, Bianchi GP, Zoli M, Bellati G, Roffi L, Martines D, Abbiati R. Long-term oral branched-chain amino acid treatment in chronic hepatic encephalopathy. A randomized double-blind casein-controlled trial. The Italian Multicenter Study Group. *J Hepatol* 1990; **11**: 92-101 [PMID: 2204661]
- 58 **Yoshida T**, Muto Y, Moriwaki H, Yamato M. Effect of long-term oral supplementation with branched-chain amino acid granules on the prognosis of liver cirrhosis. *Gastroenterol Jpn* 1989; **24**: 692-698 [PMID: 2606303]
- 59 **Orrego H**, Israel H, Blake JE, Medline A. Assessment of prognostic factors in alcoholic liver disease: toward a global quantitative expression of severity. *Hepatology* 1983; **3**: 896-905 [PMID: 6629318]
- 60 **Hoek JB**, Pastorino JG. Ethanol, oxidative stress, and cytokine-induced liver cell injury. *Alcohol* 2002; **27**: 63-68 [PMID: 12062639]
- 61 **Kono H**, Rusyn I, Yin M, G  bele E, Yamashina S, Dikalova A, Kadiiska MB, Connor HD, Mason RP, Segal BH, Bradford BU, Holland SM, Thurman RG. NADPH oxidase-derived free radicals are key oxidants in alcohol-induced liver disease. *J Clin Invest* 2000; **106**: 867-872 [PMID: 11018074]
- 62 **Tome S**, Lucey MR. Review article: current management of alcoholic liver disease. *Aliment Pharmacol Ther* 2004; **19**: 707-714 [PMID: 15043511]
- 63 **Sherman DI**, Williams R. Liver damage: mechanisms and management. *Br Med Bull* 1994; **50**: 124-138 [PMID: 8149189]
- 64 **Maddrey WC**, Boitnott JK, Bedine MS, Weber FL, Mezey E, White RI. Corticosteroid therapy of alcoholic hepatitis. *Gastroenterology* 1978; **75**: 193-199 [PMID: 352788]
- 65 **Carithers RL**, Herlong HF, Diehl AM, Shaw EW, Combes B, Fallon HJ, Maddrey WC. Methylprednisolone therapy in patients with severe alcoholic hepatitis. A randomized multicenter trial. *Ann Intern Med* 1989; **110**: 685-690 [PMID: 2648927]
- 66 **Helman RA**, Temko MH, Nye SW, Fallon HJ. Alcoholic hepatitis. Natural history and evaluation of prednisolone therapy. *Ann Intern Med* 1971; **74**: 311-321 [PMID: 4928161]
- 67 **Lesesne HR**, Bozymski EM, Fallon HJ. Treatment of alcoholic hepatitis with encephalopathy. Comparison of prednisolone with caloric supplements. *Gastroenterology* 1978; **74**: 169-173 [PMID: 340319]
- 68 **Ramond MJ**, Poynard T, Rueff B, Mathurin P, Th  odore C, Chaput JC, Benhamou JP. A randomized trial of prednisolone in patients with severe alcoholic hepatitis. *N Engl J Med* 1992; **326**: 507-512 [PMID: 1531090]
- 69 **Schlichting P**, Juhl E, Poulsen H, Winkel P. Alcoholic hepatitis superimposed on cirrhosis. Clinical significance and effect of long-term prednisone treatment. *Scand J Gastroenterol* 1976; **11**: 305-312 [PMID: 775615]
- 70 **Porter HP**, Simon FR, Pope CE, Volwiler W, Fenster LF. Corticosteroid therapy in severe alcoholic hepatitis. A double-blind drug trial. *N Engl J Med* 1971; **284**: 1350-1355 [PMID: 4930603]
- 71 **Campra JL**, Hamlin EM, Kirshbaum RJ, Olivier M, Redeker AG, Reynolds TB. Prednisone therapy of acute alcoholic hepatitis. Report of a controlled trial. *Ann Intern Med* 1973; **79**: 625-631 [PMID: 4751740]
- 72 **Blitzer BL**, Mutchnick MG, Joshi PH, Phillips MM, Fessel JM, Conn HO. Adrenocorticosteroid therapy in alcoholic hepatitis. A prospective, double-blind randomized study. *Am J Dig Dis* 1977; **22**: 477-484 [PMID: 326034]
- 73 **Shumaker JB**, Resnick RH, Galambos JT, Makopour H, Iber FL. A controlled trial of 6-methylprednisolone in acute alcoholic hepatitis. With a note on published results in encephalopathic patients. *Am J Gastroenterol* 1978; **69**: 443-449 [PMID: 356593]
- 74 **Depew W**, Boyer T, Omata M, Redeker A, Reynolds T. Double-blind controlled trial of prednisolone therapy in patients with severe acute alcoholic hepatitis and spontaneous encephalopathy. *Gastroenterology* 1980; **78**: 524-529 [PMID: 6985881]
- 75 **Theodossi A**, Eddleston AL, Williams R. Controlled trial of methylprednisolone therapy in severe acute alcoholic hepatitis. *Gut* 1982; **23**: 75-79 [PMID: 7035299]
- 76 **Imperiale TF**, McCullough AJ. Do corticosteroids reduce mortality from alcoholic hepatitis? A meta-analysis of the randomized trials. *Ann Intern Med* 1990; **113**: 299-307 [PMID: 2142869]
- 77 **Rambaldi A**, Saconato HH, Christensen E, Thorlund K, Wetterslev J, Gluud C. Systematic review: glucocorticosteroids for alcoholic hepatitis--a Cochrane Hepato-Biliary Group systematic review with meta-analyses and trial sequential analyses of randomized clinical trials. *Aliment Pharmacol Ther* 2008; **27**: 1167-1178 [PMID: 18363896]
- 78 **Strieter RM**, Remick DG, Ward PA, Spengler RN, Lynch JP, Larrick J, Kunkel SL. Cellular and molecular regulation of tumor necrosis factor-   production by pentoxifylline. *Biochem Biophys Res Commun* 1988; **155**: 1230-1236 [PMID: 2460096]
- 79 **Whitfield K**, Rambaldi A, Wetterslev J, Gluud C. Pentoxifylline for alcoholic hepatitis. *Cochrane Database Syst Rev* 2009; **(4)**: CD007339 [PMID: 19821406]
- 80 **Parker R**, Armstrong MJ, Corbett C, Rowe IA, Houlihan DD. Systematic review: pentoxifylline for the treatment of severe alcoholic hepatitis. *Aliment Pharmacol Ther* 2013; **37**: 845-854 [PMID: 23489011]
- 81 **Mathurin P**, Louvet A, Duhamel A, Nahon P, Carbonell N, Boursier J, Anty R, Diaz E, Thabut D, Moirand R, Lebre   D, Moreno C, Talbodec N, Paupard T, Naveau S, Silvain C, Pageaux GP, Sobesky R, Canva-Delcambre V, Dharancy S, Salleron J, Dao T. Prednisolone with vs without pentoxifylline and survival of patients with severe alcoholic hepatitis: a randomized clinical trial. *JAMA* 2013; **310**: 1033-1041 [PMID: 24026598]
- 82 **Park SH**, Kim DJ, Kim YS, Yim HJ, Tak WY, Lee HJ, Sohn JH, Yoon KT, Kim IH, Kim HS, Um SH, Baik SK, Lee JS, Suk KT, Kim SG, Suh SJ, Park SY, Kim TY, Jang JY. Pentoxifylline vs. corticosteroid to treat severe alcoholic hepatitis: a randomised, non-inferiority, open trial. *J Hepatol* 2014; **61**: 792-798 [PMID: 24845609]
- 83 **Thursz MR**, Richardson P, Allison M, Austin A, Bowers M, Day CP, Downs N, Gleeson D, MacGilchrist A, Grant A, Hood S, Masson S, McCune A, Mellor J, O'Grady J, Patch D, Ratcliffe I, Roderick P, Stanton L, Vergis N, Wright M, Ryder S, Forrest EH. Prednisolone or pentoxifylline for alcoholic hepatitis. *N Engl J Med* 2015; **372**: 1619-1628 [PMID: 25901427]
- 84 **Mookerjee RP**, Sen S, Davies NA, Hodges SJ, Williams R, Jalan R. Tumour necrosis factor alpha is an important mediator of portal and systemic haemodynamic derangements in alcoholic hepatitis. *Gut* 2003; **52**: 1182-1187 [PMID: 12865279]
- 85 **Vojt  chovsk   M**, Kr  l J. Proceedings: Chlorprothixen and thioridazine in maintenance therapy of longterm hospital psychotics. *Act Nerv Super (Praha)* 1975; **17**: 212-213 [PMID: 1221759]
- 86 **Naveau S**, Chollet-Martin S, Dharancy S, Mathurin P, Jouet P, Piquet MA, Davion T, Oberti F, Bro  t P, Emilie D. A double-

- blind randomized controlled trial of infliximab associated with prednisolone in acute alcoholic hepatitis. *Hepatology* 2004; **39**: 1390-1397 [PMID: 15122768]
- 87 **Boetticher NC**, Peine CJ, Kwo P, Abrams GA, Patel T, Aql B, Boardman L, Gores GJ, Harmsen WS, McClain CJ, Kamath PS, Shah VH. A randomized, double-blinded, placebo-controlled multicenter trial of etanercept in the treatment of alcoholic hepatitis. *Gastroenterology* 2008; **135**: 1953-1960 [PMID: 18848937]
 - 88 **Starzl TE**, Van Thiel D, Tzakis AG, Iwatsuki S, Todo S, Marsh JW, Koneru B, Staschak S, Stieber A, Gordon RD. Orthotopic liver transplantation for alcoholic cirrhosis. *JAMA* 1988; **260**: 2542-2544 [PMID: 3050180]
 - 89 **Cowling T**, Jennings LW, Goldstein RM, Sanchez EQ, Chinnakotla S, Klintmalm GB, Levy MF. Societal reintegration after liver transplantation: findings in alcohol-related and non-alcohol-related transplant recipients. *Ann Surg* 2004; **239**: 93-98 [PMID: 14685106]
 - 90 **Rice JP**, Eickhoff J, Agni R, Ghufraan A, Brahmbhatt R, Lucey MR. Abusive drinking after liver transplantation is associated with allograft loss and advanced allograft fibrosis. *Liver Transpl* 2013; **19**: 1377-1386 [PMID: 24115392]
 - 91 **Howard L**, Fahy T, Wong P, Sherman D, Gane E, Williams R. Psychiatric outcome in alcoholic liver transplant patients. *QJM* 1994; **87**: 731-736 [PMID: 7859049]
 - 92 **Vaillant GE**. What can long-term follow-up teach us about relapse and prevention of relapse in addiction? *Br J Addict* 1988; **83**: 1147-1157 [PMID: 3191263]
 - 93 **Iasi MS**, Vieira A, Añez CI, Trindade R, Codovani NT, Favero SS, Soler WV, David AI, D'Capua A, Szutan LA, Rolim EG, Iasi M. Recurrence of alcohol ingestion in liver transplantation candidates. *Transplant Proc* 2003; **35**: 1123-1124 [PMID: 12947883]
 - 94 **Pageaux GP**, Souche B, Perney P, Calvet B, Delande G, Fabre JM, Domergue J, Larrey D, Michel H. Results and cost of orthotopic liver transplantation for alcoholic cirrhosis. *Transplant Proc* 1993; **25**: 1135-1136 [PMID: 8442066]
 - 95 **Mathurin P**, Moreno C, Samuel D, Dumortier J, Salleron J, Durand F, Castel H, Duhamel A, Pageaux GP, Leroy V, Dharancy S, Louvet A, Boleslawski E, Lucidi V, Gustot T, Francoz C, Letoublon C, Castaing D, Belghiti J, Donckier V, Pruvot FR, Duclos-Vallée JC. Early liver transplantation for severe alcoholic hepatitis. *N Engl J Med* 2011; **365**: 1790-1800 [PMID: 22070476]
 - 96 **Nguyen-Khac E**, Thevenot T, Piquet MA, Benferhat S, Gorla O, Chatelain D, Tramier B, Dewaele F, Ghrib S, Rudler M, Carbonell N, Tossou H, Bental A, Bernard-Chabert B, Dupas JL. Glucocorticoids plus N-acetylcysteine in severe alcoholic hepatitis. *N Engl J Med* 2011; **365**: 1781-1789 [PMID: 22070475]
 - 97 **Louvet A**, Labreuche J, Artru F, Boursier J, Kim DJ, O'Grady J, Trépo E, Nahon P, Ganne-Carrié N, Naveau S, Diaz E, Gustot T, Lassailly G, Cannesson-Leroy A, Canva-Delcambre V, Dharancy S, Park SH, Moreno C, Morgan TR, Duhamel A, Mathurin P. Combining Data From Liver Disease Scoring Systems Better Predicts Outcomes of Patients With Alcoholic Hepatitis. *Gastroenterology* 2015; **149**: 398-406.e8; quiz e16-e17 [PMID: 25935634]

P- Reviewer: Thieringer J, Trabut JB, Uyanik M
S- Editor: Yu J **L- Editor:** A **E- Editor:** Liu XM





Published by **Baishideng Publishing Group Inc**

8226 Regency Drive, Pleasanton, CA 94588, USA

Telephone: +1-925-223-8242

Fax: +1-925-223-8243

E-mail: bpgoffice@wjgnet.com

Help Desk: <http://www.wjgnet.com/esps/helpdesk.aspx>

<http://www.wjgnet.com>



ISSN 1007-9327

