

## Review Article

*Medical Progress***PULMONARY EMBOLISM**

SAMUEL Z. GOLDBABER, M.D.

**T**HE diagnosis and treatment of pulmonary embolism demand an interdisciplinary approach, combining medical, surgical, and radiologic specialties. Despite substantial advances, mortality and recurrence rates remain high. The present article addresses thrombotic venous thromboembolism, even though the term "pulmonary embolism" encompasses embolism from many sources, including air, bone marrow, arthroplasty cement, amniotic fluid, tumor, talc, and sepsis.

**EPIDEMIOLOGY AND PATHOPHYSIOLOGY**

Pulmonary embolism ranges from incidental, clinically unimportant thromboembolism to massive embolism with sudden death. Hypercoagulability leads to the formation of thrombus in the leg veins, with proximal extension as the clot propagates. As thrombi form in the deep veins of the legs, pelvis, or arms, they may dislodge and embolize to the pulmonary arteries (Fig. 1), with potentially serious consequences. Pulmonary arterial obstruction and the release by platelets of vasoactive agents such as serotonin elevate pulmonary vascular resistance. The resulting increase in alveolar dead space and redistribution of blood flow (which creates areas of decreased ventilation to perfusion) impair gas exchange; stimulation of irritant receptors causes alveolar hyperventilation. Reflex bronchoconstriction augments airway resistance, and lung edema decreases pulmonary compliance.<sup>2</sup> As right ventricular afterload increases, tension rises in the right ventricular wall and may lead to dilatation, dysfunction, and ischemia of the right ventricle. In the presence of a patent foramen ovale or atrial septal defect, paradoxical embolism may occur, as well as right-to-left shunting of blood with severe arterial hypoxemia.

Pulmonary embolism and deep venous thrombo-

sis should be considered part of the same pathological process. In one study, nearly 40 percent of patients who had deep venous thrombosis but no symptoms of pulmonary embolism had evidence of pulmonary embolism on lung scanning.<sup>3</sup> Conversely, in a study of patients with pulmonary embolism, 29 percent had abnormalities on ultrasonographic studies of leg veins.<sup>4</sup> Deep venous thrombosis probably could not be detected in the majority of patients with pulmonary embolism because the thrombus had embolized before noninvasive evaluation of the legs was conducted or because compression ultrasonography is insensitive and does not identify small, residual clots.

**Incidence, Mortality, and Recurrence**

In studies conducted in Worcester, Massachusetts,<sup>5</sup> and Olmsted County, Minnesota,<sup>6</sup> the incidence of venous thromboembolism was about 1 in 1000 per year. In both studies, venous thromboembolism was more common in men; for each 10-year increase in age, the incidence doubled. By extrapolation, we can estimate that more than 250,000 patients are hospitalized annually in the United States with venous thromboembolism.

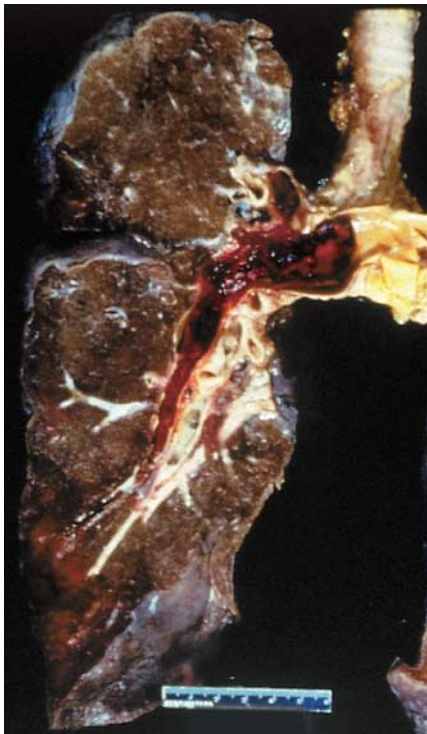
The mortality rate for pulmonary embolism continues to be high (Fig. 2). In the International Cooperative Pulmonary Embolism Registry of 2454 patients, the three-month mortality rate was 17.5 percent.<sup>8</sup> All consecutive patients with a diagnosis of pulmonary embolism were included and pulmonary embolism was the principal cause of death. In contrast, the overall three-month mortality rate in the Prospective Investigation of Pulmonary Embolism Diagnosis was about 15 percent, but only 10 percent of deaths during one year of follow-up were ascribed to pulmonary embolism.<sup>9</sup> A study of Medicare recipients who were 65 years of age or older reported 30-day case fatality rates in patients with pulmonary embolism.<sup>10</sup> Overall, men had higher fatality rates than women (13.7 percent vs. 12.8 percent) and blacks had higher fatality rates than whites (16.1 percent vs. 12.9 percent).

**Right Ventricular Function**

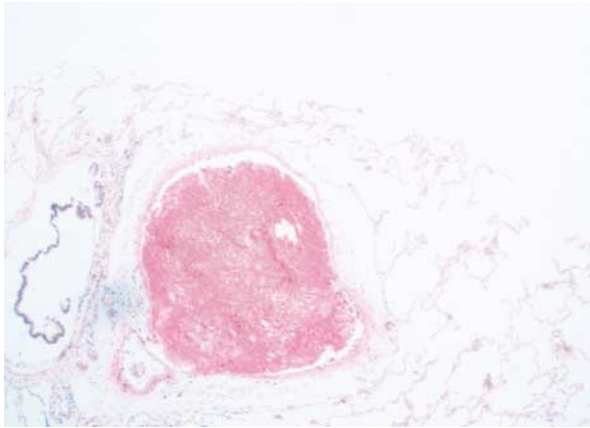
Analyses of four registries of patients with pulmonary embolism have demonstrated that a finding of right ventricular hypokinesis in the presence of normal systemic arterial pressure predicts an adverse clinical outcome. Although fewer than 5 percent of patients in the International Cooperative Pulmonary Embolism Registry presented with cardiogenic shock, half the overall population underwent echocardiogra-

From the Cardiovascular Division, Department of Medicine, Brigham and Women's Hospital, and Harvard Medical School, Boston. Address reprint requests to Dr. Goldhaber at the Cardiovascular Division, Brigham and Women's Hospital, 75 Francis St., Boston, MA 02115.

©1998, Massachusetts Medical Society.



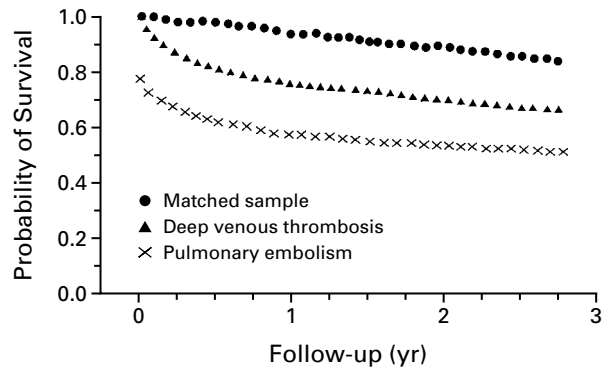
A



B

**Figure 1.** Pulmonary Thromboembolus.

Gross specimen of the right lung, sectioned in a coronal plane at the vascular pedicle, shows a recent thromboembolus lodged in the right main pulmonary artery (Panel A). The clot extends into the right-upper-lobe pulmonary artery, the interlobar pulmonary artery, and some of the segmental branches of the lower lobe. Hemorrhage is seen in the lower lateral portion of the sectioned lung. Panel B shows a histologic section of a medium-sized pulmonary artery containing recent thromboembolus (hematoxylin and eosin). Reprinted from Skibo and Goldhaber<sup>1</sup> with the permission of the publisher.



**Figure 2.** Survival of Medicare Enrollees with Deep Venous Thrombosis or Pulmonary Embolism and a Sample of Medicare Enrollees Matched for Age, Sex, and Race.

Reprinted from Kniffin et al.<sup>7</sup> with the permission of the publisher.

phy. Right ventricular hypokinesia, as assessed by echocardiography, was present in about 40 percent of patients with normal systemic arterial pressure. Among the patients who underwent echocardiography, a finding of right ventricular hypokinesia was associated with a doubling of the mortality rate at 14 days and with a rate at 3 months that was 1.5 times that in patients without hypokinesia.<sup>8</sup> In a Swedish study, 126 consecutive patients with pulmonary embolism underwent echocardiography when pulmonary embolism was initially diagnosed.<sup>11</sup> The overall mortality rate at one year was 15 percent; however, the mortality rate at one year was three times higher in patients with right ventricular dysfunction than in those with normal right ventricular function. Kasper et al. reported similar findings in a registry of 317 patients with clinically suspected pulmonary embolism.<sup>12</sup> Finally, in the Management Strategy and Prognosis of Pulmonary Embolism Registry (MAPPET) of 1001 patients with pulmonary embolism and right ventricular dysfunction,<sup>13</sup> the mortality rate increased as right ventricular failure worsened.

#### Risk Factors

Since genetic predisposition appears to explain only about one fifth of cases of pulmonary embolism, identification of other risk factors is critical. Virchow proposed a classic triad of local trauma to the vessel wall, hypercoagulability, and stasis as causes of venous thromboembolism. In the Nurses' Health Study,<sup>14</sup> the highest rates of pulmonary embolism were observed among nurses 60 years of age or older who were in the highest quintile of body-mass index. Heavy cigarette smoking and high blood pressure were also identified as risk factors for pulmonary embolism. However, no association was observed between pulmonary embolism and high cholesterol levels or diabetes.

From 1979 to 1986, 2726 pregnancy-associated deaths were reported in the United States.<sup>15</sup> For women whose pregnancies resulted in a live birth, thrombotic pulmonary embolism was the leading cause of death.

Most users of oral contraceptives take second-generation formulations that contain norgestrel, levonorgestrel, or norgestrienone as the progesterone and low-dose estrogen ( $<50 \mu\text{g}$ ). The risk of pulmonary embolism among users of these oral contraceptives is about three times the risk among non-users. Third-generation oral contraceptives contain desogestrel, gestodene, or norgestimate as the progesterone in combination with low-dose estrogen. These newly formulated oral contraceptives attenuate the androgenic side effects of acne and hirsutism. Three groups have reported that the risk of venous thromboembolism among women taking third-generation formulations is double the risk among those taking second-generation formulations,<sup>16-18</sup> but this observation is not universally accepted.<sup>19</sup>

Hormone-replacement therapy doubles the risk of venous thromboembolism. Interestingly, the risk is higher near the start of therapy than after long-term use.<sup>20</sup> This conclusion emerges from three separate studies<sup>21-23</sup> that report remarkably similar findings. As is true for oral-contraceptive therapy, current but not prior use places women at increased risk.

Neoplastic cells can generate thrombin or synthesize various procoagulants.<sup>24</sup> Occasionally, previously unsuspected cancer is identified in patients with newly diagnosed venous thrombosis.<sup>25</sup> However, this finding is unlikely in patients known to have hypercoagulability; after trauma, surgery, or immobilization; or during pregnancy or in the postpartum period.<sup>26</sup> An extensive diagnostic evaluation for cancer rarely prolongs life in patients with newly diagnosed venous thrombosis, because in most cases, the cancer has already widely metastasized, and the prognosis is ominous.

Surgery predisposes patients to pulmonary embolism, even as late as one month postoperatively. In a study in Malmö, Sweden, 25 percent of the cases of pulmonary embolism occurred between the 15th and 30th postoperative day and 15 percent were detected more than 30 days postoperatively.<sup>27</sup> In a Swiss study,<sup>28</sup> pulmonary embolism after discharge occurred a median of 18 days postoperatively and led to an overall increase of 30 percent in the rate of postoperative pulmonary embolism.

### Thrombophilia

Activated protein C is the most potent endogenous anticoagulant. Resistance to this protein is considered to be present when challenge with activated protein C prolongs the partial-thromboplastin time in plasma less in patients than in control subjects. In 1994, Svensson and Dahlbäck found a high preva-

lence of resistance to activated protein C among persons with a history of venous thrombosis. This resistance appeared to be inherited as an autosomal dominant trait.<sup>29</sup> Soon thereafter, three groups almost simultaneously described the point mutation (the substitution of adenine for guanine) in the gene coding for coagulation factor V that is responsible for activated protein C resistance.<sup>30-32</sup> Glutamine replaces arginine at position 506, thereby making activated factor V more difficult for activated protein C to cleave and inactivate.<sup>33</sup> This is called the factor V Leiden mutation. In the Physicians' Health Study,<sup>34</sup> the relative risk of venous thrombosis in men with the mutation was 2.7. When 24 populations were analyzed, the mutation appeared to be most common in Europe and least common in Africa and Southeast Asia.<sup>35</sup> Factor V Leiden also appeared to increase the risk of recurrent pulmonary embolism after discontinuation of anticoagulation by a factor of 2 to 4.<sup>36,37</sup>

Use of oral contraceptive agents<sup>38</sup> and pregnancy<sup>39</sup> increase the frequency of activated protein C resistance even in women without the factor V Leiden mutation. Women with factor V Leiden who use oral contraceptive agents have an estimated 35-fold increase in the risk of venous thromboembolism, as compared with women without the mutation.<sup>40,41</sup> It has been hypothesized that the reported increased risk of pulmonary embolism associated with third-generation oral contraceptive agents results from these agents' being more likely to cause resistance to activated protein C than second-generation oral contraceptive agents.<sup>42</sup>

Plasma hyperhomocysteinemia is usually caused by mild deficiencies of folate and is occasionally caused by inadequate intake of vitamin B<sub>6</sub> or B<sub>12</sub>.<sup>43</sup> In case-control studies from Padua, Italy,<sup>44</sup> and the Netherlands,<sup>45</sup> the risk of deep venous thrombosis among patients with hyperhomocysteinemia was two to three times that among subjects without hyperhomocysteinemia. In the Physicians' Health Study,<sup>46</sup> hyperhomocysteinemia tripled the risk of idiopathic venous thrombosis, and the factor V Leiden mutation doubled the risk of venous thrombosis. However, the presence of both hyperhomocysteinemia and the factor V Leiden mutation increased the risk of any venous thrombosis by almost 10-fold and increased the risk of idiopathic venous thrombosis by a factor of 20.

Many patients with antiphospholipid antibodies or the lupus anticoagulant do not have systemic lupus erythematosus. This acquired abnormality may be associated with an increased risk of venous thrombosis, recurrent miscarriage, stroke, or pulmonary hypertension.<sup>47</sup> In a case-control study, the lupus anticoagulant was detected in 8.5 percent of the 59 patients who had deep venous thrombosis confirmed by contrast venography but in none of the 117 with no abnormalities on venography.<sup>48</sup>

The routine laboratory workup for a hypercoagulable state in patients with pulmonary embolism used to include assay of antithrombin III, protein C, and protein S. The levels of all three of these coagulation-inhibiting proteins can be depressed during an acute thrombotic state. In addition, heparin depresses antithrombin III levels, and warfarin depresses protein C and protein S levels. Furthermore, pregnancy<sup>49</sup> and the use of oral-contraceptive agents<sup>50</sup> cause protein S levels to decline. Overall, these proteins should not be measured routinely because the results may be misleading and because deficiencies of antithrombin III, protein C, and protein S rarely occur.<sup>51</sup> Patients with these protein deficiencies have frequent recurrences of venous thromboembolism during the first one to three years after the cessation of anticoagulant therapy.<sup>52</sup> I usually test for the factor V Leiden mutation, because it is responsible for the most common hypercoagulable state; hyperhomocysteinemia, because it can be readily treated with B vitamins; and the lupus anticoagulant, because if it is present, particularly intensive anticoagulation may be required.

### DIAGNOSIS

The accurate detection of pulmonary embolism remains difficult, and the differential diagnosis is extensive (Table 1). Pulmonary embolism can accompany as well as mimic other cardiopulmonary illnesses. Overdiagnosis is as likely as underdiagnosis. The optimal strategy is an integrated diagnostic approach that includes a methodical history taking and physical examination, supplemented by selective testing when appropriate.

Details should be sought regarding the patient's history and a family history of venous thrombosis, as well as coexisting conditions, environmental risk factors, and hormonal influences. Dyspnea is the most frequent symptom of pulmonary embolism, and tachypnea is the most frequent sign.<sup>53</sup> Whereas the presence of dyspnea, syncope, or cyanosis usually indicates a massive pulmonary embolism, a finding of pleuritic pain, cough, or hemoptysis often suggests a small embolism near the pleura. On physical examination, findings of right ventricular dysfunction include bulging neck veins with v waves, a left parasternal lift, an accentuated pulmonic component of the second heart sound, and a systolic murmur at the left lower sternal border that increases in intensity during inspiration. These signs may be obscured by obesity or by a barrel chest with increased anteroposterior diameter. Bulging neck veins may be replaced by profound hypoxemia when right-to-left shunting occurs through a patent foramen ovale.

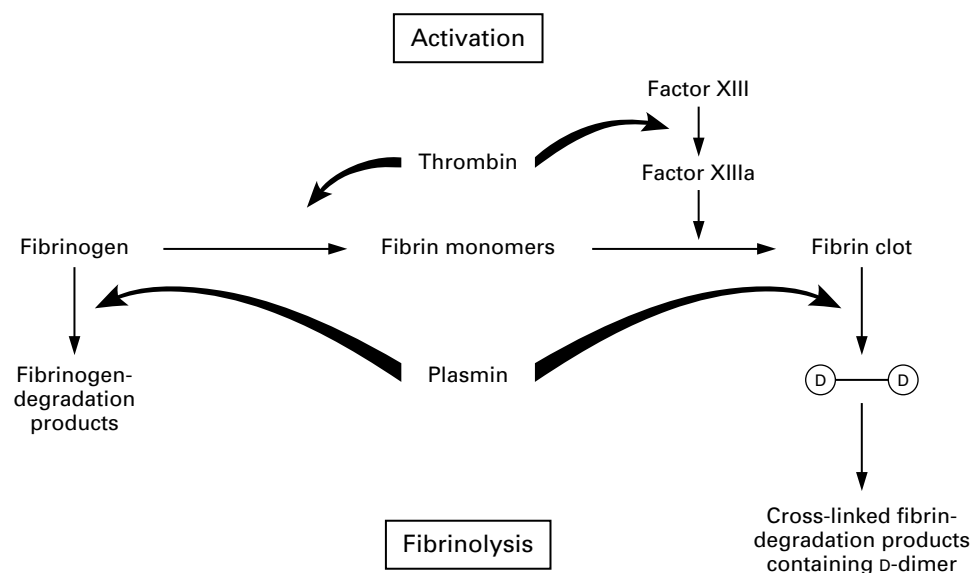
Electrocardiography and chest radiography should usually be incorporated into the diagnostic workup. The most frequent electrocardiographic abnormality is T-wave inversion in the anterior leads, especially

**TABLE 1. DIFFERENTIAL DIAGNOSIS OF PULMONARY EMBOLISM.**

Pneumonia or bronchitis
Asthma
Exacerbation of chronic obstructive pulmonary disease
Myocardial infarction
Pulmonary edema
Anxiety
Dissection of the aorta
Pericardial tamponade
Lung cancer
Primary pulmonary hypertension
Rib fracture
Pneumothorax
Costochondritis
Musculoskeletal pain

leads V<sub>1</sub> to V<sub>4</sub>.<sup>54</sup> These are probably reciprocal changes reflecting inferoposterior ischemia due to compression of the right coronary artery by the right ventricle as a result of pressure overload. New-onset right-bundle branch block or atrial fibrillation is uncommon. Abnormal findings on the chest film may include focal oligemia (Westermark's sign), a peripheral wedge-shaped density above the diaphragm (Hampton's hump), and an enlarged right descending pulmonary artery (Palla's sign).<sup>55</sup>

In the presence of risk factors for venous thromboembolism or coexisting conditions, a finding of unexplained dyspnea, chest discomfort, or syncope indicates a moderate or high clinical likelihood of pulmonary embolism. If the clinical likelihood is low, however, a D-dimer enzyme-linked immunosorbent assay (ELISA) (Fig. 3) and venous ultrasonography may be useful. Because the D-dimer ELISA lacks specificity and levels of D-dimer are elevated in patients with myocardial infarction, pneumonia, heart failure, or cancer and in those who have undergone surgery,<sup>56</sup> the assay is best suited for patients who present to the emergency department or a physician's office without other systemic illnesses.<sup>57</sup> The assay usually requires three to four hours to perform and is generally not performed on nights or weekends. Alternatively, a more rapid and readily available latex-agglutination test can be performed, but about half the time the results will be normal in the presence of an elevated D-dimer ELISA level.<sup>58</sup> Unfortunately, the finding of normal arterial-blood gas values does not rule out the diagnosis of pulmonary embolism and cannot accurately be used to discriminate between patients suspected of having pulmonary embolism who require further investigation and those in whom no further workup is required.<sup>59,60</sup> Findings of hypoxemia or hypocapnia may increase the physician's level of diagnostic sus-



**Figure 3.** Endogenous Fibrinolysis and Release of D-Dimers.

In the presence of thrombin, fibrinogen is cleaved to form fibrin monomers, which are subsequently stabilized by thrombin-activated factor XIII. Covalent cross-linkages in the D-domain region of fibrin produce an insoluble fibrin clot. The presence of the fibrin clot, in turn, triggers plasmin to lyse the clot as well as fibrinogen. Whereas fibrinogenolysis leads to fibrinogen-degradation products, lysis of the fibrin clot generates cross-linked fibrin-degradation products containing D-dimer. Most patients with pulmonary embolism have some endogenous (although clinically ineffective) fibrinolysis. When plasmin digests cross-linked fibrin from the pulmonary embolus that has formed, D-dimers are released into the plasma and can be recognized by commercially available monoclonal antibodies. The plasma D-dimer ELISA is highly sensitive but not specific for the diagnosis of pulmonary embolism, with a high negative predictive value. Generally, a finding of more than 500 ng of D-dimer per milliliter is considered abnormal, and such levels are present in more than 90 percent of patients with pulmonary embolism. Conversely, the finding of a normal D-dimer level provides reassurance in more than 90 percent of cases that pulmonary embolism is not present.

picion, but these findings are not specific for pulmonary embolism.

Venous ultrasonography is highly accurate in symptomatic outpatients with suspected deep venous thrombosis,<sup>61</sup> but normal results do not rule out pulmonary embolism if the level of clinical suspicion is moderately high. The rate of ultrasonographic detection of deep venous thrombosis is much lower when symptoms or signs are absent. Even a finding of normal results on bilateral contrast venography does not rule out pulmonary embolism. For example, in one study of 41 patients with abnormalities on pulmonary angiography, the results of leg venography were normal in 12.<sup>62</sup>

Perfusion lung scanning remains the most useful screening test to rule out clinically important acute pulmonary embolism. Normal results are almost never associated with recurrent pulmonary embolism, even if anticoagulants are withheld. In the Prospective Investigation of Pulmonary Embolism Diagnosis, the use of a scanning pattern thought to indicate a high probability of pulmonary embolism identified only 41 percent of affected patients.<sup>63</sup> Whereas normal results or results indicating a high

probability of disease are extremely helpful, nondiagnostic results<sup>64</sup> are difficult to interpret. Only rarely does ventilation scanning clarify the interpretation of perfusion lung scans.<sup>65</sup> Furthermore, in the presence of a high index of clinical suspicion, results of lung scanning indicating a low probability of pulmonary embolism may inadvertently steer the clinician away from the correct diagnosis.<sup>66</sup> Such results should instead be interpreted as nondiagnostic.<sup>67</sup>

An alternative to lung scanning or conventional pulmonary angiography is spiral computed tomography (CT) of the chest with contrast medium.<sup>68</sup> This approach is best suited for identifying pulmonary embolism in the proximal pulmonary vascular tree.<sup>69</sup> However, if the CT findings are normal in the presence of a high index of clinical suspicion, contrast pulmonary angiography that focuses on the distal pulmonary vasculature should be performed. It is important to identify small distal pulmonary emboli that may not be detected by spiral CT of the chest, because a major pulmonary embolism may ensue unless adequate anticoagulation is initiated. For patients with renal insufficiency and a high probability of pulmonary embolism, the exposure to

contrast medium will be minimized if one forgoes CT and proceeds directly to conventional pulmonary angiography. Another promising new technique is gadolinium-enhanced magnetic resonance pulmonary angiography,<sup>70</sup> which reveals anatomical features as well as assessing right ventricular wall motion.

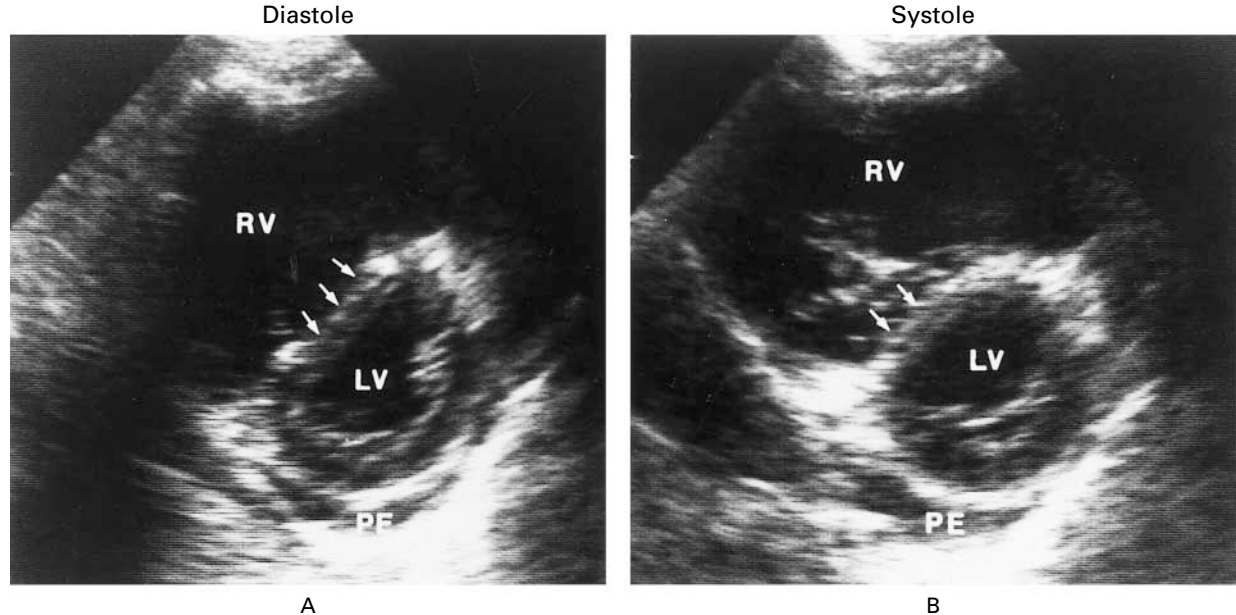
When consecutive patients with pulmonary embolism undergo echocardiography, about 40 percent have abnormalities of the right ventricle. Transthoracic echocardiography (Fig. 4) is particularly useful in critically ill patients suspected of having pulmonary emboli<sup>72</sup> and can help identify right ventricular pressure overload as well as myocardial infarction, dissection of the aorta, or pericardial tamponade, which may mimic pulmonary embolism. The McConnell sign of pulmonary embolism is a pattern of regional right ventricular dysfunction in which apical wall motion remains normal despite hypokinesis of the free wall.<sup>73</sup>

Combining noninvasive diagnostic tests may be especially useful. For instance, a normal D-dimer ELISA and venous ultrasonographic examination can help rule out pulmonary embolism, whereas an echocardiogram showing right ventricular hypokinesis combined with positive findings on ultrasonography of the legs is virtually pathognomonic of pulmonary embolism.

Contrast pulmonary angiography remains the gold standard. It can generally be performed safely<sup>74</sup> and may pinpoint the diagnosis in cases in which there is a high index of clinical suspicion despite nondiagnostic findings on lung scanning and normal results on venous ultrasonography and echocardiography. Occasionally, pulmonary angiography is used when the clinical suspicion is low despite the fact that other test results indicate pulmonary embolism.

### THERAPY

Heparin constitutes the cornerstone of management.<sup>75</sup> It accelerates the action of antithrombin III, thereby preventing an additional thrombus from forming and permitting endogenous fibrinolysis to dissolve some of the clot. Initial therapy with an oral anticoagulant and no heparin may paradoxically intensify hypercoagulability and increase the frequency of recurrent venous thromboembolism.<sup>76</sup> In the absence of overt contraindications such as active gastrointestinal hemorrhage, patients with a moderate or high clinical likelihood of pulmonary embolism should receive intensive anticoagulation with heparin during the diagnostic workup. A bolus of unfractionated heparin (usually 5000 to 10,000 U) followed by a continuous infusion (initiated at a dose



**Figure 4.** Typical Findings of Transthoracic Echocardiography in Patients with Massive Pulmonary Embolism.

In patients with pulmonary embolism, the transthoracic echocardiogram rarely demonstrates thrombus; instead, findings suggestive of pulmonary embolism may be observed. Shown here are parasternal short-axis views of the right ventricle (RV) and left ventricle (LV) in diastole (Panel A) and systole (Panel B) in a patient with angiographically proved pulmonary embolism. There is diastolic and systolic bowing of the interventricular septum (arrows) into the left ventricle — a finding compatible with the presence of right ventricular volume overload and pressure overload, respectively. The left ventricle has assumed a classic D-shaped configuration, indicating impaired left ventricular relaxation. The right ventricle is appreciably dilated and markedly hypokinetic, with little change in the apparent right ventricular area from diastole to systole. There is a small pericardial effusion (PE). Reprinted from Come<sup>71</sup> with the permission of the publisher.

of 18 U per kilogram of body weight per hour, but not exceeding 1600 U per hour, in otherwise healthy patients) usually rapidly results in a therapeutic partial-thromboplastin time of 60 to 80 seconds. The use of heparin nomograms facilitates proper dosing.<sup>77</sup> In patients who appear to have a resistance to heparin, arbitrarily defined as a requirement for more than 50,000 U of heparin per 24 hours, measurement of the plasma heparin level rather than the partial-thromboplastin time may avoid unnecessary dose escalation.<sup>78</sup> Plasma heparin levels are also useful for titrating heparin concentrations in the presence of a prolonged partial-thromboplastin time at base line due to lupus anticoagulants.

Heparin without oral anticoagulation is used throughout pregnancy to manage pulmonary embolism.<sup>79</sup> Heparin is also used as short-term or long-term therapy in some patients with venous thrombosis associated with metastatic cancer, because oral anticoagulation usually fails to prevent recurrent thrombosis.<sup>80</sup> Recently, inpatient administration of low-molecular-weight heparin has been shown to be as safe and effective as unfractionated heparin to treat hemodynamically stable pulmonary embolism.<sup>81,82</sup>

Although the insertion of inferior vena caval filters can usually prevent major pulmonary embolism,<sup>83</sup> filters appear to offer no advantage in patients with proximal deep venous thrombosis with free-floating thrombi.<sup>84</sup> Filters do not halt the thrombotic process; large venous collateral vessels may develop; and in rare cases, caval thrombosis accompanied by massive edema of the legs may ensue. Furthermore, in a randomized, controlled trial of 400 patients with deep venous thrombosis, inferior vena caval filters plus anticoagulation did not reduce the two-year mortality rate, as compared with anticoagulation alone.<sup>85</sup> However, an inferior vena caval filter is warranted in patients with pulmonary embolism in the presence of active hemorrhage or recurrent pulmonary embolism despite intensive and prolonged anticoagulation.

Warfarin can be safely started once a therapeutic partial-thromboplastin time or heparin level has been achieved. Loading of warfarin does not shorten the five-day period needed to achieve adequate oral anticoagulation, and an initial daily dose of 5 mg (rather than 10 mg) is often sufficient.<sup>86</sup> Factor VII, the main coagulation factor affecting the prothrombin time, has a half-life of about six hours. However, true anticoagulation requires the depletion of factor II (thrombin), which takes about five days. Therefore, at least five days of continuous intravenous heparin is recommended. In general, the initial target international normalized ratio (INR) should be 3.0, because concomitant administration of unfractionated heparin usually prolongs the INR by an additional 0.5, thus yielding an effective INR due to

warfarin alone of 2.5. After hospital discharge, the risk of bleeding complications<sup>87</sup> and thromboembolic events<sup>88</sup> can be minimized by having a centralized anticoagulation clinic monitor the patient. Recently, the Food and Drug Administration (FDA) approved devices for monitoring the prothrombin time at home. Analogous to blood glucose home-monitoring devices, these devices may ultimately improve anticoagulation control.<sup>89</sup>

Patients with the antiphospholipid antibody syndrome who are being treated for pulmonary embolism appear to require more intensive anticoagulation than other patients with pulmonary embolism.<sup>90</sup> However, accurate monitoring of oral anticoagulation in these patients may require special laboratory tests.<sup>91</sup>

The optimal duration of anticoagulation after pulmonary embolism remains uncertain. A treatment period of six months prevents far more recurrences than a period of six weeks among patients with a first episode of pulmonary embolism.<sup>92</sup> An indefinite (lifelong) period of anticoagulation should be considered in patients with recurrent pulmonary embolism if the risk of major bleeding is low.<sup>93</sup> For patients with deficiencies of antithrombin III, protein C, or protein S, several years rather than lifelong anticoagulation may suffice.<sup>52</sup> Whether patients with factor V Leiden and pulmonary embolism should receive prolonged courses of anticoagulation remains sharply debated.<sup>94</sup>

Heparin-induced thrombocytopenia<sup>95</sup> causes venous thrombosis more often than arterial thrombosis.<sup>96</sup> Although rapid loading of warfarin used to be recommended, this strategy may precipitate venous gangrene of the limbs, possibly as a result of a precipitous warfarin-mediated decline in protein C levels.<sup>97</sup> Appropriate treatment approaches include use of a heparinoid<sup>98</sup> or direct thrombin inhibitor.<sup>99</sup>

Thrombolysis can be lifesaving in patients with massive pulmonary embolism, cardiogenic shock, or overt hemodynamic instability.<sup>100</sup> There appears to be a 14-day window for its effective administration.<sup>101</sup> Controversy persists regarding the use of thrombolytic therapy in patients with stable systemic arterial pressure and right ventricular dysfunction (usually documented by echocardiography). In this population, rapid improvement of right ventricular function and pulmonary perfusion, accomplished with thrombolytic therapy in addition to heparin, may lead to a lower rate of recurrent pulmonary embolism than with heparin alone.<sup>102</sup> Multivariate analysis of the patients in the MAPPET registry suggested that those who were initially treated with thrombolysis plus anticoagulation had better clinical outcomes than those who were initially treated with anticoagulation alone.<sup>103</sup> However, the potential benefit must be weighed against the risk of major hemorrhage, which rises with increasing age and body-mass index.<sup>104</sup>

If aggressive intervention is warranted in patients in whom thrombolysis is contraindicated or unsuccessful, transvenous catheter embolectomy<sup>105</sup> or open surgical embolectomy<sup>106</sup> should be considered. Thrombectomy can be accomplished with the use of a newly developed catheter that delivers high-velocity jets of saline that draw thrombus toward the catheter tip and subsequently pulverize the clot.<sup>107</sup> Another interventional approach combines mechanical fragmentation with pharmacologic thrombolysis.<sup>108</sup> During the treatment of such critically ill patients, norepinephrine or dobutamine may be required to maintain the mean arterial pressure and thus ensure adequate perfusion of the right coronary artery.<sup>109</sup>

Patients with chronic thrombotic involvement of large pulmonary arteries and cor pulmonale may be candidates for pulmonary thromboendarterectomy. After the institution of cardiopulmonary bypass and deep hypothermia, incisions are made in both pulmonary arteries to remove organized thrombi.<sup>110</sup> When this approach is successful, pulmonary hypertension will abate during the first few postoperative months and the quality of life will improve. Among properly selected patients at experienced centers, the mortality rate ranges from 5 to 10 percent. The inability to remove sufficient thrombotic material at surgery (resulting in persistent postoperative pulmonary hypertension and right ventricular dysfunction) and severe reperfusion-associated lung injury are the two major causes of death.

### PREVENTION

Prevention of pulmonary embolism is of paramount importance because the disorder is difficult to detect, and treatment of established pulmonary embolism is not universally successful.<sup>111</sup> The specific regimen that is chosen is less important than ensuring that all hospitalized patients are evaluated and stratified according to the risk of pulmonary embolism and that appropriate prophylaxis is implemented.<sup>112</sup>

Mechanical approaches to prevention include the use of graduated-compression stockings, devices that provide intermittent pneumatic compression, and inferior vena caval filters alone or in combination. In addition to increasing venous blood flow in the legs, intermittent pneumatic compression increases endogenous fibrinolysis by stimulating the vascular endothelial wall.<sup>113-115</sup> This approach also had the highest rate of compliance among patients in an intensive care unit. Among less critically ill patients, however, compliance may not be adequate.<sup>116</sup> Foot pumps, which compress the plantar venous plexus, have also been used as prophylaxis, but they have not been investigated extensively in randomized, controlled studies.<sup>117</sup>

Until recently, fixed, low doses of subcutaneous unfractionated heparin have been used for perioper-

ative prophylaxis.<sup>118</sup> This strategy does not require laboratory monitoring and reduces the rate of fatal pulmonary embolism by two thirds.<sup>119</sup> The initial injection is administered two hours before the skin is incised. Heparin is continued until the patient is discharged and fully ambulatory. Low-molecular-weight heparins have increasingly replaced unfractionated heparin because of their superior bioavailability and absorption, the need for less frequent injections, and lower rates of heparin-induced thrombocytopenia.<sup>120</sup> Three low-molecular-weight heparins — enoxaparin, dalteparin, and ardeparin — and one heparinoid, danaparoid,<sup>121</sup> have received FDA approval for specific prophylactic indications. Unlike enoxaparin and dalteparin, ardeparin has been approved for use in a weight-adjusted dose rather than a fixed dose.<sup>122</sup> Although aspirin probably has slight efficacy in preventing pulmonary embolism,<sup>123</sup> it should not be used as the only pharmacologic agent.

Table 2 lists various approaches to prophylaxis.<sup>124-131</sup> However, several aspects of the prevention of pulmonary embolism remain problematic. During total knee replacement, deflation of the tourniquet is associated with a high rate of pulmonary embolism. In one study, in all 29 patients who were monitored with transesophageal echocardiography during tourniquet deflation, showers of echogenic material, lasting for 3 to 15 minutes, were noted in the right atrium and right ventricle. These showers caused transient hypotension and transient increases in pulmonary vascular resistance. The composition of this echogenic material is uncertain but could be thrombus, cement, or bone marrow.<sup>132</sup>

Controversy surrounds the optimal timing, intensity, and duration of prophylaxis after total hip and knee replacement. In Europe, it is customary to initiate low-molecular-weight heparin on the night before total hip or knee replacement, followed by once-daily injections thereafter. In North America, however, twice-daily injections of low-molecular-weight heparin are usually initiated postoperatively, without preoperative anticoagulation.

For total hip replacement,<sup>133-135</sup> four to six weeks of low-molecular-weight heparin postoperatively may be more effective than restricting treatment to the initial period of hospitalization. Some authors have proposed limiting the duration of postoperative anticoagulation to 10 days, with the administration of either 30 mg of enoxaparin subcutaneously twice daily<sup>136</sup> or warfarin with the use of a target INR of 2.0 to 3.0.<sup>137</sup> Among 3016 patients who underwent total hip replacement, postoperative treatment with 30 mg of enoxaparin every 12 hours or warfarin only during hospitalization was associated with just four fatal pulmonary embolisms during the first three postoperative months (Colwell CW Jr, et al.: personal communication). Deciding to continue prophylaxis at the time of discharge on the basis of venous ultrasonog-

**TABLE 2.** APPROACHES TO THE PREVENTION OF VENOUS THROMBOEMBOLISM.

CONDITION OR PROCEDURE	PROPHYLAXIS*
General surgery	Unfractionated heparin, 5000 U two or three times daily Enoxaparin, 40 mg/day SC Dalteparin, 2500 or 5000 U/day SC Nadroparin, 3100 U/day SC† Tinzaparin, 3500 U/day SC, with or without graduated-compression stockings‡
Total hip replacement	Warfarin (target INR, 2.5)‡ Intermittent pneumatic compression <sup>124</sup> Enoxaparin, 30 mg SC twice daily <sup>125</sup> § Danaparoid, 750 U SC twice daily
Total knee replacement	Enoxaparin, 30 mg SC twice daily <sup>126</sup> § Ardeparin, 50 U/kg SC twice daily <sup>127</sup>
Neurosurgery	Graduated-compression stockings and intermittent pneumatic compression, with or without unfractionated heparin, 5000 U twice daily
Trauma (non-brain)	Enoxaparin, 30 mg SC twice daily <sup>128</sup>
Thoracic surgery	Graduated-compression stockings, intermittent pneumatic compression, and unfractionated heparin, 5000 U three times daily
Uncomplicated coronary-artery bypass grafting	Graduated-compression stockings, with or without unfractionated heparin, 5000 U two or three times daily
General medical condition requiring hospitalization	Graduated-compression stockings, intermittent pneumatic compression, or unfractionated heparin, 5000 U two or three times daily <sup>129</sup>
Condition requiring hospitalization in the intensive care unit	Graduated-compression stockings and intermittent pneumatic compression, with or without unfractionated heparin, 5000 U two or three times daily
Pregnancy¶	Dalteparin, 5000 U/day SC <sup>130</sup> Enoxaparin, 40 mg/day SC <sup>131</sup>

\*SC denotes subcutaneously.

†This drug has not been approved for use by the Food and Drug Administration.

‡Warfarin is started the night before surgery, usually in a dose of 5 mg. INR denotes international normalized ratio.

§In Europe, the customary approach to prophylaxis in patients undergoing joint replacement is to give 40 mg of enoxaparin the night before surgery and then 40 mg once daily thereafter.

¶Prophylaxis is used in women with a history of idiopathic pulmonary embolism or deep venous thrombosis.

raphy may be misleading. In a meta-analysis of hip-replacement and knee-replacement studies, venous ultrasonography (as compared with contrast venography) had only a 62 percent sensitivity for detecting proximal deep venous thrombosis.<sup>138</sup>

In a survey of patients in medical intensive care units, deep venous thrombosis developed in one third, and half of these cases involved the proximal portion of the leg.<sup>139</sup> Patients in intensive care units are often poor candidates for pharmacologic prophylaxis because of overt bleeding or thrombocytopenia. Leg ulcers, wounds, or peripheral arterial occlusive disease may preclude the use of intermittent pneumatic compression.

## CONCLUSIONS

We have recently gained a better understanding of environmental and inherited risk factors for venous thromboembolism. A wide array of diagnostic tools maximizes our ability to detect or rule out pulmonary embolism. New appreciation of the importance of right ventricular dysfunction in patients with pulmonary embolism enables us to prognosticate more precisely. Finally, the expansion of options for prophylaxis facilitates the prevention of this potentially serious disorder.

## REFERENCES

- Skibo L, Goldhaber SZ. Diagnosis of acute pulmonary embolism. In: Goldhaber SZ, ed. Cardiopulmonary diseases and cardiac tumors. Vol. 3 of Atlas of heart diseases. Philadelphia: Current Medicine, 1995;2.1-2.31.
- Elliott CG. Pulmonary physiology during pulmonary embolism. *Chest* 1992;101:Suppl:163S-171S.
- Moser KM, Fedullo PF, LitteJohn JK, Crawford R. Frequent asymptomatic pulmonary embolism in patients with deep venous thrombosis. *JAMA* 1994;271:223-5. [Erratum, *JAMA* 1994;271:1908.]
- Turkstra F, Kuijter PMM, van Beek EJR, Brandjes DPM, ten Cate JW, Büller HR. Diagnostic utility of ultrasonography of leg veins in patients suspected of having pulmonary embolism. *Ann Intern Med* 1997;127:75-81.
- Anderson FA Jr, Wheeler HB, Goldberg RJ, et al. A population-based perspective of the hospital incidence and case-fatality rates of deep vein thrombosis and pulmonary embolism: the Worcester DVT Study. *Arch Intern Med* 1991;151:933-8.
- Silverstein MD, Heit JA, Mohr DN, Petterson TM, O'Fallon WM, Melton LJ III. Trends in the incidence of deep vein thrombosis and pulmonary embolism: a 25-year population-based study. *Arch Intern Med* 1998;158:585-93.
- Kniffin WD Jr, Baron JA, Barrett J, Birkmeyer JD, Anderson FA Jr. The epidemiology of diagnosed pulmonary embolism and deep venous thrombosis in the elderly. *Arch Intern Med* 1994;154:861-6.
- Goldhaber SZ, De Rosa M, Visani L. International Cooperative Pulmonary Embolism Registry detects high mortality rate. *Circulation* 1997;96:Suppl I:159. abstract.
- Carson JL, Kelley MA, Duff A, et al. The clinical course of pulmonary embolism. *N Engl J Med* 1992;326:1240-5.
- Siddique RM, Siddique MI, Connors AF Jr, Rimm AA. Thirty-day case-fatality rates for pulmonary embolism in the elderly. *Arch Intern Med* 1996;156:2343-7.
- Ribeiro A, Lindmarker P, Juhlin-Dannfelt A, Johnsson H, Jorfeldt L. Echocardiography Doppler in pulmonary embolism: right ventricular dysfunction as a predictor of mortality rate. *Am Heart J* 1997;134:479-87.
- Kasper W, Konstantinides S, Geibel A, Tiede N, Krause T, Just H. Prognostic significance of right ventricular afterload stress detected by echocardiography in patients with clinically suspected pulmonary embolism. *Heart* 1997;77:346-9.
- Kasper W, Konstantinides S, Geibel A, et al. Management strategies and determinants of outcome in acute major pulmonary embolism: results of a multicenter registry. *J Am Coll Cardiol* 1997;30:1165-71.
- Goldhaber SZ, Grodstein F, Stampfer MJ, et al. A prospective study of risk factors for pulmonary embolism in women. *JAMA* 1997;277:642-5.
- Koonin LM, Atrash HK, Lawson HW, Smith JC. Maternal mortality surveillance, United States, 1979-1986. *MMWR CDC Surveill Summ* 1991;40(SS-2):1-13.
- World Health Organization Collaborative Study of Cardiovascular Disease and Steroid Hormone Contraception. Venous thromboembolic disease and combined oral contraceptives: results of international multicenter case-control study. *Lancet* 1995;346:1575-82.
- Idem. Effect of different progestagens in low oestrogen oral contraceptives on venous thromboembolic disease. *Lancet* 1995;346:1582-8.
- Jick H, Jick SS, Gurewich V, Myers MW, Vasilakis C. Risk of idiopathic cardiovascular death and nonfatal venous thromboembolism in women using oral contraceptives with differing progestagen components. *Lancet* 1995;346:1589-93.
- Farmer RDT, Lawrenson RA, Thompson CR, Kennedy JG, Hambleton IR. Population-based study of risk of venous thromboembolism associated with various oral contraceptives. *Lancet* 1997;349:83-8.
- Vandenbroucke JP, Helmerhorst FM. Risk of venous thrombosis with hormone-replacement therapy. *Lancet* 1996;348:972.

21. Daly E, Vessey MP, Hawkins MM, Carson JL, Gough P, Marsh S. Risk of venous thromboembolism in users of hormone replacement therapy. *Lancet* 1996;348:977-80.
22. Jick H, Derby LE, Myers MW, Vasilakis C, Newton KM. Risk of hospital admission for idiopathic venous thromboembolism among users of postmenopausal oestrogens. *Lancet* 1996;348:981-3.
23. Grodstein F, Stampfer MJ, Goldhaber SZ, et al. Prospective study of exogenous hormones and risk of pulmonary embolism in women. *Lancet* 1996;348:983-7.
24. Piccoli A, Prandoni P, Ewenstein BM, Goldhaber SZ. Cancer and venous thromboembolism. *Am Heart J* 1996;132:850-5.
25. Nordström M, Lindblad B, Anderson H, Bergqvist D, Kjellström T. Deep venous thrombosis and occult malignancy: an epidemiological study. *BMJ* 1994;308:891-4.
26. Prandoni P, Lensing AWA, Büller HR, et al. Deep-vein thrombosis and the incidence of subsequent symptomatic cancer. *N Engl J Med* 1992;327:1128-33.
27. Bergqvist D, Lindblad B. A 30-year survey of pulmonary embolism verified at autopsy: an analysis of 1274 surgical patients. *Br J Surg* 1985;72:105-8.
28. Huber O, Bounameaux H, Borst F, Rohner A. Postoperative pulmonary embolism after hospital discharge: an underestimated risk. *Arch Surg* 1992;127:310-3.
29. Svensson PJ, Dahlbäck B. Resistance to activated protein C as a basis for venous thrombosis. *N Engl J Med* 1994;330:517-22.
30. Bertina RM, Koeleman BPC, Koster T, et al. Mutation in blood coagulation factor V associated with resistance to activated protein C. *Nature* 1994;369:64-7.
31. Voorberg J, Roelke J, Koopman R, et al. Association of idiopathic venous thromboembolism with single point-mutation at ARG<sup>506</sup> of factor V. *Lancet* 1994;343:1535-6.
32. Zoller B, Svensson PJ, He X, Dahlback B. Identification of the same factor V gene mutation in 47 out of 50 thrombosis-prone families with inherited resistance to activated protein C. *J Clin Invest* 1994;94:2521-4.
33. Price DT, Ridker PM. Factor V Leiden mutation and the risks for thromboembolic disease: a clinical perspective. *Ann Intern Med* 1997;127:895-903.
34. Ridker PM, Hennekens CH, Lindpaintner K, Stampfer MJ, Eisenberg PR, Miletich JP. Mutation in the gene coding for coagulation factor V and the risks of myocardial infarction, stroke, and venous thrombosis in apparently healthy men. *N Engl J Med* 1995;332:912-7.
35. Rees DC, Cox M, Clegg JB. World distribution of factor V Leiden. *Lancet* 1995;346:1133-4.
36. Simioni P, Prandoni P, Lensing AWA, et al. The risk of recurrent venous thromboembolism in patients with an Arg506→Gln mutation in the gene for factor V (factor V Leiden). *N Engl J Med* 1997;336:399-403.
37. Ridker PM, Miletich JP, Stampfer MJ, Goldhaber SZ, Lindpaintner K, Hennekens CH. Factor V Leiden and risks of recurrent idiopathic venous thromboembolism. *Circulation* 1995;92:2800-2.
38. Olivieri O, Friso S, Manzato F, et al. Resistance to activated protein C in healthy women taking oral contraceptives. *Br J Haematol* 1995;91:465-70.
39. Hirsch DR, Mikkola KM, Marks PW, et al. Pulmonary embolism and deep venous thrombosis during pregnancy or oral contraceptive use: prevalence of factor V Leiden. *Am Heart J* 1996;131:1145-8.
40. Vandenbroucke JP, Koster T, Briët E, Reitsma PH, Bertina RM, Rosendaal FR. Increased risk of venous thrombosis in oral-contraceptive users who are carriers of factor V Leiden mutation. *Lancet* 1994;344:1453-7.
41. Bloemenkamp KWM, Rosendaal FR, Helmerhorst FM, Büller HR, Vandenbroucke JP. Enhancement by factor V Leiden mutation of risk of deep-vein thrombosis associated with oral contraceptives containing a third-generation progestagen. *Lancet* 1995;346:1593-6.
42. Rosing J, Tans G, Nicolaes GAF, et al. Oral contraceptives and venous thrombosis: different sensitivities to activated protein C in women using second- and third-generation oral contraceptives. *Br J Haematol* 1997;97:233-8.
43. D'Angelo A, Selhub J. Homocysteine and thrombotic disease. *Blood* 1997;90:1-11.
44. Simioni P, Prandoni P, Burlina A, et al. Hyperhomocysteinemia and deep-vein thrombosis: a case-control study. *Thromb Haemost* 1996;76:883-6.
45. den Heijer M, Koster T, Blom HJ, et al. Hyperhomocysteinemia as a risk factor for deep-vein thrombosis. *N Engl J Med* 1996;334:759-62.
46. Ridker PM, Hennekens CH, Selhub J, Miletich JP, Malinow MR, Stampfer MJ. Interrelation of hyperhomocyst(e)inemia, factor V Leiden, and risk of future venous thromboembolism. *Circulation* 1997;95:1777-82.
47. Hughes GRV. The antiphospholipid syndrome: ten years on. *Lancet* 1993;342:341-4.
48. Simioni P, Prandoni P, Zanoni E, et al. Deep venous thrombosis and lupus anticoagulant: a case-control study. *Thromb Haemost* 1996;76:187-9.
49. Comp PC, Thurnau GR, Welsh J, Esmon CT. Functional and immunologic protein S levels are decreased during pregnancy. *Blood* 1986;68:881-5.
50. Alving BM, Comp PC. Recent advances in understanding clotting and evaluating patients with recurrent thrombosis. *Am J Obstet Gynecol* 1992;167:1184-91.
51. Heijboer H, Brandjes DPM, Büller HR, Sturk A, ten Cate JW. Deficiencies of coagulation-inhibiting and fibrinolytic proteins in outpatients with deep-vein thrombosis. *N Engl J Med* 1990;323:1512-6.
52. van den Belt AGM, Sanson B-J, Simioni P, et al. Recurrence of venous thromboembolism in patients with familial thrombophilia. *Arch Intern Med* 1997;157:2227-32.
53. Stein PD, Terrin ML, Hales CA, et al. Clinical laboratory, roentgenographic, and electrocardiographic findings in patients with acute pulmonary embolism and no pre-existing cardiac or pulmonary disease. *Chest* 1991;100:598-603.
54. Ferrari E, Imbert A, Chevalier T, Mihoubi A, Morand P, Baudouy M. The ECG in pulmonary embolism: predictive value of negative T waves in precordial leads — 80 case reports. *Chest* 1997;111:537-43.
55. Palla A, Donnamaria V, Petruzzelli S, Rossi G, Riccetti G, Giuntini C. Enlargement of the right descending pulmonary artery in pulmonary embolism. *AJR Am J Roentgenol* 1983;141:513-7.
56. Bounameaux H, de Moerloose P, Perrier A, Reber G. Plasma measurement of D-dimer as diagnostic aid in suspected venous thromboembolism: an overview. *Thromb Haemost* 1994;71:1-6.
57. Bounameaux H, de Moerloose P, Perrier A, Miron MJ. D-dimer testing in suspected venous thromboembolism: an update. *QJM* 1997;90:437-42.
58. de Moerloose P, Minazio P, Reber G, Perrier A, Bounameaux H. D-dimer determination to exclude pulmonary embolism: a two-step approach using latex assay as a screening tool. *Thromb Haemost* 1994;72:89-91.
59. Stein PD, Goldhaber SZ, Henry JW, Miller AC. Arterial blood gas analysis in the assessment of suspected acute pulmonary embolism. *Chest* 1996;109:78-81.
60. Stein PD, Goldhaber SZ, Henry JW. Alveolar-arterial oxygen gradient in the assessment of acute pulmonary embolism. *Chest* 1995;107:139-43.
61. Lensing AWA, Prandoni P, Brandjes D, et al. Detection of deep-vein thrombosis by real-time B-mode ultrasonography. *N Engl J Med* 1989;320:342-5.
62. Hull RD, Hirsh J, Carter CJ, et al. Pulmonary angiography, ventilation lung scanning, and venography for clinically suspected pulmonary embolism with abnormal perfusion lung scan. *Ann Intern Med* 1983;98:891-9.
63. The PIOPE Investigators. Value of the ventilation/perfusion scan in acute pulmonary embolism: results of the Prospective Investigation of Pulmonary Embolism Diagnosis (PIOPE). *JAMA* 1990;263:2753-9.
64. Gottschalk A, Sostman HD, Coleman RE, et al. Ventilation-perfusion scintigraphy in the PIOPE study. II. Evaluation of the scintigraphic criteria and interpretation. *J Nucl Med* 1993;34:1119-26.
65. Stein PD, Terrin ML, Gottschalk A, Alavi A, Henry JW. Value of ventilation/perfusion scans versus perfusion scans alone in acute pulmonary embolism. *Am J Cardiol* 1992;69:1239-41.
66. Bone RC. The low-probability lung scan: a potentially lethal reading. *Arch Intern Med* 1993;153:2621-2.
67. Hull RD, Raskob GE, Pineo GF, Brant RF. The low-probability lung scan: a need for change in nomenclature. *Arch Intern Med* 1995;155:1845-51.
68. Goodman LR, Lipchik RJ. Diagnosis of acute pulmonary embolism: time for a new approach. *Radiology* 1996;199:25-7.
69. Remy-Jardin M, Remy J, Deschildre F, et al. Diagnosis of pulmonary embolism with spiral CT: comparison with pulmonary angiography and scintigraphy. *Radiology* 1996;200:699-706.
70. Meaney JFM, Weg JG, Chenevert TL, Stafford-Johnson D, Hamilton BH, Prince MR. Diagnosis of pulmonary embolism with magnetic resonance angiography. *N Engl J Med* 1997;336:1422-7.
71. Come PC. Echocardiographic evaluation of pulmonary embolism and its response to therapeutic interventions. *Chest* 1992;101:Suppl:151S-162S.
72. Jardin F, Dubourg O, Bourdarias JP. Echocardiographic pattern of acute cor pulmonale. *Chest* 1997;111:209-17.
73. McConnell MV, Solomon SD, Rayan ME, Come PC, Goldhaber SZ, Lee RT. Regional right ventricular dysfunction detected by echocardiography in acute pulmonary embolism. *Am J Cardiol* 1996;78:469-73.
74. Stein PD, Athanasoulis C, Alavi A, et al. Complications and validity of pulmonary angiography in acute pulmonary embolism. *Circulation* 1992;85:462-8.
75. Barritt DW, Jordan SC. Anticoagulant drugs in the treatment of pulmonary embolism: a controlled trial. *Lancet* 1960;1:1309-12.

76. Brandjes DPM, Heijboer H, Büller HR, de Rijk M, Jagt H, ten Cate JW. Acenocoumarol and heparin compared with acenocoumarol alone in the initial treatment of proximal-vein thrombosis. *N Engl J Med* 1992;327:1485-9.
77. Raschke RA, Reilly BM, Guidry JR, Fontana JR, Srinivas S. The weight-based heparin dosing nomogram compared with a "standard care" nomogram: a randomized controlled trial. *Ann Intern Med* 1993;119:874-81.
78. Levine MN, Hirsh J, Gent M, et al. A randomized trial comparing activated thromboplastin time with heparin assay in patients with acute venous thromboembolism requiring large daily doses of heparin. *Arch Intern Med* 1994;154:49-56.
79. Togli MR, Weg JG. Venous thromboembolism during pregnancy. *N Engl J Med* 1996;335:108-14.
80. Callander N, Rapaport SI. Trousseau's syndrome. *West J Med* 1993;158:364-71.
81. The Columbus Investigators. Low-molecular-weight heparin in the treatment of patients with venous thromboembolism. *N Engl J Med* 1997;337:657-62.
82. Simonneau G, Sors H, Charbonnier B, et al. A comparison of low-molecular-weight heparin with unfractionated heparin for acute pulmonary embolism. *N Engl J Med* 1997;337:663-9.
83. Whitehill TA. Caval interruption methods: comparison of options. *Semin Vasc Surg* 1996;9:59-69.
84. Pacouret G, Alison D, Pottier J-M, Bertrand P, Charbonnier B. Free-floating thrombus and embolic risk in patients with angiographically confirmed proximal deep venous thrombosis: a prospective study. *Arch Intern Med* 1997;157:305-8.
85. Decousus H, Leizorovicz A, Parent F, et al. A clinical trial of vena caval filters in the prevention of pulmonary embolism in patients with proximal deep-vein thrombosis. *N Engl J Med* 1998;338:409-15.
86. Harrison L, Johnston M, Massicotte MP, Crowther M, Moffat K, Hirsh J. Comparison of 5-mg and 10-mg loading doses in initiation of warfarin therapy. *Ann Intern Med* 1997;126:133-6.
87. Palareti G, Leali N, Coccheri S, et al. Bleeding complications of oral anticoagulant treatment: an inception-cohort, prospective collaborative study (ISCOAT). *Lancet* 1996;348:423-8.
88. Bussey HI, Chiquette E, Amato MG. Anticoagulation clinic care versus routine medical care: a review and interim report. *J Thromb Thrombolysis* 1996;2:315-9.
89. White RH, McCurdy SA, von Marensdorff H, Woodruff DE Jr, Leftgoff L. Home prothrombin time monitoring after the initiation of warfarin therapy: a randomized, prospective study. *Ann Intern Med* 1989;111:730-7.
90. Khamashta MA, Cuadrado MJ, Mujic F, Taub NA, Hunt BJ, Hughes GRV. The management of thrombosis in the antiphospholipid-antibody syndrome. *N Engl J Med* 1995;332:993-7.
91. Moll S, Ortel TL. Monitoring warfarin therapy in patients with lupus anticoagulants. *Ann Intern Med* 1997;127:177-85.
92. Schulman S, Rhedin A-S, Lindmarker P, et al. A comparison of six weeks with six months of oral anticoagulant therapy after a first episode of venous thromboembolism. *N Engl J Med* 1995;332:1661-5.
93. Schulman S, Granqvist S, Holmström M, et al. The duration of oral anticoagulant therapy after a second episode of venous thromboembolism. *N Engl J Med* 1997;336:393-8.
94. Hirsh J, Kearon C, Ginsberg J. Duration of anticoagulant therapy after first episode of venous thrombosis in patients with inherited thrombophilia. *Arch Intern Med* 1997;157:2174-7.
95. Warkentin TE. Heparin-induced thrombocytopenia: IgG-mediated platelet activation, platelet microparticle generation, and altered procoagulant/anticoagulant balance in the pathogenesis of thrombosis and venous limb gangrene complicating heparin-induced thrombocytopenia. *Transfus Med Rev* 1996;10:249-58.
96. Warkentin TE, Kelton JG. A 14-year study of heparin-induced thrombocytopenia. *Am J Med* 1996;101:502-7.
97. Warkentin TE, Elavathil LJ, Hayward CPM, Johnston MA, Russett JI, Kelton JG. The pathogenesis of venous limb gangrene associated with heparin-induced thrombocytopenia. *Ann Intern Med* 1997;127:804-12.
98. Magnani HN. Heparin-induced thrombocytopenia (HIT): an overview of 230 patients treated with Organon. *Thromb Haemost* 1993;70:554-61. [Erratum, *Thromb Haemost* 1993;70:1072.]
99. Schwarz RP Jr, Becker J-CP, Brooks RL, et al. The preclinical and clinical pharmacology of novastan (Argatroban): a small-molecule, direct thrombin inhibitor. *Clin Appl Thromb Hemost* 1997;3:1-15.
100. Jerjes-Sanchez C, Ramirez-Rivera A, Garcia ML, et al. Streptokinase and heparin versus heparin alone in massive pulmonary embolism: a randomized controlled trial. *J Thromb Thrombolysis* 1995;2:227-9.
101. Daniels LB, Parker JA, Patel SR, Grodstein F, Goldhaber SZ. Relation of duration of symptoms with response to thrombolytic therapy in pulmonary embolism. *Am J Cardiol* 1997;80:184-8.
102. Goldhaber SZ, Haire WD, Feldstein ML, et al. Alteplase versus heparin in acute pulmonary embolism: randomised trial assessing right-ventricular function and pulmonary perfusion. *Lancet* 1993;341:507-11.
103. Konstantinides S, Geibel A, Olschewski M, et al. Association between thrombolytic treatment and the prognosis of hemodynamically stable patients with major pulmonary embolism: results of a multicenter registry. *Circulation* 1997;96:882-8.
104. Mikkola KM, Patel SR, Parker JA, Grodstein F, Goldhaber SZ. Increasing age is a major risk factor for hemorrhagic complications after pulmonary embolism thrombolysis. *Am Heart J* 1997;134:69-72.
105. Greenfield LJ, Proctor MC, Williams DM, Wakefield TW. Long-term experience with transvenous catheter pulmonary embolectomy. *J Vasc Surg* 1997;96:450-7.
106. Gulba DC, Schmid C, Borst H-G, Lichtlen P, Dietz R, Luft FC. Medical compared with surgical treatment for massive pulmonary embolism. *Lancet* 1994;343:576-7.
107. Koning R, Cribier A, Gerber L, et al. A new treatment for severe pulmonary embolism: percutaneous rheolytic thrombectomy. *Circulation* 1997;96:2498-500.
108. Fava M, Loyola S, Flores P, Huete I. Mechanical fragmentation and pharmacologic thrombolysis in massive pulmonary embolism. *J Vasc Interv Radiol* 1997;8:261-6.
109. Layish DT, Tapson VE. Pharmacologic hemodynamic support in massive pulmonary embolism. *Chest* 1997;111:218-24.
110. Fedullo PF, Auger WR, Channick RN, Jamieson SW, Moser KM. A multidisciplinary approach to chronic thromboembolic pulmonary hypertension. In: Goldhaber SZ, ed. *Cardiopulmonary diseases and cardiac tumors*. Vol. 3 of *Atlas of heart diseases*. Philadelphia: Current Medicine, 1995:71-725.
111. Prevention of venous thromboembolism: international consensus statement (guidelines according to scientific evidence). *Int Angiol* 1997;16:3-38.
112. Goldhaber SZ, ed. *Prevention of venous thromboembolism*. New York: Marcel Dekker, 1993.
113. Allenby F, Boardman L, Pflug JJ, Calnan JS. Effects of external pneumatic intermittent compression on fibrinolysis in man. *Lancet* 1973;2:1412-4.
114. Guyton DP, Khayat A, Husni EA, Schreiber H. Elevated levels of 6-keto-prostaglandin-Fl $\alpha$  from a lower extremity during external pneumatic compression. *Surg Gynecol Obstet* 1988;166:338-42.
115. Kessler CM, Hirsch DR, Jacobs H, MacDougall R, Goldhaber SZ. Intermittent pneumatic compression in chronic venous insufficiency favorably affects fibrinolytic potential and platelet activation. *Blood Coagul Fibrinolysis* 1996;7:437-46.
116. Comerota AJ, Katz ML, White JV. Why does prophylaxis with external pneumatic compression for deep vein thrombosis fail? *Am J Surg* 1992;164:265-8.
117. Stannard JP, Harris RM, Bucknell AL, Cossi A, Ward J, Arrington ED. Prophylaxis of deep venous thrombosis after total hip arthroplasty by using intermittent compression of the plantar venous plexus. *Am J Orthop* 1996;25:127-34.
118. Prevention of fatal postoperative pulmonary embolism by low doses of heparin: an international multicentre trial. *Lancet* 1975;2:45-51.
119. Collins R, Scrimgeour A, Yusuf S, Peto R. Reduction in fatal pulmonary embolism and venous thrombosis by perioperative administration of subcutaneous heparin: overview of results of randomized trials in general, orthopedic, and urologic surgery. *N Engl J Med* 1988;318:1162-73.
120. Weitz JI. Low-molecular-weight heparins. *N Engl J Med* 1997;337:688-98. [Erratum, *N Engl J Med* 1997;337:1567.]
121. Hoek JA, Nurmohamed MT, Hamelnyck KJ, et al. Prevention of deep vein thrombosis following total hip replacement by low molecular weight heparinoid. *Thromb Haemost* 1992;67:28-32.
122. Heit JA, Berkowitz SD, Bona R, et al. Efficacy and safety of low molecular weight heparin (ardepurin sodium) compared to warfarin for the prevention of venous thromboembolism after total knee replacement surgery: a double-blind, dose-ranging study. *Thromb Haemost* 1997;77:32-8.
123. Antiplatelet Trialists' Collaboration. Collaborative overview of randomized trials of antiplatelet therapy. III. Reduction in venous thrombosis and pulmonary embolism by antiplatelet prophylaxis among surgical and medical patients. *BMJ* 1994;308:235-46.
124. Hull RD, Raskob GE, Gent M, et al. Effectiveness of intermittent pneumatic leg compression for preventing deep vein thrombosis after total hip replacement. *JAMA* 1990;263:2313-7.
125. Levine MN, Hirsh J, Gent M, et al. Prevention of deep vein thrombosis after elective hip surgery: a randomized trial comparing low molecular weight heparin with standard unfractionated heparin. *Ann Intern Med* 1991;114:545-51.
126. Leclerc JR, Geerts WH, Desjardins L, et al. Prevention of venous thromboembolism after knee arthroplasty: a randomized, double-blind trial comparing enoxaparin with warfarin. *Ann Intern Med* 1996;124:619-26.
127. Levine MN, Gent M, Hirsh J, et al. Ardepurin (low-molecular-weight

heparin) vs graduated compression stockings for the prevention of venous thromboembolism: a randomized trial in patients undergoing knee surgery. *Arch Intern Med* 1996;156:851-6.

**128.** Geerts WH, Jay RM, Code KI, et al. A comparison of low-dose heparin with low-molecular-weight heparin as prophylaxis against venous thromboembolism after major trauma. *N Engl J Med* 1996;335:701-7.

**129.** Halkin H, Goldberg J, Modan M, Modan B. Reduction of mortality in general medical in-patients by low-dose heparin prophylaxis. *Ann Intern Med* 1982;96:561-5.

**130.** Hunt BJ, Doughty HA, Majumdar G, et al. Thromboprophylaxis with low molecular weight heparin (Fragmin) in high risk pregnancies. *Thromb Haemost* 1997;77:39-43.

**131.** ENOXACAN Study Group. Efficacy and safety of enoxaparin versus unfractionated heparin for prevention of deep vein thrombosis in elective cancer surgery: a double-blind randomised multicentre trial with venographic assessment. *Br J Surg* 1997;84:1099-103.

**132.** Parment JL, Berman AT, Horrow JC, Harding S, Rosenberg H. Thromboembolism coincident with tourniquet deflation during total knee arthroplasty. *Lancet* 1993;341:1057-8.

**133.** Planes A, Vochelle N, Darmon J-Y, Fagola M, Bellaud M, Huet Y. Risk of deep-venous thrombosis after hospital discharge in patients having undergone total hip replacement: double-blind randomised comparison of enoxaparin versus placebo. *Lancet* 1996;348:224-8.

**134.** Bergqvist D, Benoni G, Björgell O, et al. Low-molecular-weight heparin (enoxaparin) as prophylaxis against venous thromboembolism after total hip replacement. *N Engl J Med* 1996;335:696-700.

**135.** Dahl EO, Andreassen G, Aspelin T, et al. Prolonged thromboprophylaxis following hip replacement surgery — results of a double-blind, prospective, randomised, placebo-controlled study with dalteparin. *Thromb Haemost* 1997;77:26-31.

**136.** Leclerc JR, Gent M, Hirsh J, Geerts WH, Ginsberg JS, Canadian Collaborative Group. The incidence of symptomatic venous thromboembolism during and after prophylaxis with enoxaparin: a multi-institutional cohort study in patients who underwent hip or knee arthroplasty. *Arch Intern Med* 1998;158:873-8.

**137.** Robinson KS, Anderson DR, Gross M, et al. Ultrasonographic screening before hospital discharge for deep venous thrombosis after arthroplasty: The Post-Arthroplasty Screening Study: a randomized controlled trial. *Ann Intern Med* 1997;127:439-45.

**138.** Wells PS, Lensing AWA, Davidson BL, Prins MH, Hirsh J. Accuracy of ultrasound for the diagnosis of deep venous thrombosis in asymptomatic patients after orthopedic surgery: a meta-analysis. *Ann Intern Med* 1995;122:47-53.

**139.** Hirsch DR, Ingenito EP, Goldhaber SZ. Prevalence of deep venous thrombosis among patients in medical intensive care. *JAMA* 1995;274:335-7.