

## Hemodynamic Instability in Sepsis Bedside Assessment by Doppler Echocardiography

Antoine Vieillard-Baron, Sebastien Prin, Karim Chergui, Olivier Dubourg, and François Jardin

Medical Intensive Care Unit and the Department of Cardiology, University Hospital Ambroise Paré, Assistance Publique Hôpitaux de Paris, Boulogne Cedex, France

Septic shock is associated with important hemodynamic alterations, including absolute or relative decrease in central blood volume (1), systolic alterations of left ventricular (LV) (2, 3) and right ventricular (RV) (4) function, and severe peripheral vasodilatation responsible in part for alterations in regional blood flow distribution and probably linked to outcome (5). Hemodynamic treatment of septic shock requires blood volume expansion, which has proved to enhance survival if not delayed (6), and vasoactive support with catecholamines, according to the hemodynamic status (7).

For a long time, assessment of hemodynamic instability in sepsis was based on right heart catheterization at the bedside. Recently, the Task Force of the American College of Critical Care Medicine reiterated the usefulness of right heart catheterization in guiding hemodynamic support in patients requiring more than an initial blood volume expansion (7). Concerns about the data obtained by this technique, and their interpretation in a mechanically ventilated patient, are not new (8). Moreover, this technique has been criticized for its invasiveness and associated specific complications (9). However, large cooperative clinical trials have not demonstrated an increase in mortality carried by right heart catheterization (10, 11).

We abandoned right heart catheterization in our unit in 1990 and have replaced it by routine echocardiography. Since then, all patients hospitalized with septic shock have been monitored using echocardiography as a noninvasive bedside procedure. In our daily practice, echocardiography is performed after physical examination in all hemodynamically unstable patients and repeated immediately after each major hemodynamic intervention. For this purpose, the frozen multiplane probe can be kept in the esophagus for the time needed to assess the results of a major hemodynamic intervention (10–20 minutes). This strategy is original, few French teams use it, and no trial has demonstrated the usefulness of echocardiography in severe sepsis. But the quality of the data obtained and the growing demand for training from intensivists have convinced us that this procedure will be widely used in the future.

Data from echocardiographic evaluation of a series of 183 patients have been published, emphasizing that a large spectrum of changes in ventricular systolic function can be observed in

septic shock (12–15). More recently, examination of the superior vena cava by echography has allowed us to assess volume status in this setting (16). In the present commentary, we shall try to provide a practical approach to the assessment of hemodynamic derangement in patients with sepsis on the basis of our previous work. For this purpose, we shall describe our step-by-step evaluation of hemodynamics by Doppler echocardiography, allowing us to delineate the precise cause(s) of hemodynamic compromise in a given patient with sepsis and to assess the efficacy of the supportive therapy implemented.

In addition to echocardiographic examples given to illustrate this clinical commentary, 19 narrated video clips can be found in the online supplement.

### DESCRIPTION OF THE MAIN ECHOCARDIOGRAPHIC VIEWS USED TO ASSESS HEMODYNAMIC STATUS IN PATIENTS WITH SEPTIC SHOCK

In a mechanically ventilated patient, transesophageal echocardiography is the preferred approach for an accurate examination. However, transthoracic echocardiography may also be useful, depending on the quality of views obtained by this approach. In a spontaneously breathing patient, we only use transthoracic echocardiography because transesophageal echocardiography may be uncomfortable.

By transesophageal echocardiography, a long-axis view permits examination of the four cardiac cavities (Figure 1A). From this view we measure LV and RV end-diastolic and end-systolic size and calculate the LV ejection fraction. A similar pattern is obtained by an apical four-chamber view by transthoracic echocardiography. A short-axis view of both ventricles by a transgastric or a transthoracic approach also permits measurement of LV size, calculation of LV fractional area contraction, and examination of septal shape and kinetics (Figure 1B). Using transesophageal echocardiography, a long-axis view of the superior vena cava, anastomosing with the right atrium, allows us to examine variation in its diameter during the respiratory cycle (Figure 1C). Finally, a long-axis view of the LV outflow tract, by a transgastric approach (Figure 1D), and a long-axis view of the RV outflow tract, by a transesophageal or a transgastric approach (Figure 1E), permits Doppler measurement of both left and right stroke outputs, by simultaneously measuring aortic and pulmonary artery diameters.

Echocardiography is essentially a qualitative procedure. However, quantitative measurements may be useful, and examples will be given in this paper. The main echocardiographic values obtained in normal volunteers in our laboratory are reported in Table 1. We have also tested the reproducibility of these measurements in normal volunteers (Table 2).

When assessing cardiac stroke index in a hemodynamically unstable patient with sepsis, we usually use Doppler aortic flow velocity measurement. However, if it is not possible to obtain

(Received in original form June 19, 2003; accepted in final form September 25, 2003)

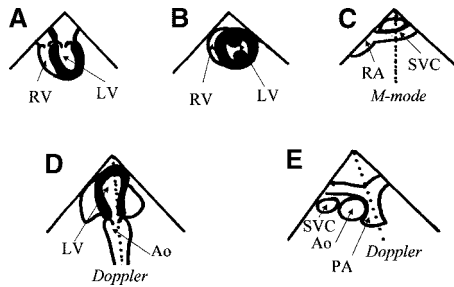
Correspondence and requests for reprints should be addressed to François Jardin, M.D., Hôpital Ambroise Paré, 9 Avenue Charles de Gaulle, 92104 Boulogne Cedex, France. E-mail: francois.jardin@apr.ap-hop-paris.fr

This article has an online supplement, which is accessible from this issue's table of contents online at [www.atsjournals.com](http://www.atsjournals.com)

Am J Respir Crit Care Med Vol 168. pp 1270–1276, 2003

DOI: 10.1164/rccm.200306-816CC

Internet address: [www.atsjournals.org](http://www.atsjournals.org)



**Figure 1.** Main echocardiographic views used to assess hemodynamic status: (A) a long-axis transesophageal view; (B) a transgastric view; (C) a long-axis view of the superior vena cava (SVC) at its entry in the pericardial space; (D) a long-axis transgastric view of the left ventricle (LV) outflow tract; (E) a long-axis view of the main pulmonary artery (PA). Broken lines denote the orientation of M-mode or Doppler ultrasound beam. Ao = aorta; RA = right atrium; RV = right ventricle.

a transaortic flow velocity with a multiplane probe, a situation encountered in approximately 10% of patients, cardiac stroke index can be measured using Doppler pulmonary artery flow velocity. By comparing 76 simultaneous measurements obtained in 38 patients by both techniques, we found an average stroke index of  $29 \pm 8$  ml/m<sup>2</sup> (range 14–46 ml/m<sup>2</sup>) and of  $28 \pm 8$  ml/m<sup>2</sup> (range 13–41 ml/m<sup>2</sup>) by aortic flow and pulmonary artery flow velocity, respectively. Both values were strongly correlated ( $r = 0.96$ ,  $p = 0.0000$ ), and we found a good agreement between the two techniques (lower limit of agreement: 3 ml/m<sup>2</sup>, upper limit of agreement: 7 ml/m<sup>2</sup>).

## EVALUATION OF VOLUME STATUS

Central blood volume, i.e., the blood present in the thoracic vessels ( $\sim 500$  ml in a normal adult, i.e., 10% of the total blood volume), constitutes the filling reserve for the LV. Central blood volume is regularly mobilized by RV systole, after LV systole has occurred (17). Central blood volume may be inadequate in a patient with hypovolemia, or relatively inadequate, as a result of an excessive airway and/or pleural pressure displacing blood from the intrathoracic vessels toward the extrathoracic vessels. In both settings, LV diastolic filling is insufficient, LV stroke is reduced, and  $\dot{Q}$  becomes abnormally low.

**TABLE 1. MAIN ECHOCARDIOGRAPHIC VALUES OBTAINED BY TRANSTHORACIC ECHOCARDIOGRAPHY IN 44 ADULT VOLUNTEERS**

LVEDVi, ml/m <sup>2</sup>	$71 \pm 15$
LVESVi, ml/m <sup>2</sup>	$22 \pm 8$
LVEF, %	$69 \pm 7$
LVEDAi, cm <sup>2</sup> /m <sup>2</sup>	$13 \pm 2$
LVEAi, cm <sup>2</sup> /m <sup>2</sup>	$5 \pm 1$
RVEDA/LVEDA	$0.48 \pm 0.11$
Ao <sub>VTI</sub> , cm	$20 \pm 4$
PA <sub>VTI</sub> , cm	$16 \pm 3$

*Definition of abbreviations:* Ao<sub>VTI</sub> = aortic velocity time integral; LVEDAi = left ventricular end-diastolic area index (short axis); LVEDVi = left ventricular end-diastolic volume index (long axis); LVEF = left ventricular ejection fraction; LVEAi = left ventricular end-systolic area index (short axis); LVESVi = left ventricular end-systolic volume index (long axis); PA<sub>VTI</sub> = pulmonary artery velocity time integral; RVEDA/LVEDA = right ventricular end-diastolic/left ventricular end-diastolic area ratio (long axis).

Comparisons performed in our unit in ventilated patients have shown that measurements obtained by transesophageal echocardiography (TEE) are in the same range as those obtained by transthoracic echocardiography, except for LV volumes in the long axis: 12% smaller on average by TEE.

**TABLE 2. REPRODUCIBILITY OF ECHO-DOPPLER MEASUREMENT USED TO ASSESS HEMODYNAMIC INSTABILITY, OBTAINED IN A GROUP OF 44 NORMAL VOLUNTEERS**

	Intraobserver Variability (%)	Interobserver Variability (%)
LVEDVi	$7 \pm 7$	$6 \pm 6$
LVESVi	$9 \pm 8$	$10 \pm 9$
RVEDA/LVEDA	$6 \pm 5$	$8 \pm 5$
Ao <sub>VTI</sub>	$3 \pm 5$	$8 \pm 7$
PA <sub>VTI</sub>	$9 \pm 6$	$10 \pm 2$

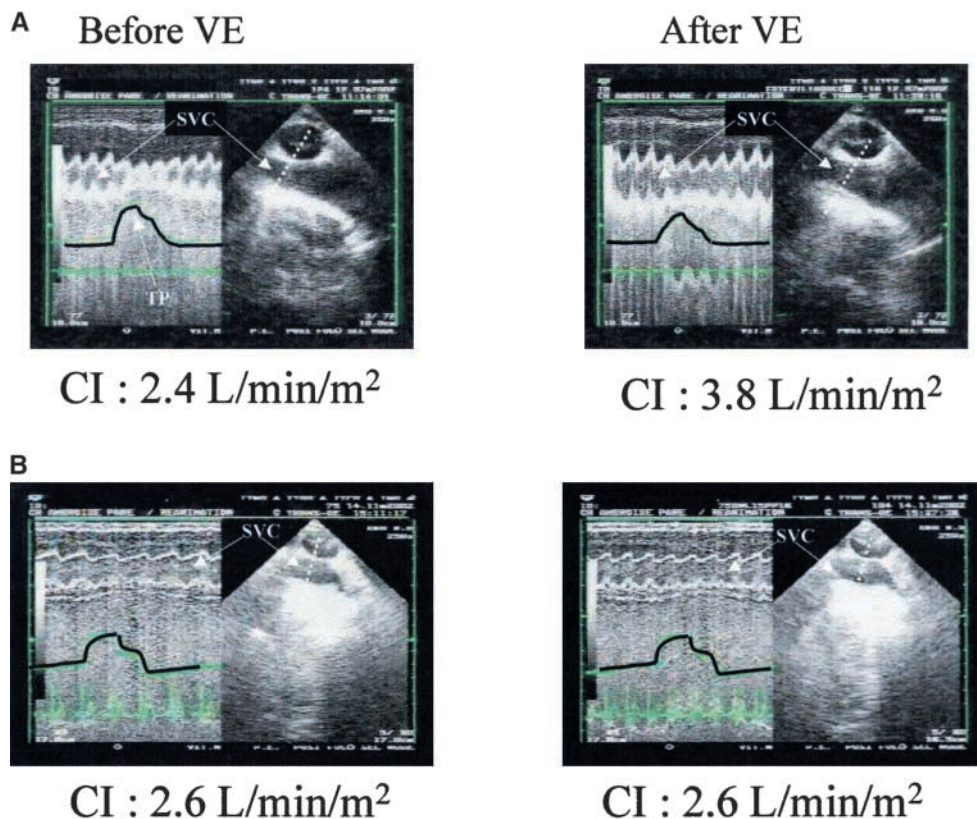
*Definition of abbreviations:* Ao<sub>VTI</sub> = aortic velocity time integral; LVEDVi = left ventricular end-diastolic volume index; LVESVi = left ventricular end-systolic volume index; PA<sub>VTI</sub> = pulmonary artery velocity time integral; RVEDA/LVEDA = right ventricular end-diastolic/left ventricular end-diastolic area ratio (long axis).

The inadequacy of volume status should be rapidly detected and corrected in patients with sepsis. Indeed, blood volume expansion has proved to improve prognosis significantly (6), whereas inappropriate use of vasopressor agents in hypovolemic situations leads to increase in tissue hypoperfusion and severe ischemia of vital organs (18). The Task Force of the American College of Critical Care Medicine has recently recommended in patients with septic shock an increase in left heart filling pressure to a level associated with a maximal increase in  $\dot{Q}$ , i.e., between 12 and 15 mm Hg of pulmonary capillary wedge pressure in most patients (7). However, recent studies have clearly demonstrated that the baseline value of pulmonary capillary wedge pressure was unable to predict fluid responsiveness in a given patient (19, 20).

In a patient having abdominal surgery requiring temporary clamping of the inferior vena cava and monitored by transesophageal echocardiography in the operating room, we recently observed an acute inadequacy of the vascular filling of the central compartment, by visualizing a sudden inspiratory collapse of the superior vena cava, (see Films 1A and 1B in the online supplement). When insufficiently filled, the superior vena cava becomes sensitive to respiratory changes in pleural pressure. We thus hypothesized that the adequacy of volume status can be evaluated by inspection of respiratory changes in the superior vena cava. We recently confirmed this relationship in 22 patients with septic shock undergoing mechanical ventilation (16). In particular, a high collapsibility index (i.e., maximal expiratory diameter minus minimal inspiratory diameter, divided by maximal expiratory diameter) of the superior vena cava, which reveals a conflict between the level of pleural pressure (i.e., the external pressure for the vessel) and the amount of vascular filling, indicated a need for volume expansion (Figure 2, see Films 2A and 2B in the online supplement) (16). Since then, we have demonstrated in 48 patients with circulatory failure that a superior vena caval collapsibility index of greater than or equal to 60% could predict a positive response to volume expansion, marked by a 15% or greater increase in Doppler  $\dot{Q}$  (Figure 3).

## EVALUATION OF LV SYSTOLIC FUNCTION

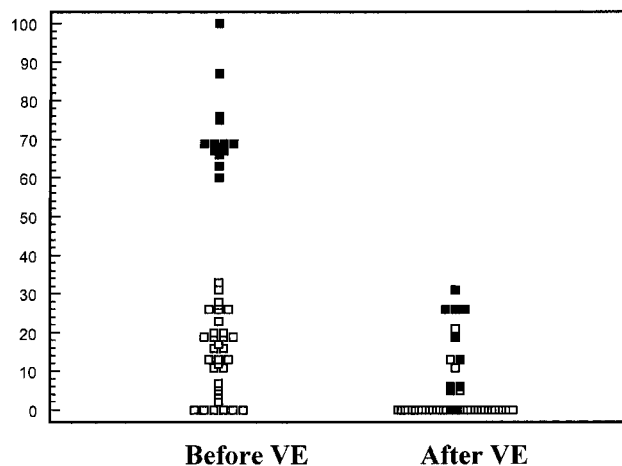
Septic shock has long been considered as hyperkinetic shock (21, 22). Even if this concept remains largely true, a hypokinetic state of septic shock is now well recognized, as illustrated by a significant decrease in LV systolic function measured by both radionuclide angiography (2) and echocardiography (3, 12). In this situation, patients with sepsis have a markedly depressed LV ejection fraction, a low  $\dot{Q}$  as measured by the Doppler technique, and systemic vascular resistance higher than usual in sepsis (13, 22).



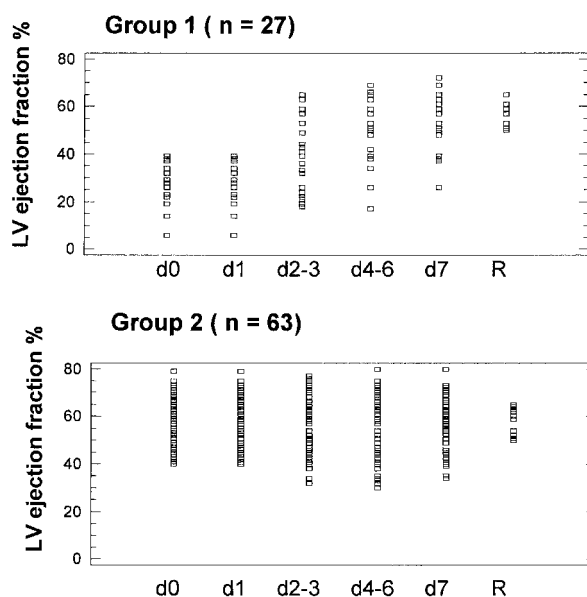
**Figure 2.** Illustrative examples of changes in SVC collapsibility before and after volume expansion (VE). In Patient A (*top*), a high collapsibility during lung inflation was associated with a low cardiac index (CI), and both were corrected by VE. In Patient B (*bottom*), the vena caval diameter was uninfluenced by lung inflation, and VE did not produce any increase in CI. TP = tracheal pressure.

#### Incidence of LV Systolic Dysfunction and Specific Vasoactive Treatment

In our series of 183 patients with septic shock (12–15) a hypokinetic state at admission, as defined by a low cardiac index ( $< 3$  L/minute/m<sup>2</sup>), was present in 64 patients (35%). Assessment of LV systolic function by echocardiography found this profile associated with a markedly hypokinetic LV (mean LV ejection fraction:  $38 \pm 17\%$ ) (*see Film 3 in the online supplement*). In the initial study by Parker and coworkers using radionuclide



**Figure 3.** Individual values of SVC collapsibility index (%) in 48 patients with septic shock before and after volume expansion (VE). A threshold value of 60% permitted discrimination between responders (*closed squares*) and nonresponders (*open squares*) to VE.



**Figure 4.** Serial measurements of LV ejection fraction (LVEF) in 90 patients with septic shock evaluated daily by transthoracic echocardiography. Patients were individualized into two groups, according to their initial LVEF: Group 1 had an ejection fraction at admission lower than 40%, whereas Group 2 had an ejection fraction at admission greater than 40%. d0 = admission; d1 = after 24 hours of treatment; d2–3 = after 2–3 days of treatment; d4–6 = after 4–6 days of treatment; d7 = after 1 week of treatment; R = recovery (data from Reference 14).

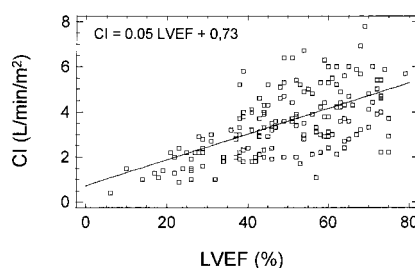


angiography, hypokinetic LV defined by an LV ejection fraction less than 45% was found in 55% of the population (2). We, and Parker and coworkers, previously reported the ability of the LV ejection fraction to normalize during patients' recovery (2, 14). This is now illustrated in Figure 4 (*top panel*) (see also Films 4A and 4B in the online supplement). The large range of LV ejection fractions observed at the onset of septic shock is also illustrated in Figure 4. However, it should be remembered that the ejection fraction only gives a rough approximation of systolic function because it is affected not only by contractility but also by preload and afterload (23).

When detected by bedside echocardiography, severely hypokinetic shock (LV ejection fraction < 35%) is always associated with a low  $\dot{Q}$  (Figure 5) (12) and requires administration of an inotropic agent (24). Dobutamine (5–8  $\mu\text{g/kg/minute}$ ) may be sufficient in isolated cases (25), but epinephrine (0.5–2  $\mu\text{g/kg/minute}$ ) is often required (Figure 6).

#### Incidence of Hyperkinetic State and Specific Vasoactive Treatment

Hyperdynamic shock is characterized by the combination of a low arterial pressure with marked tachycardia (26) and, from



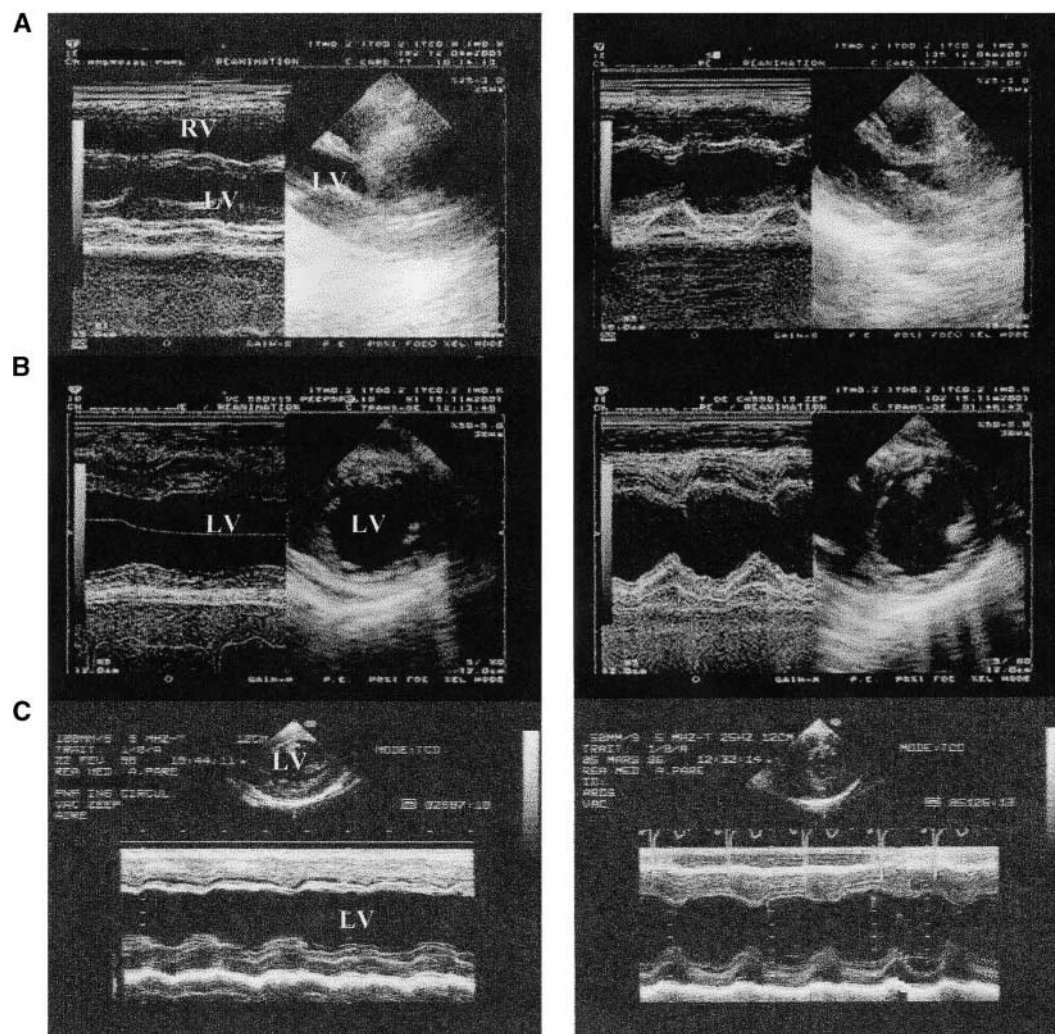
**Figure 5.** Simultaneous Doppler echocardiographic measurement of CI and LVEF in 183 patients with septic shock (pooled data from References 12–15). Note that the patients exhibiting a LVEF less than or equal to 35% also had a CI less than or equal to 3 L/minute/m<sup>2</sup>.

an echocardiographic point of view, by a hyperkinetic LV on echocardiography and/or a high  $\dot{Q}$  by Doppler measurement (see Film 5 in the online supplement).

In our series of 183 patients with septic shock in whom LV systolic function was explored using echocardiography, we found that 119 patients (65%) had an elevated cardiac index at admission (> 3 L/minute/m<sup>2</sup>). However, this proportion was higher

### Before inotropic support

### After inotropic support



**Figure 6.** Three illustrative examples of the beneficial effect of inotropic support on left ventricular (LV) contractility evaluated by M-mode study. (A) In a 23-year-old woman with septic shock of urinary origin, initial echocardiographic examination (transthoracic parasternal long axis) revealed severe LV hypokinesia (*left panel*, before inotropic support), which was corrected 30 minutes later by dobutamine (5 mcg/kg/minute) (*right panel*, after inotropic support). (B) In a 45-year-old woman with septic shock of urinary origin, initial echocardiographic examination (transgastric short-axis view) also revealed severe LV hypokinesia (*left panel*), which was corrected 30 minutes later by the same dosage of dobutamine (*right panel*). (C) In a 62-year-old man with septic shock of pulmonary origin, initial echocardiographic examination (transgastric short-axis view) demonstrated severe LV hypokinesia (*left panel*). Correction was achieved by epinephrine infusion, at a dosage of 0.5  $\mu\text{g/kg/minute}$  (*right panel*).

in the first studies (81%), where  $\dot{Q}$  was measured by the thermodilution method (12, 13), than in the two other studies (65%), where  $\dot{Q}$  was measured by Doppler echocardiography (14, 15). The thermodilution method, which is well known to overestimate  $\dot{Q}$  when a low flow state is present (27), has probably contributed to the assertion that septic shock is always hyperkinetic, whereas more than 30% of patients actually have hypodynamic shock with increased systemic vascular resistance. This inaccurate technique has also led to the debatable concept of acute LV dilatation in septic shock (2). A normal LV in a supine subject is really close to its limit of distension and has not much additional preload to offer. And although LV systolic dysfunction is often observed, dilatation is rarely seen using echocardiographic techniques in septic shock, as shown in Table 3. Moreover, we have reported that LV systolic function, and not LV dimensions, was the main determinant of LV stroke index, after optimal blood volume expansion (15).

Dopamine, at a dosage of 10 to 20  $\mu\text{g/kg/minute}$ , has been proposed as the first drug of choice for hyperdynamic shock (7). However, recent publications have suggested that use of this drug might retard the use of norepinephrine and adversely affect its efficacy (28, 29). Our personal strategy is to use norepinephrine, at a dosage of 0.5 to 2  $\mu\text{g/kg/minute}$ , as a first-line drug for hyperdynamic shock, as recommended by Martin and coworkers (28). However, a marked fall in systemic vascular resistance lowering LV afterload may well mask depressed myocardial contractility, which will be revealed when restoring arterial pressure by norepinephrine (*see* Films 6A and 6B in the online supplement). Echocardiographic control is thus required after starting norepinephrine infusion: when the afterload effect of norepinephrine appears excessive, a reduced dosage associated with dobutamine may be appropriate (*see* Film 6C in the online supplement).

**TABLE 3. LEFT VENTRICULAR DIMENSIONS BY TRANSTHORACIC ECHOCARDIOGRAPHY\* AND BY TRANSESOPHAGEAL ECHOCARDIOGRAPHY†**

	LVEDVi (ml/m <sup>2</sup> )	LVESVi (ml/m <sup>2</sup> )
1988–1989: 21 patients (13)	73 $\pm$ 20	29 $\pm$ 10
1993–1994: 32 patients (14)	66 $\pm$ 18	26 $\pm$ 18
1989–1993: 90 patients (15)	69 $\pm$ 24	36 $\pm$ 20
1997–1999: 40 patients (16)	61 $\pm$ 17	22 $\pm$ 8

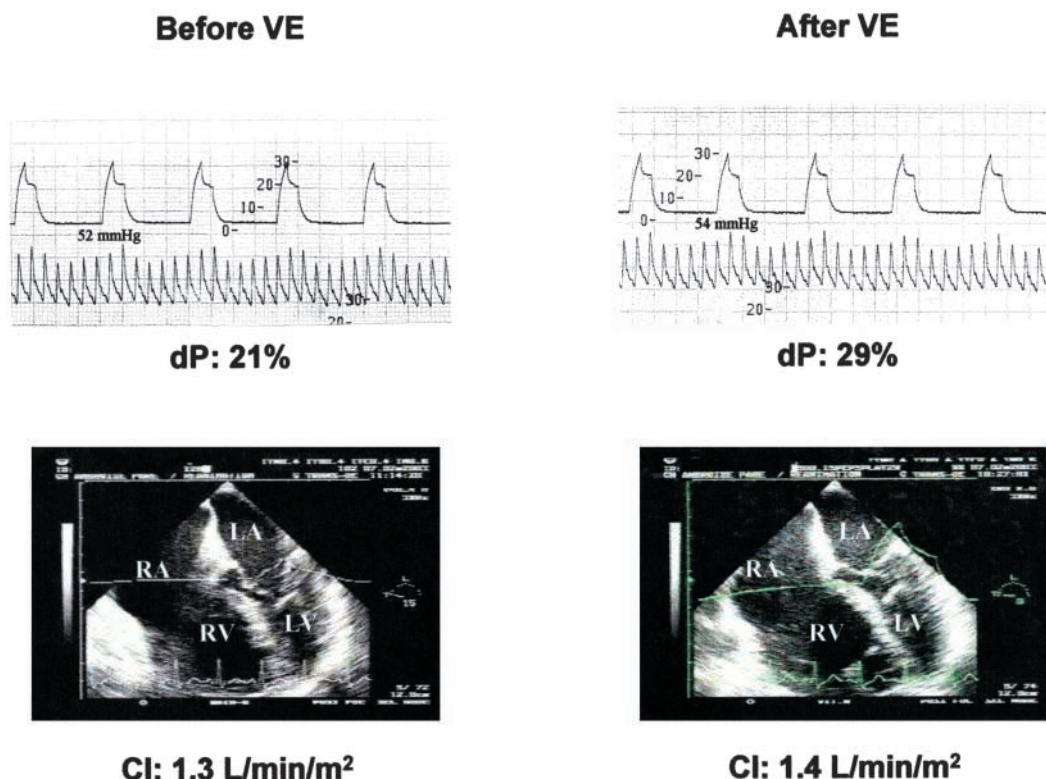
Definition of abbreviations: LVEDVi = left ventricular end-diastolic volume index; LVESVi = left ventricular end-systolic volume index.

\*References 12–14.

†Reference 15.

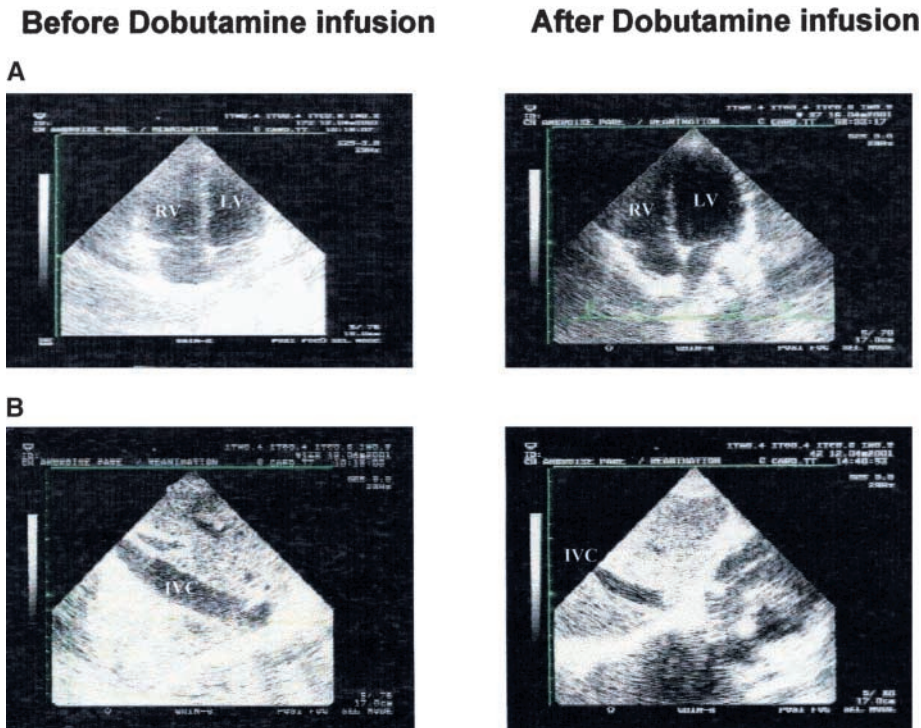
## THE RV IN SEPTIC SHOCK

As previously reported for the LV, RV dysfunction has also been demonstrated in septic shock, using radionuclide angiography (4, 30) or echocardiography (12). Its occurrence may explain in some patients the inability of blood volume expansion to improve clinical status and to increase  $\dot{Q}$ , whereas LV preload is markedly decreased (Figure 7) (31). In our most recent transesophageal echocardiographic study of 40 patients with septic shock (15), RV dysfunction was observed in 13 patients (32%), consistent with findings from our previous study using transthoracic echocardiography (12). RV dysfunction may be related not only to intrinsic depression in contractility producing hypokinesia (Figure 8, *see* Films 7A and 7B in the online supplement), as described for the LV, but also to acute cor pulmonale (32). Acute cor pulmonale is produced by an acute increase in pulmonary vascular resistance, combining, from an echocardiographic point of view, acute RV enlargement and septal dyskinesia (33). But this increase may be relative to the quality of the RV systolic



**Figure 7.** In this patient exhibiting a low arterial pressure and a major expiratory depression in arterial pulse (dP), in the context of bacterial pneumonia, Doppler echocardiographic examination revealed acute cor pulmonale, associated with a low Doppler cardiac index (CI). The SVC diameter (not shown in the figure) was uninfluenced by lung inflation, thus predicting the inefficiency of volume expansion (VE) in correcting both arterial pressure and CI. Conversely, a beneficial effect of VE on CI was expected from dP analysis, but this beneficial effect actually did not occur. Arterial pressure was restored by norepinephrine infusion (1  $\mu\text{g/kg/minute}$ , not shown in the figure). LA = left atrium; LV = left ventricle; RA = right atrium; RV = right ventricle.





**Figure 8.** In the same patient as in Figure 5A, exhibiting severe LV hypokinesia, initial trans-thoracic examination also revealed RV dilatation (left panel, top) and enlargement of the IVC (left panel, bottom). At this time, the patient complained of acute hepatic pain. This hepatic pain was relieved by dobutamine infusion, together with RV and vena caval enlargement (right panel). IVC = inferior vena cava.

function, and a minor rise in airway pressure, as produced by mechanical ventilation, may produce acute cor pulmonale when applied on a depressed RV. Severe RV dysfunction as a part of biventricular failure requires inotropic support, whereas preeminent RV dysfunction may be corrected by norepinephrine infusion (by way of restoring arterial pressure and coronary perfusion) (see Films 8A and 8B in the online supplement). Other specific therapies when acute cor pulmonale is present have extensively been described in a previous Clinical Commentary (34).

### Conclusions

By permitting successive inspection of the superior vena cava, the right and LV cavities, bedside echocardiography can identify the precise cause of hemodynamic instability in septic shock, which may be hypovolemic, cardiogenic, or distributive. This diagnosis is required for an adequate treatment, which may be rapid fluid administration, infusion of an inotropic agent, infusion of a vasoconstrictor agent, or various combinations of the above. Repeated bedside echocardiography can also assess the adequacy and efficacy of therapies implemented. A synthetic example is provided in Films 9A–9D in the online supplement.

**Conflict of Interest Statement:** A.V.B. has no declared conflict of interest; S.P. has no declared conflict of interest; K.C. has no declared conflict of interest; O.D. has no declared conflict of interest; F.J. has no declared conflict of interest.

**Acknowledgment:** The authors gratefully acknowledge Christian Brun-Buisson, M.D., for helping with the presentation of this manuscript.

### References

1. Rackow EC, Astiz ME. Mechanisms and management of septic shock. *Crit Care Clin* 1993;9:219–237.
2. Parker MM, Shelhamer JH, Bacharach, Green MV, Natanson C, Frederick TM, Damske BA, Parrillo JE. Profound but reversible myocardial depression in patients with septic shock. *Ann Intern Med* 1984;100:483–490.
3. Ozier Y, Gueret P, Jardin F, Farcot JC, Bourdarias JP, Margairaz A. Two-dimensional echocardiographic demonstration of acute myocardial depression in septic shock. *Crit Care Med* 1984;12:596–599.
4. Kimchi A, Ellrodt GA, Berman DS, Riedinger M, Riedinger MS, Swan HJC, Murata GH. Right ventricular performance in septic shock: a combined radionuclide and hemodynamic study. *J Am Coll Cardiol* 1984;4:945–951.
5. Groeneveld ABJ, Nauta JJ, Thijs L. Peripheral vascular resistance in septic shock: its relation to outcome. *Intensive Care Med* 1988;14:141–147.
6. Rivers E, Nguyen B, Havstad S, Ressler J, Muzzin A, Knoblich B, Peterson E, Tomlanovich M. Early-goal directed therapy in the treatment of severe sepsis and septic shock. *N Engl J Med* 2001;345:1368–1377.
7. Practice parameters for hemodynamic support of sepsis in adult patients in sepsis: Task Force of the American College of Critical Care Medicine, Society of Critical Care Medicine. *Crit Care Med* 1999;27:639–660.
8. Jardin F, Bourdarias JP. Right heart catheterization at bedside: a critical view. *Intensive Care Med* 1995;21:291–295.
9. Connors A, Speroff T, Dawson N, Thomas C, Harrell F, Wagner D, Desbien N, Goldman L, Wu A, Califf R, et al. The effectiveness of right heart catheterization in the initial care of critically ill patients. *JAMA* 1996;276:889–897.
10. Sandham J, Hull R, Brant R, Knox L, Pineau G, Doig C, Laporta D, Viner S, Passerini L, Devitt H, et al. A randomized, controlled trial of the use of pulmonary-artery catheters in high-risk surgical patients. *N Engl J Med* 2003;354:5–14.
11. Richard C, Warzawski J. French multicenter trial of efficacy and safety of pulmonary artery catheter in shock and/or ARDS: preliminary results. *Am J Respir Crit Care Med* 2002;165:A22.
12. Jardin F, Brun-Ney D, Auvert B, Beauchet A, Bourdarias JP. Sepsis-related cardiogenic shock. *Crit Care Med* 1990;18:1055–1060.
13. Jardin F, Valtier B, Beauchet A, Dubourg O, Bourdarias JP. Invasive monitoring combined with two-dimensional echocardiographic study in septic shock. *Intensive Care Med* 1994;20:550–554.
14. Jardin F, Fourme T, Page B, Loubières Y, Vieillard-Baron A, Beauchet A, Bourdarias JP. Persistent preload defect in severe sepsis despite fluid loading: a longitudinal echocardiographic study in patients with septic shock. *Chest* 1999;116:1354–1359.
15. Vieillard-Baron A, Schmitt JM, Beauchet A, Augarde R, Prin S, Page B, Jardin F. Early preload adaptation in septic shock? A transesophageal echocardiographic study. *Anesthesiology* 2001;94:400–406.
16. Vieillard-Baron A, Augarde R, Prin S, Page B, Beauchet A, Jardin F. Influence of superior vena caval zone conditions on cyclic changes in right ventricular outflow during respiratory support. *Anesthesiology* 2001;95:1083–1088.
17. Vieillard-Baron A, Chergui K, Augarde R, Prin S, Beauchet A, Jardin

- F. Cyclic changes in arterial pulse during respiratory support revisited by Doppler echocardiography. *Am J Respir Crit Care Med* 2003;168:671-676.
18. Marakawa K, Kobayashi A. Effect of vasopressors on renal tissue gas tensions during hemorrhagic shock in dogs. *Crit Care Med* 1988;16:789-792.
19. Michard F, Boussat S, Chemla D, Anguel N, Mercat A, Lecarpentier Y, Richard C, Pinsky M, Teboul JL. Relation between respiratory changes in arterial pulse pressure and fluid responsiveness in septic patients with acute circulatory failure. *Am J Respir Crit Care Med* 2000;162:134-138.
20. Tavernier B, Makhotine O, Lebuffe G, Dupont J, Scherpereel P. Systolic pressure variation as a guide to fluid therapy in patients with sepsis-induced hypotension. *Anesthesiology* 1998;89:1313-1321.
21. Winslow E, Loeb H, Rahimtoola S, Kamath S, Gunnar R. Hemodynamic studies and results of therapy in 50 patients with bacteremic shock. *Am J Med* 1972;54:421.
22. Parrillo J. Pathogenetic mechanisms of septic shock. *N Engl J Med* 1993;328:1471-1477.
23. Robotham J, Takata M, Berman M, Harasawa Y. Ejection fraction revisited. *Anesthesiology* 1991;74:172-183.
24. Dellinger P. Cardiovascular management of septic shock. *Crit Care Med* 2003;31:946-955.
25. Jardin F, Sportiche M, Bazin M, Bourokba A, Margairaz A. Dobutamine: a hemodynamic evaluation in septic shock. *Crit Care Med* 1981;9:329-332.
26. Parker M, Shelhamer J, Natanson C, Allig D, Parrillo J. Serial cardiovascular variables in survivors and nonsurvivors of human septic shock: heart rate as an early predictor of prognosis. *Crit Care Med* 1987;15:923-929.
27. Van Grondelle A, Ditchey R, Groves B, Wagner W, Reeves J. Thermolite method overestimates low cardiac output in humans. *Am J Physiol* 1983;245:H690-H692.
28. Martin C, Viviani X, Leone M, Thirion X. Effect of norepinephrine on the outcome of septic shock. *Crit Care Med* 2000;28:2758-2765.
29. Abid O, Akça S, Haji-Michael P, Vincent JL. Strong vasopressor support may be futile in the intensive care unit patient with multiple organ failure. *Crit Care Med* 2000;28:947-949.
30. Parker M, McCarty K, Ognibene F, Parillo J. Right ventricular dysfunction, similar to left ventricular changes, characterize the cardiac depression of septic shock in humans. *Chest* 1990;97:126-131.
31. Schneider A, Teule G, Groeneveld A, Nauta J, Heidendal G, Thijs L. Biventricular performance during volume loading in patients with early septic shock, with emphasis on the right ventricle: a combined hemodynamic and radionuclide study. *Am Heart J* 1988;116:103-112.
32. Vieillard-Baron A, Schmitt JM, Augarde R, Fellahi JL, Prin, Page B, Beauchet A, Jardin F. Acute cor pulmonale in ARDS submitted to protective ventilation: incidence, clinical implications and prognosis. *Crit Care Med* 2001;29:1551-1555.
33. Jardin F, Dubourg O, Bourdarias JP. Echocardiographic pattern of acute cor pulmonale. *Chest* 1997;111:209-217.
34. Vieillard-Baron A, Prin S, Chergui K, Dubourg O, Jardin F. Echo-Doppler demonstration of acute cor pulmonale at the bedside in the medical intensive care. *Am J Respir Crit Care Med* 2002;166:1310-1319