



Expert Statements on the Standard of Care in Critically Ill Adult Patients With Atypical Hemolytic Uremic Syndrome

Elie Azoulay, MD, PhD; Paul Knoebl, MD; José Garnacho-Montero, MD, PhD; Katerina Rusinova, MD, PhD; Gennadii Galstian, MD, PhD; Philippe Eggimann, MD, PhD; Fekri Abroug, MD, PhD; Dominique Benoit, MD, PhD; Michael von Bergwelt-Baildon, MD, PhD; Julia Wendon, MD; and Marie Scully, MD

A typical hemolytic uremic syndrome (aHUS) presents similarly to thrombotic thrombocytopenic purpura (TTP) and other causes or conditions with thrombotic microangiopathy (TMA), such as disseminated intravascular coagulation or sepsis. Similarity in clinical presentation may hinder diagnosis and optimal treatment selection in the urgent setting in the ICU. However, there is currently no consensus on the diagnosis or treatment of aHUS for ICU specialists. This review aims to summarize available data on the diagnosis and treatment strategies of aHUS in the ICU to enhance the understanding of aHUS diagnosis and outcomes in patients managed in the ICU. To this end, a review of the recent literature (January 2009-March 2016) was performed to select the most relevant articles for ICU physicians. Based on the paucity of adult aHUS cases overall and within the ICU, no specific recommendations could be formally graded for the critical care setting. However, we recognize a core set of skills required by intensivists for diagnosing and managing patients with aHUS: recognizing thrombotic microangiopathies, differentiating aHUS from related conditions, recognizing involvement of other organ systems, understanding the pathophysiology of aHUS, knowing the diagnostic workup and relevant outcomes in critically ill patients with aHUS, and knowing the standard of care for patients with aHUS based on available data and guidelines. In conclusion, managing critically ill patients with aHUS requires basic skills that, in the absence of sufficient data from patients treated within the ICU, can be gleaned from an increasingly relevant literature outside the ICU. More data on critically ill patients with aHUS are needed to validate these conclusions within the ICU setting. CHEST 2017; 152(2):424-434

KEY WORDS: atypical hemolytic uremic syndrome; eculizumab; intensive care; organ failure; plasma exchange; thrombocytopenia; thrombotic microangiopathy

ABBREVIATIONS: aHUS = atypical hemolytic uremic syndrome; C3 = complement component 3; HUS = hemolytic uremic syndrome; STEC = Shiga toxin-producing *Escherichia coli*; STEC-HUS = Shiga toxin-associated hemolytic uremic syndrome; TMA = thrombotic microangiopathy; TTP = thrombotic thrombocytopenic purpura

AFFILIATIONS: From the Medical Intensive Care Unit (Dr Azoulay), Hôpital Saint-Louis, Paris, France; the Medical University of Vienna (Dr Knoebl), Vienna General Hospital, Vienna, Austria; the Virgen de Macarena University Hospital (Dr Garnacho-Montero), Seville, Spain; the University Hospital, 1st Faculty of Medicine (Dr Rusinova), Charles University, Prague, Czech Republic; the National Research Center for Hematology (Dr Galstian), Russia; the University Hospital of Lausanne (Dr Eggimann), Lausanne, Switzerland; the Fattouma Bourguiba Teaching Hospital Monastir (Dr Abroug), Tunisia; the Ghent University Hospital (Dr Benoit), Ghent, Belgium; the Uniklinik (Dr von

Bergwelt-Baildon), Cologne, Germany; the King's College Hospital (Dr Wendon), London, England; and the University College London (Dr Scully), London, England.

CORRESPONDENCE TO: Elie Azoulay, MD, PhD, Medical Intensive Care Unit, Hôpital Saint-Louis, ECSTRA team, Biostatistics and Clinical Epidemiology, UMR 1153 (Center of Epidemiology and Biostatistics, Sorbonne Paris Cité, CRESS), INSERM, Paris Diderot Sorbonne University, 1 Ave Claude Vellefaux, 75010 Paris, France; e-mail: elie.azoulay@sls.aphp.fr

Copyright © 2017 The Authors. Published by Elsevier Inc under license from the American College of Chest Physicians. This is an open access article under the CC BY-NC-ND license (<http://creativecommons.org/licenses/by-nc-nd/4.0/>).

DOI: <http://dx.doi.org/10.1016/j.chest.2017.03.055>

Thrombotic microangiopathies (TMAs) are a group of disorders characterized by **thrombocytopenia**, **microangiopathic hemolytic anemia**, and **organ dysfunction**, in which **ischemic organ** injury can occur to the brain, kidneys, heart, pancreas, liver, lungs, eyes, and skin. Conditions occurring with TMAs include **hemolytic uremic syndromes (HUSs)** and **thrombotic thrombocytopenic purpura (TTP)**, and a number of differential diagnoses that must also be excluded (Fig 1).¹ These conditions have a **similar clinical presentation** of **consumptive thrombocytopenia**, **mechanical hemolysis**, and organ failure, but with distinct causes, and are typically associated with thickening and **inflammation of arterioles** and capillaries, detachment and swelling of endothelial cells, subendothelial widening, accumulation of proteins and cellular debris, or **platelet thrombi** that obstruct the vascular lumen.^{1,2}

Herein, we will **focus on one of these conditions, atypical hemolytic uremic syndrome (aHUS)**. aHUS is a rare but life-threatening condition that affects both children and

adults. It accounts for approximately 10% of cases of HUS in children, but **most HUS cases in adults**.³ The annual incidence of aHUS is thought to be around 1 to 2 **per million** in adults⁴; however, epidemiologic data are limited.⁵ aHUS is **distinct** from typical, or **diarrhea-associated, HUS**, now commonly called **Shiga toxin-associated hemolytic uremic syndrome (STEC-HUS)**, which is typically caused by **Shiga toxin** because of **bacterial infection** and often associated with **bloody diarrhea**. In most cases, **aHUS** is caused by the **uncontrolled activation of the complement system**, which leads to platelet, leucocyte, and endothelial cell activation and TMA,^{1,6-8} ultimately causing **thrombosis** and **organ dysfunction**.^{8,9} Accordingly, it may be **unmasked** by conditions with **enhanced complement activation**, such as **systemic lupus erythematosus**, **pregnancy**, **malignant hypertension**, and **hematopoietic stem cell transplantation**.

Genetic abnormalities have been found in approximately 50% to 70% of patients with aHUS,^{4,10} and a wide variety of mutations are associated with the condition.^{4,8}

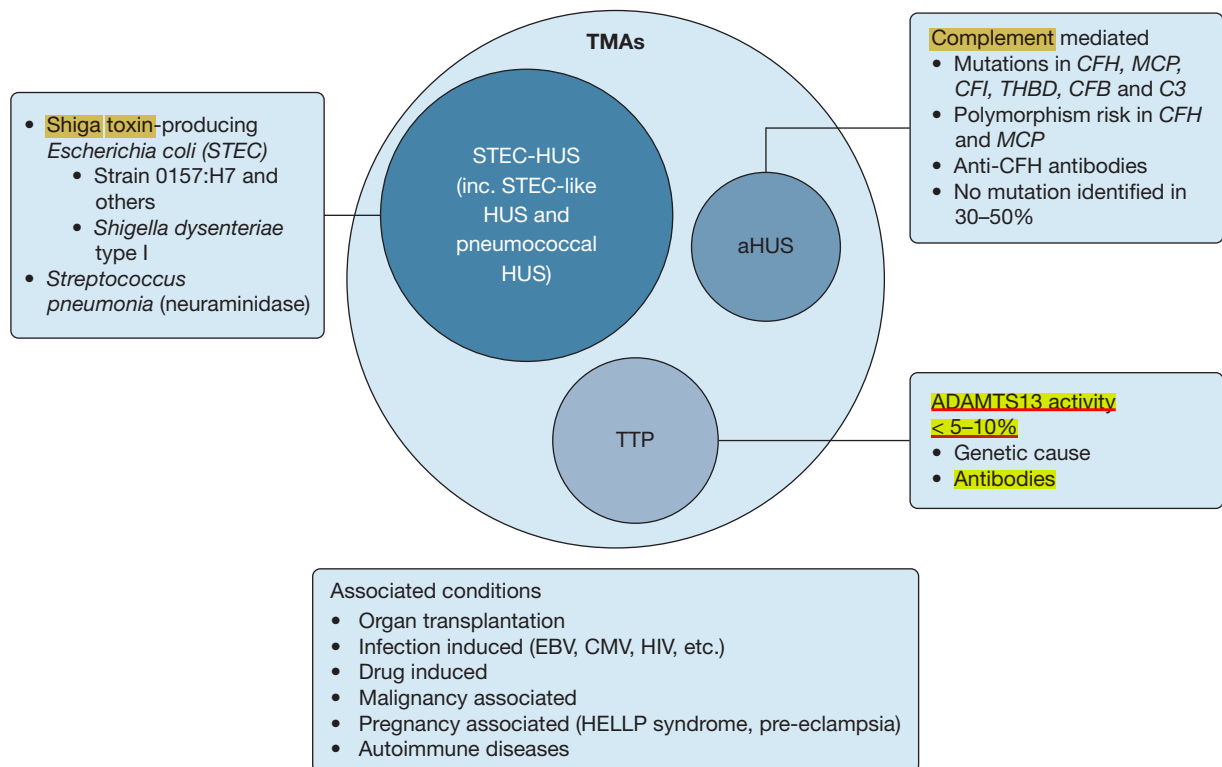


Figure 1 – **Pathophysiology of TMAs**.¹ **ADAMTS13 = a disintegrin and metalloproteinase with thrombospondin motifs 13**; aHUS = atypical hemolytic uremic syndrome; C3 = complement component 3; CMV = cytomegalovirus; EBV = Epstein-Barr virus; FB = complement factor B; FH = complement factor H; FI = complement factor I; HELLP = hemolysis, elevated liver enzymes, low platelet count; HUS = hemolytic uremic syndrome; inc. = including; MCP = membrane cofactor protein; STEC = Shiga toxin-producing Escherichia coli; STEC-HUS = Shiga toxin-associated hemolytic uremic syndrome; THBD = thrombomodulin; TMA = thrombotic microangiopathy; TTP = thrombotic thrombocytopenic purpura.

Although gene mutations increase the risk of aHUS, they may not be sufficient to cause overt symptoms without additional **environmental triggers**. These include **infections, pregnancy, certain medications, malignancy, sepsis, bone marrow transplantation, and connective tissue disorders**.^{2,9,11} Consequently, genetic testing is currently not useful for the acute diagnosis of aHUS (eg, in the ICU setting), but it can provide diagnostic confirmation, prognostic value, and information on long-term treatment. Furthermore, because of the severe nature of the condition, the time delay in obtaining genetic results is not consistent with the need for rapid initiation of therapy. In the absence of any fast, specific diagnostic tests for aHUS, the **condition can only be diagnosed** after **exclusion of TTP¹²** and **related TMAs**.

Previously, aHUS and TTP have been managed in the same way because the conditions are difficult to differentiate and only one treatment option, plasma therapy (**plasma infusion or plasma exchange**), was available.^{1,4} The **benefits of plasma exchange**, although not evaluated in prospective studies, include the **removal of pathologic substances from the blood and the replacement of deficient plasma components**.¹³ However, although plasma therapy has **improved outcomes** considerably in TTP, **reducing the mortality rate from 90% to 10% to 20%,¹⁴** > 50% of patients with aHUS proceed to end-stage **renal disease or death despite plasma therapy**.^{8,12} Consequently, **specific, urgent, and interdisciplinary management is paramount in the treatment of patients with aHUS** because of both the **severity of the illness and the potential development of irreversible complications** of organ involvement.¹ **Eculizumab**, approved in 2011, is the first treatment for aHUS with proven efficacy and safety in prospective clinical trials.⁶ This monoclonal **antibody targets the complement system** by blocking the cleavage of **C5**, avoiding the production of cleavage products C5a and C5b¹⁵; evidence suggests that early initiation can improve renal and nonrenal recovery.^{16,17}

In many cases, the ICU is the only clinical environment in which such specialized urgent care can be effectively provided at any time. Based on our experience, physicians in the ICU see an average of three patients with TMA per year, many of whom are not diagnosed at the time of admission. Although treatment guidelines for aHUS are available for nephrology,^{14,18–20} there is currently no consensus on the diagnosis or treatment of aHUS for ICU specialists. This review aims to summarize available data on the diagnosis and treatment of aHUS in the ICU with the goal of enhancing the

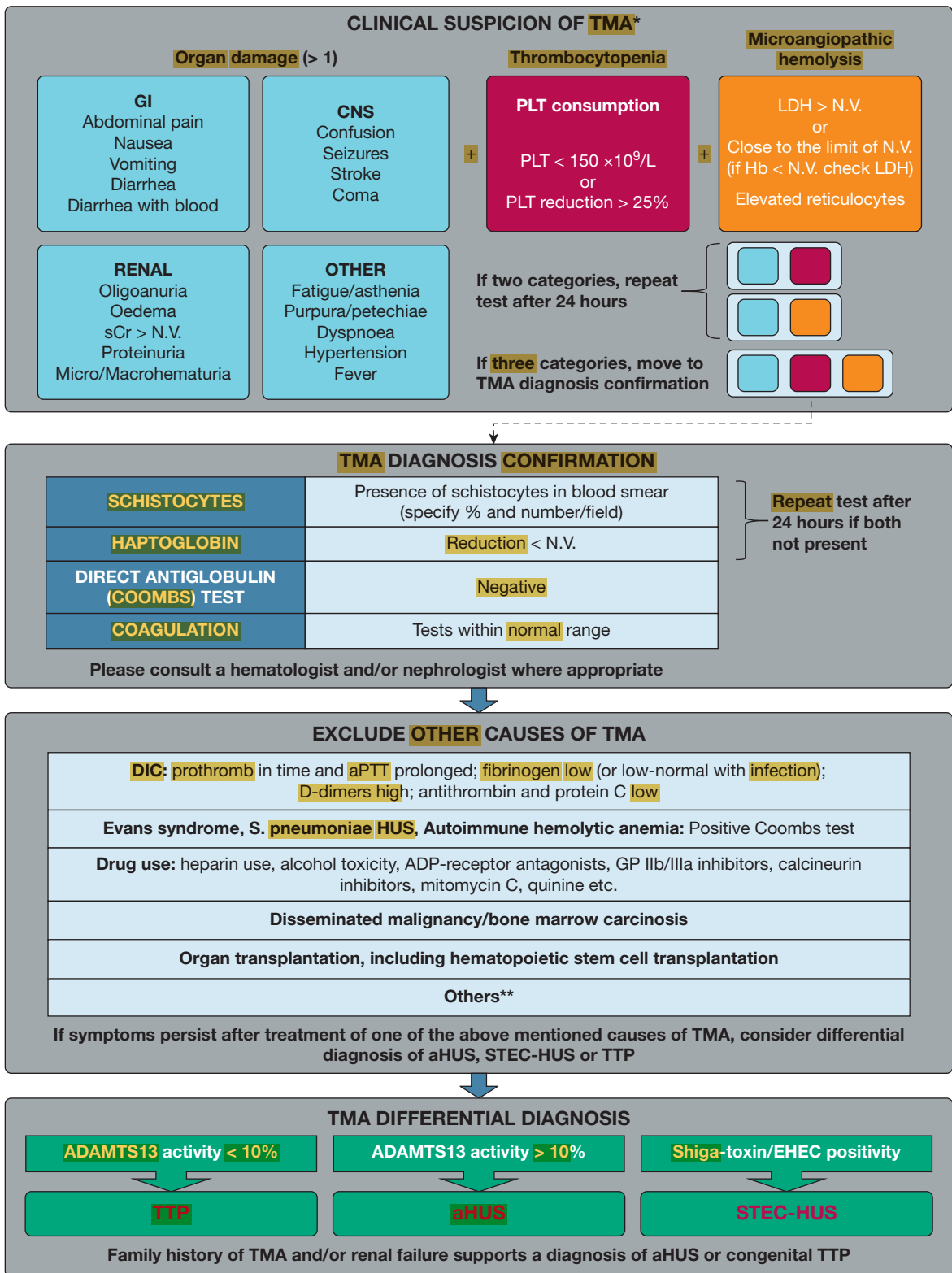
understanding of aHUS diagnosis and outcomes in patients managed in the ICU.

Research Design and Methods

The need for this article was identified by a multidisciplinary multinational expert panel of 11 members (nine intensive care physicians and two hematologists) who met in September 2015 to define unmet needs and skill priorities for ICU clinicians managing critically ill patients with aHUS and to evaluate existing recommendations outside critical care. A literature search was conducted in the National Library of Medicine database (PubMed) looking for articles published between January 2009 and March 2016, using the following search terms: “atypical haemolytic uraemic syndrome” or “atypical hemolytic uremic syndrome” or “diarrhoea negative haemolytic uraemic syndrome” or “diarrhea negative hemolytic uremic syndrome” or “aHUS” or “D-HUS,” with search filters of “humans” and “English language.” Additional relevant articles were also included from Internet searches using the same search terms. Articles were reviewed manually for relevance by the authors; studies concerning both transplant and native kidney patients with aHUS were permitted in this study, as were systematic literature reviews and specialist review articles. In total, 539 articles were identified, of which 56 were considered relevant (included diagnosis and/or treatment of adult patients with aHUS).

Diagnosis of Patients With aHUS

Diagnosis of aHUS typically **commences with the broad diagnosis of TMA (Fig 2, Table 1)^{21–24}** and implicates the involvement of not only the ICU physician but also other specialists, notably hematologists and nephrologists. Clinical suspicion of a TMA is based on **clinical findings, including microangiopathic hemolytic anemia, thrombocytopenia, low haptoglobin, elevated lactate dehydrogenase, elevated reticulocytes, fragmented red cells, and schistocytes** on peripheral blood **smear**. Acute **kidney injury** is common in aHUS, but other **organ involvement, including cardiac, gastrointestinal, or neurological damage, may be present and can dominate the clinical picture^{1,5,25–28}** (Fig 2, Table 1). Once suspicion of TMA has been established, further investigations, including a full patient medical and family history, are required to **exclude other potential causes of TMA, including TTP, STEC-HUS, or TMA as a transient manifestation of another condition (eg, malignancy, autoimmune disease) or**



RENAL

Oligoanuria
Oedema
sCr > N.V.
Proteinuria
Micro/Macrohematuria

OTHER

Fatigue/asthenia
Purpura/petechiae
Dyspnoea
Hypertension
Fever

If two categories, repeat test after 24 hours

If three categories, move to TMA diagnosis confirmation

Figure 2 – Algorithm for the differential diagnosis of aHUS in the ICU.^{1,12,14,21-24} *If two categories of clinical findings are present (organ damage and/or thrombocytopenia and/or microangiopathic hemolysis), repeat tests after 24 hours. If three categories of clinical findings are present, move to TMA diagnosis confirmation. **Includes acute viremia (CMV, HIV, or EBV), pregnancy-associated complications (HELLP or preeclampsia), malignant hypertension, catastrophic antiphospholipid antibody syndrome, and severe systemic autoimmune diseases. This list is not exhaustive. ADP = adenosine diphosphate; aPTT= activated partial thromboplastin time; CNS = central nervous system; DIC = disseminated intravascular coagulation; EHEC = enterohemorrhagic Escherichia coli; GI = gastrointestinal; GP = glycoprotein; Hb = hemoglobin; LDH, = lactate dehydrogenase; N.V. = normal value; PLT = platelet; sCr = serum creatinine. See Figure 1 legend for expansion of other abbreviations.

TABLE 1] Recommended Tests for the Differential Diagnosis of aHUS^{1,12,14,21-24}

Identify TMA		
Test	Outcome in aHUS	Alternative Diagnosis
Reticulocyte counts	Increased	
Free serum hemoglobin	Increased	
LDH	Increased	
Haptoglobin	Decreased	Often decreased in TMA s, normal in DIC and sepsis
Schistocytes	Present	Can be present in all TMA
Platelet count	Decreased (most of the time)	Can be reduced in all TMA
Hemoglobin	Decreased	Can be decreased in all TMA
Serum creatinine	Increased (most of the time)	Can be increased in all TMA
Hematuria and proteinuria	Present (most of the time)	Can be present in all TMA
Kidney biopsy ^a	Often arteriolar and/or glomerular intracapillary thrombosis if kidney affected	
Additional tests to perform to advise on other possible causes of TMA		
Direct antiglobulin test (Coombs test)	Negative	Positive in autoimmune hemolytic anemias , Evans syndrome, and pneumococcal HUS
Fibrinogen	Normal	Reduced fibrinogen and elevated fibrinogen degradation products in DIC
aPTT, PT	Normal	Prolonged in DIC
Plasma coagulation tests	Normal	Reduced in DIC
D-dimer	Normal (can be elevated)	Elevated D-dimer in DIC or TMA
Liver enzyme levels	Normal (can be elevated if liver is involved)	Elevated in HELLP syndrome
Viral infections, including HIV, HBV, HCV, and H1N1	Can be a precipitant of aHUS	Known external precipitant of TMA
Pregnancy test (where appropriate)	Pregnancy-triggered TMA caused by aHUS usually presents in late pregnancy or postpartum	Pregnancy-triggered TMA caused by TTP usually presents during pregnancy
Antibody testing, including antinuclear antibody, lupus anticoagulant, and antiphospholipid antibodies	Negative	Positive in systemic diseases, such as SLE, CAPS; 30% of TTP have positive antinuclear antibodies
Rule out TTP and STEC-HUS		
STEC infection: fecal sample or rectal swab test for Escherichia coli and/or PCR for Shiga toxin, and serology of LPS of common Shiga toxin-producing strains	Negative	Positive in STEC-HUS
ADAMTS13	> 10% activity	< 10% activity in TTP

This is not an exhaustive list, but a suggestion. Further tests for conditions that can mimic TMA, such as malaria, babesiosis, and vitamin deficiency, may be warranted. ADAMTS13 = a disintegrin and metalloproteinase with thrombospondin motifs 13; aHUS = atypical hemolytic uremic syndrome; aPTT = activated partial thromboplastin time; CAPS = cryopyrin-associated autoinflammatory syndrome; DIC = disseminated intravascular coagulation; HBV = hepatitis B virus; HCV = hepatitis C virus; HELLP = hemolysis, elevated liver enzymes, low platelet count; HUS = hemolytic uremic syndrome; LDH = lactate dehydrogenase; LPS = lipopolysaccharide; PCR = polymerase chain reaction; PT = prothrombin time; SLE = systemic lupus erythematosus; STEC = Shiga toxin-producing *Escherichia coli*; STEC-HUS = Shiga toxin-associated hemolytic uremic syndrome; TMA = thrombotic microangiopathy; TTP = thrombotic thrombocytopenic purpura.

^aKidney biopsies are rarely performed because little information can be obtained above that from laboratory results; kidney biopsy in critically ill patients with low platelet counts should not be performed because of bleeding risk.

adverse drug effect; however, identification of one of these modulating factors does not preclude development of aHUS in individuals with a genetic predisposition.

Additionally, an **HIV** test and a **pregnancy** test in women of child-bearing age should be performed to account for these **potential triggers**.²¹

Differential Diagnosis

Distinguishing aHUS From TTP: ADAMTS13

Activity: The most critical and urgent differential diagnosis is to differentiate TTP from aHUS because of the urgency of specific treatment. Testing for ADAMTS13 (a disintegrin and metalloproteinase with thrombospondin motifs 13) activity is recommended to differentiate between TTP and aHUS,²⁷ and sampling must take place prior to administration of plasma therapy. ADAMTS13 deficiency is characteristic of TTP, with levels < 10% widely considered to be diagnostic for the condition.^{12,14,27,29-32} ADAMTS13, also known as von Wilbrand Factor cleavage protease, acts by cleavage of von Wilbrand Factor into smaller, less thrombotic fragments, thereby reducing platelet aggregation. Conversely, in TTP, reduced activity of ADAMTS13 results in platelet hyperadhesiveness and clumping within the microvasculature.^{27,33}

Somewhat reduced ADAMTS13 activity levels (> 10% of normal) may also occur in aHUS, but such levels are sufficient to exclude TTP. Although results from the ADAMTS13 assay are typically available within a few hours when the assay is established in the local laboratory, they may take some additional days when the sample has to be shipped, meaning that treatment decisions may need to be made prior to receiving the results of the test. If ADAMTS13 tests are not available within a few hours, a diagnostic algorithm developed by Coppo et al,³⁴ in which TTP is suggested by low platelet count (< 30 × 10⁹/L), mildly elevated serum creatinine (≤ 200 μmol/L), and detectable antinuclear antibodies, could help form an initial differential diagnosis. In the interim, until TTP has been excluded, patients should receive plasma exchange.

Organ Involvement: The presence of associated organ involvement may be included within the diagnostic workup to provide evidence for differentiation of aHUS from TTP, but it is not conclusive. Renal impairment is the most common complication in aHUS (Fig 3), but renal function may be preserved in up to 20% of cases. Acute kidney injury may be seen in TTP, but it is typically reversible with therapy.³⁵ The need for renal support, such as hemodialysis, is not a common feature of TTP, but it can be seen in progressive disease with multiorgan involvement.

Neurologic signs (eg, confusion, focal cerebral abnormalities, seizures) and cardiovascular signs (eg, cardiomyopathy, myocardial infarction, myocarditis, heart failure) occur in 10% to 48% and 10% of aHUS cases,

respectively⁹; however, these signs tend to be more frequent in TTP.^{14,36} Tsai³⁷ reported that complications of abnormal vascular permeability (including brain edema, pleural or pericardial effusions, pulmonary edema from oliguria or cardiac insufficiency, and ascites) may be used to differentiate TTP from aHUS because they are thought to occur rarely in TTP without comorbidity. aHUS is also occasionally associated with large artery obstruction.³⁸ Arterial hypertension may be present, whereas pulmonary involvement is frequent in untreated aHUS but rarely associated with other TMAs.²⁷

Complement Protein-Level Testing: Complement factor testing for complement component 3 (C3) and complement component 4, complement factor H, complement factor I, and antibodies against complement components can detect protein deficiencies caused by genetic mutations but cannot differentiate between normal protein and normal levels of functionally ineffective protein.³¹ Complement component 4 levels are usually normal, but C3 levels are low (normal range, 88-252 mg/dL in men and 88-206 mg/dL in women³⁹) in up to 40% of patients with aHUS.^{26,40} Many functional complement tests are very sensitive to preanalytical errors. Therefore, complement testing may help to confirm suspected aHUS, but it is not useful as a diagnostic test by itself.

Genetic Testing: Genetic abnormalities in the complement system proteins have been documented,⁴¹ and assessment of these mutations may be used to confirm a diagnosis. Mutations in complement factor H account for approximately 25% of aHUS cases, membrane cofactor protein for approximately 10%, complement factor I for 5% to 10%, and thrombomodulin for up to 5% of cases⁴²; however, no known mutations are identified in 30% to 50% of patients.^{4,10} Other genetic variants include gain-of-function mutations in the genes coding for complement factor B and C3, and anticomplement factor H antibodies associated with homozygous complement factor H-related 1-3 deletion.^{4,8} The parameters associated with clinical aHUS onset are yet to be wholly elucidated. The current hypothesis is a two-hit model: (1) preexisting genetic susceptibility factors that are capable of stimulating endothelial cell activation/damage and/or platelet aggregation; and (2) modulating factors, encompassing a variety of conditions that can be infectious, inflammatory, or related to pregnancy, drugs, or stress and are linked epidemiologically to both TTP and aHUS.²⁷ Mutations confer a genetic predisposition; therefore, although a positive result is compatible with the diagnosis, a negative

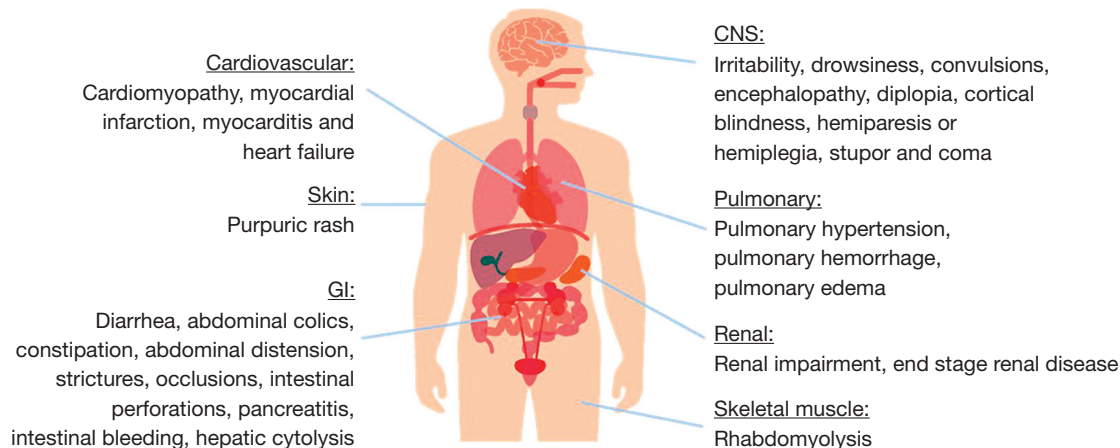


Figure 3 – Frequency of organ involvement in atypical hemolytic uremic syndrome.⁹ See Figure 2 legend for expansion of abbreviations.

result does not necessarily exclude aHUS. Additionally, the results from such tests may take weeks, which is not compatible with the urgent care setting of the ICU, where rapid treatment decisions and administration of urgent therapy are necessities.

Distinguishing aHUS From STEC-HUS and Pneumococcal HUS

Culture-based assays (serology or polymerase chain reaction) for Shiga toxin-producing *Escherichia coli* (STEC), using a stool or rectal swab, in patients with diarrhea can diagnose STEC-HUS and clearly differentiate it from aHUS. Although *E coli* is not the only source of Shiga toxin, STEC-HUS, previously referred to as typical HUS or diarrhea-positive HUS, is the most commonly used terminology today and is used here to refer to this subset of HUS. The presence of diarrhea alone has been used in the past to differentiate between the conditions; however, this cannot be relied on because up to one-third of aHUS cases also involve diarrhea; therefore, so the presence of Shiga toxin must be analyzed in patients with diarrhea.²⁷ Pneumococcal HUS is linked to the evidence of invasive pneumococcal infection. Bacterial culture from sterile bodily fluids is required for confirmation of pneumococcal infection, and pneumococcal HUS is—in contrast with aHUS and TTP—often associated with a positive Coombs test.²¹

Further Tests to Consider in the Workup of a Patient Presenting With TMA

Patients presenting with TMA may require further testing to rule out additional associated conditions. Disseminated intravascular coagulopathy and sepsis may present with TMA features but can be ruled out by measuring coagulation parameters, which are all normal

in aHUS and TTP.¹⁴ Pregnancy can result in complications of TMAs; TMA often leads to fetal death, and TMA therapy may have an influence on the fetus. Therefore, a pregnancy test should be performed in women of childbearing age.²² Viral infections, including HIV, hepatitis B virus, hepatitis C virus, cytomegalovirus, and Epstein-Barr virus, can also cause TMA and therefore must be investigated.^{1,22} Serology tests, such as antinuclear antibodies and anti-DNA-antibodies to neutrophil cytoplasmic antigens, must be considered to rule out systemic diseases,¹ and basal organ testing, including a brain and lung CT scan, troponin levels, blood glucose levels, and serum lipase levels, is also recommended.²² Although a negative direct antiglobulin test (Coombs test) can confirm TMA, a positive result may be indicative of autoimmune hemolytic anemia, Evans syndrome (when in conjunction with immune-mediated thrombocytopenia), or pneumococcal HUS. A full medical history should be acquired to determine underlying conditions, such as malignancies and drug- or medication-associated TMAs,^{1,22} for example heparin-induced thrombocytopenia.⁴³ Family history of TMA or renal injury should also be evaluated considering the important genetic component of aHUS.

Diagnosing aHUS in the ICU Setting

Data on the clinical presentation and diagnosis of aHUS, particularly in the ICU setting, are limited by the small number of patients with this condition reported in the ICU literature.³¹ Furthermore, findings relating to aHUS are mostly published in nephrology and hematology journals, with limited reach to the ICU specialist. An industry-supported global aHUS registry was initiated in 2012, and data on the baseline demographics and

clinical characteristics of 516 patients with aHUS were recently published.⁴⁴

A review of the available case studies relevant to the ICU setting revealed that the initial diagnostic workup was similar for all patients, regardless of the presenting symptoms. It is notable that a variety of approaches were taken for progression beyond the TMA diagnosis, with most patients receiving initial plasma exchange while undergoing further investigations, including ADAMTS13 activity, Shiga toxin testing, kidney biopsy if feasible in critically ill patients, and genetic screening. Together, information from these case studies can inform an appropriate workup relevant to patients presenting with aHUS symptoms within the ICU. A summary of the key considerations for the differential diagnosis of aHUS in the ICU setting is presented in [Table 2](#).

Treatment of Patients With aHUS in the ICU

Knowing the standard of care for patients with aHUS, based on available guidelines and expert suggestions on best practice in the treatment of critically ill patients with aHUS, is a skill we consider necessary within the ICU. No published guidelines or recommendations focus on the management of patients in the ICU; however, there are no differences in treatment requirements between settings, and published treatment guidelines from other clinical settings apply.

TABLE 2] Key Considerations for Differential Diagnosis of aHUS in the ICU

1. Microangiopathic hemolytic anemia, thrombocytopenia, and organ impairment should be recognized as being suggestive of TMA.
2. A full medical history should be taken to exclude or identify other causes (eg, previous TMA episodes, pregnancy, prior malignancies, drug use).
3. Disseminated intravascular coagulation and sepsis should be ruled out by clinical picture, microbiologic testing, and assessment of coagulation screen.
4. TTP and STEC-HUS should be ruled out with ADAMTS13 activity (before initiation of plasma therapy) and Shiga toxin tests; if ADAMTS13 activity test is not available, the Coppo algorithm ³¹ to assess serum creatinine and platelet count may be considered.
5. If TMA persists on specific treatment of associated condition (Fig 1), differential diagnosis for aHUS should be considered.

See [Table 1](#) legend for expansion of abbreviations.

Immediate ICU Management

The critical nature of acute TMA means that a high proportion of patients may be admitted to the ICU at presentation. Because of the severity of the progression of aHUS and other TMAs, a suspected diagnosis should be treated as a medical emergency, and initial supportive measures should be introduced with urgency. The British Committee for Standards in Haematology guidelines¹⁴ suggest that appropriate treatment should be initiated within 4 to 8 h from diagnosis because delays are associated with increased morbidity and mortality.

Although plasma exchange has greatly improved the survival of patients with TTP,¹² it is not considered the most effective therapy for aHUS because most patients will die or require long-term renal replacement therapy despite this treatment.^{4,12,40} However, because of the difficulty in differentiating between aHUS and TTP, initiation of plasma exchange is often necessary while laboratory results are being determined.⁴⁵ Exceptions include patients with metastatic cancer with bone marrow involvement for which plasma exchange would not improve the situation. Plasma exchange requires careful monitoring of organ function, platelet counts, and the presence of infections, which can arise from central venous lines and other sources related to medical interventions. Platelet concentrates should be avoided during initial therapy because they may aggravate platelet aggregation.²²

Specific Management of aHUS

Once ADAMTS13 is proven detectable (> 10% activity), the probability of a diagnosis of aHUS is high, and more specific therapy can be applied. This can be confirmed with a negative test for STEC, once laboratory results have been received. Treatment options for aHUS were limited to plasma exchange, dialysis for renal failure, and kidney transplantation until 2011, when eculizumab, a recombinant, humanized, monoclonal antibody was approved for use in patients with aHUS.^{12,45} Eculizumab selectively targets and inhibits the terminal complement protein C5, thereby inhibiting the terminal complement activation.⁴⁶

Eculizumab has been demonstrated to be effective and well tolerated in four prospective phase II trials in patients with aHUS.⁴⁶⁻⁴⁹ These trials were however not carried out in the critical care setting. In these trials, terminal complement inhibition with eculizumab was associated with inhibition of further TMA progression, increased platelet count, and significant improvement in renal function, including discontinuation of dialysis in

80% of patients on dialysis at initiation of treatment and prevention of recurrence after transplantation.⁶ Based on these results, eculizumab was included in a 2015 update to the clinical guidelines¹ and in an international consensus for the treatment of aHUS in children in 2016.¹⁹ In addition, a number of reviews on the management of patients with aHUS recommend the use of eculizumab.^{14,20,21,31,45,50,51} However, eculizumab is contraindicated in patients with unresolved neisserial infection (eg, *Neisseria meningitidis*) and in unvaccinated individuals because of the role of terminal complement in the prevention of neisserial infection, unless the benefits of treatment outweigh the risks of contracting the infection.⁵² Vaccination against *N meningitidis* serotypes A, C, Y, and W135 and meningococcus type B should be administered at least 2 weeks prior to initiation of eculizumab. If eculizumab treatment needs to be initiated immediately in a critically ill patient, prophylactic antibiotics should be given at the start of therapy and maintained for a minimum of 2 weeks⁵³ or as specified in individual country guidelines.

Management should also include supportive measures aimed at managing the risks and consequences of aHUS, such as hypertension, anemia, thrombocytopenia, acute renal failure, and infections, particularly in patients not receiving specific targeted treatment (eg, eculizumab). Hypertension is common in patients presenting with aHUS and should be managed with appropriate medications (angiotensin converting enzyme inhibitors or angiotensin receptor blockers), and red blood cell transfusion may be considered for patients with anemia, noting that platelet infusions are contraindicated unless the patient is bleeding or at high risk of hemorrhage (ie, at-risk surgical procedure) or severely thrombocytopenic (platelet count < 30,000/mm³). Because of the risk of relapse triggered by infections, physicians should be vigilant for signs of infection, initiating appropriate treatment where necessary.^{1,3}

Recommendations for Standard of Care for Patients With aHUS in the ICU

Using published recommendations¹ and expert opinions of our author group, recommendations for the standard of care for adult patients with aHUS in the ICU are outlined in Table 3.

Outcomes of Critically Ill Patients With aHUS

Data regarding the outcomes of adult patients with aHUS are sparse because of the rarity of the disorder,

TABLE 3] Recommendations for Management of Adult Patients With Suspected aHUS in the ICU

1. Obtain adequate diagnostic samples before plasma therapy.
2. Make use of multidisciplinary care, including nephrologists and hematologists.
3. Initiate plasma therapy within 4-8 h of admission or diagnosis of TMA. For patients with an initial presentation of TMA, switch to eculizumab as soon as a diagnosis of aHUS is confirmed (ADAMTS13 > 10% and STEC negative); for patients with a history of previous aHUS, initiate eculizumab immediately on admission to the ICU.
4. Careful ICU monitoring should be offered because organ dysfunction may appear or worsen until remission.
5. Because of the increased risk of <i>Neisseria meningitidis</i> infection with eculizumab treatment, patients should be vaccinated against serotypes A, C, Y, and W135 and subtype B 2 weeks before eculizumab is initiated; unvaccinated individuals should receive prophylactic antibiotics on eculizumab initiation until at least 2 weeks after <i>N meningitidis</i> vaccination (please refer to country-specific guidelines).

See Table 1 legend for expansion of abbreviations.

and data relating to the treatment of such patients in the ICU are rarer still. However, existing studies agree that the prognosis of patients with aHUS is poor, with approximately 50% of patients requiring dialysis, suffering permanent kidney damage, or dying within 1 year of first occurrence despite plasma therapy.^{4,10,54} In an Italian cohort, mortality after the first episode was 2% in adults; this was markedly lower than the 12% mortality rate reported in children in the same study. Furthermore, 32% of survivors never recovered renal function.¹⁰ Despite plasma therapy, at 3 to 5 years after onset, 67% of adults with aHUS had either died or reached end-stage renal failure.¹⁰

Kidney transplantation, although cited as a treatment option for aHUS, was, in fact, rarely considered because of an overall risk of recurrence after transplantation of 50%, with a high risk of graft rejection (up to 100%) in those with recurrence.³ The risk of posttransplant recurrence varies according to the genetic mutation present and ranges from 0% to 30% in patients with membrane cofactor protein mutation, 40% to 70% with C3 mutation, 45% to 80% with complement factor I mutation, 75% to 90% with complement factor H mutation, and up to 100% with complement factor B mutation.^{3,10,17,55} Because of the high risk of graft rejection, living-donor transplantation is not recommended, particularly from living relations because of the

increased risk of the donor subsequently developing aHUS.³

Since the approval of eculizumab, outcomes of patients with aHUS have improved significantly, causing a paradigm shift in the management of these patients.^{19,49} Notably, 80% of patients on dialysis at baseline could discontinue dialysis with eculizumab.^{21,47} A 2-year extension of a phase II study with eculizumab found that hematologic normalization was achieved by 13 of 17 patients after 26 weeks and by 15 patients at both years 1 and 2. In a retrospective study of 19 cases of aHUS in adults, all with acute kidney injury, nine had normal kidney function after 3 months' treatment with eculizumab.⁵⁶

Conclusions

To our knowledge, this review is the first of its kind to outline the standard of care in critically ill adult patients with aHUS in the ICU. aHUS is defined by thrombocytopenia, nonimmune hemolytic anemia, and acute kidney injury, and often presents with associated organ dysfunction. Although TTP is fairly well recognized by critical care specialists, aHUS remains a diagnostic challenge because of the rarity of the disease. Because there are no specific tests, and aHUS is diagnosed by exclusion, diagnosis should be oriented toward aHUS if disseminated intravascular coagulation is ruled out, STEC test is negative, and plasma activity of ADAMTS13 is > 10%. For optimal patient outcomes, early recognition and appropriate treatment are critical to reduce the risk of irreversible organ damage or death. This review suggests initiating plasma therapy within 4 to 8 h of TMA diagnosis and switching to eculizumab treatment as early as possible after a confirmed aHUS diagnosis (ADAMTS13 > 10% and a negative STEC test).

Acknowledgments

Author contributions: E. A., P. K., J. G.-M., K. R., G. G., P. E., F. A., D. B., M. v.B.-B., J. W., and M. S. met at an advisory board to discuss thrombotic microangiopathies in critically ill patients. Together, they defined the content of this article, the scope of the systematic review, the elements needed to make this review didactical and thoughtful for the readers, and to select the content of each table and figures. E. A. and M. S. drafted the review, and all authors added their contribution and suggested changes. A medical writer edited the sentences where needed and improved the language. Before submission, the article circulated several times within authors, and each single suggestion was taken into account. All authors were involved in drafting and critical revision of the manuscript.

Financial/nonfinancial disclosures: The authors have reported to *CHEST* the following: Alexion paid for the travels and the hotel (for one night) to make the meeting happen. Alexion also paid the medical writer. E. A. is part of the board of Gilead France, and has received fees for lectures from Alexion and Astellas. His institution has received

grants from Fisher & Paykel, Pfizer, and Cubist. P. K. has served as an advisory board member, speaker, and consultant for Alexion, Ablynx, and Baxalta (now Shire). G. G. has received lecture honoraria from Alexion Pharma International Sàrl and Alexion Pharma LLC, Russia. D. B. has received speaker's honoraria from Pfizer and MSD. M. S. has received advisory board and speaker's honoraria for Alexion, Ablynx, Baxalta, and Novartis. None declared (J. G.-M., K. R., P. E., F. A., M.v.B.-B., J.W.).

Role of sponsors: The sponsor had no role in the design of the study, the collection and analysis of the data, or the preparation of the manuscript.

Other contributions: Medical writing and editorial assistance were provided by Kate Kavanagh and Lindsay Napier at Darwin Healthcare Communications, which was funded by Alexion Pharma GmbH. The authors are grateful to Professor Domenico Santoro, MD, PhD (University of Messina, Italy), for valuable input on the algorithm for differential diagnosis for Figure 2.

References

1. Campistol JM, Arias M, Ariceta G, et al. An update for atypical haemolytic uraemic syndrome: diagnosis and treatment. A consensus document. *Nefrologia*. 2015;35(5):421-447.
2. Franchini M. Atypical hemolytic uremic syndrome: from diagnosis to treatment. *Clin Chem Lab Med*. 2015;53(11):1679-1688.
3. Loirat C, Fremeaux-Bacchi V. Atypical hemolytic uremic syndrome. *Orphanet J Rare Dis*. 2011;6:60.
4. Fremeaux-Bacchi V, Fakhouri F, Garnier A, et al. Genetics and outcome of atypical hemolytic uremic syndrome: a nationwide French series comparing children and adults. *Clin J Am Soc Nephrol*. 2013;8(4):554-562.
5. Mele C, Remuzzi G, Noris M. Hemolytic uremic syndrome. *Semin Immunopathol*. 2014;36(4):399-420.
6. Legendre CM, Licht C, Loirat C. Eculizumab in atypical hemolytic-uremic syndrome. *N Engl J Med*. 2013;369(14):1379-1380.
7. Riedl M, Fakhouri F, Le Quintrec M, et al. Spectrum of complement-mediated thrombotic microangiopathies: pathogenetic insights identifying novel treatment approaches. *Semin Thromb Hemost*. 2014;40(4):444-464.
8. Noris M, Mele C, Remuzzi G. Podocyte dysfunction in atypical haemolytic uraemic syndrome. *Nat Rev Nephrol*. 2015;11(4):245-252.
9. Hofer J, Rosales A, Fischer C, Giner T. Extra-renal manifestations of complement-mediated thrombotic microangiopathies. *Front Pediatr*. 2014;2:97.
10. Noris M, Caprioli J, Bresin E, et al. Relative role of genetic complement abnormalities in sporadic and familial aHUS and their impact on clinical phenotype. *Clin J Am Soc Nephrol*. 2010;5(10):1844-1859.
11. Mannucci PM. Understanding organ dysfunction in thrombotic thrombocytopenic purpura. *Intensive Care Med*. 2015;41(4):715-718.
12. Scully M, Goodship T. How I treat thrombotic thrombocytopenic purpura and atypical haemolytic uraemic syndrome. *Br J Haematol*. 2014;164(6):759-766.
13. Reeves HM, Winters JL. The mechanisms of action of plasma exchange. *Br J Haematol*. 2014;164(3):342-351.
14. Scully M, Hunt BJ, Benjamin S, et al. Guidelines on the diagnosis and management of thrombotic thrombocytopenic purpura and other thrombotic microangiopathies. *Br J Haematol*. 2012;158(3):323-335.
15. Cofield R, Kukreja A, Bedard K, et al. Eculizumab reduces complement activation, inflammation, endothelial damage, thrombosis, and renal injury markers in aHUS. *Blood*. 2015;125(21):3253-3262.
16. Walle JV, Delmas Y, Ardissino G, Wang J, Kincaid JF, Haller H. Improved renal recovery in patients with atypical hemolytic uremic syndrome following rapid initiation of eculizumab treatment. *J Nephrol*. 2017;30(1):127-134.

17. Zuber J, Le QM, Sberro-Soussan R, Loirat C, Fremeaux-Bacchi V, Legendre C. New insights into postrenal transplant hemolytic uremic syndrome. *Nat Rev Nephrol*. 2011;7(1):23-35.
18. Sawai T, Nangaku M, Ashida A, et al. Diagnostic criteria for atypical hemolytic uremic syndrome proposed by the Joint Committee of the Japanese Society of Nephrology and the Japan Pediatric Society. *Pediatr Int*. 2014;56(1):1-5.
19. Loirat C, Fakhouri F, Ariceta G, et al. An international consensus approach to the management of atypical hemolytic uremic syndrome in children. *Pediatr Nephrol*. 2016;31(1):15-39.
20. Nester CM. Managing atypical hemolytic uremic syndrome: chapter 2. *Kidney Int*. 2015;87(5):882-884.
21. Loirat C, Saland J, Bitzan M. Management of hemolytic uremic syndrome. *Presse Med*. 2012;41(3 Pt 2):e115-e135.
22. Knobl PN. Treatment of thrombotic microangiopathy with a focus on new treatment options. *Hamostaseologie*. 2013;33(2):149-159.
23. Greenbaum LA. Atypical hemolytic uremic syndrome. *Adv Pediatr*. 2014;61(1):335-356.
24. Hunt BJ. Bleeding and coagulopathies in critical care. *N Engl J Med*. 2014;370(22):2153.
25. Sallee M, Ismail K, Fakhouri F, et al. Thrombocytopenia is not mandatory to diagnose haemolytic and uremic syndrome. *BMC Nephrol*. 2013;14:3.
26. Nester CM, Barbour T, de Cordoba SR, et al. Atypical aHUS: state of the art. *Mol Immunol*. 2015;67(1):31-42.
27. Laurence J. Atypical hemolytic uremic syndrome (aHUS): making the diagnosis. *Clin Adv Hematol Oncol*. 2012;10(10 suppl 17):1-12.
28. Shinkman B, Einav Y. Thrombotic thrombocytopenic purpura and other thrombotic microangiopathic hemolytic anemias: diagnosis and classification. *Autoimmun Rev*. 2014;13(4-5):584-586.
29. Feng S, Eyler SJ, Zhang Y, et al. Partial ADAMTS13 deficiency in atypical hemolytic uremic syndrome. *Blood*. 2013;122(8):1487-1493.
30. Campistol JM, Arias M, Ariceta G, et al. An update for atypical haemolytic uremic syndrome: diagnosis and treatment. A consensus document. *Nefrologia*. 2013;33(1):27-45.
31. Nester CM, Thomas CP. Atypical hemolytic uremic syndrome: what is it, how is it diagnosed, and how is it treated? *Hematology Am Soc Hematol Educ Program*. 2012;2012:617-625.
32. Contreras E, de la Rubia J, Del Rio-Garma J, Diaz-Ricart M, Garcia-Gala JM, Lozano M. Diagnostic and therapeutic guidelines of thrombotic microangiopathies of the Spanish Apheresis Group [in Spanish]. *Med Clin (Barc)*. 2015;144(7):331.
33. Tsai HM. Untying the knot of thrombotic thrombocytopenic purpura and atypical hemolytic uremic syndrome. *Am J Med*. 2013;126(3):200-209.
34. Coppo P, Schwarzinger M, Buffet M, et al. Predictive features of severe acquired ADAMTS13 deficiency in idiopathic thrombotic microangiopathies: the French TMA reference center experience. *PLoS One*. 2010;5(4):e10208.
35. Zafrani L, Mariotte E, Darmon M, et al. Acute renal failure is prevalent in patients with thrombotic thrombocytopenic purpura associated with low plasma ADAMTS13 activity. *J Thromb Haemost*. 2015;13(3):380-389.
36. Noris M, Remuzzi G. Cardiovascular complications in atypical haemolytic uremic syndrome. *Nat Rev Nephrol*. 2014;10(3):174-180.
37. Tsai HM. Thrombotic thrombocytopenic purpura and the atypical hemolytic uremic syndrome: an update. *Hematol Oncol Clin North Am*. 2013;27(3):565-584.
38. Rosove MH. Thrombotic microangiopathies. *Semin Arthritis Rheum*. 2014;43(6):797-805.
39. Caliskan Y, Ozluk Y, Celik D, et al. The clinical significance of uric acid and complement activation in the progression of IgA nephropathy. *Kidney Blood Press Res*. 2016;41(2):148-157.
40. Taylor CM, Machin S, Wigmore SJ, Goodship TH. Clinical practice guidelines for the management of atypical haemolytic uremic syndrome in the United Kingdom. *Br J Haematol*. 2010;148(1):37-47.
41. Noris M, Remuzzi G. Atypical hemolytic-uremic syndrome. *N Engl J Med*. 2009;361(17):1676-1687.
42. Kavanagh D, Goodship TH, Richards A. Atypical hemolytic uremic syndrome. *Semin Nephrol*. 2013;33(6):508-530.
43. Studt JD, Binet I, Nair G, Schanz U. Heparin-induced thrombocytopenia associated with thrombotic microangiopathy. *Hamostaseologie*. 2013;33(2):160-163.
44. Licht C, Ardisino G, Ariceta G, et al. The global aHUS registry: methodology and initial patient characteristics. *BMC Nephrol*. 2015;16:207.
45. Cataland SR, Wu HM. How I treat: the clinical differentiation and initial treatment of adult patients with atypical hemolytic uremic syndrome. *Blood*. 2014;123(16):2478-2484.
46. Legendre CM, Licht C, Muus P, et al. Terminal complement inhibitor eculizumab in atypical hemolytic-uremic syndrome. *N Engl J Med*. 2013;368(23):2169-2181.
47. Licht C, Greenbaum LA, Muus P, et al. Efficacy and safety of eculizumab in atypical hemolytic uremic syndrome from 2-year extensions of phase 2 studies. *Kidney Int*. 2015;87(5):1061-1073.
48. Greenbaum LA, Fila M, Ardisino G, et al. Eculizumab is a safe and effective treatment in pediatric patients with atypical hemolytic uremic syndrome. *Kidney Int*. 2016;89(3):701-711.
49. Fakhouri F, Hourmant M, Campistol JM, et al. Terminal complement inhibitor eculizumab in adult patients with atypical hemolytic uremic syndrome: a single-arm, open-label trial. *Am J Kidney Dis*. 2016;68(1):84-93.
50. Picard C, Burtey S, Bornet C, Curti C, Montana M, Vanelle P. Pathophysiology and treatment of typical and atypical hemolytic uremic syndrome. *Pathol Biol (Paris)*. 2015;63(3):136-143.
51. Schmidtke J, Peine S, El-Housseini Y, Pascual M, Meier P. Treatment of atypical hemolytic uremic syndrome and thrombotic microangiopathies: a focus on eculizumab. *Am J Kidney Dis*. 2013;61(2):289-299.
52. Alexion. Soliris summary of product characteristics. 2016. <https://www.medicines.org.uk/emc/medicine/19966>. Accessed May 22, 2017.
53. Bouts A, Monnens L, Davin JC, Struijk G, Spanjaard L. Insufficient protection by *Neisseria meningitidis* vaccination alone during eculizumab therapy. *Pediatr Nephrol*. 2011;26(10):1919-1920.
54. Caprioli J, Noris M, Brioschi S, et al. Genetics of HUS: the impact of MCP, CFH, and IF mutations on clinical presentation, response to treatment, and outcome. *Blood*. 2006;108(4):1267-1279.
55. Fremeaux-Bacchi V, Miller EC, Liszewski MK, et al. Mutations in complement C3 predispose to development of atypical hemolytic uremic syndrome. *Blood*. 2008;112(13):4948-4952.
56. Fakhouri F, Delmas Y, Provot F, et al. Insights from the use in clinical practice of eculizumab in adult patients with atypical hemolytic uremic syndrome affecting the native kidneys: an analysis of 19 cases. *Am J Kidney Dis*. 2014;63(1):40-48.