

Perioperative Analgesia With Posterior Continuous Lumbar Plexus Block for Simultaneous Ipsilateral Total Hip and Knee Arthroplasty

To the Editor:

Major prosthetic orthopedic surgery of the lower limb often causes severe postoperative pain. Poorly managed pain may hinder prompt joint mobilization and delay functional recovery.¹ Regional anesthesia techniques such as continuous lumbar plexus block (CLPB) by the posterior approach are well recognized to provide good analgesia for total hip arthroplasty (THA)² as well as for total knee arthroplasty (TKA).³ The addition of sciatic nerve block to CLPB performed by the anterior approach (inguinal) has been shown to improve the quality of postoperative analgesia after TKA.^{4,5}

We describe the case of a 31-year-old man (weight 65 kg and height 165 cm) suffering from Stickler dysplasia, an autosomal dominant connective tissue disorder with severe multiple arthroses. He was scheduled for simultaneous right THA and TKA under posterior CLPB with single-injection sciatic nerve block combined with general anesthesia. Insertion of the lumbar catheter was performed with the patient awake, according to the approach described by Capdevila et al.² After observing a contraction of the quadriceps femoris with patellar movement at 0.4 mA, 2 mL ropivacaine 0.5% was injected. A 24-gauge single-end orifice catheter was then inserted through the needle and advanced 3 cm beyond the needle tip. Eighteen millilitres of ropivacaine 0.5% was administered through the catheter with repeated aspiration. A posterior sciatic nerve block was performed with 20 mL bupivacaine 0.5% with epinephrine 1:200,000. Good anesthesia in the territory of the femoral and sciatic nerves was evidenced. General anesthesia was maintained with a mixture of air/oxygen and desflurane. During the 5-hour 30-minute surgical procedure, 0.7 mg fentanyl was injected. Postoperative analgesia consisted of patient-controlled lumbar plexus analgesia with a continuous infusion of ropivacaine 0.2% at the rate of 7 mL/h, 5-mL bolus, and a lockout period of 30 minutes. Paracetamol 4 × 1g and ibuprofen 3 × 400 mg were prescribed orally per day, and rescue morphine 20 mg orally with a maximum of 6 doses in 24 hours was available if the residual pain score was higher than 3 during the lockout period of PCLPA, which was commenced after an x-ray confirmed the correct placement of the catheter. In the recovery room, the visual analog scale (VAS) score was 5 mainly because of pain in the hip area, which was treated with 10 mL ropivacaine 0.5% injected in the lumbar catheter before beginning the continuous infusion. During the operative day, the patient received morphine 20 mg orally twice as rescue for a VAS >3. Afterwards, the VAS was between 0 and 2 through the third postoperative day when the catheter was removed.

Eight months later, the patient was scheduled for THA and TKA on the left side. The anesthetic technique and the postoperative analgesia were similar to the ones described earlier, except for of the patient-controlled lumbar plexus analgesia whose rate of continuous infusion of

ropivacaine 0.2% was set at 8 mL/h and bolus at 8 mL with a lockout period of 60 minutes. The surgery lasted 5 hours 30 minutes as well, and the patient received 0.325 mg fentanyl. At the recovery room, the VAS score was 0. During the operative day, the VAS score was once 4 (hip area), requiring a ropivacaine bolus via the lumbar catheter. Then, the VAS score was between 0 and 1 up to the fifth postoperative day when the catheter was removed. No rescue morphine was necessary during this period.

For this patient, posterior CLPB combined with single-injection sciatic nerve block provided a very effective postoperative analgesia for simultaneous THA and TKA. The better analgesia obtained during the second surgery may be because of a better quality of the posterior CLPB. Differences in nerve supplies of right and left hip between lumbar and sacral plexus as well as sciatic nerve should also be considered.

Alexandre Michel Faust, M.D.
Roxane Fournier, M.D.
Zdravko Gamulin, M.D.
Division d'Anesthesiologie
Hopitaux Universitaires de Geneve
Geneve, Switzerland

References

1. Capdevila X, Bartelet Y, Biboulet P, Ryckwaert Y, Rubenovich J, d'Athis F. Effects of perioperative analgesic technique on the surgical outcome and duration of rehabilitation after major knee surgery. *Anesthesiology* 1999;91:8-15.
2. Capdevila X, Macaire P, Dadure C, Choquet O, Biboulet Ph, Ryckwaert Y, d'Athis F. Continuous psoas compartment block for postoperative analgesia after total hip arthroplasty: New landmarks, technical guidelines, and clinical evaluation. *Anesth Analg* 2002;94:1606-1613.
3. Kaloul I, Guay J, Cote C, Fallaha M. The posterior lumbar plexus block and the 3-in-1 femoral nerve block provide similar postoperative analgesia after total knee replacement. *Can J Anaesth* 2004;51:45-51.
4. Weber A, Fournier R, Van Gessel E, Gamulin Z. Sciatic nerve block and the improvement of femoral nerve block analgesia after total knee replacement. *Eur J Anaesthesiol* 2002; 19:834-836.
5. Morin AM, Kratz CD, Eberhart LHJ, Dinges G, Heider E, Schwartz N, Eisenhardt G, Geldner G, Wulf H. Postoperative analgesia and functional recovery after total-knee replacement: Comparison of a continuous posterior lumbar plexus (psoas compartment) block, a continuous femoral block, and the combination of a continuous femoral and sciatic nerve block. *Reg Anesth Pain Med* 2005;30:434-445.

Accepted for publication August 15, 2006.
doi:10.1016/j.rapm.2006.08.007

Ultrasound-Guided Supraclavicular Brachial Plexus Block: A Modified Plumb-Bob Technique

To the Editor:

Supraclavicular block was originally described in 1953 by Przybora¹ and is regarded as a general-purpose bra-

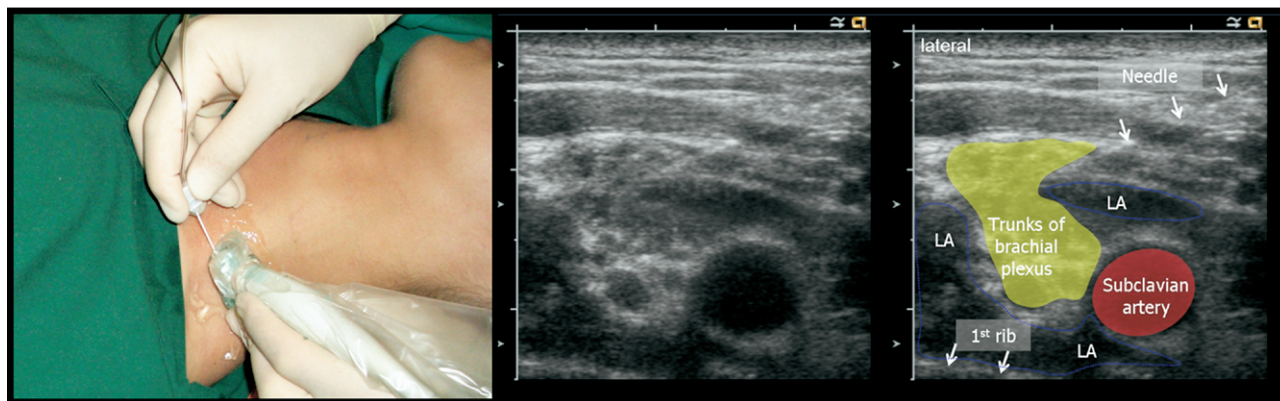


Fig 1. (Left panel) In-plane approach to supraclavicular block. (Middle and right panels) Corresponding sonogram showing the trunks of the brachial plexus, subclavian artery, first rib, block needle, and injected local anesthetic distribution (LA). In this example, a 22-gauge, 5-cm Stimuplex needle (B. Braun, Melsungen, Germany) was used.

chial plexus block that facilitates surgery on the upper extremity. Two common approaches to supraclavicular block are the classical approach, in which the needle is advanced from cephalad to caudad, and the plumb-bob approach,² which uses an anterior to posterior trajectory. In contrast to axillary nerve block, the supraclavicular block is performed with the ipsilateral arm adducted. However, supraclavicular procedures carry the risk of pneumothorax,^{2,3} which has led anesthesiologists to seek inherently safer sites along the brachial plexus.

Ultrasound-guided regional anesthesia has gained an enthusiastic following and promises to deliver new approaches to peripheral regional anesthesia techniques. It allows real-time visualization of nerves and their adjacent structures as well as showing needle position and local anesthetic distribution. Numerous regional anesthetic techniques are being freed from the constraints of surrogate landmarks and are now guided by the nerves themselves.

Ultrasound may address the shortcomings of the supraclavicular brachial plexus block, given that the brachial plexus is superficial and well visualized, as are the pleura and subclavian artery. Although this technique has been evaluated in several studies,^{4,5} the approach has only been explicitly described in 2 articles.^{6,7} In this case series and volunteer study, the described needle approach is lateral to medial, which differs from the classical and plumb-bob approaches. Safety concerns have been raised because this needle trajectory risks pneumothorax if the needle is unintentionally advanced too far or without proper visualization.

Here we describe the use of ultrasound to modify the traditional plumb-bob approach.² This provides a safer needle trajectory when needle tip visibility is suboptimal. Our initial experience suggests that a successful supraclavicular block can be obtained by advancing the needle in a posterolateral direction from the sternocleidomastoid-clavicle junction, within the imaging plane of a high-frequency linear ultrasound transducer. The brachial plexus is compact and well visualized adjacent to the subclavian artery. The needle tip can be seen, and final position confirmed by nerve stimulation if desired. Subsequent spread of local anesthetic injection is observed and potentially optimized by needle adjustment (Fig 1).

The resulting conduction block includes proximal branches of the brachial plexus and should be suitable for shoulder surgery. Further study will be required to determine the relative efficacy and safety of this approach, but it offers a mechanism for possibly avoiding complications when proximal brachial plexus block is desired.

Adam B. Collins, M.D.^a

Andrew T. Gray, M.D., Ph.D.^a

Jens Kessler, M.D.^b

^aDepartment of Anesthesia and Perioperative Care
University of California
San Francisco, CA

^bDepartment of Anaesthesiology
University of Heidelberg
Heidelberg, Germany

References

1. Przybora W. [Supraclavicular block of the brachial plexus.] *Pol Tyg Lek (Wars)* 1953;8:663-667.
2. Brown DL, Cahill DR, Bridenbaugh LD. Supraclavicular nerve block: Anatomic analysis of a method to prevent pneumothorax. *Anesth Analg* 1993;76:530-534.
3. Guzeldemir ME. Pneumothorax and supraclavicular block. *Anesth Analg* 1993;76:685.
4. Kapral S, Krafft P, Eibenberger K, Fitzgerald R, Gosch M, Weinstabl C. Ultrasound-guided supraclavicular approach for regional anesthesia of the brachial plexus. *Anesth Analg* 1994;78:507-513.
5. Williams SR, Chouinard P, Arcand G, Harris P, Ruel M, Boudreault D, Girard F. Ultrasound guidance speeds execution and improves the quality of supraclavicular block. *Anesth Analg* 2003;97:1518-1523.
6. Perlas A, Chan VW, Simons M. Brachial plexus examination and localization using ultrasound and electrical stimulation: A volunteer study. *Anesthesiology* 2003;99:429-435.
7. Chan VW, Perlas A, Rawson R, Odukoya O. Ultrasound-guided supraclavicular brachial plexus block. *Anesth Analg* 2003;97:1514-1517.