

Incidence of lower thoracic ligamentum flavum midline gaps[†]

P. Lirk^{1*}, J. Colvin¹, B. Steger¹, H.-P. Colvin¹, C. Keller¹, J. Rieder¹,
C. Kolbitsch¹ and B. Moriggl²

¹Department of Anesthesiology and Critical Care Medicine, Innsbruck Medical University and

²Institute of Anatomy, Histology and Embryology, Innsbruck Medical University,
Anichstrasse 35, 6020 Innsbruck, Austria

*Corresponding author. E-mail: philipp.lirk@uibk.ac.at

Background. Lower thoracic epidural anaesthesia and analgesia (EDA) has gained increasing importance in perioperative pain therapy. The loss-of-resistance technique used to identify the epidural space is thought to rely on the penetration of the ligamentum flavum. Investigations at the cervical and lumbar regions have demonstrated that the ligamentum flavum frequently exhibits incomplete fusion at different vertebral levels. Therefore, the aim of this study was to directly investigate the incidence of lower thoracic ligamentum flavum midline gaps in embalmed cadavers.

Methods. Vertebral column specimens were obtained from 47 human cadavers. Ligamentum flavum midline gaps were recorded between the vertebral levels T₆ and L₁.

Results. The incidence of midline gaps/number of viable specimens at the following levels was: T_{6–7}: 2/45 (4.4%), T_{7–8}: 1/47 (2.1%), T_{8–9}: 2/45 (4.4%), T_{9–10}: 7/39 (17.9%), T_{10–11}: 12/34 (35.2%), T_{11–12}: 10/35 (28.5%), T₁₂/L₁: 6/38 (15.8%).

Conclusions. In the present study we have determined the frequency of lower thoracic ligamentum flavum midline gaps. Gaps are less frequent than at cervical levels, but more frequent than at lumbar levels. Peak incidence was found in the region between T₁₀ and T₁₂. Using a strict midline approach, one cannot therefore rely on the ligamentum flavum to impede entering the epidural space in all patients.

Br J Anaesth 2005; **94**: 852–5

Keywords: anaesthetic techniques, extradural; anatomy; model, cadaver; spinal cord, extradural space

Accepted for publication: February 23, 2005

The loss-of-resistance (LOR) technique is most commonly used to identify the epidural space in the lower thoracic and lumbar region. This technique depends fundamentally on the resistance to injection of saline and needle advancement offered by spinal ligaments, which abruptly decreases once the tip of the needle has penetrated the ligamentum flavum, and reached the epidural space. Previous cryomicrotome investigations concluded that ligamentum flavum midline fusion could be absent 'to a variable degree', although no exact incidences were given.¹ Recent investigations at cervical, high thoracic, and lumbar levels have confirmed and extended this finding, indicating that, depending upon the vertebral level, up to 74% of ligamenta flava may fail to fuse in the midline.^{2,3} No investigations concerning the detailed incidence of ligamentum flavum midline gaps at lower thoracic levels have been performed. Therefore, the aim of the present study was to directly investigate lower thoracic ligamentum flavum midline gaps in embalmed cadavers.

Methods

Following institutional approval, vertebral column specimens were obtained from 47 human cadavers in legal property of the Institute of Anatomy, Histology and Embryology, Innsbruck Medical University. Cadavers were preserved in a mixture of formaldehyde and carbol.⁴

Vertebral arches were detached at the pedicles of Th₆–L₁ and removed en bloc. The dural sac and epidural connective tissue were removed by blunt dissection, and the ligamentum flavum was directly examined anteriorly.

At each dissected level, the ligamentum flavum was thoroughly investigated for signs of midline gaps and then probed gently using a blunt needle with a diameter of 1 mm. Two investigators (P.L. and J.C.), blinded to each other's results, recorded the frequency of midline gaps.

[†]Presented in abstract form at the IARS 78th Clinical and Scientific Congress, Tampa Bay, Florida, USA, 2004.

Statistics

Descriptive statistics were used for analysis. Inter-observer reliability was analysed using intra-class correlation coefficient (ICC). Scores for statistical measurements with the ICC range from 0 to 1, where the former shows no reliability and the latter perfect reliability.

Results

Mean (range) cadaver age was 81 (39–100) yr. The tissues within the spinal canal were removed easily, with only minimal adherence between adipose tissue and the inner surface of the ligamentum flavum. The ligamentum flavum appeared as a rigid but pliable structure easily distinguishable by its yellowish color and smooth surface. Gaps as a result of lack of fusion in the midline were readily visible, and confirmed by gentle probing. Ligamentous structures in a number of specimens were damaged during harvesting from the cadavers, or during dissection, and were excluded from analysis. Out of the 47 harvested lower thoracic vertebral columns, the numbers of intact specimens allowing for unambiguous interpretation of ligamentum flavum anatomy at different levels were as follows: T_{6–7}: 45, T_{7–8}: 47, T_{8–9}: 45, T_{9–10}: 39, T_{10–11}: 34, T_{11–12}: 35, T_{12/L1}: 38.

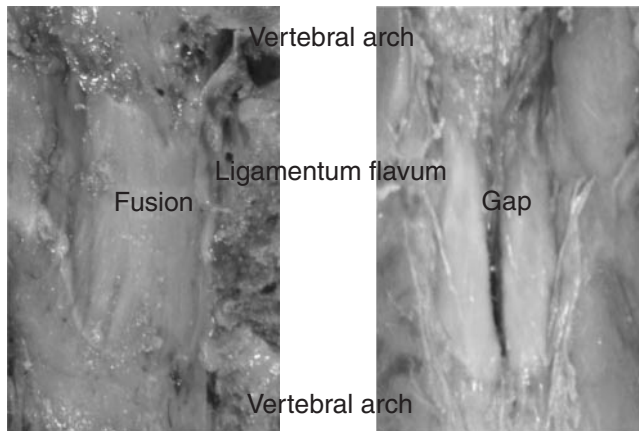


Fig 1 Variations in lower thoracic ligamentum flavum morphology. Left, complete fusion; right, gap throughout entire height.

The following variations were encountered: complete fusion of the ligamentum flavum in the midline, and midline gap throughout the entire height (Fig. 1). The incidence of midline gaps/number of viable specimens at the following levels was (Fig. 2): T_{6–7}: 2/45 (4.4%), T_{7–8}: 1/47 (2.1%), T_{8–9}: 2/45 (4.4%), T_{9–10}: 7/39 (17.9%), T_{10–11}: 12/34 (35.2%), T_{11–12}: 10/35 (28.5%), T_{12/L1}: 6/38 (15.8%). ICC between the two investigators was 1.

Discussion

The present study investigated the incidence of lower thoracic ligamentum flavum midline gaps. Depending on the vertebral level, up to 35% of lower thoracic ligamenta flava are discontinuous in the midline. The incidence of discontinuous ligaments was highest in the region between T₁₀ and T₁₂, gaps being less frequent above and below this level.

During epidural anaesthesia, the needle traverses three main ligamentous structures, the supraspinal and intraspinal ligaments, and the ligamentum flavum. Whereas the first two are composed of collagenous fibres, the ligamentum flavum consists of 80% elastin, and its dense homogenous texture is readily appreciated as a needle passes through it. There is considerable tension in the ligamentum flavum as it spans from the upper rim of the anterior surface of the cephalad lamina of an adjacent pair of vertebrae to the posterior aspect of the lower lamina. Ligamenta flava are thinnest at cervical levels, and increase in strength towards the lumbar spine.⁵ In a transverse plane, it extends from the midline to the roots of the articular processes, where it reinforces the anterior capsules of the zygapophyseal joints. Imaging studies describe ligamenta as most frail in the midline,⁶ the most plausible reason being that the ligamentum flavum embryologically consists of a left and right lateral portion.⁷ These lateral parts of the ligamentum flavum may fuse in the midline, or remain separate.^{2,3,8} Between the left and right half of the ligamentum flavum, frequent intervals for the passage of veins connecting the posterior external vertebral venous plexus with the posterior internal vertebral venous plexus have been described.⁵

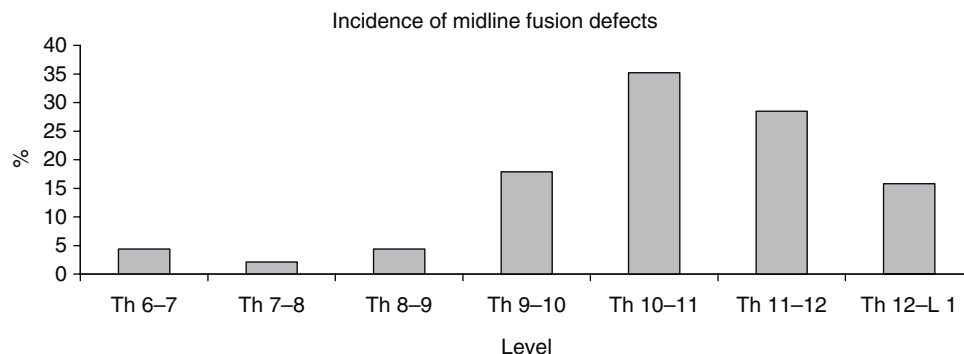


Fig 2 Incidence of ligamentum flavum midline gaps (given as per cent) at different vertebral levels.

Table 1 Summary of ligamentum flavum anatomy investigations. CT, computed tomography; MR, magnetic resonance imaging. Present study, Lirk 2005

Author, yr	Investigated levels	Type of investigation	Incidence of gaps	Comments
Harrison 1999 ¹¹	Lumbar	CT imaging	Always	n=15, low back pain patients
Grenier 1987 ¹⁰	Lumbar	MR imaging	'No ligamentum flavum in midline'	n=30, healthy test persons
Zarzur 1984 ¹⁴	Lumbar	Direct dissection	'Usually'	n=10, gap for venules
Olszewski 1996 ⁹	Lumbar	Direct dissection	Never	n=6
Hogan 1991 ¹	Lumbar	Cryomicrotome	'Variable'	n=38
Lirk 2004 ³	Lumbar	Direct dissection	0% (L ₅ /S ₁) to 22.2% (L _{1/2})	n=45
Lirk 2005	Lower thoracic	Direct dissection	2 (Th _{7/8}) to 35% (Th _{10/11})	n=47
Lirk 2003 ²	Upper thoracic	Direct dissection	2 (Th _{5/6}) to 21% (Th _{1/2})	n=52
Hogan 1996 ⁸	Cervical and thoracic	Cryomicrotome	'About half'	n=26
Lirk 2003 ²	Cervical	Direct dissection	50 (C ₇ /Th ₁) to 74% (cervical)	n=52
Panjabi 1991 ¹⁵	Cervical	Direct dissection	Never	n=6

The incidence of ligamentum flavum midline gaps has been controversially discussed (summarized in Table 1). In general, there seems to be agreement that gaps most regularly occur in the cervical region, and decrease in frequency at high thoracic and lumbar levels.^{2,3} Most investigations have been carried out in the lumbar region using diverse techniques. Here, reported midline gap incidences range from 'never'⁹ to 'always'.^{10,11} More congruence exists for the upper thoracic region, where the incidence is roughly between one-third² and one-half⁸ of cases. In the cervical region, incidences between 50 and 74% have been described. Results from this investigation support and substantially widen the latter findings, in as much as the exact incidence of midline gaps in the lower thoracic region was described for the first time. Gaps appear to be less frequent than at cervical levels, but more frequent as compared with lumbar levels.

It has been reported previously that the superficially located supraspinal and interspinous ligaments do not offer the same elastic resistance to injection of saline as the ligamentum flavum, and the perceptible resistance to needle advancement may therefore be blunted.^{13,12} In cases of failed ligamentum flavum midline fusion, the superficial ligaments may offer some resistance to the advancing needle and injection.¹² However, the latter ligaments are composed of collagenous fibres, and thus the actual loss of resistance may be blunted. Using a strict median approach, the midline gaps described in the present study could be responsible for a considerable proportion of failures to recognize the epidural space.

In principle, a midline gap could thus impede the LOR encountered using the median approach, whereas the paramedian approach should, in all instances, rely safely upon the penetration of the ligamentum flavum. Therefore, the anatomic variations encountered in the present study may offer one possible explanation for impaired epidural space detection during midline puncture.¹³ However, it is not known how often strict 'midline' punctures are actually midline, rather than actually slightly paramedian. In clinical practice, cervical and high thoracic epidural punctures are classically performed using the 'hanging-drop' technique, while the 'LOR' is more commonly used to determine

needle position in the lower thoracic and lumbar region. The reasons for this can only be speculated upon. First, this obviously, at least in part, reflects the excellent reliability of cervical epidural subatmospheric pressure as an indicator of epidural needle placement, which is by far less pronounced in the lumbar region. Secondly, ligamenta flava are thinnest at cervical, and thickest at lumbar levels, increasing the resistance to needle advancement the more caudally puncture is performed.^{2,3} Thirdly, the findings from this and previous studies suggest that using a strict midline approach, one cannot always rely on the ligamentum flavum as a perceptible barrier to epidural needle placement, and, moreover, that this effect is more likely to occur at cervical and high thoracic than at lower thoracic and lumbar levels.^{2,3}

Finally, some potential limitations of this study should be addressed briefly. We chose direct dissection of embalmed specimens to investigate ligamentum flavum anatomy. Therefore, we cannot exclude a potential artifact resulting from the embalming or dissection processes. This, however, is unlikely to be a significant factor as we performed dissections with great care to avoid any damage to the ligamentum flavum. Moreover, if such damage was noted, the specimen was excluded from evaluation. Furthermore, results from anatomic dissections^{2,3} are congruent with previous investigations on non-embalmed specimens.¹⁸ There are no reports that midline gaps of the ligamentum flavum are degenerative in nature, which is relevant to the present study, since the cadavers represented a distinct subpopulation owing to their high average age. In previous investigations in patients suffering from, for example low back pain, no midline fusion defects were described as characteristic or etiologic for degenerative disease.^{10,11}

In conclusion, in the present study we determined the frequency of lower thoracic ligamentum flavum midline gaps. The latter are most frequent in the region between T₁₀ and T₁₂. Using a strict midline approach, one cannot therefore rely on the ligamentum flavum to impede entering the epidural space in all patients.

References

- Hogan QH. Lumbar epidural anatomy. A new look by cryomicrotome section. *Anesthesiology* 1991; **75**: 767–75

- 2 Lirk P, Kolbitsch C, Putz G, et al. Cervical and high thoracic ligamentum flavum frequently fails to fuse in the midline. *Anesthesiology* 2003; **99**: 1387–90
- 3 Lirk P, Moriggl B, Colvin J, et al. The incidence of lumbar ligamentum flavum midline gaps. *Anesth Analg* 2004; **98**: 1178–80
- 4 Platzer W, Putz R, Poisel S. [New system for the preservation and storage of anatomical matter]. *Acta Anat (Basel)* 1978; **102**: 60–7
- 5 Gray H. *Gray's Anatomy*, 20th edn. New York: Bartleby, 2000
- 6 Baledent O, Gondry-Jouet C, Meyer ME, et al. Relationship between cerebrospinal fluid and blood dynamics in healthy volunteers and patients with communicating hydrocephalus. *Invest Radiol* 2004; **39**: 45–55
- 7 Misawa H, Ohtsuka K, Nakata K, Kinoshita H. Embryological study of the spinal ligaments in human fetuses. *J Spinal Disord* 1994; **7**: 495–8
- 8 Hogan QH. Epidural anatomy examined by cryomicrotome section. Influence of age, vertebral level, and disease. *Reg Anesth* 1996; **21**: 395–406
- 9 Olszewski AD, Yaszemski MJ, White AA 3rd. The anatomy of the human lumbar ligamentum flavum. New observations and their surgical importance. *Spine* 1996; **21**: 2307–12
- 10 Grenier N, Kressel HY, Schiebler ML, Grossman RI, Dalinka MK. Normal and degenerative posterior spinal structures: MR imaging. *Radiology* 1987; **165**: 517–25
- 11 Harrison GR. Topographical anatomy of the lumbar epidural region: an *in vivo* study using computerized axial tomography. *Br J Anaesth* 1999; **83**: 229–34
- 12 Cousins MJ, Bridenbaugh PO. *Neural Blockade in Clinical Anesthesia and Pain Management*, 3rd edn. Philadelphia: Lippincott Williams & Wilkins, 1998
- 13 Blomberg RG, Jaanivald A, Walther S. Advantages of the paramedian approach for lumbar epidural analgesia with catheter technique. A clinical comparison between midline and paramedian approaches. *Anaesthesia* 1989; **44**: 742–6
- 14 Zarzur E. Genesis of the 'true' negative pressure in the lumbar epidural space. A new hypothesis. *Anaesthesia* 1984; **39**: 1101–4
- 15 Panjabi MM, Oxland TR, Parks EH. Quantitative anatomy of cervical spine ligaments. Part II. Middle and lower cervical spine. *J Spinal Disord* 1991; **4**: 277–85