

# C6

## Paratracheal Cervicothoracic Sympathetic Block: Safety, Comfort and Reliability Reside in the C6 Approach



Douglas G. Merrill, M.D.  
Staff Anesthesiologist  
Virginia Mason Medical Clinic  
Seattle, Washington

What is wrong with the following sentence?

"When performing a stellate ganglion block for diagnosis of sympathetically mediated pain of the upper extremity, it is best to place the needle closer to the stellate itself, i.e., at the C7 level, to allow a minimum amount of medication to be used – thus avoiding inadvertent somatic blockade while insuring that the sympathetic block of the upper extremity is complete."

In addition to its length and boredom, the sentence errs in four assumptions. In fact:

- The aim is not to block the outflow of the stellate ganglion.
- It is not a diagnostic block.
- Neither placement site nor specific volume injected will ensure *complete* interruption of sympathetic outflow at these levels.
- No placement of the needle, no type of anesthetic and no specific volume injected will ensure *only* a block of sympathetic outflow at these levels.

Freed of these beliefs, we also are free from concern over the best needle placement site (there isn't one), and the "correct" volume to inject (there isn't one) to ensure a "pure" stellate ganglion block that will allow us to diagnose "sympathetically mediated pain" (we cannot). We can, however, use this block to successfully aid the treatment of patients with such diverse diseases as complex regional pain syndrome, congestive heart failure, vasculitis, gangrene and cerebral vascular insufficiency.<sup>1,2</sup>

It is not a stellate block? Moore, who advocated placement of the needle at the level of C7, stated that:

*The term "stellate ganglion block" is now used merely because the needle is inserted in the region of the ganglion. The*

*block ... is actually a block of ... the entire cervicothoracic sympathetic nervous system.*<sup>3</sup>

In fact the stellate ganglion may be the only structure we are not blocking.<sup>4</sup> The various portions of the cervicothoracic sympathetic chain are notably undependable in their shapes, sizes and locations.<sup>5,6,7</sup> The best theoretical construct for the practitioner is to consider this set of structures as a "tangled trunk" rather than a "chain" of discrete and identifiable ganglia, some of which may actually exist only in a minority of humans.<sup>8</sup>

Although computed tomography scan and fluoroscopy have proven to be useful adjuncts that may increase the efficacy of the paratracheal block, no approach can ensure that the stellate ganglion is blocked.<sup>9</sup> Rather it is probable that successful sympatholytic paratracheal injections at any level only block the upper sympathetic chain, but not the lower (i.e., the stellate ganglion). Instead caudal flow of medication instilled in that area appears to be too anterior to block the lower sympathetic trunk. It has been suggested that effective blockade is more likely achieved by action of the anesthetic at other loci such as the sympathetic fibers to the upper extremity that accompany both the subclavian and carotid arteries.<sup>10</sup>

If the stellate ganglion is not the target, logic evanesces for any and all the arguments for a low approach (at C7). Even if we did want to reach the stellate, however, the C7 approach is not reliable for that anyway.<sup>11</sup> In truth we should choose our technique based upon three criteria: safety, comfort and reliability. They are important because this block most often must be employed repeatedly and frequently in order to be an effective adjunct to patient recovery. So we should go where it is safest, most comfortable and most reliable. That's right: C6!

### Safety

The paratracheal area abounds with easy opportunities to inject local anesthetic of significant toxicity into vessels and the neuraxis.<sup>12,13</sup> For this reason, I recommend the C6 level where Chassaignac's tubercle usually (but not always!<sup>14</sup>) provides a clear indicator of the bony

*Continued on page 8*

***"... this block [C7] most often must be employed repeatedly and frequently in order to be an effective adjunct to patient recovery. So we should go where it is safest, most comfortable and most reliable. That's right: C6!"***

## I Use Only the **C7** Approach to the Stellate Ganglion

The stellate ganglion is located at C7, T1 and usually lies in front of the neck of the first rib. Anterior C6 and C7 approaches have been described. Overall safety considerations clearly, without doubt, favor the C7 approach. For this approach, the neck is placed in a slightly flexed position, and the cricoid cartilage is palpated. One finger breadth below the cricoid, the left index finger is gently pressed next to the trachea. The fleshy part of the fingertip easily palpates the carotid pulse. A groove is created between the trachea and the carotid artery, and a 1.5-inch, 22-gauge B-bevel needle is passed in a slightly medial direction. Bony contact is made when the needle tip reaches the ventrolateral side of the body of C7. At this point, the hub of the needle is held between the left index finger and thumb, and a syringe, which should not contain more than 5 ml of local anesthetic solution, is connected to the needle. Following negative aspiration, injection is initiated. If there is significant resistance to injection, the tip is withdrawn slightly, and the 5 cc volume is deposited. The onset of the block is rapid, and Horner's sign becomes visible. The needle is removed, and slight pressure is applied.

The technique just described is for the blind technique. For the fluoroscopy-guided technique, a right-angle, short, flexible connecting piece and a 22-gauge, 2.5-inch needle is used. The needle is placed in the same way as it is for the blind technique. The C7 vertebral body, however, is located with fluoroscopy and is marked externally with an instrument such as a long hemostat [Figure 1]. The needle is placed a fingerbreadth below the cricoid cartilage between the trachea and the carotid artery. After bony contact is made, the hub of the needle is held with an instrument; this reduces exposure of the fingers to radiation. The needle tip location on the ventrolateral aspect of the C7 body is verified by fluoroscopy. Omnipaque<sup>®</sup> 240, approximately 1 ml, is injected [Figure 2]. The contrast will spread from C7 to the top of T1 and toward C6. Next, 5 ml of local anesthetic is injected during continuous fluoroscopy. The local anesthetic should disperse the contrast [Figure 3].

The C7 approach to stellate ganglion is clearly a technique that can be used even in patients with radical neck dissection. It is very effective when the radial or median

nerves are involved in sympathetically maintained pain. The 5 ml volume is adequate to cover the stellate ganglion and the middle cervical sympathetic ganglia. Therefore the block is effective for sympathetically maintained pain affecting facial structures — such as supraorbital shingles, or vascular problems such as Reynaud's Disease — and shoulder pain where often there is a significant sympathetically maintained component. The spread does not go to T2 and T3, which is essential when the ulnar nerve is involved, in which case the T2-T3 sympathetic ganglia needs to be blocked rather than the stellate. To produce a long-lasting block, we use 2.8 percent phenol under fluoroscopic guidance. The illustrations in this article are from a patient who received phenol stellate ganglion block on two occasions at a two-year interval along with 100 units botulinum toxin injected into the biceps. The combined treatment relieved pain and muscle contracture.

Our experience using the C7 approach to the stellate ganglion spans 20 years, during which more than 2,000 injections have been performed. There was one case of hoarseness that lasted four and a half to five months with full recovery.<sup>1</sup>

I am aware of many disasters resulting from the C6 transverse process approach, including seizure from vertebral artery injection, total spinal from intraneural injection at the C6 nerve root, several delayed onset respiratory arrests leading to death that clearly resulted from subdural spread of local anesthetic and infarcted spinal cord



**Gabor B. Racz, M.D., F.I.P.P.**  
Professor and Chair Emeritus  
Department of Anesthesiology  
Texas Tech University  
Health Sciences Center  
Lubbock, Texas

*Continued on page 9*

***"Our experience using the C7 approach to the stellate ganglion spans 20 years, during which more than 2,000 injections have been performed. There was one case of hoarseness that lasted four and a half to five months with full recovery."***

# C6

vertebral transverse process' exact location, thereby usually guiding the operator and the needle away from the vertebral artery and access to the central neuraxis. At the C7 level, the sympathetic elements are often *posterior* to the artery, and it is therefore a site of greater risk.<sup>15</sup> Finally the lung is almost never in play at C6 yet can be punctured with even scrupulously careful placement of a needle at C7.<sup>16</sup>

## Comfort

Two aspects of the use of the C6 level enhance patient comfort. When present, a prominent Chassaignac's tubercle enhances operator confidence, so there is less time spent grinding around on the patient's neck in preparation to strike. Also the transverse process is rapidly encountered at a more shallow level with passage through less tissue, speeding up needle placement and diminishing its painful nature.

## Reliability

Paratracheal injection is not a diagnostic test for sympathetically mediated pain. When this procedure provides pain relief of sympathetically mediated pain, it is only variably associated with production of clinical signs of altered autonomic function.<sup>17</sup> Even the largest volumes of injectate may not completely abolish sympathetic activity in the upper extremity.<sup>18,19</sup> As well, no injection site will reliably produce a purely sympatholytic block because the sympathetic structures are not sufficiently segregated from the brachial plexus and epidural space. Neither of these failings should dissuade its use, however, as a therapeutic adjunct. In most cases, the frequent outcome of only partial sympatholysis and some degree of somatic block are still valuable.

In conclusion paratracheal injection at any level is not a stellate ganglion block, and it is not a diagnostic block. It is, however, a therapeutic tool that may save a

limb or even a life. It also is apparent that no one site of injection or specific volume of injectate is completely reliable in producing the desired sympatholytic block. For that reason, I advocate that the initial plan should always be to inject 10 to 15 cc of local anesthetic at the C6 level, as this is usually the safest, easiest and most comfortable approach. If you find that sympathetic outflow is not sufficiently blocked at C6, I would first increase the volume of injectate before moving the needle "south."

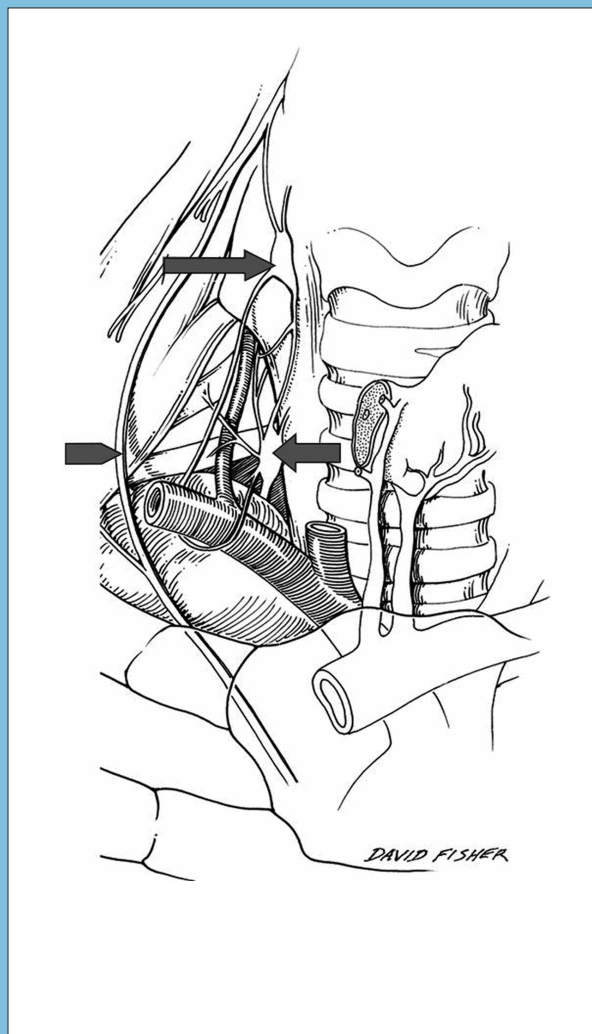
## Anterior neck:

*Tip of long arrow is on the middle cervical ganglion at C6.*

*Tip of short arrow is on the inferior cervical ganglion.*

*Arrowhead points to the phrenic nerve.*

*Note the vertebral artery traveling cephalad and posterior to the middle cervical ganglion.*

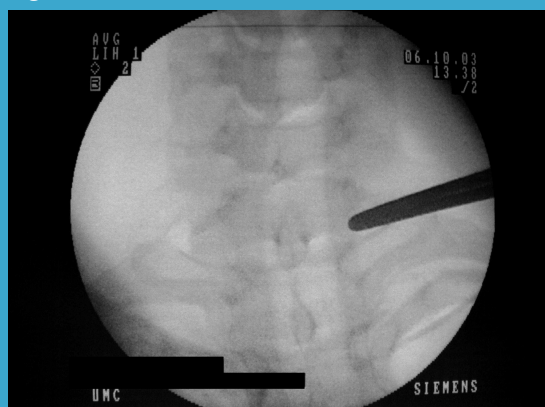

*Used by permission of the publisher, Lippincott Williams & Wilkins. Source: Tubbs RS. et al. Anatomic landmarks for nerves of the neck: A vade mecum for neurosurgeons. Neurosurgery. 2005; 56(4):256-260.*

*Continued on page 12*

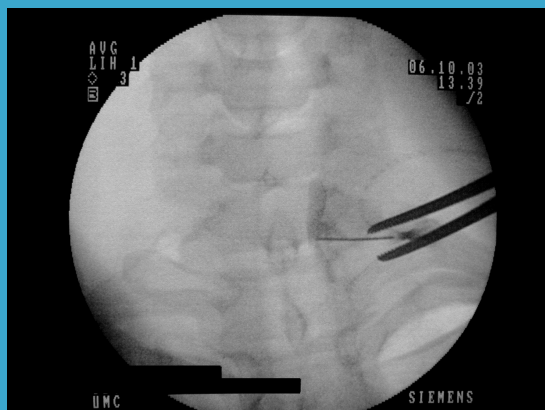


**Figure 1**



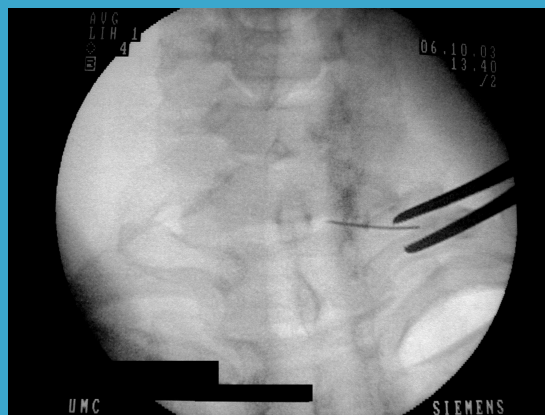*Radiopaque instrument marking the target site.*

**Figure 2**



*Spread of contrast after injection.*

**Figure 3**



*Dispersion of contrast following phenol injection*

from intravascular injection. All of these cases come from the medical-legal arena and have not been reported in the medical literature. Kyzelshytin (personal communication) presented anatomical dissections done after injection of contrast and methylene blue. He found that, with C6, dye spreads to the mediastinum and across to the contralateral side because the injectate is deposited behind the longus colli muscle. Volumes recommended for stellate ganglion blocks using the C6 approach are in the 10-15 ml volume range. Injections are made in the vicinity of not only the vertebral artery and the nerve roots but also near arteries in the posterior neuroforamin. The C6 transverse process may be absent, allowing the needle to enter the posterior wall of the neuroforamin canal and reach the arteries described by Huntoon. Chassaignac's tubercle generally is easily recognizable, but clearly the tip of a sharp needle can enter structures leading to the disasters that occur with an unacceptable frequency. Landmarks are more certain, which makes injection into blood vessels less likely, and smaller volumes of local anesthetic are required for the C7 versus C6 approach. Thus the C7 approach is safer. I recommend the C7 image-guided technique for stellate ganglion block.

#### Reference:

1. Racz GB, Holubec JT. Stellate ganglion phenol neurolysis. In: *Techniques of Neurolysis*. GB Racz, ed. Boston: Kluwer. 1989:133-144.

## Registration

*for the*

**2005 Annual  
Fall Meeting  
and Workshops**

*is available online at*

**www.asra.com**

# C6

## Paratracheal Cervicothoracic Sympathetic Block: Safety, Comfort and Reliability Reside in the C6 Approach

### References:

1. Treggiari MM. Cervical sympathetic block to reverse delayed ischemic neurological deficits after aneurysmal subarachnoid hemorrhage. *Stroke*. 2003; 34:961-966.
2. Dam AK Mishra JC. Managing ergot-induced gangrene: The anesthesiologist as a key player. *Anesth Analg*. 2002; 95:409-410.
3. Moore DC. *Regional Block*. 4<sup>th</sup> ed., CC Thomas. 1979:135.
4. Hogan QH, et al. The spread of solutions during stellate ganglion block. *Reg Anesth*. 1992; 17:78-83.
5. Tubbs RS, et al. The triangle of the vertebral artery. *Neurosurgery*. 2005; 56(S2): 252-255.
6. Hogan QH, Abram SE. Neural blockade for diagnosis and prognosis. *Anesthesiology*. 1997; 86:216-241.
7. Lofstrom FB, et al. Sympathetic neural blockade of upper and lower extremity. In: *Neural Blockade in Clinical Anesthesia and Management of Pain*. Cousins MJ Bridenbaugh PO, eds. 1980:367.
8. Ebraheim NA, et al. Vulnerability of the sympathetic trunk during the anterior approach to the lower cervical spine. *Spine*. 2000; 25:1603-1606.
9. Erickson SJ Hogan QH. CT-guided injection of the stellate ganglion: Description of technique and efficacy of sympathetic blockade. *Radiology*. 1993; 188:707-709.
10. Hogan QH, et al. The spread of solutions during stellate ganglion block. *Reg Anesth*. 1992;17:78-83.
11. Hogan QH, et al. The spread of solutions during stellate ganglion block. *Reg Anesth*. 1992;17:78-83.
12. Mahli A, et al. Aetiology of convulsions due to stellate ganglion block: A review and report of two cases. *Eur J Anaesth*. 2002;19:376-380.
13. Saruki N, et al. Rare complication after stellate ganglion block. *Can J Anaesth*. 1997;44:784.
14. Hoeft MA et al. Variable osteology of the sixth cervical vertebra in relation to stellate ganglion block. *ASRA Newsletter*, Feb. 2005:14-15.
15. Tubbs RS, et al. Anatomic landmarks for nerves of the neck: A vade mecum for neurosurgeons. *Neurosurgery*. 2005; 56(S2):256-260.
16. Raj PP. Stellate ganglion block. In: Waldman SD, ed. *Interventional Pain Management*. Philadelphia: WB Saunders; 1996:267-274.
17. Price DD, et al. Analysis of peak magnitude and duration of analgesia produced by local anesthetics injected into sympathetic ganglia of complex regional pain syndrome patients. *Clin J Pain*. 1998;14:216-226.
18. Hogan QH, et al. The spread of solutions during stellate ganglion block. *Reg Anesth*. 1992;17:78-83.
19. Hogan QH, et al. Success rates in producing sympathetic blockade by paratracheal injection. *Clin J Pain*. 1994; 10:139-145.

## How I Do It: *Ultrasound-Guided Axillary Block*

### References:

1. Perlas A, Chan VWS, Simons M. Brachial plexus examination and localization using ultrasound and electrical stimulation — A volunteer study. *Anesthesiology*. 2003; 99:429-435.
2. Chan VWS, Perlas A, Rawson R, Odukoya O. Ultrasound-guided supraclavicular brachial plexus block. *Anesth Analg*. 2003; 97:1514-17.