



American Journal of Anesthesia & Clinical Research

Case Report

Serratus Anterior Plane Block-An Analgesic Technique for Multiple Rib Fractures: A Case Series - @

Ashok Jadon* and Priyanka Jain

Department of Anaesthesia & Pain Relief Service, Chief Consultant & Head Of Department, Tata Motors Hospital, Jamshedpur-831004, India

***Address for Correspondence:** Ashok Jadon, Department of Anaesthesia & Pain Relief Service, Chief Consultant & Head of Department, Tata Motors Hospital, Jamshedpur-831004, India, Tel: +91-9234554341; E-mail: jadona@rediffmail.com

Submitted: 13 December 2016; **Approved:** 29 December 2016; **Published:** 02 January 2017

Citation this article: Jadon A, Jain P. Serratus Anterior Plane Block-An Analgesic Technique for Multiple Rib Fractures: A Case Series. American J Anesth Clin Res. 2017;3(1): 001-004.

Copyright: © 2017 Jadon A, et al. This is an open access article distributed under the Creative Commons Attribution License, which permits unrestricted use, distribution, and reproduction in any medium, provided the original work is properly cited.

ABSTRACT

Introduction: Multiple rib fractures results in excruciating pain and can predispose to respiratory failure particularly in patients with compromised respiratory function. Thoracic epidural and thoracic paravertebral blocks are effective but invasive techniques to relieve the pain of multiple rib fractures; serratus anterior plane block is a relatively newer technique that is easier to perform and has a better safety profile.

Methods: Six patients with unilateral multiple rib fractures and severe pain were given serratus anterior plane block. Under ultrasound guidance, a bolus dose of 20ml 0.5% Ropivacaine was given between the serratus anterior and external intercostal muscle. A catheter was inserted and an infusion of 0.1% Ropivacaine+1mcg/ ml Fentanyl was given @6ml/ hr. Patients also received oral paracetamol round the clock and IV tramadol was given for breakthrough pain. Pain scores were recorded in all the patients before and after the block.

Results: All the patients had pain relief following the block and no additional doses of analgesics were required. The median pain score on deep breathing before block was 8.5 (\pm 1.211) while median pain score on deep breathing after block was 3.0 (\pm 0.894). None of the patients had respiratory complications owing to improved ability to cough. No complications were recorded from the block.

Conclusion: Serratus anterior plane block can provide effective analgesia in patients with multiple rib fractures. However, the results need to be further substantiated in randomised controlled studies with larger number of patients comparing the efficacy of this block with other regional anaesthetic techniques.

CLINICAL PROBLEM

Multiple rib fractures cause severe pain and contribute significantly to the morbidity and mortality of trauma patients particularly in patients with poor respiratory reserve [1,2]. Inability to cough and breathe deeply due to severe pain leads to sputum retention, atelectasis and a reduction in functional residual capacity [3]. These factors in turn lead to decreased lung compliance, ventilation perfusion mismatch, hypoxemia and respiratory distress [3]. Therefore, effective pain relief remains the cornerstone of management to prevent serious respiratory complications.

CURRENT THERAPEUTIC OPTIONS

Opioids based analgesic techniques are effective but have inherent limitations of respiratory compromise. Therefore, regional analgesic techniques are preferred choice over opioids for pain relief in fractured ribs [3]. Thoracic epidural analgesia and thoracic paravertebral block are effective techniques [3]. However, these techniques are invasive and associated with various adverse effects. Other regional techniques like **Intrapleural block** and **intercostal nerve blocks** have variable success and high potential for local anaesthetic toxicity. **Serratus anterior plane block** is relatively novel technique that is less invasive, easier to perform and has a better safety profile. We present a case series of six patients who were given serratus anterior plane block as an analgesic technique for multiple rib fractures.

METHODS

Six patients with unilateral multiple rib fractures (3 to 6 in numbers) included in this clinical study. All patients were suffering with excruciating pain and were not responding to conventional opioid analgesics. Serratus anterior plane block (Table 1) was given after informed consent about technique and available alternatives. During blocks, patients were placed in supine position with their

arms abducted above the head (Figure 1). A linear ultrasound probe (3-16 MHz, Sonosite M-Turbo) was placed over the 5th rib in the mid axillary line (Figure 2). Under ultrasound guidance and using in-plane technique an 18G Tuohy needle was directed to reach in the inter-fascial plane between the serratus anterior muscle and external intercostal muscle. After confirming needle position by hydro dissection with 3-5 ml of normal saline, a bolus of 20ml 0.5% Ropivacaine was given in this plane (Figure 3). During the injection, the patients were closely monitored for any signs of local anaesthetic toxicity (tachycardia, arrhythmias, altered consciousness, and seizures). After creating a potential space by injection of local anaesthetic an 18G epidural catheter was inserted in the inter-facial plane of muscles through Tuohy needle 3cm beyond the needle. Catheter was tunnelled subcutaneously for 2-3 cm and fixed by adhesive. An infusion of 0.1% ropivacaine+ Fentanyl 1mcg/ ml was given @10-14 ml/ hr for continuous analgesia through an elastomeric pump. Pain scores were recorded before the block and 30 min after the block thereafter 4hourly in all the subjects until discharge. The subjects also received oral Paracetamol and Tramadol (500mg+ 50mg) 8hrly. Tramadol 50mg IV was given for breakthrough pain if VAS was 4 or more. Aggressive respiratory physiotherapy and early mobilisation was encouraged in the patients once pain was 4 or less on deep breathing. The infusion was stopped once the patient was comfortable (VAS 0-2), catheters were removed between 3-5 days and discharged 24 hours later if they had no pain.

RESULTS

All the subjects had significant reduction in pain scores following the block (Figure 4) and none of them required additional doses of analgesia with IV medication. The median pain score on deep breathing before block was 8.5 (\pm 1.211) while median pain score on deep breathing after block was 3.0 (\pm 0.894). Pain scores at rest and movement gradually decreased and patients were mobile on

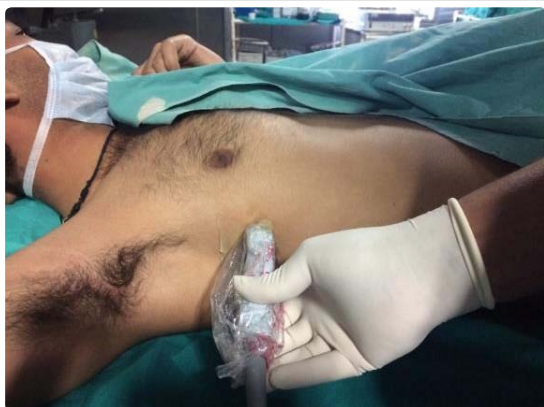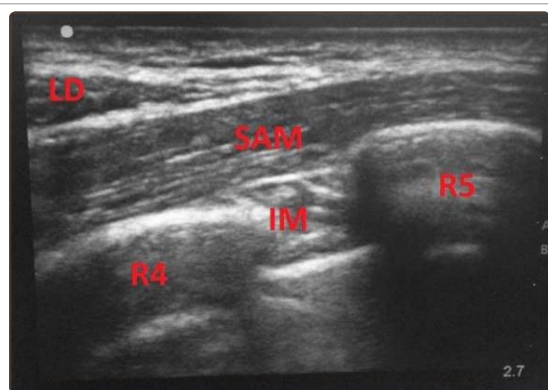
Table 1: Demographic Data.

S.No.	Age(years)	Gender	No. of ribs fractured	Side of involvement	Co-morbidities
1	67	Female	3	Left	HTN, COPD
2	45	Female	3	Right	Nil
3	74	Male	3	Right	HTN, DM
4	69	Male	4	Right	DM
5	43	Male	6	Left	Nil
6	42	Male	6	Right	COPD

HTN: Hypertension, DM: Diabetes Mellitus, COPD: Chronic Obstructive Pulmonary Disease.

Table 2: Mean Pain scores during the stay of the patients.

S.No	Day 1		Day 2		Day 3		Day 4		Day 5		Day 6	
	Pain at rest	Pain on coughing	Pain at rest	Pain on coughing	Pain at rest	Pain on coughing	Pain at rest	Pain on coughing	Pain at rest	Pain on coughing	Pain at rest	Pain on coughing
1	3	5	3	3	2	2	2	2	-	-	-	-
2	4	6	4	5	3	5	3	4	2	3	1	2
3	3	6	3	5	2	5	2	3	1	2	-	-
4	4	7	3	5	3	4	2	3	2	3	2	2
5	3	5	2	3	2	1	-	-	-	-	-	-
6	3	6	3	5	2	4	2	3	1	2	1	2

**Figure 1:** Position of the patient and the probe while performing the block.**Figure 2:** Sonoanatomy of Serratus Anterior Plane, Needle position and LA deposit in the Serratus Anterior Plane; SAM – Serratus anterior muscle, LD – Latissimus Dorsi, IM – Intercostal Muscle, R4 - 4th rib, R5 - 5th rib,

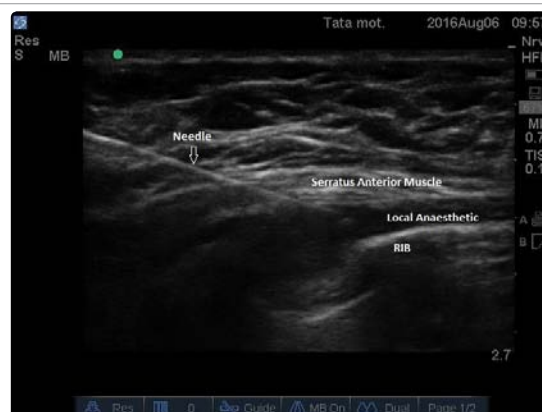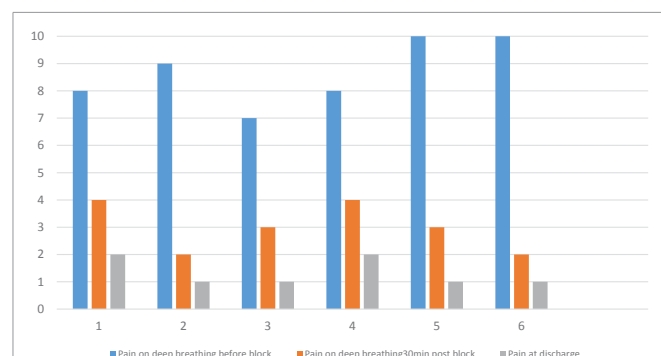
an average by day 3 (Table 2). All the patients had reduced pain on coughing and hence aggressive physiotherapy was possible. None of the patients had respiratory complications. All the patients were satisfied with the pain relief management and early discharge (within 6 days of admission) was possible in all the patients. There were no reported complications from the block.

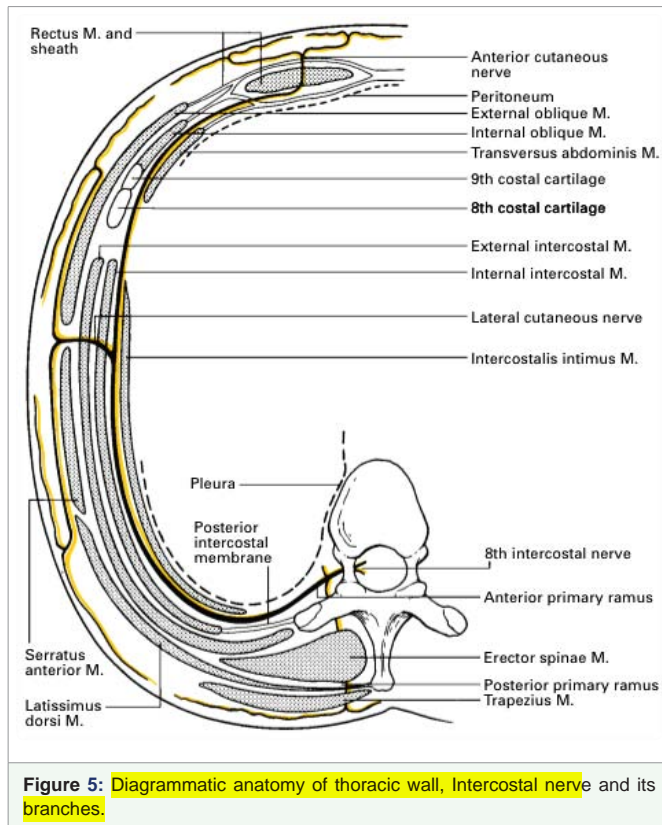
DISCUSSION

Our study showed that serratus anterior plane block provided a reliable analgesia for multiple rib fractures. We propose this as an alternative to other regional anaesthetic techniques. Pain of rib fractures is best managed by epidural analgesia although intercostal nerve block, interpleural block and thoracic paravertebral blocks

have also been described to provide adequate pain relief. However, these techniques are more invasive and are associated with serious complications like pneumothorax, local anaesthetic toxicity, phrenic nerve paralysis and sympathetic blockade [3].

Initially described for breast surgeries by Blanco, et al. [4] serratus anterior plane block can achieve paraesthesia of the complete hemithorax. The serratus muscle is a superficial muscle and can be easily identified on ultrasound. The intercostal nerves originate from the anterior rami of the thoracic spinal nerves (Figure 5) and travel adjacent to the intercostal artery in the intercostal muscles. The lateral cutaneous branches of the intercostal nerves pierce the external and internal intercostal muscles at the mid axillary line to innervate the muscles and skin of the lateral trunk [5]. When the block is performed, the local anaesthetic is deposited directly in contact with

**Figure 3:** Ultrasound image showing block needle below the serratus anterior muscle and spread of local anaesthetic.**Figure 4:** Pain relief following Serratus Anterior Plane Block.



the lateral cutaneous branches. The pain relief from the block implies that the local anaesthetic soaks into the intercostal space to reach the intercostal nerve roots that supply the rib periosteum and parietal pleura [6].

However, two different schools of thought exist regarding the site of deposition of local anaesthetic in the serratus block. Blanco, et al. [4] identified two potential compartments that could be used in this block: one superficial to the serratus muscle and one deep to the muscle. They concluded that the superficial plane is more effective based on the distribution of the injection and sensory mapping. In our study, we used Fajardo's approach and deposited the local anaesthetic below the Serratus Muscle [7]. We believe that greater spread is achieved if the injection is located between the Serratus Anterior and external intercostal muscles because respiratory movements allow the local anaesthetic to be dispersed along the space due to capillary action [8].

Many controversies also exist regarding the anatomy of the serratus anterior plane. Although it has been described to achieve complete paraesthesia of the hemithorax [4]; the posterior rami, the anterior cutaneous branches of the intercostal nerves and the supraclavicular nerves are not blocked which is achieved by epidural and paravertebral blocks [9]. Also not clear is the effect of this block on the deeper intercostal muscles, which might result in pain while coughing [10]. So far, we could find only one case series of 10 cases [11] and one case report [12] regarding use of serratus plane block for management of fracture rib pain. However, none of the study has

mentioned about the nature of injury (number of ribs involved or place of fracture in the ribs). In our study all the patients had fracture in anterior 2/3 area and that could be a reason for successful outcome in our patients. However, further studies are needed to evaluate the efficacy of Serratus Plane Block for thoracic wall blockade if fractures are occurring in posterior 1/3 portion of the rib.

Our study is limited by the fact that a small number of patients were studied in this trial. We did not study patients with serious injuries like bilateral rib fractures with respiratory compromise and polytrauma patients. Also, the analgesic efficacy of this technique compared to other regional anaesthetic techniques needs to be further evaluated in randomised controlled trials. However, the results of our study indicate that this block holds promise in the management of patients with multiple rib fractures.

CONCLUSION

We conclude that Serratus Anterior Plane block is an effective means of providing analgesia in patients with multiple rib fractures. It is relatively straightforward to perform and is amenable to continuous infusion catheter techniques with fewer risks of complications. However, the results need to be further substantiated in randomised controlled trials using a larger number of patients.

REFERENCES

- Mayberry JC, Trunkey DD. The fractured rib in chest wall trauma. *Chest Surg Clin N Am.* 1997; 7: 239–261.
- Ziegler DW, Agarwal NN. The morbidity and mortality of rib fractures. *J Trauma.* 1994; 37: 975–979.
- Karmakar, M. and Ho, A. Acute Pain Management of Patients with Multiple Fractured Ribs. *The Journal of Trauma: Injury, Infection, and Critical Care.* 2003; 54: 615-625.
- Blanco R, Parras T, McDonnell JG, Prats-Galino A. Serratus plane block: a novel ultrasound-guided thoracic wall nerve block. *Anaesthesia.* 2013; 68: 1107-1113.
- Mayes J, Davison E, Panahi P, Patten D, Eljelani F, Womack J, Varma M. An anatomical evaluation of the serratus anterior plane block. *Anaesthesia.* 2016; 71: 1064-1069.
- Durant, E., Dixon, B., Luftig, J., Mantuani, D. and Herring, A. Ultrasound-guided serratus plane block for ED rib fracture pain control. *The American Journal of Emergency Medicine* 2017 Jan; 35: 197.e3-197.e6.
- Fajardo M, López S, Diéguez P, Alfaro P, García FJ. A new ultrasound guided cutaneous intercostal branches nerves block for analgesia after non reconstructive breast surgery. *Cirugia Mayor Ambulatoria.* 2013; 18: 36.
- Fajardo MP, Torre ADL, López S, Garcia F.J. Serratus-intercostal Plane block. An encouraging approach for breast surgery. *Anaesthesia* 2011; 66 Issue 9.(In-Reply)
- Tighe, S. and Karmakar, M. Serratus plane block: do we need to learn another technique for thoracic wall blockade? *Anaesthesia.* 2013; 68; 1103-1106.
- Hammerback H, Venkatachalam S, Rashid A. Serratus plane block and rib fractures. *Anaesthesia* 2016. 77. (In-Reply)
- Parras T. Case series: serratus plane block for rib fracture analgesia. *ESRA Academy.* 2015; 105289.
- Kunhabdulla NP, Agarwal A, Gaur A, Gautam SK, Gupta R, Agarwal A. Serratus anterior plane block for multiple rib fractures. *Pain Physician* 2014; 17: 651-653.