

# A New Inguinal Approach for the Obturator Nerve Block

## Anatomical and Randomized Clinical Studies

Olivier Choquet, M.D.,\* Xavier Capdevila, M.D., Ph.D.,† Khaled Bennourine, M.D.,\* Jean-Louis Feugeas, M.D.,\* Sophie Bringuier-Branchereau, M.Sc.,‡ Jean-Claude Manelli, M.D.§

**Background:** Obturator nerve block is highly recommended for knee surgery in addition to a femoral nerve block. The main disadvantage of the classic approach at the pubic tubercle is low patient acceptance due to pain and discomfort. The authors hypothesized that the use of a new inguinal obturator nerve block technique would reduce pain and discomfort in patients.

**Methods:** The inguinal approach was simulated in five fresh cadavers. Injection of latex was performed in two cadavers. The location of the needle and the extent of latex solution were analyzed. Fifty patients scheduled to undergo arthroscopic knee surgery were randomly assigned to receive obturator nerve block using either the inguinal ( $n = 25$ ) or the pubic tubercle approach ( $n = 25$ ).

**Results:** In all cadavers, the needle was close to the obturator nerve branches, which were surrounded by the latex solution. In the clinical study, visual analog scale pain scores and discomfort of block placement were significantly lower in the inguinal group compared with the pubic tubercle group ( $P < 0.01$ ). In the inguinal group, there was a significant decrease in block performance time ( $P < 0.05$ ) and in bolus of propofol and fentanyl used for the procedure ( $P < 0.01$ ). Twenty minutes after application of the block, adductor strength decrease, occurrence, and location of cutaneous distribution of the obturator nerve were not significantly different between the groups. The incidence of minor complications was significantly increased in the pubic tubercle group ( $P < 0.05$ ). No major complications were observed.

**Conclusions:** The new inguinal approach decreases patient discomfort and pain of block placement as well as the time and sedation and analgesics required for a similar quality of sensory and motor block compared with the pubic tubercle approach.

FEMORAL block combined with sciatic nerve block is frequently used for lower limb surgery. However, com-

bination with deep sedation or general anesthesia is frequently reported in 13–37% of patients scheduled to undergo knee arthroscopy<sup>1–3</sup> and in 42% of patients scheduled to undergo open knee surgery.<sup>4</sup> Femoral nerve block is effective for femoral nerve blockade but not constantly for lateral femoral cutaneous nerve blockade. On the other hand, authors were unable to demonstrate a constant cutaneous loss of sensation after an obturator nerve block (ONB).<sup>5–12</sup> They concluded that testing of motor function (adductor muscle weakness) is necessary to ascertain the success of block. This suggests that the concept of three-in-one block is now defunct and that it is necessary to block individual nerves separately to consistently provide complete anesthesia for procedures on the knee joint.<sup>10–13</sup> Recent clinical studies demonstrated that obturator nerve block improves the quality of anesthesia during knee surgery during peripheral nerve block<sup>13</sup> and postoperative analgesia after total knee arthroplasty.<sup>14,15</sup> Authors in most studies performed the ONB using the classic landmarks near the pubic tubercle described by Labat.<sup>16</sup> However, Wasser<sup>17</sup> reported that the degree of patient discomfort was an important consideration, and patient satisfaction was low. This could be due in part to the puncture site at the mons pubis close to the genitals and because of painful bone contact. We hypothesized that the application of the block would be easier and patient acceptance would be higher with an approach on the anterior and upper inner part of the thigh. The purpose of this work was (1) to describe a simple and reliable method of ONB at the level of the inguinal crease (inguinal ONB) using cadavers and (2) to compare this new approach with the traditional pubic approach (pubic ONB) in a randomized clinical study. Pain, patient comfort during application of the block, quality of sensory blockade, adductor muscle weakness after injection of 1% mepivacaine, and adverse events were evaluated.



Additional material related to this article can be found on the ANESTHESIOLOGY Web site. Go to <http://www.anesthesiology.org>, click on Enhancements Index, and then scroll down to find the appropriate article and link. Supplementary material can also be accessed on the Web by clicking on the "ArticlePlus" link either in the Table of Contents or at the top of the Abstract or HTML version of the article.

\* Associate Professor, Department of Anesthesiology, § Professor, Head of Department, Department of Anesthesiology and Critical Care Medicine, La Conception University Hospital. † Professor, Head of Department, Department of Anesthesiology and Critical Care Medicine, ‡ Associate Professor, Clinical Research Physician, Department of Anesthesiology and Critical Care Medicine and Department of Medical Biostatistics, Lapeyronie University Hospital.

Received from Departments of Anesthesiology and Intensive Care Medicine, La Conception University Hospital, Marseille, France, and Lapeyronie University Hospital, Montpellier, France. Submitted for publication January 11, 2005. Accepted for publication July 28, 2005. Support was provided solely from institutional and/or departmental sources. Presented in part at the 43rd National Meeting of the French Society of Anesthesiology and Critical Care Medicine, September 21–23, 2001.

Address reprint requests to Prof. Capdevila: Lapeyronie University Hospital, 371, Av du Doyen G Giraud, 34295 Montpellier cedex 5, France. Address electronic mail to: [x-capdevila@chu-montpellier.fr](mailto:x-capdevila@chu-montpellier.fr). Individual article reprints may be purchased through the Journal Web site, [www.anesthesiology.org](http://www.anesthesiology.org).

## Materials and Methods

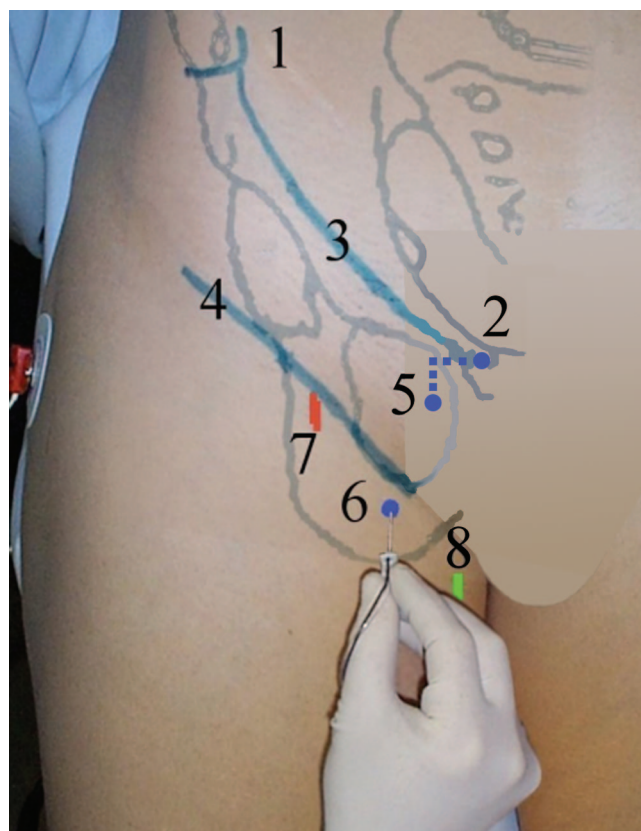
### Anatomical Study

The anatomical study was performed in nine cadavers. Cadavers with evidence of surgery or pathology of the thigh or pelvis were excluded. All experiments were performed on both legs. Two cadavers were initially dissected on both sides to locate both branches of obturator nerve at the level of the inguinal crease between the femoral artery and the adductor muscles.<sup>18–20</sup> The new inguinal approach for ONB was simulated on a

further five mature adult cadavers to confirm that a needle inserted in a posterior direction at the middle of a line drawn in the inguinal crease between the femoral artery and the inner border of the adductor longus tendon would pass in the vicinity of the anterior and posterior obturator nerve branches. The inguinal crease and the groove between the vascular bundle and the adductor longus tendon were identified. A 16-gauge 90-mm Tuohy needle was inserted cephalad, midway between the femoral artery and the inner border of the adductor longus tendon in a sagittal plane at a 30° cephalic angle to the skin until bone contact occurred. The inner thigh was then opened, and the location of the needle with respect to the femoral artery, adductor muscles, obturator nerve branches, and foramen was observed. Finally, liquid latex was injected into two additional cadavers. Careful bilateral dissection exposed the terminal branches of the obturator nerve without disturbing the adjacent anatomic structures. A 10-cm, 16-gauge catheter was inserted between the adductor longus and adductor brevis in contact with the anterior branches of the obturator nerve on one side, and between the adductor brevis and the adductor longus in contact with the posterior branches on the other side of each cadaver. The different anatomical layers were closed in inverse order, and 5 ml latex was slowly injected under low pressure into the catheters. The inner thigh was opened 24 h later, and the extent to which the nerves branches were surrounded with latex was analyzed.

### Clinical Study

After approval from our institutional review board (La Conception Hospital, Marseille, France) and written informed patient consent, 50 patients scheduled to undergo knee arthroscopy (American Society of Anesthesiologists physical status I, II, or III) during combined femoral-obturator-sciatic nerve blocks were included in the clinical study. Exclusion criteria included age younger than 18 yr or older than 85 yr, allergy to local anesthetics or other medications used in this study, pre-existing neurologic deficits of the lower extremities, pregnancy, breast-feeding, and inability to understand the explanations about the procedure because of a language barrier or other problems. Patients were premedicated with 100 mg oral hydroxyzine and received no sedation before the application of the blocks. Standard monitoring was used throughout the study (intravenous line, electrocardiography, automated sphygmomanometer, and pulse oximetry). Patients were randomly assigned to one of the two groups: ONB at the pubic tubercle (pubic group,  $n = 25$ ) or at the inguinal crease (inguinal group,  $n = 25$ ). All blocks were performed by investigators who were not involved in further treatment of the patients. Nerve blocks were performed using a nerve stimulator (HNS 11; B. Braun, Melsungen, Germany) and a 100-mm insulated needle for ONB and



**Fig. 1.** Illustration of the traditional pubic and the inguinal approach for obturator nerve block. In the pubic approach, the insertion point of the needle is 2 cm lateral and 2 cm inferior to the pubic tubercle. In the inguinal approach, the insertion point of the needle is at the midpoint of the line drawn between the femoral arterial pulse and the inner border of the adductor longus tendon. (1) Superior anterior iliac spine, (2) pubic tubercle, (3) inguinal ligament, (4) inguinal crease, (5) insertion point of needle in the pubic approach, (6) insertion point of the needle in the inguinal approach, (7) femoral pulse, (8) inner border of the adductor longus tendon.

sciatic nerve block (21-gauge Stimuplex; B. Braun) and a 50-mm insulated needle for femoral nerve block (21-gauge Stimuplex). Mechanical paresthesia was never intentionally sought.

The technique used to block the obturator nerve near the pubic tubercle was performed as follows (fig. 1): With the patient supine and with the legs slightly abducted and externally rotated, the needle was inserted posteriorly and 20° laterally, 2 cm caudal and 2 cm lateral to the pubic tubercle. Intentional contact with the inferior border of the superior pubic ramus bone and sliding off the inferior margin of the superior pubic ramus was not purposefully attempted. Stimulation was begun using a current of 3 mA for 0.1 ms at 1 Hz. The current was gradually decreased until the muscle twitch stopped between 0.2 and 0.7 mA. At that time, 10 ml mepivacaine, 1%, was injected.

The inguinal ONB was performed as follows (fig. 1). The patient, placed supine and with the legs slightly abducted, was first asked to flex his or her hip, and a line

marked the inguinal crease. The adductor longus tendon was identified as the most superficial palpable tendon in the medial part of the thigh. A mark on the skin was made in the inguinal crease at the midpoint of the line drawn between the inner border of the adductor longus tendon and the femoral arterial pulse. This point corresponds to the center of an easily palpable groove between the vascular bundle and the adductor longus muscle. The needle was inserted at this insertion point in a 30° cephalad direction until contractions of the gracilis or adductor longus muscle were elicited. The adductor longus response of the obturator nerve (anterior branch) is observed at the anterior part of the inner thigh. Weak contraction of the gracilis, which frequently accompanies the former, forms a narrow muscular band down to the medial part of the knee. The stimulation was begun using a current of 3 mA for 0.1 ms at 1 Hz. The current was gradually decreased until the muscle twitch stopped between 0.2 and 0.7 mA. At that time, 5 ml mepivacaine, 1%, was injected (anterior branch of the obturator nerve). The needle was inserted deeper and in a 5° lateral direction until contractions of the adductor magnus muscle were elicited. The adductor magnus response of the obturator nerve (posterior branch) appears at the posterior part of the inner thigh and produces a noticeable hip adduction. In the same manner, 5 ml mepivacaine, 1%, was injected (posterior branch of the obturator nerve). Additional information is available on the ANESTHESIOLOGY Web site at <http://www.anesthesiology.org>.||

Patients were able to receive a 50- $\mu$ g intravenous fentanyl and/or 0.3-mg/kg propofol bolus if they found the ONB application painful or uncomfortable. The number of needle attempts (defined by insertion of the needle in the planned direction until a motor response was elicited), the needle depth, and the minimal intensity of stimulation were recorded. The block performance times for each branch (time between initial insertion of the needle and first motor response for a branch) were noted. These times were added to reach a complete time for the inguinal approach. The clock was stopped for intravenous administration of sedation and started again 3 min later. When the nerve was not located after four attempts, the insertion point was moved first 1 cm more laterally, then 1 cm more medially if necessary. The needle was removed; the groin and mons pubis were covered to hide the two injection sites during the remainder of the assessment to facilitate blinding.

|| Inguinal ONB procedure: Adductor longus tendon and femoral artery pulse were identified at the level of the inguinal skin crease (landmarks video). An insulated needle was inserted in a 30° angle at the midpoint between both landmarks and elicited first adductor longus response of the obturator nerve (anterior branch video) and subsequently 1 cm deeper adductor magnus response of the obturator nerve (posterior branch video). Five milliliters local anesthetic was separately injected on each branch.

An independent observer who was blinded to the approach performed recorded the following data. The degree of patient discomfort associated with the ONB was assessed (0 = no or mild discomfort; 1 = moderate discomfort; 2 = important discomfort). Visual analog scale pain scores (0 = no pain; 100 = worst imaginable pain) after application of the block and time of application (the time taken to elicit an adequate response that disappeared at low current) were recorded. The zero time for sensory block and adductor muscle weakness assessments was the completion of local anesthetic injections. The assessment of adductor muscle strength was performed with a sphygmomanometer as described by Lang *et al.*<sup>12</sup> before and 20 min after block application. The patients were asked to extend the knees and hips and then to squeeze a blood pressure cuff previously inflated to 40 mmHg between their knees. The investigator resisted the patient's attempt to adduct the contralateral leg toward the midline to ensure that the maximal sustained pressure generated on the mercury sphygmomanometer was recorded as an index of adductor strength of only the blocked leg. Because of the application of a selective ONB, any degree of decrease in adductor strength was considered a positive sign of obturator paresis. Patients with evidence of motor deficit were considered to have a successful ONB and were subsequently included in this analysis. Patients were then assessed by the same investigator for sensory block in the anterior, medial, and posterior aspects of their thigh and knee by light touch and loss of cold sensation with an ice cube enclosed in a fine plastic bag. Patients were not able to watch the investigator performing the sensory or motor evaluation. The response was compared with that of the noninjected side and scored at 20 min using the following scale: 0 = no perception; 1 = reduced sensation; 2 = normal sensation.

After this initial evaluation, a femoral nerve block was performed. A 50-mm insulated needle was inserted just lateral to the fingertip palpating the lateral edge of the femoral artery. The stimulation was begun using a current of 3 mA for 0.1 ms at 1 Hz. The needle was advanced cephalad in a sagittal plane at a 30° angle to the skin until an appropriate evoked motor response (quadriceps muscle contraction with patellar ascension) was elicited. The current was decreased until the muscle twitch stopped at 0.2 mA or greater. The needle was inserted slowly, 5 mm deeper, without reappearance of the twitches to ascertain that the tip of the needle was under the fascia iliaca. The current was increased again at 3 mA, and the needle was withdrawn until the quadriceps twitch reappeared and then stopped between 0.2 and 0.7 mA. Twenty milliliters mepivacaine, 1%, was injected over a 2-min period. The patient was then placed in the lateral Sims position with the side to be blocked uppermost, and sciatic nerve block was performed according to the classic Labat approach. A



100-mm insulated needle was inserted and redirected in sequence to elicit flexion and dorsiflexion of the foot. For each of the twitches, the current was gradually decreased until the muscle twitch stopped between 0.2 and 0.7 mA, and 20 ml mepivacaine, 1%, was injected (10 ml per twitch). The adequacy of femoral nerve block and sciatic nerve block was assessed 20 min later. In case of femoral nerve block or sciatic nerve block failure (no motor block—normal knee extension and ankle movements and no sensory block in femoral and sciatic territories), general anesthesia would have been delivered, and the patient would have been excluded from the study. Then, patients were taken to surgery. The surgical procedure was performed in all patients using a standard thigh tourniquet inflated 100 mmHg higher than systolic arterial blood pressure. Partial or total combined femoral-obturator-sciatic block failure, respectively defined by sedation or a general anesthesia required to complete surgery, was assessed. At the end of surgery, the patient was taken to the postanesthesia care unit until the sensory block ended. Minor (small local bleeding, painful bone contact, persistent groin pain, replacement of needle insertion point) and major (hematoma, painful paresthesia, neuropathy) adverse events were recorded.

### Statistics

We hypothesized that the use of the inguinal ONB technique would reduce pain in patients. The visual analog scale score was chosen as the primary criterion for analysis. The number of patients required was calculated based on a power of 90%, an  $\alpha$  risk of 0.05, an SD of 18 mm, and an expected difference between groups of 15 mm. SD and expected difference originated from previously published values.<sup>21,22</sup> The sample size was 25 patients in each group. The statistical analysis was performed using SAS software (version 6.12; SAS Institute, Cary, NC) in the Medical Computer Programming Department of the University Hospital of Montpellier, France. Results are presented as mean  $\pm$  SD or median (range).

Initially, we carried out a description of each variable and calculated the frequency for each modality of the qualitative variables. For each quantitative variable, the normal distribution was studied.

Comparison of two qualitative variables was conducted using the chi-square test or Fischer's exact test when the assumptions for the chi-square test were not satisfied. Comparisons of averages were performed using the Student *t* test or the Wilcoxon Mann-Whitney non-parametric test in case of weak conditions or non-Gaussian distribution of the variables under consideration.

For all analyses,  $P < 0.05$  was considered significant.

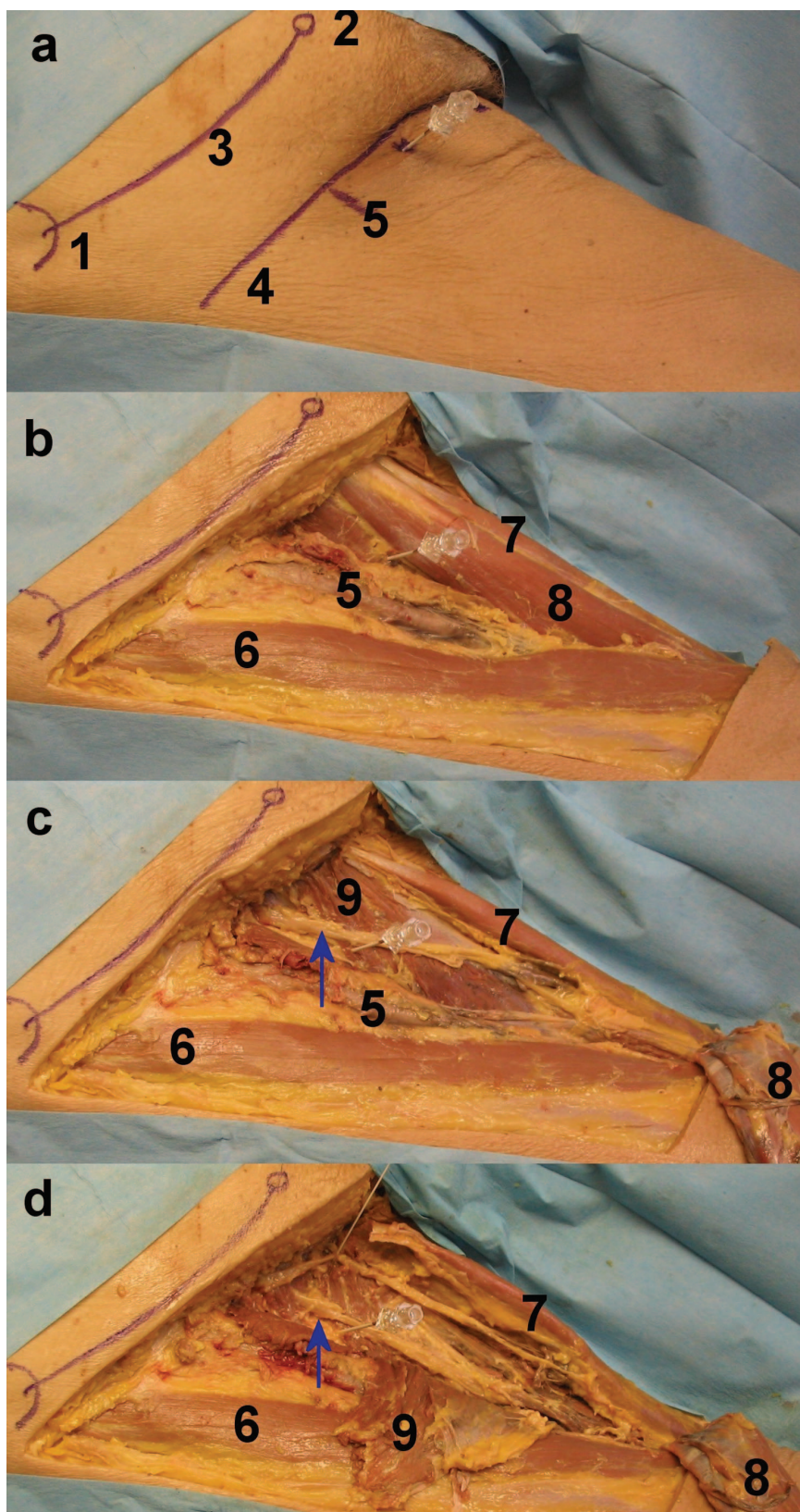
### Results

In all nine cadavers, the obturator nerves emerged into the thigh from the obturator foramen and were already divided into an anterior and a posterior branch. The two branches were separated by some fibers of the obturator externus muscle (14 of 18 thighs) or ran over the obturator externus (4 of 18 thighs). At the level of the inguinal crease, the two branches were separated by the adductor brevis muscle. On the first two cadavers, the anterior and posterior obturator nerve branches were in a sagittal plane that crosses the middle of a line drawn in the inguinal crease between the femoral artery and the inner border of the adductor longus tendon. On the further five cadavers, the needle went through the skin, the inferior border of pectineus or superior border of adductor longus muscle, the adductor brevis, and the adductor longus and touched the ischiopubic ramus. The needle passed close to the great saphenous vein, far from the medial circumflex arteries and veins and the pelvic content. The distance between the needle and a branch of the obturator nerve was less than 2 mm in the 10 cases (fig. 2). In the last two cadavers, the injection of latex solution resulted in spread of the solution to the branch of the obturator nerve close to the needle's tip on all four sides. Surprisingly, in one of the two cadavers, the two branches of the obturator nerve were surrounded by the latex solution at the level of the obturator foramen on both sides (fig. 3).

Fifty patients scheduled to undergo knee arthroscopy were enrolled in the clinical study. There were no significant differences in demographics between the two groups of patients (table 1). No patient was excluded because of initial ONB, femoral nerve block, or sciatic nerve block failure. Patients in the inguinal group reported significantly lower visual analog scale pain scores, discomfort, and fentanyl and/or propofol bolus during ONB performance than those in the pubic group ( $P < 0.01$ ; table 2).

The anterior and posterior branches of the obturator nerve were blocked separately for all but one patient. In this case, contractions of adductor longus and gracilis were obtained at the same depth as those of adductor magnus after the needle was redirected in a 5° lateral direction. The posterior branch was located before the anterior branch for one patient.

The inguinal group showed a significant decrease in block performance time ( $P < 0.05$ ) compared with the pubic group (table 3). Twenty minutes after application of the block, adductor strength decreased by  $65.38 \pm 16.37\%$  in the inguinal group and by  $59.98 \pm 18.71\%$  in pubic group (not significant). In the postanesthesia care unit, the adductor strength was decreased by  $94 \pm 7\%$  in the inguinal group and by  $93 \pm 11\%$  in pubic group (not significant). The occurrence and location of cutaneous distribution of the obturator nerve was not significantly different in the two groups (table 3).



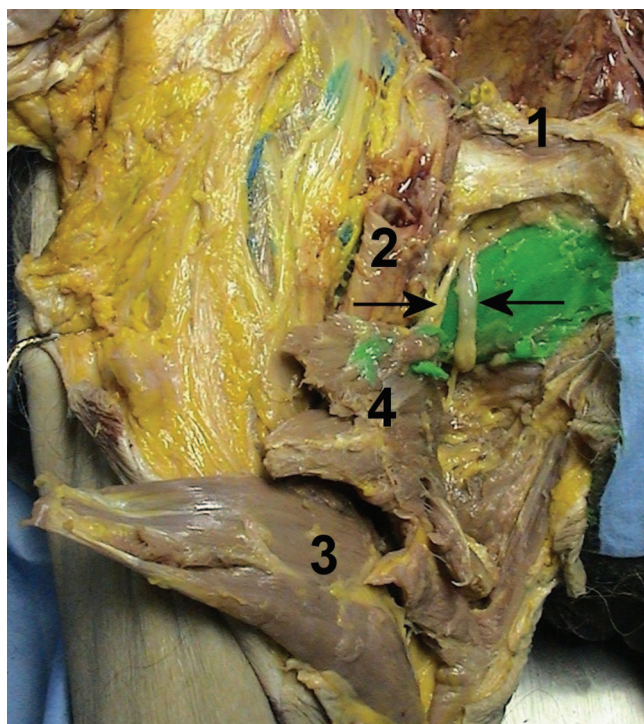
**Fig. 2.** Simulation of inguinal obturator nerve block in cadaver (*right side*). (A) Tuohy needle (16 gauge, 90 mm) inserted midway between the femoral artery and the inner border of the adductor longus tendon at the level of the inguinal crease. (B) Needle passing between the inferior border of the pectineus muscle and the superior border of the adductor longus muscle after resection of the skin and superficial fascia. (C) Needle in contact with branches of the anterior branch of the obturator nerve (*arrow*) after adductor longus muscle has been sectioned and removed. (D) Needle in contact with branches of the posterior branch of the obturator nerve (*arrow*) after adductor brevis muscle has been sectioned and removed. (1) Superior anterior iliac spine, (2) pubic tubercle, (3) inguinal ligament, (4) inguinal crease, (5) femoral artery, (6) sartorius muscle, (7) Gracilis muscle, (8) adductor longus muscle, (9) adductor brevis muscle.

The incidence of minor complications was significantly higher in the pubic group ( $P < 0.05$ ). Two puncture point bleedings, one aspiration of blood and one persistent groin pain, were noted in the pubic group. No

minor complications were noted in the inguinal group. No major complications were observed.

In no case was general anesthesia required to complete surgery. Additional intravenous analgesia or sedation





**Fig. 3.** Simulation of inguinal obturator nerve block by injection of latex into the cadaver. (→) Spread of the injectate to the anterior branch of the obturator nerve. (←) Spread of the injectate to the posterior branch of the obturator nerve; attains the level of the obturator foramen. (1) Inguinal ligament, (2) femoral artery, (3) adductor longus muscle, (4) adductor brevis muscle.

during surgery was required in two patients in the inguinal group and in three patients in the pubic group.

## Discussion

We have described a new approach for ONB in which the two branches of the obturator nerve are separately blocked using a nerve stimulator in the inguinal crease. This approach significantly decreases discomfort and pain during application of the block, the time taken and the number of bolus of sedatives or analgesics during ONB procedure to achieve a similar quality of sensory and motor blockade compared with the classic pubic tubercle approach, and the number of minor complications.

In our study, intravenous sedation, which may blunt

**Table 1.** Anthropometric Characteristics

	Inguinal Group (n = 25)	Pubic Group (n = 25)
Sex, M/F	11/14	14/11
ASA physical status, I/II/III	21/3/1	15/7/2
Body mass index, kg/m <sup>2</sup>	23.5 ± 3.44	24.1 ± 4.45
Age, yr	48 ± 17.60	51 ± 16.05

Data are presented as mean ± SD. No significant differences were observed.  
ASA = American Society of Anesthesiologists.

**Table 2.** VAS Pain Scores and Discomfort with the ONB, and Patients Receiving Intravenous Fentanyl and/or Propofol Bolus during ONB Placement

	Inguinal Group (n = 25)	Pubic Group (n = 25)	P Value
VAS obturator nerve block, mean ± SD	20 ± 14	40 ± 17*	< 0.001
Discomfort, 0/1/2†	15/10/0	4/12/9*	< 0.01
Propofol, No. of patients	3	2	NS
Fentanyl, No. of patients	2	3	NS
Both, No. of patients	1	8*	< 0.01
Total, No. of patients	6	13*	< 0.01

Data are presented as mean ± SD or number of patients.

\*  $P < 0.05$  vs. inguinal group. † 0 = no or mild discomfort; 1 = moderate discomfort; 2 = important discomfort.

NS = not significant; ONB = obturator nerve block; VAS = visual analog scale.

patient perception of pain, and analgesics, which may treat discomfort, were not administered before needle placement. By premedication with oral hydroxyzine before the application of the block, we could artificially exaggerate the difference in discomfort between groups. Standards for application of sedation and analgesic during peripheral nerve block seem lacking. Fanelli *et al.*<sup>23</sup> advocated the use of analgesic drugs in all patients undergoing multiple nerve stimulation block to decrease patient pain or discomfort and improve patient acceptance. Kinirons *et al.*<sup>24</sup> do not believe that all patients require sedation during a regional anesthesia procedure. In the inguinal group, few patients asked for sedatives and analgesics, and visual analog scale pain scores at the time of the block were significantly lower than those of the pubic group. The methodology was the same in the two groups, and the pubic tubercle approach was clearly more painful.

In 1967, Parks and Kennedy<sup>9</sup> stated that the medial cutaneous branch of the femoral nerve may supply innervation of the proximal medial thigh. They pointed out that one may be unable to demonstrate cutaneous loss of sensation after ONB and that test of motor function is necessary to ascertain the success of block. We have confirmed that the cutaneous distribution of obturator nerve cannot be assessed on the medial aspect of the thigh<sup>10-12</sup> and that the only way to evaluate obturator nerve function effectively is to assess adductor strength.<sup>10</sup> The adductor strength decreased by 60–65% 20 min after the injection of 1% mepivacaine in our study. Bouaziz *et al.*<sup>10</sup> reported a  $77 \pm 17\%$  decrease in strength 30 min after injection of 0.75% ropivacaine. Despite the fact that local anesthetic solution was administered at a level where the branches of the obturator nerve were already separated in the inguinal group, our experiment on cadavers and the absence of differences between both approaches suggest that both the anterior and the posterior branches of the obturator nerve had been impregnated. Forty-eight percent of our patients

**Table 3. Minimal Intensity of Stimulation, Needle Depth, Number of Needle Attempts, and Cutaneous Distribution with the Two Approaches to Obturator Nerve Block**

	Inguinal Group (n = 25)		Pubic Group (n = 25)
	Anterior Branch	Posterior Branch	
Minimal intensity of stimulation, mA	0.51 ± 0.20	0.56 ± 0.19	0.49 ± 0.19
Needle depth, mm	38 ± 9	45 ± 7	51 ± 13
Needle attempts and duration of puncture for both branches			
No. of needle attempts, median (25th–75th centiles)	2 (2–3)		3 (1–4)
Duration of puncture, median (25th–75th centiles), s	80 (60–120)		120 (90–180)*
Cutaneous distribution, n (%)			
None	11 (44)		13 (52)
Posterior aspect of knee	3 (12)		6 (24)
Medial aspect of knee	10 (40)		6 (24)
Medial aspect of knee and inferior thigh	1 (4)		0

\* Significantly different between the inguinal and pubic groups ( $P < 0.05$ ).

perceived no area of cutaneous anesthesia 20 min after injection. In half of the cases in our study, the cutaneous contribution of the obturator nerve was missing or overlapped by the femoral, posterior cutaneous, or sciatic nerve. The remaining patients described hypoesthesia either in the medial part of the knee or in the inner part of the popliteal fossa. Interestingly, the medial cutaneous aspect of the thigh was anesthetized in 100% of our patients after femoral nerve block. With an adequate assessment, the three-in-one block described by Winnie *et al.*<sup>25</sup> has proved to be more a two-in-one or solely a femoral block because the obturator nerve is almost always spared. This misnomer should not be used anymore.<sup>26</sup>

Selective blockade of the obturator nerve is not as common as other major peripheral nerve blocks (e.g., sciatic or femoral nerves). However, recent studies have demonstrated that separate ONB improves the quality of anesthesia for knee surgery<sup>13</sup> and analgesia after total knee arthroplasty.<sup>14,15</sup> Some practitioners are reluctant to perform an ONB using the pubic approach, which is reputed to be difficult. Moore<sup>27</sup> said that the block could be missed, even in the most expert hands. Wassef<sup>17</sup> studied the degree of patient discomfort with the pubic approach and found that 90% of patients reported moderate to severe discomfort. The inguinal approach described here is more acceptable to the patient because palpation and penetration of the mons pubis is avoided. Delineating the groove between the vascular bundle and adductor muscles, drawing only in the inner part of the thigh, and introducing the needle at the level of the inguinal crease probably improved patient acceptance. Preliminary contact and sliding off the pubic ramus is not necessary for the pubic approach with the aid of the nerve stimulator,<sup>28</sup> but inadvertent painful bone contact is common. With the inguinal approach, bone contact is unlikely. Fesenthal<sup>29</sup> asserted that the anterior and posterior divisions must be localized to accomplish an effective ONB to reduce spasticity. We chose to study two injections for the inguinal approach because the two

branches are separated by the adductor brevis muscle at this level. The inguinal approach, separately blocking both branches, resulted in faster performance than the classic approach. Some specific complications are likely with the traditional approach.<sup>30–33</sup> The risk of penetrating the pelvic cavity is present for both techniques. For the pubic approach, the needle may pass above the pubic ramus, particularly when identifying the pubic spine is difficult. Care must be taken not to advance the needle too far and to damage surrounding structures (e.g., bladder, rectum, spermatic cord).<sup>30,31</sup> Moreover, this approach is performed in a highly vascularized region. The obturator nerve crosses the obturator canal closed to the obturator vessels. The circumflex arteries and veins are in close proximity to the obturator foramen. Intravascular injection and hematoma may occur.<sup>32,33</sup> The vascular connections between the obturator and external iliac systems behind the pubic ramus (*i.e.*, corona mortis) can be life threatening in case of injury.<sup>34</sup> The puncture at a distance from the pelvis and large vessels in our inguinal approach could minimize the risk of complications and allows compression in the event of a hematoma. No adverse event was noted in our study.

Some limitations of our technique deserve comment. The main limitation is failure to reach obturator branches contributing to hip joint innervation, which arises frequently before entry of the nerve into the thigh. Second, the plasma concentrations of mepivacaine were not studied. Despite the fact that the plasma concentrations of local anesthetic were within reference range after bilateral ONB and higher doses of local anesthetic,<sup>35</sup> the total dose must be taken into consideration in the case of combined blocks.

In conclusion, the inguinal approach for ONB offers advantages. In our clinical experience, this technique was found to be easy, successful, and less painful than the pubic approach. The risk of complications seems very low. The efficacy and reliability when associated

with femoral and sciatic nerve block for knee procedures must be verified in a clinical study involving a greater number of patients. Furthermore, at the inguinal level, the anterior and posterior branches are only separated by the adductor brevis. An injection on a single branch could potentially achieve a complete block on both branches. Further comparative studies between single and double injection are necessary.

The authors thank Serge Nazarian, M.D. (Professor, Service de Thanatopraxie, Faculté de médecine de Marseille, Marseille, France), for his cooperation with this study.

## References

1. Bonicalzi V, Gallino M: Comparison of two regional anesthetic techniques for knee arthroscopy. *Arthroscopy* 1995; 11:207-12
2. Sansone V, De Ponti A, Fanelli G, Agostoni M: Combined sciatic and femoral nerve block for knee arthroscopy: 4 years' experience. *Arch Orthop Trauma Surg* 1999; 119:163-7
3. Casati A, Fanelli G, Beccaria P, Cappelleri G, Berti M, Aldegheri G, Torri G: The effects of the single or multiple injection technique on the onset time of femoral nerve blocks with 0.75% ropivacaine. *Anesth Analg* 2000; 91:181-4
4. Dennig L, Billich R, Buhle E: Die kombinierte ischiadicus/«3 in 1»-blockade im operativen routinebetrieb. *Reg Anaesth* 1987; 10:114-20
5. Ritter JW: Femoral nerve "sheath" for inguinal paravascular lumbar plexus block is not found in human cadavers. *J Clin Anesth* 1995; 7:470-3
6. Cauhepe C, Oliver M, Colombani R, Railhac N: Le bloc «3 en 1»: mythe ou réalité? *Ann Fr Anesth Reanim* 1989; 8:376-8
7. Marhofer P, Nasel C, Sitzwohl C, Kapral S: Magnetic resonance imaging of the distribution of local anesthetic during the three-in-one block. *Anesth Analg* 2000; 90:119-24
8. Atanassoff PG, Weiss BM, Brull SJ, Horst A, Kulling D, Stein R, Theiler I: Electromyographic comparison of obturator nerve block to three-in-one block. *Anesth Analg* 1995; 81:529-33
9. Parks CR, Kennedy WF Jr: Obturator nerve block: A simplified approach. *ANESTHESIOLOGY* 1967; 28:775-8
10. Bouaziz H, Vial F, Jochum D, Macalou D, Heck M, Meuret P, Braun M, Laxenaire MC: An evaluation of the cutaneous distribution after obturator nerve block. *Anesth Analg* 2002; 94:445-9
11. Lang SA, Yip RW, Chang PC, Gerard MA: The femoral 3-in-1 block revisited. *J Clin Anesth* 1993; 5:292-6
12. Parkinson SK, Mueller JB, Little WL, Bailey SL: Extent of blockade with various approaches to the lumbar plexus. *Anesth Analg* 1989; 68:243-8
13. Macaire P, Joubert C, Jochum D, Gaertner E, Choquet O: Should an obturator nerve block be combined to femoral and sciatic nerve blocks for knee surgery purposes? (abstract). *ANESTHESIOLOGY* 2003; 99:A1041
14. McNamee DA, Parks L, Milligan KR: Post-operative analgesia following total knee replacement: An evaluation of the addition of an obturator nerve block to combined femoral and sciatic nerve block. *Acta Anaesthesiol Scand* 2002; 46:95-9
15. Macalou D, Trueck S, Meuret P, Heck M, Vial F, Ouologuem S, Capdevila X, Virion JM, Bouaziz H: Postoperative analgesia after total knee replacement: The effect of an obturator nerve block added to the femoral 3-in-1 nerve block. *Anesth Analg* 2004; 99:251-4
16. Pauchet V, Sourdat P, Labat G, De Butler D'Ormont R: Anesthésie du Nerf Obturateur au Pli de l'Aïne, L'Anesthésie Régionale. Paris, Doin, 1927, pp 199-201
17. Wassef MR: Interadductor approach to obturator nerve blockade for spastic conditions of adductor thigh muscles. *Reg Anesth* 1993; 18:13-7
18. Kamina P, Santini JJ: Nerf obturateur, Anatomie Introduction à la Clinique—Nerfs des Membres. Paris, Maloine, 1997, pp 111-7
19. Gray H: Anatomy of the Human Body. Philadelphia, Lea & Febiger, 1918, chapter III/7, p IX.6
20. Netter FH: Atlas of Human Anatomy, 2nd edition. East Hanover, New Jersey, 1997, p 475
21. Sia S, Lepri A, Campolo MC, Fiaschi R, : Four-injection brachial plexus block using peripheral nerve stimulator: A comparison between axillary and humeral approaches *Anesth Analg* 2002; 95:1075-9
22. Koscielniak-Nielsen ZJ, Rasmussen H, Nielsen PT: Patients' perception of pain during axillary and humeral blocks using multiple nerve stimulations *Reg Anesth Pain Med* 2004; 29:328-32
23. Fanelli G, Casati A, Garancini P, Torri G: Nerve stimulator and multiple injection technique for upper and lower limb blockade: Failure rate, patient acceptance, and neurological complications. *Anesth Analg* 1999; 88:847-32
24. Kinirons BP, Bouaziz H, Paqueron X, Ababou A, Jandart C, Mai Cao M, Bur ML, Laxenaire MC, Benhamou D: Sedation with sufentanil and midazolam decreases pain in patients undergoing upper limb surgery under multiple nerve block. *Anesth Analg* 2000; 90:1118-21
25. Winnie AP, Ramamurthy S, Durrani Z: The inguinal paravascular technic of lumbar plexus anesthesia: The "3-in-1 block." *Anesth Analg* 1973; 52:989-96
26. Enneking FK, Chan V, Greger J, Hadzic A, Lang SA, Horlocker TT: Lower-extremity peripheral nerve blockade: Essentials of our current understanding. *Reg Anesth Pain Med* 2005; 30:4-35
27. Moore DC: Obturator nerve block. *Regional Block*, 4th edition. Edited by Moore DC. Springfield, Illinois, Charles C. Thomas, 1965, pp 289-93
28. Dalens B: Blocs du plexus lombaire et de ses branches, Anesthésie Locorégionale de la Naissance à l'Âge Adulte. Paris, Pradel, 1993, pp 325-52
29. Fesenthal G: Nerve block in the lower extremities: Anatomic considerations. *Arch Phys Med Rehabil* 1974; 55:504-7
30. Hong Y, O'Grady T, Lopresti D, Carlsson C: Diagnostic obturator nerve block for inguinal and back pain: A recovered opinion. *Pain* 1996; 67:507-9
31. Shulman MS, Vellayappan U, Monaghan TG, Coukos WJ, Krenis LJ: Simultaneous bilateral obturator nerve stimulation during transurethral electrovaporization of the prostate. *J Clin Anesth* 1998; 10:518-21
32. Akata T, Murakami J, Yoshinaga A: Life-threatening haemorrhage following obturator artery injury during transurethral bladder surgery: A sequel of an unsuccessful obturator nerve block. *Acta Anaesthesiol Scand* 1999; 43:784-8
33. Brown DL: Atlas of Regional Anesthesia. Philadelphia, WB Saunders, 1992, chapter 13, pp 103-8
34. Berberoglu M, Uz A, Ozmen MM, Bozkurt C, Erkuran C, Taner S, Tekin A, Tekdemir I: Corona mortis: An anatomic study in seven cadavers and an endoscopic study in 28 patients. *Surg Endosc* 2001; 15:72-5
35. Atanassoff PG, Weiss BM, Brull SJ: Lidocaine plasma levels following two techniques of obturator nerve block. *J Clin Anesth* 1996; 8:535-9