

Bruno Riou, M.D., Ph.D., Editor

Case Scenario: Neurologic Complication after Continuous Interscalene Block

Alain Borgeat, M.D., Ph.D.,* José Aguirre, M.D.,† Armin Curt, M.D., F.R.C.P.C.‡

A 33-YR-OLD woman, American Society of Anesthesiologists risk classification I, was referred for surgical treatment of left shoulder instability. Her medical history was unremarkable, but she had undergone two previous shoulder surgeries: anterior stabilization of left shoulder 3 yr ago followed by a posterior Bankart stabilization 2 yr later because of recurrent luxation and pain. At examination, she still complained about pain in her left shoulder, and movement was severely limited. A left Bankart operation and capsulotomy were scheduled.

A preoperative interscalene catheter was placed according to the modified lateral approach.¹ The interscalene brachial plexus was identified using a nerve stimulator (Stimuplex® HNS II, B. Braun Melsungen AG, Melsungen, Germany) connected to the proximal end of the metal inner part of a short beveled needle. A contraction of the deltoid muscle was observed with a current output of 0.35 mA, with an impulse duration of 0.1 ms. The insertion of the perineural catheter was performed using the cannula-over-needle technique with a plastic cannula (Polymedic®, Polyplex N-50 T, 20 gauge external diameter, te me na, Bondy, France). The catheter was introduced distally between the anterior and middle scalene muscle up to 3 cm. A bolus of 30 ml ropivacaine (0.5%) was administered, and the procedure was uneventful. No pain, dysesthesias, or paresthesias occurred at any time. Fifteen minutes later, a complete sensorimotor block of the left arm was observed. Then, general anesthesia with target-controlled infusion (TCI Diprifusor, SIMS Graseby Ltd., Watford, Herts, United Kingdom) of propofol and remifen-

tanil was administered. The patient was positioned in the beach chair for surgery. The procedure lasted 3 h 30 min and was described by the surgeon as difficult. Postoperative analgesia was performed with patient-controlled interscalene analgesia using ropivacaine (0.2%) and was started 4 h after the end of the surgery. The pump settings were basal rate of 5 ml/h with supplementary boli of 4 ml for every 20 min. The patient was pain free, and the patient-controlled interscalene analgesia was stopped after 54 h. Even after 36 h of termination of patient-controlled interscalene analgesia, no motor or sensory recovery was observed. An ultrasonography of the brachial plexus was performed to exclude a hematoma and revealed no irregular finding.

A complete neurologic examination including neurophysiologic recordings on the following day (72 h after surgery) demonstrated a motor and sensory incomplete lesion of nerve fibers originating from the upper brachial plexus (involving the following muscles: deltoid M0/5, biceps M0/5, and triceps M3/5). Motor nerve conduction studies (figs. 1 and 2) and somatosensory-evoked potentials (SSEPs) of the median and ulnar nerves that originate from the lower brachial plexus revealed normal recordings. Electromyography at the initial examination did not show signs of denervation (fibrillation or positive waves) but resulted in complete paralysis (no retrievable voluntary electromyography activity). The later finding at this early stage after injury can be in line with a neurapraxia (conduction failure) or axonotmesis (structural neural damage). Eventually, 1 month later, at the first follow-up, electromyographies showed signs of denervation most severe within the deltoid and biceps muscles, disclosing objective signs of neural damage (fig. 3) congruent to the clinical condition in which no motor improvement was observed.

Six months later, although no clinical improvement occurred, a surgical exploration was performed that revealed no pathologic findings. At this time, a perioperative stimulation of the trunks of the brachial plexus elicited reliable responses for the three trunks. In repeated electromyographic recordings during a period of 2 yr, increasing signs of motor recovery could be observed, although the patient still demonstrated severe proximal muscle weakness that could not be

* Professor and Chief-of-Staff, † Consultant, Department of Anesthesiology, ‡ Professor and Chairman, Spinal Cord Injury Center, University of Zurich, Balgrist University Hospital, Zurich, Switzerland.

Received from the Department of Anesthesiology, Balgrist University Hospital, Zurich, Switzerland. Submitted for publication July 8, 2009. Accepted for publication December 11, 2009. Support was provided solely from institutional and/or departmental sources.

Address correspondence to Dr. Borgeat: Department of Anesthesiology, Balgrist University Hospital, Forchstrasse 340, 8008 Zurich, Switzerland. alain.borgeat@balgrist.ch. Information on purchasing reprints may be found at www.anesthesiology.org or on the masthead page at the beginning of this issue. ANESTHESIOLOGY's articles are made freely accessible to all readers, for personal use only, 6 months from the cover date of the issue.

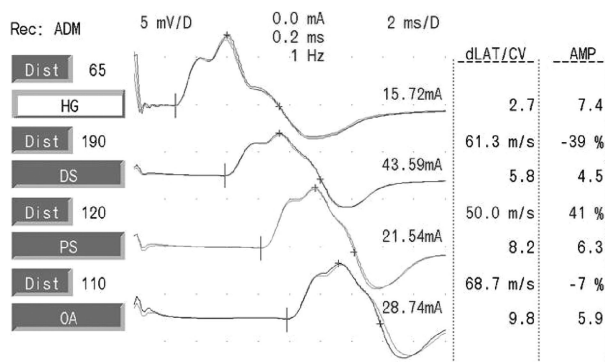


Fig. 1. Nerve conduction study performed 72 h after surgery of the ulnar nerve with stimulations at the wrist (HG), distal (DS), and proximal (PS) of the sulcus ulnaris and upper arm (OA) and regular responses (CMAP). This tracing did not reveal any abnormality. AMP = amplitude muscle potential; ADM = abductor digiti minimi; dLAT = distal latency.

explained by the neurophysiologic testing. Eventually, a psychiatric evaluation suggested a hysterical conversion reaction. Two years later, the patient's clinical outcome did not improve. Her social and professional situations have dramatically worsened. The diagnosis of hysterical conversion could not have been confirmed because a recovery (arm movement) is necessary to support it. This case shows the complexity a psychiatric component superimposes on a neurologic complication. Indeed, the latter shows objective signs of nerve repair without corresponding clinical improvement.

Epidemiologic Note

Recent prospective studies using electroneuromyographic investigations looking at this complication 1 yr after the block have shown that the incidence of severe (sensorimotor

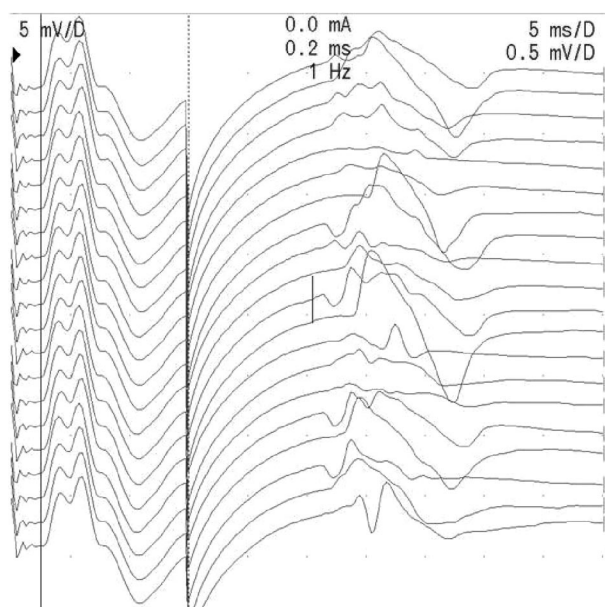


Fig. 2. F-wave recordings performed 72 h after surgery of ulnar nerve with regular latency (25.5 ms) and high persistence (90%). This tracing did not reveal any abnormality.

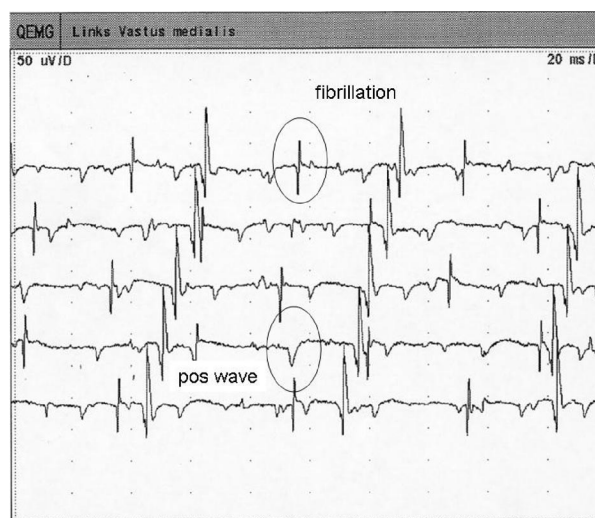


Fig. 3. Electromyographic recording performed 1 month after surgery showing signs of acute neurogenic denervation with positive waves¹ and fibrillations² (circle). QEMG = electromyography.

deficit lasting >6 months) neurologic complication is between 0.2 and 0.4%.²⁻⁷ Interestingly, investigations in orthopedic literature have reported an incidence of 3.6% in patients having no block but only general anesthesia.^{8,9}

Comments from the Neurophysiologist

Timing

In acute peripheral nerve damage, SSEPs that are transmitted by related nerve fibers would become immediately deteriorated but remained normal in this case because only upper parts of the cervical plexus had been affected (ulnar and median SSEP become deteriorated in lesions of the lower cervical plexus). The same is true for the nerve conduction studies of the median and ulnar nerves, which are not affected in upper cervical plexus disorders. In this case, they also proved that no general preexisting neuropathy within the upper limb has been present. Electromyographic recordings of the proximal shoulder muscles revealed no signs of chronic (*i.e.*, preexisting) nerve damage but disclosed a complete acute paralysis of proximal muscles because no voluntary activation could be recorded. Eventually, signs of denervation appeared and could quantify the extent of nerve damage.

Although in some of the typical findings, specifically in **electromyography** (signs of denervation) and **nerve conduction** studies, reduction or loss of compound muscle action potential are **delayed by about 21 or 10 days**, respectively, the immediate neurophysiologic examination can distinguish between findings related to presurgical/preexisting nerve damage and induced acute lesions. The **delay** in responsiveness is due to the effects of **Wallerian degeneration** (Wallerian degeneration is a **time-dependent** process within the nerve fibers of axonal degeneration that typically propagates **from the proximal** lesion site to the **peripheral nerve** endings revealing signs of denervation with a delay that is dependent

on the distance between lesion and recording site) that take time to occur and become obvious at the distal nerve endings and effector organs (*i.e.*, muscles). However, several tests are actually not sensitive to the time after injury and reveal very early reliable findings, specifically SSEP, motor-evoked potential, and reflex (F wave) studies.

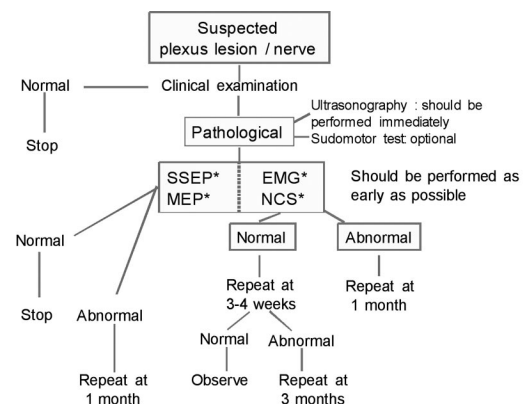
Comprehensive Testing

Neural damage is mostly rather complex and can affect different types of nerve fibers to a different extent. Therefore, an appropriate combination of sensory and motor nerve testing is advisable. In addition, the distinction between nerve function damage at central (spinal cord) and peripheral (radicular, plexus, and peripheral nerves) neural structures should be addressed. It is important to acknowledge that not all nerve fibers can be recorded to the same extent. Nerve fibers of the lower brachial plexus innervating the forearm and hand muscles are thoroughly testable by combined nerve conduction studies, SSEPs, and motor-evoked potential recordings of the median, radial, and ulnar nerves. However, the neurophysiologic assessment of proximal muscles originating from the upper brachial plexus is rather restricted to electromyographic studies because the related nerve fibers are not easily accessible. In assumed disorders of the upper brachial plexus, the assessment of the median and ulnar nerves is primarily directed to proof the integrity of lower parts of the brachial plexus and to exclude signs related to a preexisting and unrelated neuropathy. Only the combination of several neurophysiologic assessments is able to comprehensively investigate the plexus function and finally to suggest a potential hysterical conversion when severe limb paralysis, which is in contradiction of otherwise normal neurophysiologic recordings, is presented.

Follow-up Recordings

In some of the testing (electromyography and nerve conduction studies), the findings of nerve damage are sensitive to time and will show the full extent of neural damage thereafter. Furthermore, the course of changes will inform about the severity and the potential for recovery. Depending on the level of lesion and density of damage, this time period can last up to 2 yr to assess and reliably preclude on the further recovery to be expected. Follow-up recordings allow to definitively estimate the extent of axonal damage (extent of denervation) and eventual peripheral regeneration (polyphasic and prolonged motor unit potentials), whereas measures that stimulate proximal to the potential injury site can be applied to diagnose neuropraxia. In the latter condition, the response to stimulation distal of the injury site remains unaffected.

The applied neurophysiologic techniques refer to standard procedures in clinical neurophysiology.^{10–12} Based on the characteristics of the neuropathy (axonal, demyelinating, sensory, and motor), the electromyographer can direct the clinician toward suspected causes for the neuropathy (fig. 4).



* The choice of the examination will be done according to clinical condition and neurophysiologist's recommendations

Fig. 4. Algorithm recommended to be performed in case of suspected plexus/nerve lesion. EMG = electromyography; MEP = motor-evoked potential; NCS = nerve conduction study; SSEP = somatosensory-evoked potential.

The severity of the damage also has direct implication for the recovery (fig. 5).

Basic Sciences

Preclinical research regarding peripheral nerve repair and α -motoneurone regeneration is advancing into interventions that build on the development of novel and more permissive artificial nerve conduits and identification of specific neurotrophic factors. In models of peripheral nerve crush injury, the expression of specific neurotrophic factors (*e.g.*, glial cell line-derived neurotrophic factor) is related to improved regeneration, although the most potent factors need to be defined, and the optimal timing of application is yet to be determined. In addition to these approaches, mechanisms involved in the inhibition of optimal peripheral neural regeneration become increasingly identified (*e.g.*, inhibitory chondroitin sulfate proteoglycans may be cleaved by chondroitinase ABC) and, most likely, in combination with neurotrophic factors or other specific training interventions (*i.e.*, functional electrical stimulation) present novel promis-

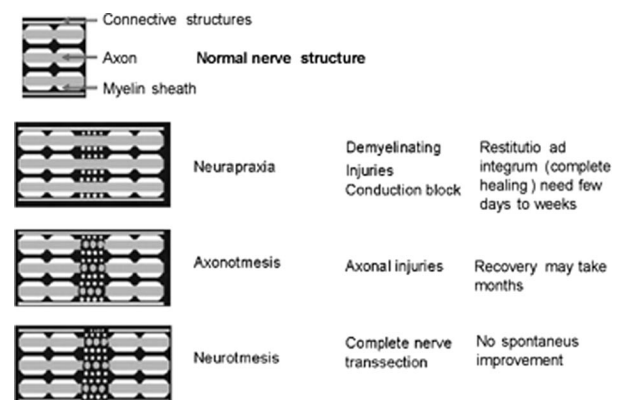


Fig. 5. Neuropraxia involves damage to the myelin sheath, axonotmesis involves damage to the myelin sheath, and the axon and neurotmesis (transection) involves damage to all nerve structures including the connective structures.

ing approaches to increase peripheral nervous system regeneration. In this context, the improvement of artificial nerve conduits and the advanced understanding of neurobiological mechanisms (gene expression, neurotrophic factors, and inhibitory molecules) involved in peripheral nerve reconstruction may also offer new opportunities in bridging nerve defects.

Knowledge Gap and Research Perspectives

To date, there is no pharmacologic treatment that has been proven to increase and effectively stimulate peripheral nerve regeneration. Adjusted physiotherapy to avoid muscle atrophy and preserve range of motion of paralyzed joints and treatment of neuropathic pain remain the cornerstones of medical treatment.

It is not well enough appreciated that peripheral nerve repair is not easily achieved to a high functional level, although there is a much higher extent of neuron survival, neuritis outgrowth, and increased remyelination in the peripheral than in the central nervous system. Regenerating motor nerve fibers have the potential to arborize and travel across nerve stumps as being induced by damage but need to be directed to avoid misconnections (pruning theory). This is dependent on neural trophic factors to promote neural survival and proliferation and targeting appropriate end-organ connections. In this context, functional electric stimulation has been shown in animal studies to provide beneficial effects on motor nerve fibers, and α -motoneurons¹³⁻¹⁶ is considered a potential tool in improving peripheral nerve repair and functional restoration. Although several studies in animals demonstrated that required effects on growth factors and gene transcription can be induced by functional electric stimulation, the clinical value remains unclear. There is some evidence that well-controlled functional electric stimulation is supportive to build muscle volume and prevents extensive muscle atrophy (so far no adverse effects on neural repair became obvious). However, the impact on neural repair that can be immediately translated into functional improvement remains speculative.

References

1. Borgeat A, Ekatodramis G: Anaesthesia for shoulder surgery. *Best Pract Res Clin Anaesthesiol* 2002; 16:211-25
2. Borgeat A, Dullenkopf A, Ekatodramis G, Nagy L: Evaluation of the lateral modified approach for continuous interscalene block after shoulder surgery. *ANESTHESIOLOGY* 2003; 99:436-42
3. Borgeat A, Ekatodramis G, Kalberer F, Benz C: Acute and nonacute complications associated with interscalene block and shoulder surgery: A prospective study. *ANESTHESIOLOGY* 2001; 95:875-80
4. Capdevila X, Pirat P, Bringuier S, Gaertner E, Singelyn F, Bernard N, Choquet O, Bouaziz H, Bonnet F: Continuous peripheral nerve blocks in hospital wards after orthopedic surgery: A multicenter prospective analysis of the quality of postoperative analgesia and complications in 1,416 patients. *ANESTHESIOLOGY* 2005; 103:1035-45
5. Tsui BC, Pillay JJ, Chu KT, Dillane D: Electrical impedance to distinguish intraneural from extraneural needle placement in porcine nerves during direct exposure and ultrasound guidance. *ANESTHESIOLOGY* 2008; 109:479-83
6. Welch MB, Brummett CM, Welch TD, Tremper KK, Shanks AM, Guglani P, Mashour GA: Perioperative peripheral nerve injuries: A retrospective study of 380,680 cases during a 10-year period at a single institution. *ANESTHESIOLOGY* 2009; 111:490-7
7. Prielipp RC, Warner MA: Perioperative nerve injury: A silent scream? *ANESTHESIOLOGY* 2009; 111:464-6
8. Lynch NM, Cofield RH, Silbert PL, Hermann RC: Neurologic complications after total shoulder arthroplasty. *J Shoulder Elbow Surg* 1996; 5:53-61
9. Wirth MA, Rockwood CA Jr.: Complications of total shoulder-replacement arthroplasty. *J Bone Joint Surg Am* 1996; 78:603-16
10. Guerit JM, Amantini A, Amodio P, Andersen KV, Butler S, de Weerd A, Facco E, Fischer C, Hantson P, Jantti V, Lamblin MD, Litscher G, Pereon Y: Consensus on the use of neurophysiological tests in the intensive care unit (ICU): Electroencephalogram (EEG), evoked potentials (EP), and electroneuromyography (ENMG). *Neurophysiol Clin* 2009; 39:71-83
11. Kim DH, Kang YK, Hwang M, Kwon HK, Lee HJ, Kim BG: Reference values of fractionated neurography of the ulnar nerve at the wrist in healthy subjects. *Clin Neurophysiol* 2005; 116:2853-7
12. Stalberg E, Fuglsang-Frederiksen A, Bischoff C: Quantitation and standardization in EMG and neurography. *Suppl Clin Neurophysiol* 2000; 53:101-11
13. Udina E, Furey M, Busch S, Silver J, Gordon T, Fouad K: Electrical stimulation of intact peripheral sensory axons in rats promotes outgrowth of their central projections. *Exp Neurol* 2008; 210:238-47
14. Lu MC, Tsai CC, Chen SC, Tsai FJ, Yao CH, Chen YS: Use of electrical stimulation at different current levels to promote recovery after peripheral nerve injury in rats. *J Trauma* 2009; 67:1066-72
15. Gordon T, Amirjani N, Edwards DC, Chan KM: Brief electrical stimulation accelerates axon regeneration in the peripheral nervous system and promotes sensory axon regeneration in the central nervous system. *Motor Control* 2009; 13:412-41
16. Asensio-Pinilla E, Udina E, Jaramillo J, Navarro X: Electrical stimulation combined with exercise increase axonal regeneration after peripheral nerve injury. *Exp Neurol* 2009; 219:258-65