

## Lower-Extremity Peripheral Nerve Blockade: Essentials of Our Current Understanding

F. Kayser Enneking, M.D., Vincent Chan, M.D., Jenny Greger, M.D., Admir Hadžić, M.D., Ph.D., Scott A. Lang, B.Sc., M.D., F.R.C.P.C., and Terese T. Horlocker, M.D.

**T**he American Society of Regional Anesthesia and Pain Medicine introduced an intensive workshop focused on lower-extremity peripheral nerve blockade in 2002. This review is the compilation of that work. Details concerning the techniques described in this text are available at the web site ASRA.com, including video demonstrations of the blocks. Lower-extremity peripheral nerve blocks (PNBs) have never been as widely taught or used as other forms of regional anesthesia. Unlike the upper extremity, the entire lower extremity cannot be anesthetized with a single injection, and injections are generally deeper than those required for upper extremity block. In addition, neuraxial techniques are widely taught and use alternative methods for providing reliable lower-extremity anesthesia. Over the past decade, several developments have led to an increased interest in lower extremity PNBs, including transient neurologic symptoms associated with spinal anesthesia, increased risk of epidural hematoma with the introduction of antithromboembolic prophylaxis regimens, and evidence of improved rehabilitation outcome with continuous lower-extremity PNBs. This review will focus on the anatomy of the lumbosacral plexus and its terminal nerves, followed by

a discussion of techniques and applications. In addition, we will review neural localization techniques and potential complications.

### Lower-Extremity Peripheral Nerve Anatomy

Lower-extremity PNB requires a thorough understanding of the neuroanatomy of the lumbosacral plexus. Anatomically, the lumbosacral plexus consists of 2 distinct entities: the lumbar plexus and the sacral plexus. There is some communication between these plexi via the lumbosacral trunk, but for functional purposes these are distinct entities.<sup>1</sup> Details of the motor and sensory branches of the lumbosacral plexus are summarized in [Tables 1 and 2](#) and [Figures 1 and 2](#). The lumbosacral plexus arises from at least 8 spinal nerve roots, each of which contains anterior and posterior divisions that innervate the embryologic ventral or dorsal portions of the limb. With the exception of a small cutaneous portion of the buttock (which is supplied by upper lumbar and sacral segmental nerves), the innervation of the lower extremity is entirely through branches of the lumbosacral plexus. The nerves to the muscles of the anterior and medial thigh are from the lumbar plexus. The muscles of the buttocks, the posterior muscles in the thigh, and all the muscles below the knee are supplied by the sacral plexus. There are a multitude of approaches to each peripheral nerve block described for the lower extremity. Thus, a detailed review of the course of each of the relevant terminal peripheral nerves of the lower extremity is warranted in this review.

### Lumbar Plexus Anatomy

The lumbar plexus is formed within the psoas muscle from the anterior rami of T12-L4.<sup>1-4</sup> The branches of this plexus, the iliohypogastric, ilioinguinal, genitofemoral, lateral femoral cutaneous,

---

From the Department of Anesthesiology, University of Florida College of Medicine, Gainesville, FL (F.K.E.); Regional Anesthesia and Acute Pain Service, University Health Network, University of Toronto, Ontario, Canada (V.C.); Greater Houston Anesthesia, Houston, TX (A.H.); Department of Anesthesiology, St Luke's/Roosevelt Hospital Center, New York, NY (J.G.); Department of Anesthesia, University of Calgary, Calgary, Alberta, Canada (S.A.L.); and Department of Anesthesia, Mayo Clinic, Rochester, MN.

Accepted for publication October 13, 2004.

Reprint requests to F. Kayser Enneking, M.D., Department of Anesthesiology, PO Box 100254, Gainesville, FL 32610-0254. E-mail: [kenneking@anest.ufl.edu](mailto:kenneking@anest.ufl.edu)

© 2005 by the American Society of Regional Anesthesia and Pain Medicine.

1098-7339/05/3001-0002\$30.00/0

doi:10.1016/j.rapm.2004.10.002

**Table 1. Lumbar Plexus Anatomy**

Nerve	Spinal Segment	Motor Innervation	Motion Observed*	Sensory Innervation	Articular Branches
Iliohypogastric	T12-L1	Int/ext oblique	Ant abdominal wall	Inferior abd wall	None
Ilioinguinal	L1	Transverse abdominis Int oblique	Ant abdominal wall	Upper lat quadrant of buttock Inferior to medial aspect of inguinal ligament Portion of genitalia	None
Genitofemoral	L1-L2	Cremaster	Testicular	Inferior to mid portion of inguinal ligament Spermatic cord	None
Lateral Femoral Cutaneous	L2-L3	None		Anterior lateral and posterior aspects of thigh terminating in prepatellar plexus	
Femoral Anterior division	L2-L4	Sartorius	Medial aspect of the lower thigh	Anterior medial skin of the thigh	None
Posterior division		Pectineus Quadriceps Saphenous	Adductor of thigh Knee extension, patellar ascension	None Ant thigh Medial leg from the tibia to the medial aspect of the foot	Hip and knee
Obturator Anterior division	L2-L4	Gracilis, adductor brevis & longus pectineus	Thigh adduction	Variable, posterior medial thigh, medial knee	Hip
Posterior division		Obturator externus, adductor magnus	Thigh adduction with lateral hip rotation		Knee

Abbreviations: Int, internal; Ext, external; Ant, anterior; Abd, abdominal; Lat, lateral.

\*Motion observed refers to the observed motor response with electrical stimulation of that nerve.

and femoral and obturator nerves emerge from the psoas laterally, medially, and anteriorly (Figs 2 and 3). Of these, the femoral, lateral femoral cutaneous, and obturator nerves are most important for lower-extremity surgery.

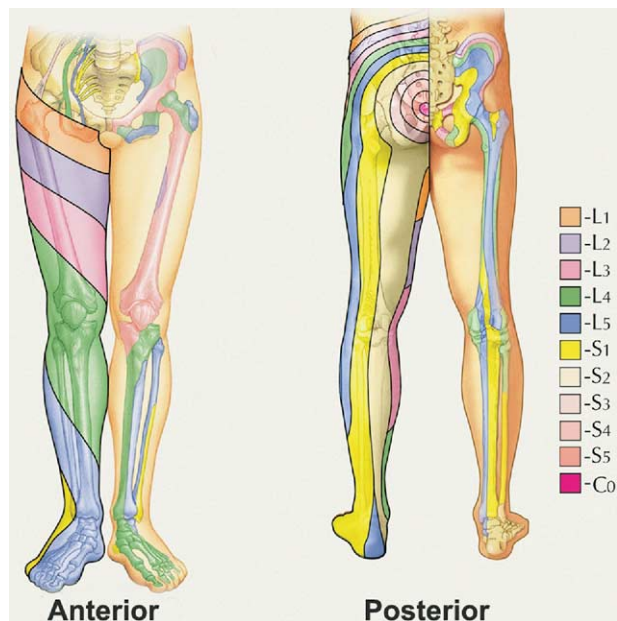
**Femoral Nerve.** The femoral nerve is formed by the dorsal divisions of the anterior rami of the second, third, and fourth lumbar nerves. The femoral nerve emerges from the psoas muscle in a fascial compartment between the psoas and iliacus

**Table 2. Sacral Plexus Anatomy**

Nerve	Spinal Segment	Motor Innervation	Motion Observed*	Sensory Innervation	Articular Branches
Gluteal nerves	L4-S2	Piriformis, sup/inf gemellus obturator internus, quadratus femoris	Buttocks with lat hip rotation	Upper medial aspect of buttock	Hip
Sciatic, tibial	L4-S3	Biceps femoris, semitendinosus, adductor magnus Popliteus Gastrocnemius, soleus, flexors of foot	Hamstrings with knee extension Knee flexion Plantar flexion Toe flexion	Medial and lat heel Sole of foot	Hip knee, and ankle
Sciatic, peroneal Superficial	L4-S3	Short head of biceps femoris peroneus longus, brevis	Knee flexion Foot inversion	Distal anterior leg, dorsum of foot	Knee and ankle
Deep		Extensors of foot, toes	Dorsiflexion of foot, ankle	Web space of 1 <sup>st</sup> toe	Ankle
Sural	None	None	None	None	
Components from peroneal & tibial			Post calf, lat border of foot and 5 <sup>th</sup> toe	None	
Post cut nerve of thigh	S1-S3	None	None	Distal medial quadrant of buttock perineum, post thigh including popliteal fossa	None

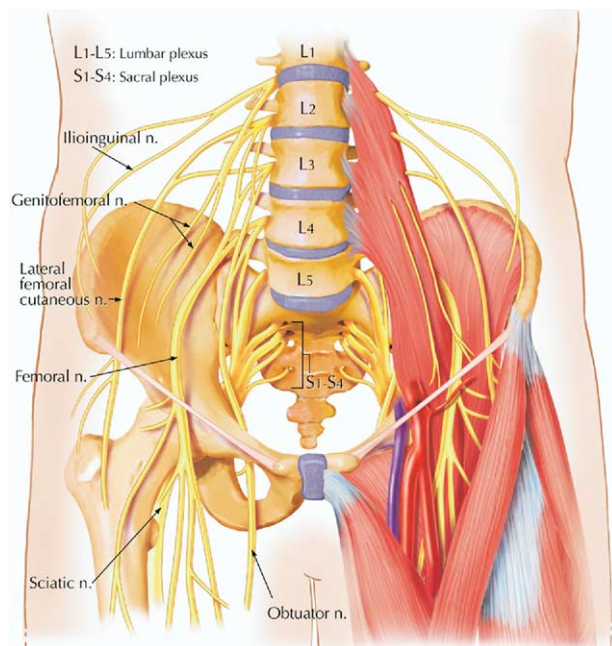
Abbreviations: Sup, superior; Inf, inferior; Lat, lateral; Post, posterior; Cut, cutaneous.

\*Motion observed refers to the observed motor response with electrical stimulation of that nerve.

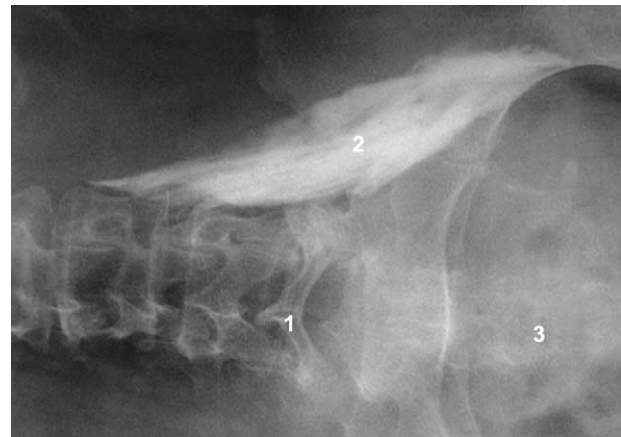

**Fig 1.** Dermatomes and osteotomes of the lumbosacral plexus are illustrated. (Courtesy of Mayo Foundation.)

muscles, in which it gives off articular branches to the hip. It enters the thigh posterior to the inguinal ligament. There it lies lateral and posterior to the femoral artery. This relationship to the femoral artery exists near the inguinal ligament, but not after the nerve enters the thigh. As the nerve passes into the thigh, it divides into an anterior and a posterior



**Fig 2.** Lumbosacral plexus. Anatomic depiction of the lumbosacral plexus with the major peripheral nerves of the lower extremity. (Courtesy of Mayo Foundation.)



**Fig 3.** A contrast radiograph after lumbar plexus block injection. The radiograph shows a typical oblique descent of the lumbar plexus branches into the pelvis contained within the iliopsoas muscle: 1, spinous processes outlining midline; 2, dispersion of radiopaque dye; 3, pelvis.

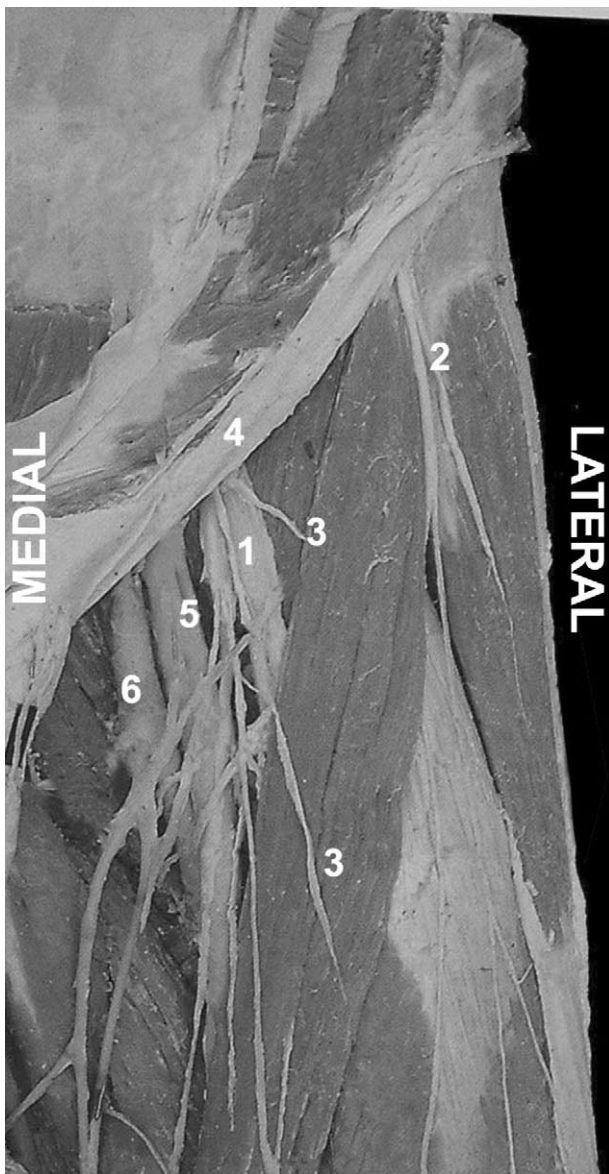
division and quickly arborizes (Fig 4). At the level of the inguinal ligament, there are dense fascial planes, the fascia lata, and fascia iliaca. The femoral nerve is situated deep to these fascial planes. The femoral artery, vein, and lymphatics reside in a separate fascial compartment medial to the nerve.

The anterior division of the femoral nerve gives off the medial and intermediate cutaneous nerves that supply the skin of the medial and anterior surfaces of the thigh. The muscular branches of the anterior division of the femoral nerve supply the sartorius muscle and the pectineus muscle and articular branches to the hip. The posterior division of the femoral nerve gives off the saphenous nerve, which is the largest cutaneous branch of the femoral nerve, and the muscular branches to the quadriceps muscle and articular branches to the knee.

The terminal nerves of the posterior division of the femoral nerve, the saphenous and the vastus medialis nerves, continue distally through the adductor canal. After leaving the adductor canal, the saphenous nerve emerges from behind the sartorius muscle, in which it gives off an infrapatellar branch and then continues distally to supply the cutaneous innervation of the anteromedial lower leg down to the medial aspect of the foot.

**Obturator Nerve.** The obturator nerve is a branch of the lumbar plexus formed within the substance of the psoas muscle from the anterior division of the second, third, and fourth lumbar nerves. It is the nerve of the adductor compartment of the thigh, which it reaches by piercing the medial border of the psoas and passing straight along the sidewall of the pelvis to the obturator foramen. After entering the thigh through the obturator





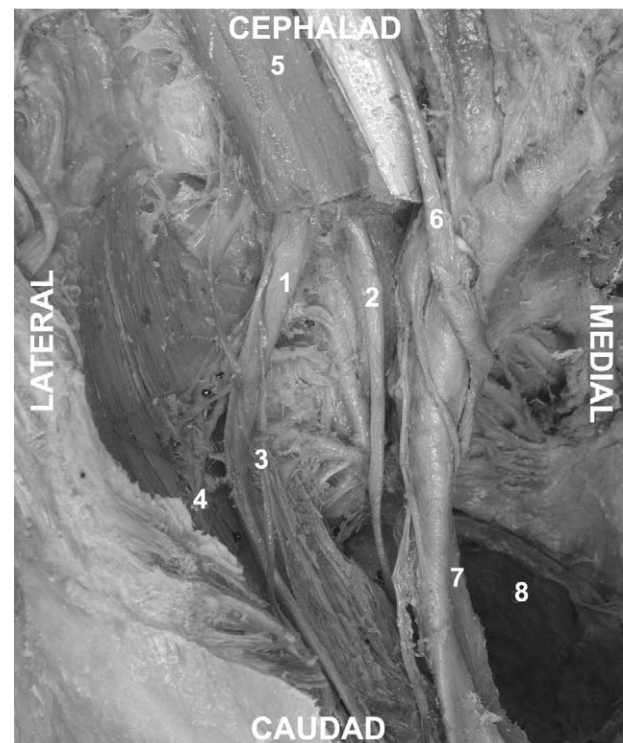
**Fig 4.** Anatomy of the femoral nerve in the inguinal area: 1, femoral nerve; 2, lateral femoral cutaneous nerve; 3, branches of the femoral nerve to the sartorius muscle; 4, inguinal ligament; 5, femoral artery; 6, femoral vein.

groove, the nerve divides into an anterior and posterior division. The anterior division has three branches including the muscular branches to the adductor muscles, an articular branch to the hip joint, and a cutaneous branch to the medial side of the thigh. The extent of this cutaneous sensory innervation has been investigated by Bouaziz et al.<sup>5</sup> These investigators performed an isolated obturator nerve block on patients before a femoral nerve block. All the obturator nerve blocks were successful as shown by adductor paresis. In 57% of the patients, there was no cutaneous sensory loss de-

monstrable. In 23% of patients, a zone of hypoaesthesia was present on the superior medial aspect of the popliteal fossae. Only 20% of the patients showed a sensory deficit on the inferior aspect of the medial thigh. The inconsistency of the sensory distribution of the obturator nerve must be considered when evaluating reports of obturator nerve block success rates based on sensory findings only.

The posterior division of the obturator nerve descends with the femoral and popliteal artery to the knee joint, and forms 2 branches: a muscular branch to the external obturator and adductor magnus muscles and an articular branch to the knee. The divergence of the obturator nerve from the femoral nerve begins as they emerge from the substance of the psoas muscle. At the level of the inguinal ligament, the obturator nerve lies deep and medial relative to the femoral nerve and is separated from it by several fascial compartments. This separation at the level of the inguinal ligament is obvious in anatomic dissections (Fig 5)<sup>6</sup> and has also been shown both radiographically with contrast and by magnetic resonance image.<sup>7,8</sup>

**Lateral Femoral Cutaneous Nerve.** The lateral femoral cutaneous nerve is formed by union of



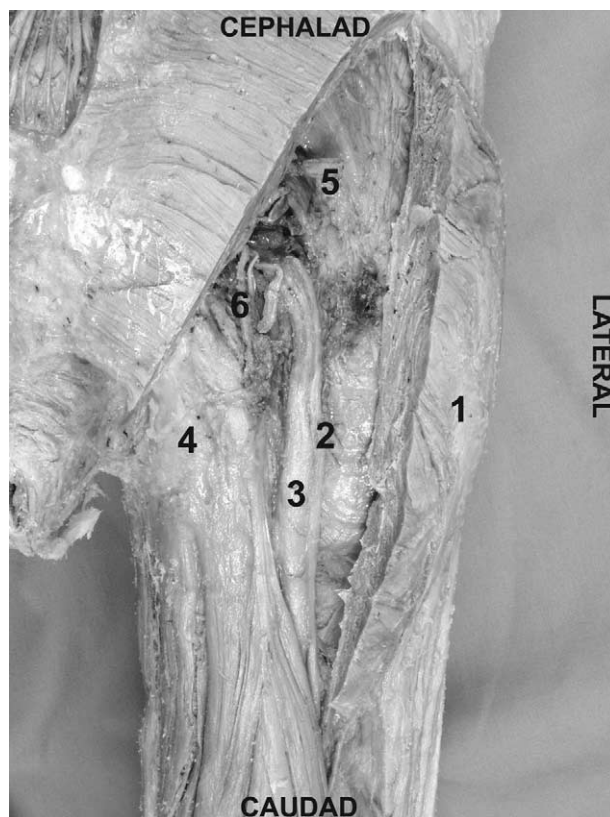
**Fig 5.** Organization of the lumbar plexus components at the level of the inguinal ligament: 1, femoral nerve; 2, obturator nerve; 3, genitofemoral nerve; 4, lateral femoral cutaneous nerve; 5, psoas muscle; 6, ureter; 7, iliacus nerve and vein; 8, rectum.

fibers from the posterior division of the anterior primary rami of L2 and L3. It emerges from the lateral border of psoas major below the iliolumbar ligament, passing around the iliac fossa on the surface of the iliacus muscle deep to the iliac fascia. Above the inguinal ligament, it slopes forward and lies inside the fibrous tissue of the iliac fascia. It perforates the inguinal ligament approximately 1 cm from the anterior superior iliac spine from where it enters the thigh. The lateral femoral cutaneous nerve supplies the parietal peritoneum of the iliac fascia and the skin over a widely variable aspect of the lateral and anterior thigh.<sup>9</sup> It has no motor innervation.

### Sacral Plexus Anatomy

The sacral plexus is formed within the pelvis by the merger of the ventral rami of the fourth and fifth lumbar and the first 3 or 4 sacral nerves. The fourth and fifth lumbar ventral rami are common to both the lumbar and the sacral plexus and the lumbosacral trunk.<sup>10</sup> Of the 12 branches of the sacral plexus, 5 are distributed within the pelvis and the other 7 emerge from the pelvis to distribute to the buttock and the lower extremity. The sacral plexus provides motor and sensory innervation to portions of the entire lower extremity including the hip, knee, and ankle. The most important components of the sacral plexus for lower-extremity surgery are the sciatic and the posterior cutaneous nerves and their terminal branches.

**Sciatic Nerve.** The lumbosacral trunk (L4-L5) and anterior divisions of the sacral plexus (S1-S3) merge to form the tibial nerve, whereas the posterior divisions merge to form the common peroneal nerve. These 2 large mixed nerves of the sacral plexus are initially bound together by connective tissue to form the sciatic nerve. At this level, the tibial component is medial and anterior, whereas the common peroneal component is lateral and slightly posterior (Fig 6). The superior gluteal artery is immediately superior and medial to the sciatic nerve at the level of the piriformis. Doppler identification of the superior gluteal artery has been used to help identify appropriate needle insertion site during sciatic nerve block.<sup>11</sup> The sciatic nerve exits the pelvis via the greater sciatic notch below the piriformis muscle.<sup>12</sup> At this level, it lies lateral and posterior to the ischial spine. As it enters the thigh and descends toward the popliteal fossa, it is posterior to the lesser trochanter of the femur, on the posterior surface of the adductor magnus muscle within the posterior medial thigh compartment deep to biceps femoris. There is no artery after a

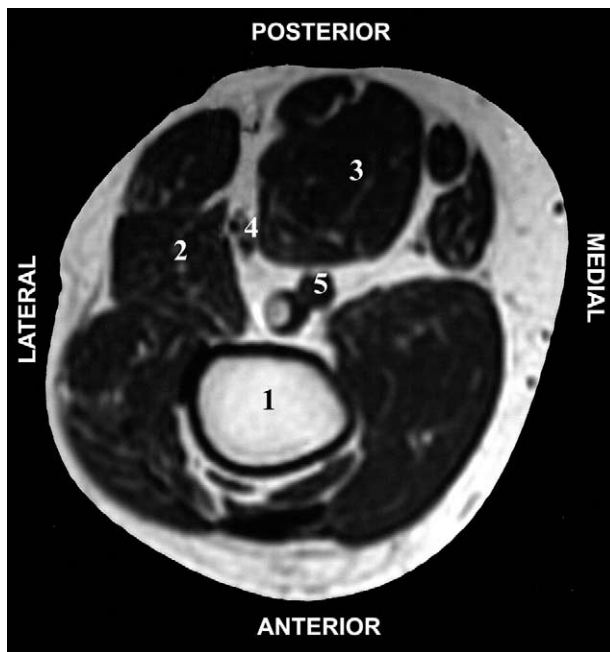


**Fig 6.** Proximal anatomy of the sciatic nerve in the gluteal region: 1, greater trochanter; 2, common peroneal component of the sciatic nerve; 3, tibial component of the sciatic nerve; 4, ischial tuberosity; 5, superior gluteal artery; 6, inferior gluteal artery.

similar course because the chief blood supply to the thigh is through the anterior femoral artery. The popliteal artery and vein, the continuation of the femoral artery and vein, reach the popliteal fossa by passing through the adductor hiatus and continue downward with the artery anterior to the vein. In the upper part of the popliteal fossa, the sciatic nerve lies posterolateral to the popliteal vessels. Specifically, the popliteal vein is medial to the nerve, whereas the popliteal artery is anterior, lying on the popliteal surface of the femur (Fig 7). The sciatic nerve usually divides into its component nerves, the tibial and common peroneal nerves, at the upper aspect of the popliteal fossa. In a cadaveric evaluation, Vloka et al.<sup>13</sup> reported that the division of the sciatic nerve into its components occurs at a mean distance of  $6 \pm 3$  cm above the popliteal crease. However, in this small sampling, the range was quite large (0-11.5 cm).

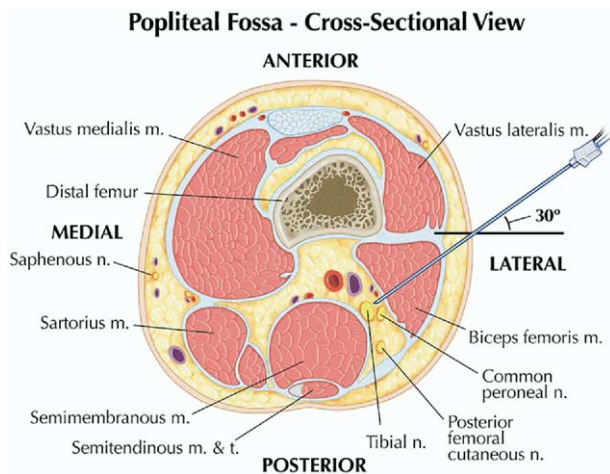
**Tibial Nerve.** In the popliteal fossa, the tibial nerve lies posterior and lateral to the popliteal vessels (Fig 8). In the lower part of the fossa, it sends branches to the major ankle plantar flexors, the



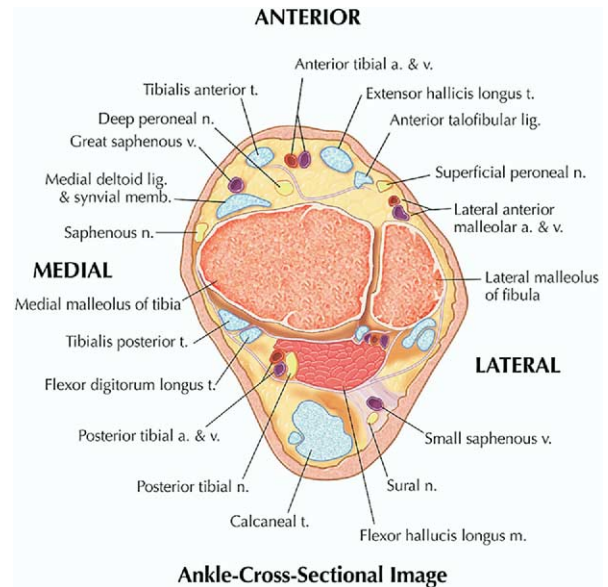


**Fig 7.** An MRI image of the popliteal fossa showing the relationship of the components of the sciatic nerve to the vessels and femur: 1, femur; 2, biceps femoris; 3, semi-tendinosus/semimembranosus; 4, sciatic nerve (tibial and common peroneal components are seen); 5, popliteal artery and vein.

gastrocnemius, and soleus muscles. The tibial nerve then courses on the posterior surface of the tibialis posterior muscle, along with the posterior tibial vessels. At the ankle, the nerve and vessels enter a



**Fig 8.** Popliteal fossa cross-sectional view. This figure shows needle position for a lateral approach to the sciatic nerve in the supine patient at the level of the popliteal fossa. Note the components of the sciatic nerve are posterior and lateral to the vessels. m, muscle; n, nerve; post, posterior; lat, lateral; t, tendon. (Courtesy of Mayo Foundation.)



**Fig 9.** Ankle cross-sectional image. The figure at the level of malleolus shows the typical distribution of the terminal branches of the sciatic nerve that comprise an ankle block. t, tendon; a, artery; v, vein; lig, ligament; n, nerve; memb, membrane; m, muscle. (Courtesy of Mayo Foundation.)

compartment beneath the flexor retinaculum (Fig 9). As it passes to the plantar aspect of the foot, it gives off the lateral and medial plantar nerves. Of the digital nerves, those to the medial 3½ toes are supplied by the medial plantar nerve, whereas those of the lateral 1½ toes are supplied by the lateral plantar nerve; a distribution similar to the median and ulnar nerves in the hand.

**Peroneal Nerve.** The common peroneal nerve diverges laterally leaving the popliteal fossa by crossing the lateral head of the gastrocnemius. It lies subcutaneously just behind the fibular head, in which it can be easily traumatized. As it rounds the neck of the fibula, the common peroneal nerve divides into its terminal branches, the deep peroneal nerve and the superficial peroneal nerve. The deep peroneal nerve continues distally, accompanied by the anterior tibial artery, on the interosseus membrane. Nerve and artery emerge on the dorsum of the foot between the extensor hallucis longus and tibialis anterior. At this level, the deep peroneal nerve is lateral to the dorsalis pedis artery. The deep peroneal nerve innervates the extensor (dorsiflexor) muscles of the foot and the first web-space. The superficial peroneal nerve descends in the lateral compartment, between the peroneus longus and brevis muscles. After supplying these ankle evertors innervates, it emerges between them to innervate the skin of the lower leg and foot.

**Posterior Femoral Cutaneous Nerve.** The posterior femoral cutaneous nerve is a purely sensory nerve derived from the anterior rami of S1–S3.<sup>14</sup> It travels with the sciatic nerve out of the pelvis and into the upper thigh. While deep to the gluteus maximus, it gives off the inferior clunial nerves (sensory nerves to the lower buttock) and perineal branches (sensory to the external genitalia). It emerges from the lower edge of the gluteus maximus to lie in subcutaneous tissue and continues down the posterior aspect of the thigh and the leg giving off, in succession, femoral and sural branches (sensory branches to the back of the thigh and the calf). It becomes superficial near the popliteal fossa where its terminal branches often anastomose with the sural nerve.

**Sural Nerve.** The medial and lateral sural nerves are pure sensory nerves derived from the tibial and common peroneal nerves, respectively, at the level of the knee joint. Together, they supply the posterolateral aspect of the leg and ankle and the dorsal surface of the foot.

## Approaches to the Lower Extremity

### Nerve Blocks of the Lumbar Plexus

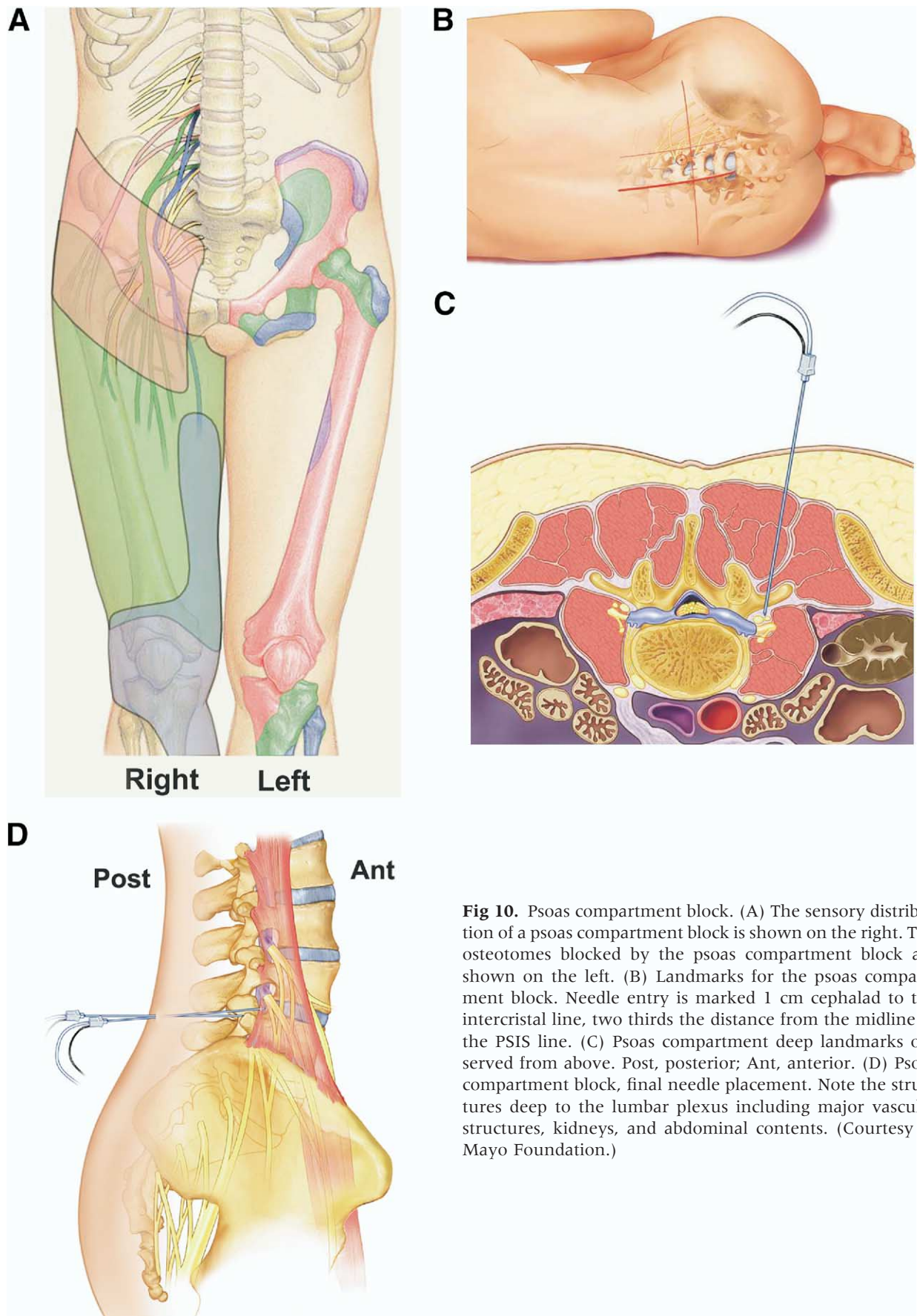
**Psoas Compartment Block.** The psoas compartment block was first described by Chayen et al.<sup>15</sup> in 1976. It can be performed as a single-injection technique or with a catheter placed for prolonged analgesia. It has been used to provide anesthesia for thigh surgery. In combination with parasacral nerve block, it has been used for hip fracture repair.<sup>16</sup> It is successfully used for analgesia after total hip arthroplasty (THA) or total knee arthroplasty (TKA).<sup>2,4,17,18</sup> It has also been used in the treatment of chronic hip pain.<sup>19</sup> The distribution of the psoas compartment block is shown in [Figure 10A](#).

The psoas compartment block is a deep block of the lumbar plexus from a posterior approach. Traversing from posterior to anterior at the level of L4–L5, the following structures would be encountered: posterior lumbar fascia, paraspinal muscles, anterior lumbar fascia, quadratus lumborum, and the psoas muscle.<sup>6,20</sup> ([Fig 10D](#)). The common iliac artery and vein are situated anterior to the psoas muscle, which is inside a fascial sheath, the psoas compartment ([Fig 3](#)). Because the final positioning of the needle is within the body of the psoas muscle through which the lumbar plexus traverses, it is thought to be the most consistent approach to block the entire lumbar plexus with a single injection. It is useful for providing consistent anesthesia in the distributions of the femoral, lateral femoral cutaneous, and the obturator nerves ([Fig 10A](#)).

Several descriptions of the needle entry site for the psoas compartment blocks have been described.<sup>2,3,21–24</sup> All rely on bony contact with the transverse process as a guide to depth of needle placement. Capdevila et al.<sup>2</sup> described a slightly modified entry point based on computed tomography (CT) scans of the lumbar plexus of patients undergoing THA. They estimated the distance from the skin to the lumbar plexus to be 8.35 cm in men (range 6.1–10.1 cm) and 7.1 cm in women (range 5.7–9.3 cm). The depth of the lumbar plexus correlated with gender and body mass index. Importantly, the distance from the transverse process to the lumbar plexus was extremely consistent at a distance of less than 2 cm. This relationship of transverse process to the lumbar plexus was independent of body mass index or gender. Thus, contact with the transverse process provides a consistent landmark to avoid excessive needle penetration during psoas compartment block<sup>2</sup> ([Fig 10B–D](#)).

The depth of needle insertion is emphasized because of the complications associated with excessive needle depth including renal hematoma, pneumocele, total spinal anesthesia, and unintended intra-abdominal, and intervertebral disk catheter placement.<sup>2,25–27</sup> To ensure the proper position of the needle during psoas compartment block and avoid excessive needle insertion, it is highly recommended that the transverse process be intentionally sought. Epidural spread of local anesthetic is another common side effect of psoas compartment block, occurring in 9% to 16% of adult patients<sup>3,28</sup> ([Table 3](#)). In children, Dalens et al.<sup>29</sup> reported a >90% incidence of epidural spread when using the original landmarks of Chayen et al.<sup>15</sup> compared with no epidural spread when using the landmarks as modified by Winnie.<sup>29</sup> This side effect is usually attributed to retrograde diffusion of the local anesthetic to the epidural space when large volumes of local anesthetic are used (greater than 20 mL). In most cases, there is residual lumbar plexus blockade apparent after the resolution of the contralateral block. However, there are case reports of total spinal anesthesia occurring during lumbar plexus blockade and vigilance must be maintained during the management of this block<sup>26,30</sup> (see complications).

**Continuous Psoas Compartment Blocks.** Continuous techniques have been described to provide analgesia after a variety of operations including THA, TKA, open reduction and internal fixation of acetabular fractures, open reduction and internal fixation of femur fractures, and anterior cruciate ligament reconstruction.<sup>2,17,18,31,32</sup> Interest in this block developed as practitioners sought alternatives to neuraxial techniques that could provide consistent analgesia after hip, femur, and knee surgery. One theoretical advantage of psoas compartment block



**Fig 10.** Psoas compartment block. (A) The sensory distribution of a psoas compartment block is shown on the right. The osteotomes blocked by the psoas compartment block are shown on the left. (B) Landmarks for the psoas compartment block. Needle entry is marked 1 cm cephalad to the intercrystal line, two thirds the distance from the midline to the PSIS line. (C) Psoas compartment deep landmarks observed from above. Post, posterior; Ant, anterior. (D) Psoas compartment block, final needle placement. Note the structures deep to the lumbar plexus including major vascular structures, kidneys, and abdominal contents. (Courtesy of Mayo Foundation.)



**Table 3.** Success Rate of Lumbar Plexus Block With Different Techniques

Reference	N	Technique	Sensory Block			Motor Block		Number of Failures (Number of Epidural Spread)
			Fem	LFC	OBT	Fem	OBT	
Parkinson <sup>28*</sup>	27	Psoas @ L3, n.s.		95%		100%	100%	7 (4 epidural)
	23	Psoas @ L4-5		95%		100%	100%	3 (1 epidural)
	20	Femoral paresthesia		95%		100%	0%	None reported
Seeberger <sup>43</sup>	20	Femoral, n.s.†		85%		100%	0%	None reported
	39	Femoral, n.s. 20 mL		41%		92%	62%	4
	41	Femoral, n.s. 40 mL		44%		93%	78%	3
Lang <sup>42</sup>	32	Femoral paresthesia 30 mL		96%		81%	4%	6
Farny <sup>3</sup>	45	Psoas, n.s. 1.0-0.5 mA		100%		100%	100%	5 (4 epidural)
Morau <sup>73</sup>	20	Femoral, n.s. @ 0.5 mA bolus via catheter	100%	70%	88%			2
	20	Fascia iliaca bolus via catheter	86%	92%	55%			2
Tokat <sup>72</sup>	30	Psoas, n.s.	100%	97%	77%	80%	63%	0 (2 epidural)
	30	Femoral, n.s.	93%	63%	47%	73%	30%	3
Pandin <sup>32</sup>	132	Psoas n.s. @ 0.3 mA bolus via catheter	100%	93%	91%	80%	63%	4 (2 epidural)
Capdevila <sup>74</sup>	50	Femoral n.s. @ 0.5 mA 30 mL	90%	62%	52%	76%	32%	5
	50	Fascia iliaca 30 mL	88%	90%	38%	80%	20%	6
Kaloul <sup>75</sup>	20	Femoral n.s. @ 0.5 mA bolus via catheter				95%	47%	Not reported
	20	Psoas n.s. @ 0.5 mA bolus via catheter				90%	93%	Not reported

Abbreviations: Fem, femoral; LFC, Lateral femoral cutaneous; OBT, obturator; n.s., nerve stimulator.

\*Use of uninsulated needles; no mA given.

†These studies reported rate of success for blocking the components of the lumbar plexus using a variety of nerve localization techniques and approaches to the nerves.

over other continuous approaches to the lumbar plexus is the decreased likelihood of catheter dislodgement because of the large muscle mass that must be traversed to reach the lumbar plexus. The muscle mass anchors the catheter.

Pandin and colleagues<sup>32</sup> described a slightly more medial puncture site for placement of continuous lumbar plexus blocks for postoperative analgesia. They believed the more medial puncture site improved the likelihood of obtaining an obturator nerve block and optimized catheter insertion with an insertion angle of 20° to 30°. They failed to place a catheter in only 3% of their patients and reported a high success rate (100% femoral, 93% obturator, 91% lateral femoral cutaneous) bolusing through a nonstimulating catheter.<sup>32</sup>

**Femoral Nerve Block.** Indications for single-injection femoral nerve block include anesthesia for knee arthroscopy in combination with intra-articular local anesthesia and analgesia for femoral shaft fractures, anterior cruciate ligament reconstruction (ACL), and TKA as a part of multimodal regimens.<sup>33-38</sup> Their use in complex knee operations is associated with lower pain scores and fewer hospital admissions after same-day surgery.<sup>39</sup> The femoral nerve divides into the posterior and anterior divisions shortly after it emerges from under the inguinal ligament and undergoes extensive arborization. Commonly, the anterior branch of the femoral nerve will be identified first. Vloka et al.<sup>40</sup> reported this to be the first motor response elicited 97% of the time. Stimulation of this branch leads to contraction of the sartorius muscle on the medial

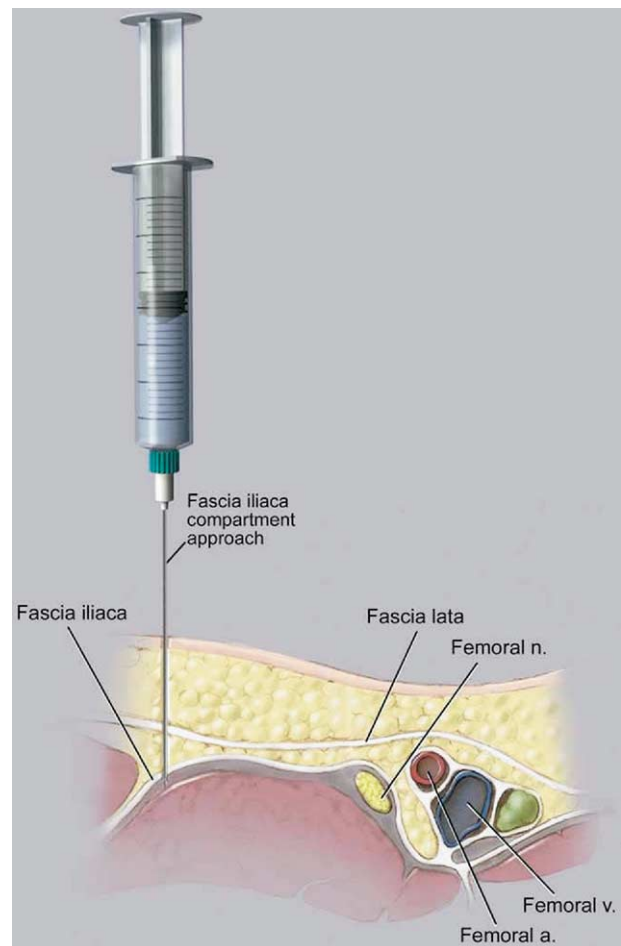
aspect of the thigh and should not be accepted, as the articular and muscular branches derive from the posterior branch of the femoral nerve. The needle should be redirected slightly laterally and with a deeper direction to encounter the posterior branch of the femoral nerve. Stimulation of this branch is identified by patellar ascension as the quadriceps contract.

**Defining the 3-in-1 Block.** During femoral nerve block, it has been advocated to use a higher volume of local anesthetic and apply firm pressure just distal to the needle during and a few minutes after injection to block the femoral, lateral femoral cutaneous, and obturator nerves, the so-named "3-in-1 block."<sup>41</sup> However, despite many efforts to consistently produce a 3-in-1 block, the effectiveness of these maneuvers has not been shown. In most reports, the femoral nerve is the only nerve consistently blocked with this approach.<sup>7,8,42,43</sup> Blockade of the lateral femoral cutaneous nerve occurs through lateral diffusion of local anesthetic and not through proximal spread to the lumbar plexus.<sup>8</sup> The obturator nerve is less frequently anesthetized during 3-in-1 block than the lateral femoral cutaneous (LFC), which is not surprising given the number of fascial barriers between these structures at the level of the inguinal ligament. Despite the lack of scientific support for the term 3-in-1, many authors still continue to refer to the anterior femoral nerve block as a 3-in-1 block. Within this text, we will refer to this approach as a femoral nerve block.

**Continuous Femoral Nerve Block.** Continuous femoral nerve block has been shown to improve outcome

after major knee and vascular surgery of the lower extremity compared with intravenous narcotic therapy or continuous infusion or injection of analgesics.<sup>44-50</sup> Chelly et al.<sup>46</sup> showed a 20% reduction in hospital length of stay in patients receiving continuous femoral nerve block analgesia compared with patients receiving intravenous patient-controlled analgesia narcotics after major knee surgery. Two prospective randomized studies examined 3 different modes of analgesia: continuous femoral nerve block, epidural analgesia, and intravenous narcotic therapy after TKA.<sup>47,48</sup> These studies showed improvement in perioperative rehabilitation scores and a decreased duration of stay in a rehabilitation center for patients receiving the regional anesthesia techniques. Continuous femoral nerve block was shown to have equivalent analgesia with fewer side effects than epidural analgesia in both of these studies.<sup>47,48</sup> However, not all investigators have been able to show these improvements in outcome with continuous femoral nerve blocks. Hirst et al.<sup>51</sup> found no differences in narcotic consumption or pain scores between patients receiving a single-injection femoral nerve block and patients receiving a continuous femoral nerve block after TKA. The accuracy of catheter placement may play a role in these conflicting findings. Continuous femoral nerve blocks have been associated with a high rate of inaccurate catheter placement. In a prospective study, Capdevila et al.<sup>52</sup> showed that continuous femoral nerve block using a standard approach led to unpredictable catheter placement. Their technique was to elicit a vastus intermedius muscle response at 0.5 mA and then insert a catheter 16 to 20 cm after distending the sheath with 5 mL saline and bolusing local anesthetic through the catheter. Catheter placement was evaluated radiographically, and only 25% of the catheters were lying near the lumbar plexus. Most of the catheters tended to course medially in the direction of the psoas muscle or laterally in the direction of the iliacus muscle. The accuracy of final catheter placement correlated with the degree of analgesia after proximal lower limb surgery, although visual analog scale values were generally low in all groups.<sup>52</sup> Comparing a stimulating catheter to a nonstimulating catheter, Salinas and colleagues<sup>53</sup> were able to increase the success rate of continuous femoral nerve block in volunteers from 85% to 100%. The role of stimulating versus nonstimulating catheters for continuous peripheral nerve blocks to improve success rate is an active area of research at this time.

**Fascia Iliacus Block.** Dalens et al.<sup>55</sup> originally described the fascia iliacus block in children. The indications for its use are the same as those for single-injection femoral nerve block. Advocates believe its utility lies in the double pop technique for



**Fig 11.** Approach to the fascia iliacus block. The needle gives a discernible pop as the fascia lata, then the fascia iliaca, is traversed. (Courtesy of Mayo Foundation.)

applying this block. The double pop refers to the sensation felt as the needle traverses the fascia lata then the fascia iliaca (Fig 11). Penetration of both layers of fascia is important for successful fascia iliacus blockade. To facilitate the appreciation of the “clicks” or “pops,” the use of a short bevel or pencil tipped needle has been advocated to provide more tactile feedback than cutting needles. This technique does not employ the use of a nerve stimulator. Although transient femoral neuropathy has been reported after fascia iliacus block, this appears to be a rare occurrence.<sup>56</sup>

The needle entry site for the fascia iliacus block is determined by drawing a line between the pubic tubercle and the anterior superior iliac crest and dividing this line into thirds. The needle entry point is 1 cm caudal to the intersection of the medial two thirds and lateral one third along this line. This site is well away from the femoral artery, making this useful for patients in whom femoral artery puncture is contraindicated.

**Continuous Fascia Iliacus Blocks.** Continuous fascia iliacus blocks have been described for analgesia after femur fracture and repair, femoral elongation procedures, skin graft harvesting, ligamentous knee reconstruction, and TKA.<sup>57,58</sup> Much like femoral continuous catheters, the degree of analgesia seems to be highly correlated with the final position of the catheter. Ganapathy et al.,<sup>57</sup> using a modified approach to the fascia iliacus block with a nerve stimulator, showed a high degree of catheter malpositioning. In this study, CT scans found only 40% of catheters placed were ideally positioned (superior to the upper third of the sacroiliac joint in the psoas sheath). Another variable examined in this study was the infusate, saline, 0.1% bupivacaine, or 0.2% bupivacaine. All the patients in the study had excellent pain relief regardless of the catheter position or infusate. This was attributed to the multimodal analgesic regimen the patients received. However, the best analgesia was highly correlated with ideal catheter tip position and the use of 0.2% bupivacaine.

**Obturator Nerve Block.** Indications for a single-injection obturator nerve block are generally limited to diagnostic indications or therapeutic relaxation of the adductor muscles of the thigh.<sup>59</sup> Despite the significant amount of literature that has been devoted to anesthetic sparing of this nerve with many approaches to the lumbar plexus, only 2 studies have examined the effect of the addition of an obturator nerve block to improve analgesia after major knee surgery.<sup>60,61</sup> Both studies reported a decrease in opioid consumption and pain scores in patients undergoing TKA receiving obturator nerve block in addition to a femoral or femoral and sciatic nerve block.

**LFC Nerve Block.** The LFC nerve of the thigh is a purely sensory nerve that supplies a large but variable area from the inguinal ligament to the knee on the lateral aspect of the thigh.<sup>9</sup> LFC nerve block is most commonly used as the sole anesthetic during diagnostic muscle biopsy and harvesting of split thickness skin grafts.<sup>62,63</sup> It has also been used to provide analgesia in elderly patients undergoing hip fracture repair.<sup>64</sup> However, in a study comparing LFC nerve block, femoral nerve block, and patients receiving no block following femoral neck repair, LFC nerve block was not as effective at controlling postoperative pain as femoral nerve block.<sup>65</sup>

Typically, this block is done as a fan technique with variable success. Whether this is because of variability in the distribution of innervation or to poorly localizing the nerve is not known. Shannon and colleagues<sup>66</sup> compared the traditional fan technique for LFC nerve block to the use of a nerve stimulator technique seeking tingling in the distribution of the nerve. They reported a 40% success

rate with the fanning technique compared with 100% with the nerve stimulating technique. There was no difference in the extent of the blockade in successful blocks. Femoral nerve block has been reported after LFC block.<sup>67</sup> This is not surprising given the bulk of data reporting spread to the LFC nerve during femoral nerve block.

**Saphenous Nerve Block.** The saphenous nerve follows the saphenous vein to the medial malleolus and supplies the cutaneous area of the medial aspect of the calf and foot to the level of the midfoot. The saphenous nerve block is often combined with a sciatic block to provide anesthesia and analgesia for surgery involving the medial aspect of the lower leg and foot. The saphenous nerve is a purely sensory nerve and does not contribute to the bony innervation of the foot. Approaches to the saphenous nerve along its entire course, from the adductor canal to the ankle, have been described. Success rates vary widely between techniques. For example, successful block is reported in 33% to 65% of cases with a field infiltration performed medially at the level of the tibial plateau,<sup>68,69</sup> 70% to 80% of cases with the trans sartorial approach,<sup>68,70</sup> 95% to 100% of cases with femoral paracondylar approach,<sup>70</sup> and near 100% of cases with the paravenous approach.<sup>69</sup> The saphenous nerve has been reported to be selectively blocked, sparing of the quadriceps musculature, in the adductor canal.<sup>71</sup> However, this has not been confirmed in a large series of patients receiving this approach to the saphenous nerve.

## Comparisons of Approaches to the Lumbar Plexus

### Psoas Compartment Block Versus Femoral Nerve Block

Parkinson et al.,<sup>28</sup> were the first to compare the extent of blockade after single-injection femoral nerve block and psoas compartment block. They compared the extent of blockade of the lumbar plexus with 5 different methods: posterior approach at L3 and L4-5 with a nerve stimulator using non-insulated needles and anterior femoral nerve block approaches with a paresthesia technique and nerve stimulating technique.<sup>28</sup> They reported a 100% success rate of femoral nerve blockade with all techniques. The lateral femoral cutaneous nerve success rate was 85% to 95%. The obturator nerve, as assessed by thigh adduction, was blocked 100% of the time with the posterior approaches and never with the anterior approaches. Limitations of this report include lack of details regarding the type of nerve stimulation, the small sample size, and exclusion of patients in whom femoral nerve block failed



to develop. A more recent comparison has been made between psoas compartment blocks and femoral nerve blocks.<sup>72</sup> In this study, patients receiving a psoas compartment block developed a sensory block of the femoral, lateral femoral cutaneous, and obturator nerves in 100%, 97%, and 77% of patients versus 93%, 63%, and 47% of the patients receiving a femoral nerve block.

### Femoral Nerve Block Versus Fascia Iliacus Block

Direct comparisons of the extent of blockade between the fascia iliacus block and femoral nerve block has been done in both adults and children. In adults, the fascia iliacus block, performed with the double-pop technique, provided faster onset and a higher rate of lateral femoral cutaneous nerve block compared with femoral nerve blocks performed with a nerve stimulator.<sup>73</sup> Both techniques provide adequate postoperative analgesia.<sup>74</sup> In children, the fascia iliacus block is more likely to block the lateral femoral cutaneous nerve compared with a femoral nerve block.<sup>54</sup> However, the duration of analgesia from these single-injection techniques was somewhat shorter in the fascia iliacus group. The authors speculated this was related to greater spread of the local anesthetic.

A single study directly comparing continuous fascia iliacus blocks to continuous femoral nerve blocks has been reported.<sup>73</sup> Again, the degree of analgesia was highly correlated with catheter positioning. Overall, there was a greater degree of blockade of the lateral femoral cutaneous nerve in the fascia iliacus group and a greater likelihood of blocking the obturator nerve in the femoral group.

### Continuous Psoas Compartment Blocks Versus Epidural Analgesia

Advantages of continuous psoas compartment block compared with epidural block include unilateral analgesia and motor block, lack of impairment of bladder function, and improved risk/benefit ratio in patients anticoagulated after surgery. These advantages must be weighed against the disadvantages of incomplete blockade for anesthesia and the need for supplementation in a balanced analgesic regimen for effective analgesia.

Turker and coworkers<sup>17</sup> compared continuous psoas compartment block with epidural block for analgesia after THA under combined general/regional technique. They showed that continuous psoas compartment block provided excellent intra- and postoperative analgesia with a low incidence of complications.<sup>17</sup> Epidural block took longer to perform and had a significantly higher incidence of hypotension, whereas analgesia and patient satis-

faction provided by the 2 blocks was similar. Epidural block also provided more motor blockade, longer time to ambulation, and significantly more complications.

**Continuous Psoas Compartment Blocks Versus Continuous Femoral Blocks.** After TKA, continuous femoral nerve block and continuous psoas compartment block reduce narcotic consumption and pain scores compared to intravenous morphine usage alone.<sup>44,45,75</sup> However, no differences in outcome were observed between the 2 peripheral nerve block groups despite a more consistent presence of obturator nerve block in the psoas compartment group.<sup>75</sup>

## Nerve Blocks of the Sacral Plexus

### Parasacral Block

The parasacral nerve block (PSNB) described by Mansour<sup>76</sup> in 1993 has been described as more than an isolated sciatic nerve block.<sup>77</sup> It has been used to provide analgesia following major foot and ankle reconstruction. Parasacral block will consistently block both components of the sciatic nerve and the posterior cutaneous nerve of the thigh. Spread of local anesthetic may also anesthetize other branches of the sacral plexus including the superior and inferior gluteal and pudendal nerves. The pelvic splanchnic nerves (S2-S4), the terminal portion of the sympathetic trunk, the inferior hypogastric plexus, and the obturator nerve all lie in close proximity to the elements of the sacral plexus and may all be anesthetized with this approach. For procedures about the knee, this may provide an advantage over more distal approaches to the sciatic nerve.<sup>77,78</sup> For procedures below the knee, the adductor weakness from the obturator and superior gluteal nerve block may actually be disadvantageous for mobilization of the patient. The sympathetic nerve supply to the bladder is also in close proximity but problems with voiding and the need for bladder catheterization after PSNB have not been reported.<sup>77</sup> A notable difference from other approaches to the sciatic nerve is the type of muscle response deemed acceptable as an endpoint for injection. Mansour<sup>76</sup> described contraction of the hamstring muscles (biceps femoris, semitendinosus) above the knee as the endpoint for PSNB with most consistent success.

### Continuous Parasacral Blocks

Continuous parasacral blocks have been used in combination with lumbar plexus block to provide lower extremity anesthesia for TKA, above the knee amputation, ACL repair, and a variety of other lower-extremity procedures.<sup>78</sup> Gaertner reported successful

**Table 4.** Sciatic Nerve Block Approaches, Nerve Stimulating Current And Block Success

Approach, Author	Number of Patients	Recommended Minimal Stimulating Current and Its Pulse Width	Success Rate
At the level of the sciatic notch Parasacral, Morris <sup>77</sup>	30	≤ 0.2 mA; 100 $\mu$ sec pulse width	97%
At the level of the ischial spine Labat, di Benedetto <sup>94</sup>	135	< 0.5 mA; 100 $\mu$ sec pulse width	98%
Trans-rectal, Chang <sup>84</sup>	40	≤ 0.4 mA; 200 $\mu$ sec pulse width	92.5% (cross-over design)*
At the level of the ischial tuberosity Lithotomy Posterior, Sutherland <sup>115</sup>	76	Not reported 0.3-0.5 mA; 100 $\mu$ sec pulse width	95%
At the level of the upper thigh Posterior Subgluteus, di Benedetto <sup>113</sup>	64	< 0.5 mA; 100 $\mu$ sec pulse width	94%
Anterior, Chelly <sup>89</sup>	22	< 0.7 mA; 100 $\mu$ sec pulse width	100%
Lateral, Guardini <sup>82</sup>	> 100	Not reported	≅ 94%

\*Failures in this study were due to the inability to obtain this endpoint or to technical factors (e.g., patient movement and abandonment of the block [12%]) rather than to the failure of the endpoint itself.

catheter placement, as confirmed by radiographic contrast dye in 86 of 87 consecutive patients undergoing lower-extremity surgery, using a nonstimulating catheter. All patients developed analgesia in the distribution of the tibial, peroneal, and posterior cutaneous nerve of thigh.

### Sciatic Nerve Block: At the Level of the Gluteus Maximus

The sciatic nerve, the largest nerve derived from the sacral plexus, innervates the posterior thigh and almost the entire leg below the knee. The most common indications for sciatic nerve block are anesthesia and analgesia for foot and ankle surgery. There are a variety of approaches to the sciatic nerve block and their success rate is widely variable, ranging from 33% to 95%.<sup>79-82</sup>

Gaston Labat<sup>83</sup> first described, at the beginning of the 20th century, the sciatic nerve block that is now referred to as the Classic Approach of Labat. This approach is based on the bony relationship of the posterior superior iliac spine and the greater trochanter with the patient positioned in a modified Sims position. Winnie<sup>79</sup> was the first to modify the original description, adding in an additional landmark, the sacral hiatus to greater trochanter distance, to more precisely account for varying body habituses (Table 4). Difficulty identifying these landmarks led Chang and colleagues<sup>84</sup> to describe a transrectal method of identifying the ischial spine.

Franco<sup>85</sup> described a simple approach to the sciatic nerve block in the prone position. The needle entry site is perpendicular to the floor 10-cm lateral from the middle of the intragluteal sulcus regardless of the patient's gender or body mass index. The sciatic nerve was found by trainees in ≤3 passes in 85% of the cases reported. Whether the success of this simple approach will be replicated in a larger sample size remains to be seen.

### Subgluteal Approaches to the Sciatic Nerve

Raj et al.<sup>80</sup> described a supine approach to the sciatic nerve in the flexed hip position, initiating the block at the midpoint between the greater trochanter of the femur and the ischial tuberosity. The positioning of the patient was thought to be advantageous compared to the classic approach of Labat by "thinning the gluteus maximus muscles, making the sciatic nerve more superficial." However, identifying these bony landmarks in very obese patients is sometimes difficult and the patient position requires additional personnel to maintain.

A lateral subgluteal approach to the sciatic nerve using the greater trochanter of the femur as a landmark was first described by Ichniyanagi in 1959.<sup>86</sup> Other investigators have described a high success rate using this high lateral approach with a slightly more caudal entry point.<sup>82</sup> Notably, when using this approach the success rate of the blockade of the posterior cutaneous nerve of the thigh was 83%. Although theoretically the posterior cutaneous nerve should reliably be blocked in most proximal approaches to the sciatic nerve, the success rate of blockade is not usually reported.

The anterior approach to the sciatic nerve has the appeal of supine positioning and a single prep of the patient for combined femoral and sciatic nerve blocks. Its popularity had long been limited by its low success rate and relatively painful use of the femur as a deep landmark.<sup>87,88</sup> Chelly and Delaunay<sup>89</sup> described a nerve stimulating technique positioning the needle at the level of the lesser trochanter as originally described by Beck. Vloka et al.<sup>90</sup> described the importance of internal rotation of the leg if the path to the sciatic nerve is obstructed by the lesser trochanter. A magnetic resonance imaging study of the anatomy of this area found that in 65% of patients the sciatic nerve is inaccessible from the anterior approach at the level

of the lesser trochanter.<sup>91</sup> These authors suggested needle placement 4 centimeters lower where obstruction to the sciatic nerve occurred in only 5% of the patients.

Dalens et al.<sup>92</sup> has compared the success rate of the posterior, lateral, and anterior approaches to the sciatic nerve in children. Although they had a success rate of 90% with all approaches, the authors reported fewer manipulations were required to perform either a lateral or posterior approach compared with the anterior approach. Recently, Chowdary and Splinter<sup>93</sup> reported on a medial approach to the sciatic nerve at the level of the lesser trochanter in only 10 children. Advantages of this approach are the lack of obstruction from the femur and no muscle mass to transverse. The authors reported a 70% rate of blockade of the posterior cutaneous nerve of the thigh with this medial approach.

di Benedetto et al.<sup>94</sup> described their experience in 135 consecutive patients using a posterior subgluteal approach to the sciatic nerve. The time to perform the block was  $41 \pm 25$  seconds (mean  $\pm$  SD), with an average of 2 needle redirections. The degree of discomfort reported was very low and only 16 patients (12%) reported severe pain during placement of the block. In contrast to this, Fanelli et al.<sup>95</sup> reported patient discomfort in 88% of patients receiving a classic Labat approach to the sciatic nerve.

### Sciatic Nerve Block at the Level of the Popliteal Fossa

Popliteal fossa block is chiefly used for foot and ankle surgery.<sup>96-98</sup> Short saphenous vein stripping may also be performed under combined popliteal and posterior cutaneous nerve block.<sup>99</sup> The block has also been successfully used in the pediatric population.<sup>100</sup> Popliteal fossa block anesthetizes the entire leg below the tibial plateau save the skin of medial aspect of the calf and foot (i.e., saphenous nerve distribution). Potential advantages of popliteal block over ankle block are improved calf tourniquet tolerance and immobile foot. The components of the sciatic nerve may be blocked at the level of the popliteal fossa via posterior or lateral approaches. Patient positioning—prone, lateral (operative side nondependent), or supine (with leg flexed at the hip and knee)—may determine the optimal approach for an individual patient.<sup>101</sup> Continuous techniques have been described using both the posterior<sup>102-104</sup> and lateral<sup>105</sup> approaches.

The classic posterior approach to the popliteal fossa is accomplished with the patient positioned prone (Fig 7). Traditionally, the sciatic nerve is lo-

cated 5 cm above the popliteal crease.<sup>96</sup> However, to block the sciatic nerve before its division, a 7- to 10-cm distance has been recommended.<sup>97,98,106-108</sup> With a large-volume single-injection technique, inversion is the motor response that best predicts complete neural block of the foot.<sup>109</sup> A lateral approach to blockade of the sciatic nerve in the popliteal fossa has been described.<sup>110-112</sup> Because the common peroneal nerve is located more superficially than the tibial nerve, the stimulating needle encounters it first (Fig 8).

Success rate with all approaches is typically 90% to 95%, with approximately 5% of patients requiring supplemental general anesthesia. It is believed that incomplete block is the result of poor diffusion (because of the size of the sciatic nerve), the separate fascial coverings of the tibial and peroneal nerves, or blockade of only a single component of the sciatic nerve. This has led some practitioners to endorse the practice of dual stimulation to improve success rate<sup>110</sup> (see Multistimulation versus single-stimulation techniques).

### Continuous Sciatic Nerve Blocks

Continuous sciatic nerve blockade can theoretically be achieved at any place along the course of the sciatic nerve. These blocks have been used for analgesia after major foot and ankle reconstruction, ankle fracture fixation, and below the knee amputation.<sup>102,103,113-115</sup> Several studies have been published on the use of continuous popliteal blocks for analgesia after extensive foot and ankle surgery.<sup>102-104</sup> All studies reported excellent analgesia with few side effects. Compared with intravenous analgesia or placebo infusion, a continuous infusion of local anesthetic via a popliteal catheter reduces pain scores and opioid consumption, and decreases sleep disturbances.<sup>102,103</sup> Successful catheter placement has been reported with both lateral and posterior approaches. The only consistent problem reported with popliteal catheters is a high incidence (15%-25%) of kinking or dislodgement.<sup>102,103</sup>

di Benedetto et al.<sup>113</sup> compared the subgluteal approach to the posterior popliteal approach for continuous infusions in a prospective study. In the 24-hour observation period after surgery, 13.3% of the catheters in the popliteal group were either occluded or dislodged compared with 6.6% of the catheters in the subgluteal group. This difference did not reach statistical difference.

### Ankle and Foot Block

Indications for blockade of the terminal nerves of the lumbosacral plexus distally, at the ankle and



midtarsal levels, include anesthesia for surgery to the foot.<sup>116,117</sup> Diagnostic block has also been described.<sup>118</sup> The peripheral nerves blocked at these levels are terminal branches of both the sciatic (posterior tibial, superficial peroneal, deep peroneal, and sural) and femoral (saphenous) nerves.

The 5 peripheral nerves that supply the foot are relatively easy to block at the ankle (Fig 9). There are no important variants in the innervation of the distal musculature. However, there is considerable variation in the branching and distribution of the sensory nerves of the foot. For this reason, blockade of all 5 nerves has been advocated.<sup>119</sup> Neural blockade of the posterior tibial nerve has been described at the supramalleolar,<sup>119-121</sup> midmalleolar,<sup>116</sup> subcalcaneal,<sup>122,123</sup> and midtarsal<sup>124</sup> levels with no evidence of superiority of any technique.

Few studies evaluating perioperative outcomes with ankle block exist,<sup>125</sup> although the technique has been performed for decades.<sup>83</sup> Rather, most publications describe variations to improve success rate. Peak blood levels of local anesthetic occur around 90 minutes after blockade and are very low even after bilateral ankle block.<sup>126</sup>

### Intravenous Regional Anesthesia of the Lower Extremity

Intravenous regional anesthesia (IVRA) may be used for foot, ankle, and knee surgery lasting up to 1 hour.<sup>127</sup> It may also be used for treatment of complex regional pain syndrome in the lower limb.<sup>128</sup> In a questionnaire survey,<sup>129</sup> most responding anesthesiologists (>80%) acknowledge that lower limb IVRA is seldom performed for surgical anesthesia because of a lack of clinical experience. Other reasons for its lack of popularity include difficulty in locating veins in the foot or ankle, thigh tourniquet pain, and perceived requirement of a larger, potentially unsafe, local anesthetic dose than for upper limb IVRA.

The technique for lower limb IVRA involves application of a double pneumatic thigh cuff after proper padding and establishment of a venous access on the dorsum of the foot or around the ankle with a 20- to 22-G cannula. The greater saphenous vein is often the most suitable vein. After limb elevation for several minutes and exsanguination with an Esmarch bandage, the proximal tourniquet is inflated to 100 mm Hg above the limb occlusion pressure (min 300 mm Hg). Most commonly, lidocaine 0.25% is injected to a maximum of 3 mg/kg over several minutes. This yields a large injected volume of up to 1.2 mL/kg (e.g., 84 mL for a 70-kg subject).<sup>127,130</sup> The recommended inflation time is 20 minutes minimum and 90 minutes maximum.

Alternatively, a calf tourniquet can be used for foot and ankle surgery.<sup>131</sup> In this case, a single cuff is applied at least 3 inches below the head of fibula to avoid common peroneal nerve injury. A proximal “back up” cuff is placed on the thigh in case of drug leakage. A double cuff in the calf is generally not advisable because tapering calf curvature prevents a firm fit and risks accidental cuff slippage. Clinical experience suggests that lidocaine 0.5% up to 3 mg/kg and 0.6 mL/kg provides consistent surgical anesthesia within 10 minutes.

An intercuff IVRA technique has been described for knee arthroscopy achieved successfully with 40 mL lidocaine 0.5%.<sup>132</sup> This technique involves inflation of a double-cuffed tourniquet in the thigh after exsanguination, injection of local anesthetic through a foot cannula, then application of a single cuff in the calf, and re-exsanguination of the foot before inflation of the calf tourniquet. This technique allows surgical anesthesia to be most concentrated around the knee joint. At the end of surgery, the calf cuff is deflated first, allowing residual local anesthetic to empty into the foot before release of the proximal thigh cuff.

### Comparisons Between Approaches to the Sacral Plexus

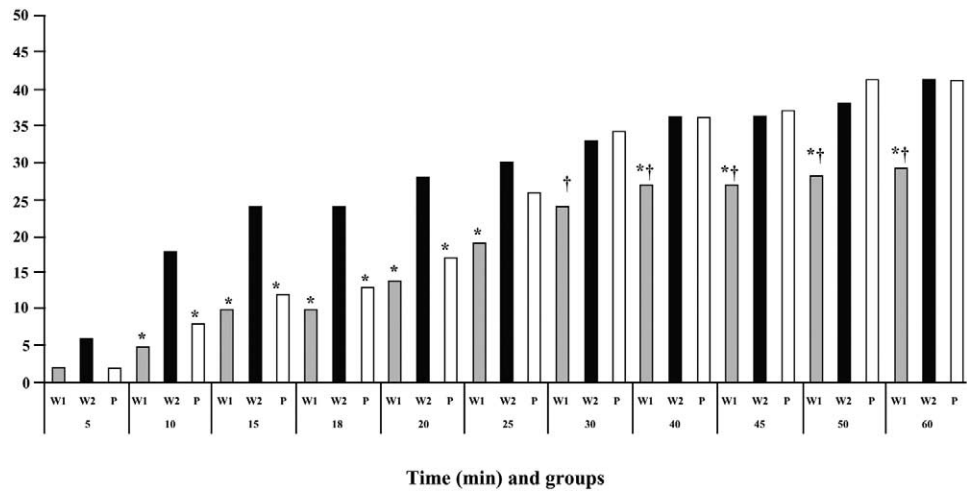
#### PSNB Versus Classic Sciatic Nerve Block

Cuvillon et al.<sup>133</sup> reported on 150 patients presenting for lower-extremity surgery using PNB. For the sciatic component of their anesthetic, the patients were randomized to receive a PSNB, a single-injection sciatic nerve block as described by Winnie, or a double-injection sciatic nerve block as described by Winnie. The onset time and success rate were similar in the PSNB and double-injection groups and were superior to the single-injection group in this report (Fig 12). The authors attributed this high rate of success with the PSNB to its proximal location with the potential for blockade of additional branches of the sacral plexus, although this was not evaluated in the study design.

#### Sciatic Block at the Gluteus Maximus Versus Sciatic Block at the Popliteal Fossa

Kilpatrick et al.<sup>134</sup> compared the classic sciatic block with popliteal fossa block in patients undergoing foot surgery. All blocks were performed using a nerve stimulator technique. Popliteal fossa blocks were less painful because the sciatic nerve is no longer covered by thick musculature at this level. However, the success rate was lower with the popliteal approach (45%) than with the classic (95%). Using more modern techniques, a comparison of

**Fig 12.** Cumulative success rates of complete sensory and motor block using 3 different techniques. W1, Winnie's modification of Classic Labat technique, single injection; W2, Winnie's modification of Classic Labat technique with a double-stimulation and injection technique; P, parasacral approach to the sciatic nerve. \* $P < .01$  vs W2,  $tP < .01$  vs P. (Reprinted with permission.<sup>9</sup>)



classic, subgluteal, and lateral popliteal approaches showed similar success rates (96%, 92%, and 96% respectively) but slower onset time for the lateral popliteal group compared with the more proximal approaches.<sup>135</sup> This difference was attributed to the greater distance separating the components of the sciatic nerve as it traverses through the popliteal fossa.

#### Posterior Versus Lateral Approaches to the Sciatic Nerve Block at the Popliteal Fossa

Hadzic and Vloka<sup>136</sup> evaluated the ease of performance and efficacy of the lateral and posterior approaches to the sciatic nerve in the popliteal fossa. All blocks were performed using a single-stimulation nerve stimulator technique. Either a tibial or common peroneal response was accepted. Onset and quality of block was comparable; there was no difference in the success rate between the 2 groups. However, time to complete the block was slightly longer with the lateral approach (mean, 8 minutes; range, 1-17 minutes) compared with the posterior approach (mean, 6 minutes; range, 1-16 minutes).

#### Popliteal Fossa Block Versus Subcutaneous Infiltration After Foot Surgery

McLeod et al.<sup>137</sup> prospectively evaluated the use of popliteal fossa block using the lateral approach and subcutaneous wound infiltration in providing postoperative analgesia for ambulatory foot surgery. All blocks were performed after induction of general anesthesia. In both groups, the local anesthetic consisted of 20 mL 0.5% bupivacaine. There was no difference in the pain scores in the recovery room or at the time of hospital dismissal. However, during the first 24 hours postoperatively, only 14% of patients in the popliteal fossa block rated their

pain as severe, whereas 60% of patients with subcutaneous infiltration complained of severe pain. The duration of analgesia was also significantly longer in the popliteal fossa group, 18 hours compared with 6 hours. The authors concluded that popliteal fossa block provided effective analgesia and was associated with a high level of patient satisfaction. A recent review also recommended popliteal fossa block as the technique of choice in patients undergoing major foot or ankle surgery.<sup>138</sup>

### Comparisons of Nerve Localization Techniques

#### Nerve Stimulation Versus Paresthesia Techniques for Lower-Extremity PNB

There are few studies directly comparing success rate with paresthesia techniques versus peripheral nerve stimulation (PNS) techniques in lower-extremity PNBs. However, PNS provides a success rate comparable to earlier reports of paresthesia techniques.<sup>28,51,139-143</sup> In addition, it may improve patient comfort during block performance. However, its biggest advantage may be the redirection cues that are provided to the operator.

#### Redirection Cues

Lower-extremity PNBs generally tend to be deeper blocks than most approaches to the brachial plexus. Perhaps one of the most compelling reasons for using PNS during lower-extremity PNB is the valuable "redirection cues" obtained during initial unsuccessful passes of the needle. For example, when performing a sciatic nerve block in the gluteal region, one may observe knee flexion as a result of stimulation of the superior gluteal nerve. This likely indicates that the needle is posterior, lateral, and

cephalad to the sciatic nerve and should be repositioned appropriately. Tables 1 and 2 list motor responses to nerve stimulation for all the muscles innervated by the lumbosacral plexi. These motor responses can be used as guides for redirection cues.

### Multistimulation Versus Single-Stimulation Techniques

Multiple-stimulation techniques by definition require individual stimulation of each component of a peripheral nerve with deposition of a small volume of local anesthetic at each site. For instance, during performance of a sciatic block a peroneal motor response is elicited first and a small volume of local anesthetic is deposited. The needle is then redirected medially to obtain a tibial nerve motor response with subsequent deposition of additional local anesthetic. Whether the search for individual components of a PNB versus identification of a single component will become the norm for PNB is not clear. Advocates of multiple-stimulation techniques believe the technique increases the success rate and allows an injection of a smaller volume of local anesthetic. Advocates of single injection techniques believe multistimulation and injection techniques may add risk of nerve injury during redirection of the needle through partially anesthetized nerves.

Several studies have supported the clinical utility of multiple-stimulation technique. Paqueron et al.<sup>110</sup> compared the block characteristics in patients undergoing popliteal fossa block with the lateral approach using either a single injection (inversion response) or a double injection (both common peroneal and tibial components identified). A total of 20 mL local anesthetic was injected. Double stimulation was associated with a higher success rate than single stimulation, 88% versus 54%, respectively. The onset time of complete sensory block was also reduced with the double-stimulation technique. Similar results were reported for multiple-stimulation sciatic nerve blocks by other investigators.<sup>144,145</sup> No neurologic complications have been reported in any of these studies.<sup>110,144,145</sup>

Casati et al.<sup>146</sup> showed that a lower volume of local anesthetic could be used for femoral nerve block when comparing multi-injection technique to single injection in a prospective randomized and blinded study. In this study, multiple stimulation of the femoral nerve involved injecting on each of 3 stimulations, the vastus medialis, vastus intermedius, and vastus lateralis, compared with a single injection on a vastus intermedius stimulation. Using a staircase method to determine the volume of local anesthetic required to produce a sensory and motor block within 20 minutes, the authors found a 27%

reduction in volume in the multistimulation group. Whether this difference in volume (total of 9 mL) will improve safety is unknown.

In each of these reports the issue of safety, specifically the risk of nerve injury, when using a multistimulation injection technique has been raised. There were no reported nerve injuries in these studies performed by experienced regional anesthesiologists. This is in agreement with the large cohort of patients studied by Fanelli et al.<sup>95</sup> using multistimulation techniques in over 2,000 patients with no nerve injury attributed to nerve block. However, nerve injury is a rare event after PNB and even in a study of this size may not have a large enough sample size to determine the relative risk of multiple versus single injection techniques.

### Imaging Aids

Several investigators have examined the use of imaging technology to improve localization of both the lumbar plexus and the femoral nerve. Kirchmair and colleagues<sup>147</sup> showed the usefulness of ultrasound in localizing the psoas major using a curved array transducer at low (4-5 MHz) frequency. The location of the lumbar plexus is then inferred. It is not possible to distinguish peripheral nerves from tendon fibers with the ultrasound technology currently commercially available. The main limitations to visualization in this volunteer study were obesity and occasional high riding iliac crests in male patients. In a follow-up study, ultrasound guidance was used to place needles in the lumbar plexus of cadaveric specimens.<sup>148</sup> CT scan verified the accuracy of needle placement in all cases. Of the 60 attempts the psoas major was visualized in 48 specimens and the needle successfully placed in 47. Again obesity, spinal deformities, and conditions related to embalming of the cadavers were the main limitations for use of this technique.

Marhofer et al.<sup>149</sup> compared the use of ultrasound guidance to nerve stimulation during femoral nerve blocks. These investigators found that ultrasound guidance was superior to nerve stimulation because it allowed the use of a smaller volume of local anesthetic and shorter latency period. The authors attributed this difference to the ability to visualize the administration of the local anesthetic during injection. They used ultrasound to reposition the needle when the local anesthetic spread out of the fascial plane and away from the nerve.<sup>149,150</sup> It should be noted that ultrasound failed to identify the femoral nerve in a small number of patients in each of these studies.



## Local Anesthetic Choices and Dosing of Lower-Extremity PNB

### Pharmacologic Considerations

Selection of a local anesthetic solution for lower-extremity blocks differs somewhat from that of upper-extremity approaches because of the indications and applications of each. For example, upper-extremity blocks are commonly performed as the intraoperative anesthetic. In addition, pain after surgery to the upper extremity may not be as severe or protracted. As a result, intermediate-acting local anesthetics and local anesthetic mixtures are frequently selected for surgery to the arm.<sup>151</sup> These principles may not apply to lower-extremity surgery in which peripheral blockade is often supplemented with a neuraxial or general anesthetic intraoperatively, and the need for sustained postoperative analgesia is achieved with long-acting amides administered either as single injections or continuous infusions. Finally, although the use of adjuvants such as clonidine, opioids, and ketorolac is common during lower-extremity peripheral techniques, their efficacy in improving the quality or duration of blockade has not been consistently shown.

**Local Anesthetic Selection.** Few randomized studies have compared local anesthetics for lower-extremity block. Fanelli et al.<sup>152</sup> evaluated the onset and duration of combined femoral-sciatic block performed with 0.75% ropivacaine, 0.5% bupivacaine, or 2% mepivacaine. Ropivacaine had an onset similar to that of mepivacaine but with a duration of analgesia between that of bupivacaine and mepivacaine. Connelly et al.<sup>153</sup> reported no significant clinical differences between 0.75% ropivacaine and 0.5% bupivacaine for sciatic nerve blockade. When equipotent (rather than equivalent) concentrations were compared, onset times for the 2 local anesthetics showed no differences in onset times for sensory and motor block. However, the times to block regression and first analgesia were slightly longer with bupivacaine.<sup>154</sup> In a single comparative study of sciatic block, levobupivacaine has block characteristics similar to ropivacaine.<sup>155</sup>

**Epinephrine.** Epinephrine prolongs the duration and quality of most local anesthetics used for lower-extremity peripheral block. The effects are the result of vasoconstriction of the perineural vessels, which decreases uptake and thereby increases the neural exposure to the local anesthetic. However, the difference is only somewhat dose dependent. The addition of epinephrine 5  $\mu\text{g/mL}$  (1:200,000 dilution) significantly increases the duration of lidocaine from 186 minutes to 264 minutes. Although epinephrine 2.5  $\mu\text{g/mL}$  (1:400,000 dilution) prolongs the block to nearly the same extent (240 minutes), it has no effect

on nerve blood flow.<sup>156</sup> The addition of epinephrine to local anesthetics with vasoconstrictive properties, such as ropivacaine, may not increase block duration but would still facilitate detection of intravascular injection.<sup>157</sup> The decision to add epinephrine (and the dose of epinephrine) is based on the concerns related to cardiac or neural ischemia versus the ability to discern an intravascular injection. In general, because seizures related to intravascular injection were highest in patients undergoing peripheral nerve block,<sup>158</sup> the benefits of adding epinephrine outweigh the risks. However, the nearly equivalent effects on block quality and duration reported with epinephrine 2.5 versus 5.0  $\mu\text{g/mL}$  suggest that the lower concentration is optimal, particularly in patients theoretically at risk for nerve injury (diabetics, patients with chemotherapy-induced neuropathy).<sup>156</sup>

**Bicarbonate.** The addition of bicarbonate has been recommended to increase the speed of onset of peripheral and plexus blockade. However, most studies that have shown statistically significant differences used commercially prepared epinephrine-containing solutions of local anesthetics (which have a much lower pH due to the addition of antioxidants) compared with plain local anesthetic solutions. A recent review of the literature involving brachial plexus block concluded that there was little reason to add sodium bicarbonate with plain local anesthetics or those with freshly added epinephrine.<sup>151</sup> These results were substantiated in a study by Candido et al.,<sup>159</sup> which reported no difference in the onset or duration of combined lumbar plexus-sciatic block in patients that received 0.5% bupivacaine with alkalization compared with those who received a non-alkalinized solution.

**Clonidine.** Clonidine has been extensively investigated as an adjuvant for brachial plexus block. Prolongation of analgesia after the addition of clonidine is most likely peripherally mediated and dose dependent. During intravenous regional anesthesia, clonidine 150  $\mu\text{g}$  may improve tourniquet tolerance.<sup>160</sup> Side effects such as hypotension, bradycardia, and sedation do not occur with a dose less than 1.5  $\mu\text{g/kg}$  or a maximum dose of 150  $\mu\text{g}$ . Clonidine as an adjuvant for lower-extremity block is much less defined. The limited data for lower-extremity techniques validates those of previous upper-extremity reviews.<sup>161,162</sup> The results are most notable with intermediate-acting agents.<sup>162</sup> A single study has compared the effect of lower-extremity peripheral block with/without clonidine. Casati et al.<sup>161</sup> reported the addition of clonidine 1  $\mu\text{g/kg}$  to 0.75% ropivacaine for patients undergoing foot surgery under sciatic-femoral block prolonged the time to first analgesia from 13.5 to 16.8 hours. Clonidine is often a component of lumbar plexus or

sciatic continuous infusions after hip, knee, or foot surgery.<sup>45,47,102</sup> However, the efficacy has not been established. A single study involving a continuous brachial plexus infusion of ropivacaine with or without clonidine failed to show a clinically significant effect.<sup>163</sup>

### Opioids

To date, there are no comparative studies evaluating the effect of opioids as adjuvants to lower-extremity single-dose or continuous techniques. Despite this lack of data, opioids, including morphine, sufentanil, and fentanyl, are often added to lumbar plexus infusions.<sup>45,47</sup> Investigations involving the brachial plexus report no difference in block onset, quality, or duration when opioids are added to the local anesthetic solution. A recent review concluded that the role of opioids in peripheral nerve block is not clinically relevant.<sup>151</sup>

### Other Adjuvants

Most studies investigating adjuvants such as neostigmine, hyaluronidase, and tramadol involve upper-extremity blocks.<sup>151</sup> A single study evaluating the efficacy of nonsteroidal antiinflammatory drugs as adjuvants reported that the addition of ketorolac to lidocaine for ankle block resulted in longer duration and improved analgesia after foot surgery compared with intravenously administered ketorolac.<sup>164</sup>

In summary, selection of a local anesthetic solution for lower-extremity peripheral blockade requires thoughtful consideration and is based on the duration of surgery, analgesic requirements, and anticipated rehabilitative efforts. The lowest effective dose and concentration should be used to minimize local anesthetic systemic and neural toxicity. Likewise, the addition of 1:200,000 or 1:400,000 epinephrine is recommended to facilitate detection of intravascular injection, as well as decrease local anesthetic levels. The role of other adjuvants is less defined; additional studies are required to determine the efficacy of clonidine, opioids, tramadol, and nonsteroidal antiinflammatory drugs in single-dose or continuous lower-extremity techniques.

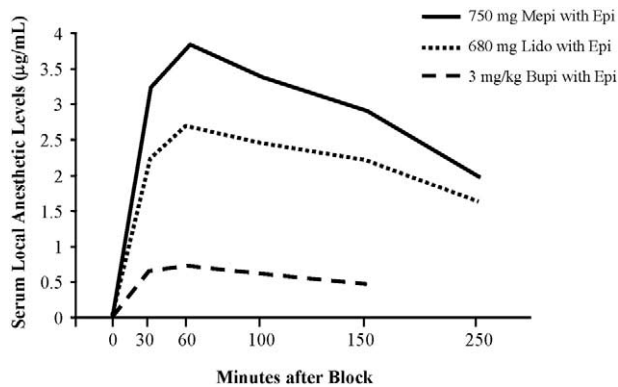
### Complications of Lower-Extremity Peripheral Nerve Blocks

Complications associated with peripheral nerve blockade are not common. Auroy and colleagues<sup>158</sup> prospectively evaluated serious complications after 21,278 PNBs in a 5-month period in France. Using a 95% confidence interval, they estimated the potential for serious complications per 10,000 PNBs to

be 0 to 2.6 deaths, 0.3 to 4.1 cardiac arrests, 0.5 to 4.8 neurologic injuries, and 3.9 to 11.2 seizures. There is a paucity of reports of complications specifically associated with lower-extremity PNBs as compared with upper-extremity PNBs. This is most likely related to their less common application rather than to inherent safety of the techniques.

**Local Anesthetic Systemic Toxicity.** The potential for systemic local anesthetic toxicity would seem to be very high for lower-extremity PNBs. Relatively large doses of local anesthetic are used for combined femoral and sciatic nerve blocks to anesthetize the entire lower extremity. However, there are only a few case reports of local anesthetic toxicity associated with lower-extremity PNBs. For instance, in Fanelli and colleagues' series of 2,175 patients undergoing femoral sciatic combined blocks, there were no systemic adverse local anesthetic reactions reported.<sup>95</sup> The apparent margin of safety seems to vary with individual block techniques. For instance, there are no case reports of toxicity after popliteal sciatic blockade, whereas there are several case reports of severe toxicity following lumbar plexus and proximal sciatic blocks.<sup>165-169</sup> Anatomic differences in the anatomy, primarily in the vascularity and presence of deep muscle beds in the area of blockade, are the most likely explanation for this discrepancy. Severe toxic reactions typically occur during the injection or immediately thereafter. This suggests that the mechanism of these events is commonly an unintentional intravascular injection of local anesthetic into the circulation, rather than absorption.<sup>3,170-173</sup> A forceful, rapid injection of local anesthetic carries a much higher risk of local anesthetic toxicity than a slow, gentle injection.<sup>174</sup> This is because the mean dose of local anesthetic that elicits the signs of central nervous system toxicity is much less during rapid intravascular injection as compared with that associated with slower absorption after appropriate deposition. After a lower-extremity peripheral nerve block, local anesthetic levels peak at approximately 60 minutes after deposition<sup>170,172,173</sup> (Fig 13). Perhaps this slow time to peak blood levels offers an explanation for the low incidence of toxic complications associated with absorption. Important measures to decrease the risk of severe toxicity include the use of epinephrine as an intravascular marker, slow methodical injection while avoiding high-injection pressure, frequent aspiration, constant assessment of the patient and vital signs, and prudent selection of local anesthetic concentration and volume.

**Proximal Spread (Neuraxial Block).** A potential needle misadventure of proximal peripheral nerve blocks is intrafascicular spread of the local anesthetic proximally toward the spinal cord, resulting in neuraxial blockade.<sup>26,30,175-177</sup> This is a



**Fig 13.** Local anesthetic levels following psoas or combined psoas/sciatic nerve blocks. Note the local anesthetic levels peak at approximately 60 minutes. Mepi, mepivacaine; epi, epinephrine; lido, lidocaine; bupi, bupivacaine. (Data from Farney et al.,<sup>3</sup> Odoom et al.,<sup>170</sup> and Simon et al.<sup>173</sup>)

particular concern with block techniques that involve needle placement at the level of the nerve roots or spinal nerves, such as paravertebral, and psoas compartment block. Forceful, fast injections within the dural cuffs or perineurium can result in unintentional spinal or epidural anesthesia.<sup>175</sup>

In their large series of severe complications associated with regional anesthesia, Auroy and colleagues<sup>165</sup> found the posterior approach to the lumbar plexus to have the highest incidence of complications of the lower extremity PNBs. With only 394 posterior lumbar plexus blocks reported, there were 5 serious complications in this cohort. Three of these complications, 1 cardiac arrest and 2 respiratory arrests, were directly attributed to central placement or diffusion of the local anesthetic to the epidural or intrathecal space.<sup>165</sup> Their recommendation was to manage this block with the same degree of vigilance as for a neuraxial block.

**Hemorrhagic Complications.** Several approaches for PNBs of the lower extremity involve deep needle penetration. These approaches include the psoas compartment approach to the lumbar plexus, the obturator nerve block, and the parasacral and classical approaches to the sciatic nerve. Despite the proximity of these deep nerves to vascular and hollow viscous structures, there are relatively few reports of needle misadventures.

Vascular puncture during femoral nerve block placement has been reported to be as frequent as 5.6%.<sup>178</sup> However, few complications were reported after unintentional vascular puncture during femoral nerve block.<sup>179</sup> Kent et al.<sup>180</sup> reported a 0.2% (20/9,585) incidence of neuropathy after cardiac catheterization. Sixteen of these patients de-

veloped neuropathies from large retroperitoneal hematomas. Twenty percent of these patients had persistent, mild sensory, or motor neuropathy at long-term follow-up. The other 4 patients had groin hematomas. In all of these patients, the neuropathy resolved.

Retroperitoneal hematoma formation after psoas compartment block has been reported by several investigators.<sup>2,181,182</sup> To reach the lumbar plexus, the needle must transverse multiple muscle and other tissue layers.<sup>183</sup> The combination of its deep location and inability to apply pressure after an inadvertent puncture of deeply situated blood vessels supplying the local muscles and other structures may make this block less suitable in the setting of anticoagulation as compared with other more superficial lower extremity nerve blocks. Conservative management of retroperitoneal hematoma is recommended unless the patient develops hypotension unresponsive to volume resuscitation.<sup>181,184</sup>

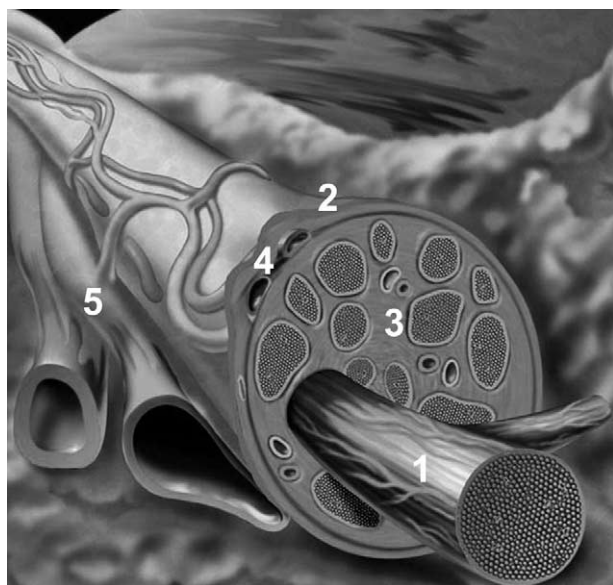
**Infectious Complications.** There are no case reports of infection after single-injection, lower-extremity PNBs. Cuvillon et al.<sup>178</sup> reported on the incidence of bacterial complications associated with the use of continuous femoral nerve blocks. In their cohort of 208 patients, 57% had positive bacterial colonization of the catheter at 48 hours postoperatively. Three patients had transitory symptoms of bacteremia that resolved with removal of the catheter. There were no long-term sequelae related to these positive catheter cultures. Two case reports of psoas abscess requiring drainage and intravenous antibiotic therapy has been reported in patients who received a continuous femoral nerve block.<sup>185,186</sup>

## Neurologic Complications

Although there are relatively few published reports of anesthesia-related nerve injury associated with the use of PNBs,<sup>95,158,165</sup> it is likely that the incidence is underestimated. The less frequent clinical application of lower-extremity nerve blocks may be the main reason that there are even fewer reports of anesthesia-related nerve injury associated with lower-extremity PNBs as compared with upper-extremity PNBs.<sup>187</sup>

Neurologic complications after lower-extremity PNB can be related to a variety of factors related to the block including needle trauma, intraneuronal injection, and neuronal ischemia. However, a search for other causes should include surgical factors such as positioning, retractor injury, and hematoma formation. In many instances, the neurologic injury may be a result of a combination of these factors.





**Fig 14.** Organization of a peripheral nerve: 1, nerve fascicle with endoneurium; 2, epineurial sheath enveloping the bundle of fascicles; 3, connective tissue inside the epineurial sheath; 4, epineurial blood vessels; 5, neighboring vasculature.

**Peripheral Nerves: Functional Anatomy and Mechanisms of Nerve Injury.** The functional anatomy of the peripheral nerve is important for understanding the mechanisms of peripheral nerve injury. A peripheral nerve is a complex structure consisting of fascicles held together by the epineurium, an enveloping, external connective sheath (Fig 14). Each fascicle contains many nerve fibers and capillary blood vessels embedded in a loose connective tissue, the endoneurium. The perineurium is a multilayered epithelial sheath that surrounds individual fascicles. Nerve fibers depend on a specific endoneurial environment for their function. This is different than the extraneural interstitium. Peripheral nerves are richly supplied by an extensive vascular network in which the endoneurial capillaries have endothelial “tight junctions,” a peripheral analogy to the “blood-brain barrier.” The entire neurovascular bed is regulated by the sympathetic nervous system and its blood flow can be as high as 30 to 40 mL/100 g per minute.<sup>188</sup> In addition to conducting nerve impulses, nerve fibers also maintain axonal transport of various functionally important substances, such as proteins and precursors for receptors and transmitters. This process is highly dependent on oxidative metabolism. Any of these structures and functions can be deranged during a traumatic nerve injury, with the possible result of temporary or permanent impairment or loss of neural function.

**Direct Needle Trauma.** Most needles available for PNBs are manufactured as short-bevel needles (i.e., angles 30°–45°). The needle designs are largely based on the work of Selander and colleagues,<sup>189</sup> who showed that the risk of perforating a nerve fascicle was significantly lower when a short-bevel (45°) needle was used compared with a standard long-bevel (12°–15°) needle. In contrast, the work of Rice and McMahon<sup>190</sup> suggested that the short-beveled needles might cause more mechanical damage than the long-beveled needles when purposefully advanced through a nerve in vitro. In their experiment, after deliberately penetrating the largest fascicle of rat sciatic nerves with 12° to 27° beveled injection needles, the degree of neural trauma on histologic examination was greater with short-beveled needles. The sharp needles produced clean cuts and the blunt needles produced noncongruent cuts on the microscopic images. In addition, the cuts produced by the sharper needles recovered faster and more completely than the irregular, more traumatic injuries caused by the blunter short-beveled needles.<sup>190</sup> Despite the lack of consistent data and no randomized controlled trials in humans, the theoretical advantage of short-beveled needles in reducing the risk of nerve penetration has had an influence on manufacturers and practitioners. Most needles manufactured for PNB placement are, today, short-beveled needles.

The clinical significance of isolated, direct needle trauma, however, remains unclear. For instance, during femoral arterial cannulation, it is likely that the needle is often inserted into the femoral nerve, yet injuries to the nerve are rare, and are usually attributed to hematoma formation.<sup>184</sup> It is possible that a needle-related trauma without injection results in injury of a lesser magnitude, which readily heals and may go undetected. In contrast, needle trauma coupled with injection of local anesthetic into the nerve may carry a risk for much more severe injury.

**Intraneural Injection.** Little is known about how to avoid or recognize insertion of a needle into a nerve or how to avoid an intraneuronal injection. Pain with injection has long been cited as the cardinal sign of intraneuronal injection. However, multiple case reports of neurologic injury suggest that pain may not be reliable as a sole warning sign of impending nerve injury.<sup>191–194</sup> Experimental evidence suggests that intraneural injection may be associated with pain on injection but also with a resistance to needle advancement or an increased pressure on injection of local anesthetic.<sup>195</sup> In a model of nerve injury by Selander et al.,<sup>195</sup> a pressure of at least 19 psi was required to inject solution into a nerve fascicle of a rabbit sciatic nerve. Injec-

tion into a nerve fascicle using such high pressures may result in rupture of the fascicle and the perineurium, with consequent histologic evidence of disruption of the neural anatomy. A more recent study using a dog model of nerve injury suggested that neurologic injury with intraneural injections is associated with high-injection pressures.<sup>196</sup> Specifically, only intraneural injections resulting in pressures greater than 20 psi were associated with clinically detectable neurologic deficits as well as histologic evidence of injury to nerve fascicles. These experiments suggest that injection pressures in excess of 20 psi during nerve block injection may be indicative of an intraneural injection and may carry a risk of nerve injury.

**Neuronal Ischemia.** The perineurium is a tough and resistant tissue layer. An injection into this compartment or a fascicle can cause a prolonged increase in endoneurial pressure, exceeding the capillary perfusion pressure. This pressure, in turn, can result in endoneurial ischemia.<sup>197</sup> The addition of vasoconstricting agents theoretically can enhance ischemia because of the resultant vasoconstriction and reduction in blood flow. The addition of epinephrine was shown in vitro to decrease the blood supply to intact nerves in the rabbit.<sup>195</sup> However, in patients undergoing lower-extremity surgery, the addition of epinephrine to the local anesthetic solution used in combined femoral and sciatic nerve blocks was not shown to be a risk factor for the development of post-block nerve dysfunction.<sup>95</sup>

### Risk Factors for Neuropathy After PNB

Few investigations exist regarding neurologic complications associated with lower-extremity PNB. The American Society of Anesthesiologists' closed-claims analysis of nerve injury associated with anesthesia showed a consistently low report of sciatic (5% of nerve injury claims) or femoral (2% of nerve injury claims) injuries.<sup>198</sup> Postoperative neurologic complications were more frequently reported after general anesthesia, 61% of the claims, and neuraxial anesthesia than after PNB. In this analysis, there was no specific discussion of lower-extremity neuropathy associated with PNB.<sup>198</sup>

In the report by Auroy and colleagues,<sup>158</sup> there were 4 neurologic injuries reported after PNB. The type of block performed and the nature of the injury are not reported. All of the neurologic injuries were reported within the first 48 hours postoperatively. All of these patients reported paresthesias during block placement or pain with injection. In all cases, the injury had the same topography as the associated paresthesia or pain. Fanelli et al.<sup>95</sup> reported on 2,175 combined sciatic-femoral nerve

blocks performed using a nerve stimulator and a technique of multiple injections. Consistent with the report of Auroy and coworkers, they reported an incidence of transient neurologic dysfunction in 1.7% of patients. There were no permanent neurologic injuries reported in this large cohort of patients. The only variable correlated with the development of postoperative neurologic dysfunction was tourniquet inflation pressure of >400 mm Hg. Unintended paresthesia was reported in 14% of patients in the Fanelli et al. study. By study protocol, no local anesthetic was injected if a paresthesia occurred.<sup>95</sup> Univariate analysis of potential risk factors for postoperative neurologic dysfunction did not demonstrate paresthesia as a risk factor. Indeed, in a more recent study from France,<sup>165</sup> a nerve stimulator was used in 9 of 12 documented nerve injuries. This suggests that the mechanism of nerve injury may be related to some events during and after the injection (e.g., intraneural injection), rather than to the method of nerve localization.

**Blocks Performed in Anesthetized Patients.** There are a several individual case reports of neuropathy after femoral or fascia iliaca block performed with a nerve stimulator or using a fascial click technique in anesthetized patients.<sup>56,199-201</sup> Although proper sedation and analgesia are essential ingredients for block success, maintenance of meaningful patient contact allows the patient to report pain or paresthesia on injection and may provide an additional margin of safety.

**Other Etiologies of Perioperative Lower-Extremity Neurologic Complications.** Nerve injuries are frequently attributed to the use of PNBs. However, neuropathy after abdominal or lower-extremity surgery is relatively common. There are a number of factors that have been implicated in the development of lower-extremity neuropathy. These factors include positioning, surgical factors, hematoma formation, compartment syndrome, and tourniquet palsy.

**Positioning.** Positioning injuries are thought to be caused mostly by compression or stretching of the nerve(s) or plexi as a result of patient positioning. Of the sciatic nerve injury claims in the closed-claims analysis of nerve injury associated with anesthesia, half were associated with the lithotomy or frog-leg operative positions.<sup>198</sup> In a prospective study of lower extremity neuropathies associated with the lithotomy position, nerve injury to the obturator, lateral femoral cutaneous, and sciatic nerves were observed.<sup>202</sup> Femoral nerve palsy is associated with deep hip flexion and extension associated with THA and repair of acetabular fractures.<sup>203,204</sup> Positioning nerve injuries are consistently correlated with the length of surgery.<sup>202,204-207</sup>

**Surgical Factors Leading to Neuropathy.** Some surgical procedures are associated with a high rate of nerve injury. For instance, femoral neuropathy is associated with operations that require deep pelvic exposure including acetabular fracture repair, in which the femoral nerve is relatively superficial and vulnerable to compression by retractors.<sup>203,206</sup> An incidence of nerve injury as high as 17% after ankle arthroscopy has been reported.<sup>208</sup> The superficial peroneal nerve, in particular, is prone to nerve injury during ankle arthroscopy because of its proximity to the dorsal arthroscopy portal.<sup>209</sup> The clinician's experience using the arthroscope is another factor associated with a high rate of nerve injury during this procedure.<sup>210</sup> This has been attributed to factors, such as joint distention, excessive traction, and extravasation of fluid during surgery.

**Compartment Syndrome.** A single case of compartment syndrome after revised forefoot arthroplasty under ankle block has been reported.<sup>211</sup> The diagnosis was delayed secondary to residual local anesthetic effects. However, prompt surgical intervention prevented long-term sequelae. This report emphasizes the need for vigilance in monitoring block resolution and patient positioning in the postoperative period. Consultation with the surgical team is of utmost importance when making a decision on the use of nerve blocks and their duration in patients with a risk of developing compartment syndrome.

**Tourniquet Neuropathy.** Tourniquet-induced neuropathy is well documented in the orthopedic literature and ranges from mild neuropraxia to permanent neurologic injury.<sup>211-215</sup> The incidence of tourniquet paralysis has been reported as 1 in 8,000 operations.<sup>216</sup> A prospective study of lower-extremity nerve blockade suggested that higher tourniquet inflation pressure (>400 mm Hg) was associated with an increased risk of transient nerve injury.<sup>95</sup> Current recommendations for appropriate use of the tourniquet include the maintenance of a pressure of no more than 150 mm Hg greater than the systolic blood pressure and deflation of the tourniquet every 90 to 120 minutes.<sup>217</sup> Even with these recommendations, posttourniquet application neuropraxia may occur, particularly in the setting of preexisting neuropathy.<sup>116,121</sup>

**Compressive Hematoma.** Compressive hematoma formation leading to neuropathy has been associated with both needle misadventures during performance of lower extremity PNB and anticoagulation.<sup>2,185</sup> As opposed to spinal or epidural hematoma, in all cases, neuropathy from this etiology has resolved completely.<sup>181,182,218-220</sup> Little data exist regarding the safety of peripheral nerve block in anticoagulated patients. The American Society of Re-

gional Anesthesia and Pain Medicine has published guidelines regarding this issue.<sup>221</sup> However, these reports emphasize the important differences in the risk-benefit ratio of peripheral nerve blocks compared with neuraxial blocks in patients receiving anticoagulant therapy.

## Evaluating the Patient After Lower-Extremity Peripheral Nerve Block

### Assessment of Lower-Extremity PNBs

Neal has proposed a simple and effective system for assessing the adequacy of lower-extremity PNBs<sup>220</sup> (Fig 15A-D). Based on a well-known system for assessing the upper extremity, the lower-extremity evaluation uses 4 Ps: push, pull, pinch, and punt. Push evaluates the adequacy of sciatic nerve block by asking the patient to push against the examiner's hand or "to step on the gas" with their foot. Pull checks the strength of the adductors of the thigh to assess obturator nerve blockade. The examiner abducts the thigh and asks the patient to pull their thigh to the midline. Pinch refers to the evaluation of the lateral femoral cutaneous nerve. A pinch on the lateral proximal thigh will check the adequacy of blockade of the lateral femoral cutaneous nerve. Finally, punt assesses the degree of motor blockade in the femoral nerve distribution. The examiner supports the patient's knee lifting it off the bed and asks the patient to punt an imaginary football. This maneuver requires quadriceps contraction to extend the leg and will be limited by femoral nerve blockade.

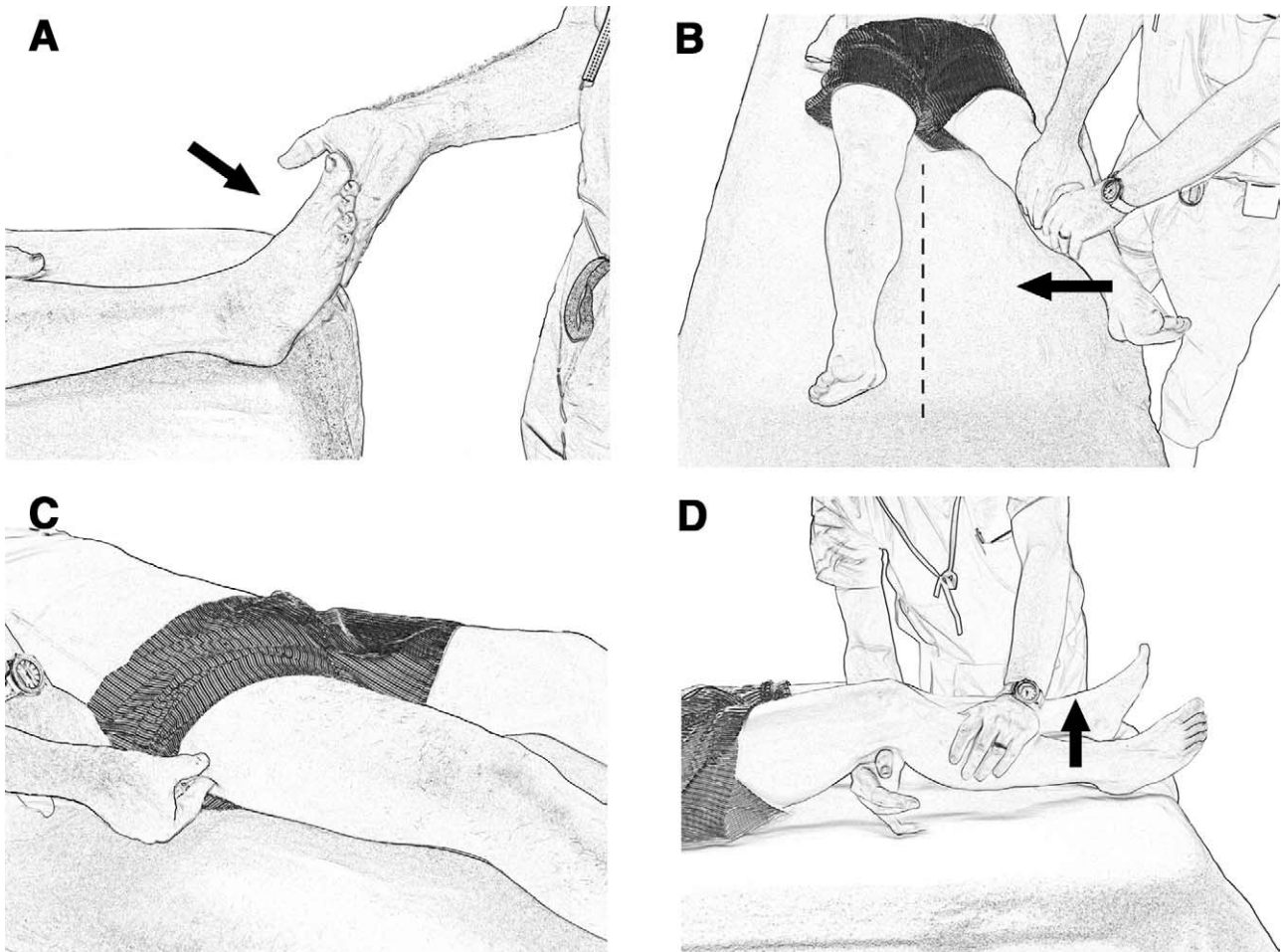
### Discharge Criteria

The ability to ambulate independently is an important consideration for patients receiving lower extremity PNBs. Klein et al.<sup>222</sup> have examined the controversy of long-lasting analgesia versus potential complications from insensate extremities after PNB in ambulatory surgery patients. They prospectively studied 1,791 patients receiving either upper- or lower-extremity nerve block with ropivacaine 0.5% and being discharged home the same day. There was a single complication related to a fall after combined femoral and sciatic nerve blocks. The authors attributed the low rate of complications to the immobilization related to the surgical procedure and generally cautious nature of postsurgical patients. Sample discharge instructions for patients with single injection and continuous lower extremity peripheral nerve blocks can be found in Table 5.

### Future Directions

Lower-extremity peripheral nerve blocks provide unquestioned superiority of analgesia after lower-





**Fig 15.** Assessment of lower-extremity nerve block by the Four P's acronym. (A) Push; inability to plantar flex the foot against resistance indicates sciatic nerve blockade. (B) Pull: the anesthesiologist resists the patient's attempt to adduct the leg toward the midline. Weakness signals conduction block of the obturator nerve. (C) Pinch: inability to detect a pinch on the proximal lateral thigh shows anesthesia within the lateral femoral cutaneous nerve distribution. (D) Punt: the anesthesiologist raises the knee and asks the patient to extend the knee against resistance. Inability to perform this task signals successful femoral nerve block. (Reprinted with permission.<sup>220</sup> Copyright 2002 by the American Society of Regional Anesthesia and Pain Medicine.)

extremity surgery compared with traditional intravenous narcotic therapy for the duration of the block. Research efforts directed toward extending the duration of analgesia that these techniques can provide should be supported. The current application of continuous infusion therapy with indwelling perineural catheters is probably just a first step toward this goal. Much work is needed to complete our understanding of the ideal delivery devices and infusates. Further efforts to prolong analgesia may include improved drug design, such as controlled release local anesthetics, or innovative additives.

Clearly, these techniques have a wider application for postoperative analgesia than is currently used. Further research efforts should be directed toward improving the ease of performing these techniques. Imaging devices that improve visual-

ization of the structures to be anesthetized may decrease the failure rate, thereby increasing their use in many anesthesia practices.

Finally, although there is a paucity of reported complications following lower-extremity PNBs, they are not without risks. Further efforts to delineate the role of injection pressure and needle design on nerve injury should be supported. Local anesthetic toxicity still complicates the use of PNBs. Efforts to improve the early detection of intravascular local anesthetic injection would be welcomed by all practitioners. An antidote to local anesthetic overdose would be added to every formulary. We envision a future in which the use of lower-extremity PNBs is widely taught and applied by all anesthesiologists not just for regional anesthesia enthusiasts.

**Table 5. Patient Instructions After Lower-Extremity Nerve Block**

You have received an injection near one of your nerves in your leg to help you with your pain after surgery. Precautions that you should take are:

1. DO NOT DRIVE while your leg is numb.
2. You must use your walker, crutches, or wheelchair until the nerve block has worn off.
3. Keep your leg elevated as much as possible for the first 24 hours after surgery to help prevent swelling.
4. Keep your leg in the brace at all times except when doing physical therapy until your surgeon tells you to take it off.
5. Do not use heating pads on your leg while it is numb.
6. The numbness in your leg will wear off completely about an hour after you notice that you can feel tingling in the numb part. Please take your pain medications when the numbness begins to wear off and you feel the tingling.
7. If you are ready for bed and the numbness has not worn off, please take your pain medication before you go to bed.

#### Instructions for Patients Receiving Continuous Lower-Extremity Blocks

Your anesthesia doctor has placed a small tube near the nerve to your leg to decrease the pain you feel after surgery. This is a very effective way to control pain when it is added to the other pain medications your surgeon has given you.

Precautions you should use during this treatment are:

1. DO NOT DRIVE while you have the catheter in place.
2. You must use your walker, crutches, or wheelchair until the nerve block has worn off and the catheter has been removed.
3. Keep your leg elevated as much as possible for the first 24 hours after surgery to help prevent swelling.
4. Keep your leg in the brace at all times except when doing physical therapy until your surgeon tells you to take it off.
5. Do not use heating pads on your leg while it is numb.
6. The medication you are getting through the pump device is not as strong as the first medicine that you got. When the numbness begins to wear off, please push the extra medication button. Wait 15 minutes and then take your pain pills if you need more pain relief. Once the initial block wears off you should be able to wiggle your toes and make a muscle in your thigh.
7. If you have questions about the pump or your pain medications call the pager number given to you.

## Acknowledgment

The authors would like to thank Anita Yeager, BS, Coordinator of Information/Publications Services in the Department of Anesthesiology at the University of Florida, for her calm aplomb in editing this beast of a manuscript. The authors also thank Dr Joseph M. Neal, Editor-in-Chief of *Regional Anesthesia and Pain Medicine*, for his patience with and guidance of this project. The authors thank you both wholeheartedly.

## References

1. Gray H. *Anatomy of the Human Body*. Philadelphia, PA: Lea & Fibiger; 1918.
2. Capdevila X, Macaire P, Dadure C, Choquet O, Biboulet P, Ryckwaert Y, D'Athis F. Continuous
3. Farny J, Girard M, Drolet P. Posterior approach to the lumbar plexus combined with a sciatic nerve block using lidocaine. *Can J Anaesth* 1994;41:486-491.
4. Chudinov A, Berkenstadt H, Salai M, Cahana A, Perel A. Continuous psoas compartment block for anesthesia and perioperative analgesia in patients with hip fractures. *Reg Anesth Pain Med* 1999;24:563-568.
5. Bouaziz H, Vial F, Jochum D, Macalou D, Heck M, Meuret P, Braun M, Laxenaire M-C. An evaluation of the cutaneous distribution after obturator nerve block. *Anesth Analg* 2002;94:445-449.
6. Available at: [http://www.nlm.nih.gov/research/visible/visible\\_human.html](http://www.nlm.nih.gov/research/visible/visible_human.html). Accessed May 3, 2004.
7. Cauhepe C, Oliver M, Colombani R, Railhac N. [The "3-in-1" block: myth or reality]. *Ann Fr Anesth Reanim* 1989;8:376-378.
8. Marhofer P, Nasel C, Sitzwohl C, Kapral S. Magnetic resonance imaging of the distribution of local anesthetic during the three-in-one block. *Anesth Analg* 2000;90:119-124.
9. Hopkins PM, Ellis FR, Halsall PJ. Evaluation of local anaesthetic blockade of the lateral femoral cutaneous nerve. *Anaesthesia* 1991;46:95-96.
10. Snell RS (ed). *Clinical Anatomy for Medical Students*. 2nd ed. Boston: Little Brown and Company; 1981: 272, 492, 479.
11. Hullander M, Spillane W, Leivers D, Balsara Z. The use of Doppler ultrasound to assist with sciatic nerve blocks. *Reg Anesth* 1991;16:282-284.
12. Snell RS (ed). *Clinical Anatomy for Medical Students*. 2nd ed. Boston: Little Brown and Company; 1981: 492.
13. Volka JD, Hadžić A, April E, Thys DM. The division of the sciatic nerve in the popliteal fossa: Anatomical implications for popliteal nerve blockade. *Anesth Analg* 2001;92:215-217.
14. Snell RS (ed). *Clinical Anatomy for Medical Students*. 2nd ed. Boston: Little Brown and Company; 1981: 479.
15. Chayen D, Nathan H, Chayen M. The psoas compartment block. *Anesthesiology* 1976;45:95-99.
16. Ho AM, Karmakar MK. Combined paravertebral lumbar plexus and parasacral sciatic nerve block for reduction of hip fracture in a patient with severe aortic stenosis. *Can J Anaesth* 2002;49:946-950.
17. Turker G, Uckunkaya N, Yavasoglu B, Yilmazlar A, Ozelik S. Comparison of the catheter-technique psoas compartment block and the epidural block for analgesia in partial hip replacement surgery. *Acta Anaesthesiol Scand* 2003;47:30-36.
18. Luber MJ, Greengrass R, Parker T. Patient satisfaction and effectiveness of lumbar plexus and sciatic nerve block for total knee arthroplasty. *J Arthroplasty* 2001;16:17-21.

19. Goroszeniuk T, di Vadi PP. Repeated psoas compartment blocks for the management of long-standing hip pain. *Reg Anesth Pain Med* 2001;26:376-378.
20. Gray H. *Anatomy of the Human Body*. Philadelphia, PA: Lea & Fibiger; 1918:416.
21. Brown DL. Psoas compartment block. In: Brow DL, ed. *Atlas of Regional Anesthesia*. 2nd ed. Philadelphia: Saunders; 1999:88-91.
22. Solanski D. Posterior lumbar plexus (psoas) block. In: Chelly JE, ed. *Peripheral Nerve Blocks: A Color Atlas*. Philadelphia, PA: Lippincott, Williams & Wilkins; 1999:90-92.
23. Bridenbaugh PO, Wedel DJ. The lower extremity: Somatic blockade. In: Cousins MJ, Bridenbaugh PO (eds). *Neural Blockade: in Clinical Anesthesia and Management of Pain*. Philadelphia, PA: Lippincott-Raven; 1998:374-376.
24. Winnie AP, Ramamurthy S, Durrani Z, Radonjic R. Plexus blocks for lower extremity surgery. *Anesthesiology Rev* 1974;1:11-16.
25. Aida S, Takahashi H, Shimoji K. Renal subcapsular hematoma after lumbar plexus block. *Anesthesiology* 1996;84:452-455.
26. Pousman RM, Mansoor Z, Sciard D. Total spinal anesthetic after continuous posterior lumbar plexus block. *Anesthesiology* 2003;98:1281-1282.
27. Reddy MB. Pneumocoele following psoas compartment block. *Anaesthesia* 2002;57:938-939.
28. Parkinson S, Mueller J, Little W, Bailey SL. Extent of blockade with various approaches to the lumbar plexus. *Anesth Analg* 1989;68:243-248.
29. Dalens B, Tanguy A, Vanneville G. Lumbar plexus block in children: A comparison of two procedures in 50 patients. *Anesth Analg* 1988;67:750-758.
30. Muravchick S, Owens WD. An unusual complication of lumbar plexus block: A case report. *Anesth Analg* 1976;55:350-352.
31. Matheny JM, Hanks GA, Rung GW, Blanda JB, Kalenak A. A comparison of patient-controlled analgesia and continuous lumbar plexus block after anterior cruciate ligament reconstruction. *Arthroscopy* 1993;9:87-90.
32. Pandin PC, Vandesteene A, d'Hollander AA. Lumbar plexus posterior approach: A catheter placement description using electrical stimulation. *Anesth Analg* 2002;95:1428-1431.
33. Goranson BD, Lang S, Cassidy JD, Dust WN, McKerrill J. A comparison of three regional anaesthesia techniques for outpatient arthroscopy. *Can J Anaesth* 1997;44:371-376.
34. Fletcher AK, Rigby AS, Heyes FL. Three-in-one femoral nerve block as analgesia for fractured neck of femur in the emergency department: A randomized, controlled trial. *Ann Emerg Med* 2003;41:227-233.
35. Mulroy MF, Larkin KL, Batra MS, Hodgson PS, Owens BD. Femoral nerve block with 0.25% or 0.5% bupivacaine improves postoperative analgesia following outpatient arthroscopic anterior cruciate ligament repair. *Reg Anesth Pain Med* 2001;26:24-29.
36. McCarty EC, Spindler KP, Tingstad E, Shyr Y, Higgins M. Does intraarticular morphine improve pain control with femoral nerve block after anterior cruciate ligament reconstruction? *Am J Sports Med* 2001;29:327-332.
37. Frost S, Grossfeld S, Kirkley A, Litchfield B, Fowler PK, Amendola A. The efficacy of femoral nerve block in pain reduction for outpatient hamstring anterior cruciate ligament reconstruction: A double-blind, prospective, randomized trial. *Arthroscopy* 2000;16:243-248.
38. Wang H, Boctor B, Verner J. The effect of single-injection femoral nerve block on rehabilitation and length of hospital stay after total knee replacement. *Reg Anesth Pain Med* 2002;27:139-144.
39. Williams BA, Kentor ML, Vogt MT, Williams JP, Chelly JE, Valalik S, Harner CD, Fu FH. Femoral-sciatic nerve blocks for complex outpatient knee surgery are associated with less postoperative pain before same-day discharge. *Anesthesiology* 2003;98:1206-1213.
40. Vloka JD, Hadžić A, Drobnik L, Ernest A, Reiss W, Thys DM. Anatomic landmarks for femoral nerve block: A comparison of four needle insertion sites. *Anesth Analg* 1999;89:1467-1470.
41. Winnie AP, Ramamurthy S, Durrani Z. The inguinal paravascular technic of lumbar plexus anesthesia: The "3-in-1 block." *Anesth Analg* 1973;52:989-996.
42. Lang SA, Yip RW, Chang P, Gerard M. The femoral 3-in-1 block revisited. *J Clin Anesth* 1993;5:292-296.
43. Seeberger M, Urwyler A. Paravascular lumbar plexus block: Block extension after femoral nerve stimulation and injection of 20 vs. 40 ml mepivacaine 10 mg/ml. *Acta Anaesthesiol Scand* 1995;39:769-773.
44. Singelyn F, Gouverneur JM. Extended "3-in-1" block after total knee arthroplasty: Continuous versus patient-controlled techniques. *Anesth Analg* 2000;91:176-180.
45. Singelyn F, Vanderelst P, Gouverneur JM. Extended femoral nerve sheath block after total hip arthroplasty: Continuous versus patient-controlled techniques. *Anesth Analg* 2001;92:455-459.
46. Chelly JE, Greger J, Gebhard R, Coupe K, Clyburn TA, Buckle R, Criswell A. Continuous femoral blocks improve recovery and outcome of patients undergoing total knee arthroplasty. *J Arthroplasty* 2001;16:436-445.
47. Capdevila X, Barthelet Y, Biboulet P, Ryckwaert Y, Rubenovitch J, d'Athis F. Effects of perioperative analgesic technique on the surgical outcome and duration of rehabilitation after major knee surgery. *Anesthesiology* 1999;91:8-15.
48. Singelyn FJ, Deyaert M, Joris D, Pendeville E, Gouverneur JM. Effects of intravenous patient-controlled analgesia with morphine, continuous epidural analgesia, and continuous "3-in-1" block on postoperative pain and knee rehabilitation after unilateral total knee arthroplasty. *Anesth Analg* 1998;87:88-92.



49. Griffith JP, Whiteley S, Gough MJ. Prospective randomized study of a new method of providing postoperative pain relief following femoropopliteal bypass. *Br J Surg* 1996;83:1735-1738.
50. Dauri M, Polzoni M, Fabbi E, Sidiropoulou T, Servetti S, Coniglione F, Mariani P, Sabato AF. Comparison of epidural, continuous femoral block and intraarticular analgesia after anterior cruciate ligament reconstruction. *Acta Anaesthesiol Scand* 2003;47:20-25.
51. Hirst GC, Lang SA, Dust WN, Cassidy JD, Yip RW. Femoral nerve block. Single injection versus continuous infusion for total knee arthroplasty. *Reg Anesth* 1996;21:292-297.
52. Capdevila X, Biboulet P, Morau D, Bernard N, Deschodt J, Lopez S, d'Athis F. Continuous three-in-one block for postoperative pain after lower limb orthopedic surgery: Where do the catheters go? *Anesth Analg* 2002;94:1001-1006.
53. Salinas FV, Neal JM, Sueda LA, Kopacz DJ, Liu SS. Prospective comparison of continuous femoral nerve block with nonstimulating catheter placement versus stimulating catheter-guided perineural placement in volunteers. *Reg Anesth Pain Med* 2004;29:212-220.
54. Dalens B, Vanneuville G, Tanguy A. Comparison of the fascia iliaca compartment with "3-in-1" block in children. *Anesth Analg* 1989;69:705-713.
55. Lopez S, Gros T, Bernard N, Plasse C, Capdevila X. Fascia iliaca compartment block for femoral bone fractures in prehospital care. *Reg Anesth Pain Med* 2003;28:203-207.
56. Atchabahian A, Brown AR. Postoperative neuropathy following fascia iliaca compartment blockade. *Anesthesiology* 2001;94:534-536.
57. Ganapathy S, Wasserman RA, Watson JT, Bennett J, Armstrong KP, Stockall CA, Chess DG, MacDonald C. Modified continuous femoral three-in-one block for postoperative pain after total knee arthroplasty. *Anesth Analg* 1999;89:1197-1202.
58. Paut O, Sallabery M, Schreiber-Deturmeny E, Remond C, Bruguerolle B, Camboulives J. Continuous fascia iliaca compartment block in children: A prospective evaluation of plasma bupivacaine concentrations, pain scores, and side effects. *Anesth Analg* 2001;92:1159-1163.
59. Wassef M. Interadductor approach to obturator nerve blockade for spastic conditions of adductor thigh muscles. *Reg Anesth* 1993;18:13-17.
60. McNamee DA, Parks L, Milligan KR. Post-operative analgesia following total knee replacement: An evaluation of the addition of an obturator nerve block to combined femoral and sciatic nerve block. *Acta Anaesthesiol Scand* 2002;46:95-99.
61. Macalou D, Trueck S, Meuret P, Heck M, Vial F, Ouloguem S, Capdevila X, Virion J-M, Bouaziz H. Postoperative analgesia after total knee replacement: The effect of an obturator nerve block added to the femoral 3-in-1 nerve block. *Anesth Analg* 2004;99:251-254.
62. Karacalar A, Karacalar S, Uckunkaya N, Sahin S, Ozcan B. Combined use of axillary block and lateral femoral cutaneous nerve block in upper-extremity injuries requiring large skin grafts. *J Hand Surg [Am]* 1998;23:1100-1105.
63. Maccani RM, Wedel DJ, Melton A, Gronert GA. Femoral and lateral femoral cutaneous nerve block for muscle biopsies in children. *Paediatr Anaesth* 1995;5:223-227.
64. Jones SF, White A. Analgesia following femoral neck surgery. Lateral cutaneous nerve block as an alternative to narcotics in the elderly. *Anaesthesia* 1985;40:682-685.
65. Coad NR. Postoperative analgesia following femoral-neck surgery—A comparison between 3 in 1 femoral nerve block and lateral cutaneous nerve block. *Eur J Anaesthesiol* 1991;8:287-290.
66. Shannon J, Lang SA, Yip RW, Gerard M. Lateral femoral cutaneous nerve block revisited. A nerve stimulator technique. *Reg Anesth* 1995;20:100-104.
67. Sharrock NE. Inadvertent "3-in-1 block" following injection of the lateral cutaneous nerve of the thigh. *Anesth Analg* 1980;59:887-888.
68. van der Wal M, Lang SA, Yip RW. Trans-sartorial approach for saphenous nerve block. *Can J Anaesth* 1993;40:542-546.
69. De Mey JC, Deruyck LJ, Cammu G, De Baeremaeker LE, Mortier EP. A paravenous approach for the saphenous nerve block. *Reg Anesth Pain Med* 2001;26:504-506.
70. Comfort VK, Lang SA, Yip RW. Saphenous nerve anaesthesia—A nerve stimulator technique. *Can J Anaesth* 1996;43:852-857.
71. Bouaziz H, Henhamou D, Narchi P. A new approach for saphenous nerve block (letter). *Reg Anesth* 1996;21:490.
72. Tokat O, Turker YG, Uckunkaya N, Yilmazlar A. A clinical comparison of psoas compartment and inguinal paravascular blocks combined with sciatic nerve block. *J Int Med Res* 2002;30:161-167.
73. Morau D, Lopez S, Biboulet P, Bernard N, Amar J, Capdevila X. Comparison of continuous 3-in-1 and fascia iliaca compartment blocks for postoperative analgesia: Feasibility, catheter migration, distribution of sensory block, and analgesic efficacy. *Reg Anesth Pain Med* 2003;28:309-314.
74. Capdevila X, Biboulet P, Bouregba M, Barthelet Y, Rubenovitch J, d'Athis F. Comparison of the three-in-one and fascia iliaca compartment blocks in adults: Clinical and radiographic analysis. *Anesth Analg* 1998;86:1039-1044.
75. Kaloul I, Guay J, Cote C, Fallaha M. The posterior lumbar plexus (psoas compartment) block and the three-in-one femoral nerve block provide similar postoperative analgesia after total knee replacement. *Can J Anaesth* 2004;51:45-51.
76. Mansour N. Sub-sartorial saphenous nerve block with the aid of nerve stimulator. *Reg Anesth* 1993;28:266-268.

77. Morris GF, Lang SA, Dust WN, Van der Wal M. The parasacral sciatic nerve block. *Reg Anesth* 1997;22:223-228.
78. Gaertner E, Lascrain P, Venet C, Maschino X, Zamfir A, Lupescu R, Hadžić A. Continuous parasacral sciatic block: A radiographic study. *Anesth Analg* 2004;98:831-834.
79. Winnie AP. Regional anesthesia. *Surg Clin North Am* 1975;55:861-892.
80. Raj PP, Parks RI, Watson TD, Jenkins MT. A new single-posterior supine approach to sciatic-femoral nerve block. *Anesth Analg* 1975;54:489-494.
81. McNichol LR. Sciatic nerve block for children: Sciatic nerve block by anterior approach for postoperative pain relief. *Anaesthesia* 1985;40:410-414.
82. Guardini R, Waldron BA, Wallace WA. Sciatic nerve block: A new lateral approach. *Acta Anaesthesiol Scand* 1985;29:515-519.
83. Labat G. *Regional Anesthesia: Its Technic and Clinical Application*. Philadelphia, PA: Saunders; 1922.
84. Chang PC, Lang SA, Yip RW. Reevaluation of the sciatic nerve block. *Reg Anesth* 1993;18:18-23.
85. Franco CD. Posterior approach to the sciatic nerve in adults: Is Euclidean geometry still necessary? *Anesthesiology* 2003;98:723-728.
86. Ichiyanagi K. Sciatic nerve block: Lateral approach with patient supine. *Anesthesiology* 1959;20:601-604.
87. Beck GP. Anterior sciatic nerve block. *Anesthesiology* 1963;24:222-224.
88. Magora F, Pessachovitch B, Shoham I. Sciatic nerve block by the anterior approach for operations on the lower extremity. *Br J Anaesth* 1974;46:121-123.
89. Chelly JE, Delaunay L. A new anterior approach to the sciatic nerve block. *Anesthesiology* 1999;91:1655-1660.
90. Vloka D, Hadžić A, April E, Thys DM. Anterior approach to the sciatic nerve block: The effects of leg rotation. *Anesth Analg* 2001;92:460-462.
91. Ericksen ML, Swenson JD, Pace NL. The anatomic relationship of the sciatic nerve to the lesser trochanter: Implications for anterior sciatic nerve block. *Anesth Analg* 2002;95:1071-1074.
92. Dalens B, Tanguy A, Vanneuville G. Sciatic nerve blocks in children: Comparison of the posterior, anterior, and lateral approaches in 180 pediatric patients. *Anesth Analg* 1990;70:131-137.
93. Chowdary K, Splinter W. Sciatic nerve block: A new approach. *Can J Anesth* 2003;50:A51 (abstr).
94. di Benedetto P, Casati A, Bertini L, Fanelli G. Posterior subgluteal approach to block the sciatic nerve: Description of the technique and initial clinical experiences. *Eur J Anaesthesiol* 2002;19:682-686.
95. Fanelli G, Casati A, Garancini P, Torri G. Nerve stimulator and multiple injection technique for upper and lower limb blockade: Failure rate, patient acceptance, and neurologic complications. Study Group on Regional Anesthesia. *Anesth Analg* 1999;88:847-852.
96. Rorie DK, Byer DE, Nelson DO, Sittipong R, Johnson KA. Assessment of block of the sciatic nerve in the popliteal fossa. *Anesth Analg* 1980;59:371-376.
97. Hansen E, Eshelman MR, Cracchiolo A. Popliteal fossa neural blockade as the sole anesthetic technique for outpatient foot and ankle surgery. *Foot Ankle Int* 2000;21:38-44.
98. Rongstad K, Mann RA, Prieskorn D, Nicholson S, Horton G. Popliteal sciatic nerve block for postoperative analgesia. *Foot Ankle Int* 1996;17:378-382.
99. Vloka JD, Hadžić A, Mulcare R, Lesser JB, Koorn R, Thys DM. Combined popliteal and posterior cutaneous nerve of the thigh blocks for short saphenous vein stripping in outpatients: An alternative to spinal anesthesia. *J Clin Anesth* 1997;9:618-622.
100. Tobias JD, Mencia GA. Popliteal fossa block for postoperative analgesia after foot surgery in infants and children. *J P Orthop* 1999;19:511-514.
101. Vloka JD, Hadžić A, Koorn R, Thys D. Supine approach to the sciatic nerve in the popliteal fossa. *Can J Anaesth* 1996;43:964-967.
102. Singelyn F, Aye F, Gouverneur JM. Continuous popliteal sciatic nerve block: An original technique to provide postoperative analgesia after foot surgery. *Anesth Analg* 1997;84:383-386.
103. Ilfeld BM, Morey TE, Wang RD, Enneking FK. Continuous popliteal sciatic nerve block for postoperative pain control at home: A randomized, double-blinded, placebo-controlled study. *Anesthesiology* 2002;97:959-965.
104. Schimek F, Deusch H. New technique of sciatic nerve block in the popliteal fossa. *Eur J Anaesth* 1995;12:163-169.
105. Levecque JP, Borne M, Saissy JM. Analgesia with continuous lateral posterior tibial nerve block (letter). *Reg Anesth Pain Med* 1999;24:191-192.
106. Gouverneur JM. Sciatic nerve block in the popliteal fossa with atraumatic needles and nerve stimulation. *Acta Anaesthesiol Belg* 1985;36:391-399.
107. Singelyn F, Gouverneur JM, Gribomont BF. Popliteal sciatic nerve block aided by a nerve stimulator: A reliable technique for foot and ankle surgery. *Reg Anesth* 1991;16:278-281.
108. Hadžić A, Vloka JD, Singson R, Santos AC, Thys DM. A comparison of intertendinous and classical approaches to popliteal nerve block using magnetic resonance imaging simulation. *Anesth Analg* 2002;94:1321-1324.
109. Benzon HT, Kim C, Benzon HP, Silverstein ME, Jericho B, Prillaman K, Buenaventura R. Correlation between evoked motor response of the sciatic nerve and sensory blockade. *Anesthesiology* 1997;87:547-552.
110. Paqueron X, Bouaziz H, Macalou D, Labaille T, Merle M, Laxenaire MC, Benhamou D. The lateral approach to the sciatic nerve at the popliteal fossa: One or two injections? *Anesth Analg* 1999;89:1221-1225.
111. Zetlaoui PJ, Bouaziz H. Lateral approach to the sciatic nerve in the popliteal fossa. *Anesth Analg* 1998;87:79-82.
112. Vloka JD, Hadžić A, Kitain E, Lesser JB, Kuroda M, April EW, Thys DM. Anatomic considerations for

- sciatic nerve block in the popliteal fossa through the lateral approach. *Reg Anesth* 1996;21:414-418.
113. di Benedetto P, Casati A, Bertini L, Fanelli G, Chelly JE. Postoperative analgesia with continuous sciatic nerve block after foot surgery: A prospective, randomized comparison between the popliteal and subgluteal approaches. *Anesth Analg* 2002;94:996-1000.
  114. Chelly JE, Greger J, Casati A, Al Samsam T, McGarvey W, Clanton T. Continuous lateral sciatic blocks for acute postoperative pain management after major ankle and foot surgery. *Foot Ankle Int* 2002;23:749-752.
  115. Sutherland ID. Continuous sciatic nerve infusion: Expanded case report describing a new approach. *Reg Anesth Pain Med* 1998;23:496-501.
  116. Schurman DJ. Ankle-block anesthesia for foot surgery. *Anesthesiology* 1976;44:348-352.
  117. Pinzur MS, Morrison C, Sage R, Stuck R, Osterman H, Vrbos L. Syme's two-stage amputation in insulin-requiring diabetics with gangrene of the forefoot. *Foot Ankle* 1991;11:394-396.
  118. Harvey CK. Dilute lidocaine ankle blocks in the diagnosis of sympathetically maintained pain. *J Am Podiatr Med Assoc* 1997;87:473-477.
  119. Delgado-Martinez AD, Marchal-Escalona JM. Supramalleolar ankle block anesthesia and ankle tourniquet for foot surgery. *Foot Ankle Int* 2001;22:836-838.
  120. Gerbert J. The location of the terminal branching of the posterior tibial nerve and its effect on administering a posterior tibial nerve block. *J Am Podiatry Assoc* 1971;61:8-11.
  121. Lichtenfeld NS. The pneumatic ankle tourniquet with ankle block anesthesia for foot surgery. *Foot Ankle* 1992;13:344-349.
  122. Colgrove RC. Posterior tibial nerve block. *Foot Ankle Int* 2001;22:839-840.
  123. Wassef MR. Posterior tibial nerve block. A new approach using the bony landmark of the sustentaculum tali. *Anaesthesia* 1991;46:841-844.
  124. Sharrock NE, Waller JF, Fierro LE. Midtarsal block for surgery of the forefoot. *Br J Anaesth* 1986;58:37-40.
  125. Needoff M, Radford P, Costigan P. Local anesthesia for postoperative pain relief after foot surgery: A prospective clinical trial. *Foot Ankle Int* 1995;6:11-13.
  126. Mineo R, Sharrock NE. Venous levels of lidocaine and bupivacaine after midtarsal ankle block. *Reg Anesth* 1992;17:47-49.
  127. Brown EM, McGriff JT, Malinowski RW. Intravenous regional anaesthesia (Bier block): Review of 20 years' experience. *Can J Anesth* 1989;36:307-310.
  128. Ruben SS, Sklar J. Intravenous regional anesthesia with clonidine in the management of complex regional pain syndrome of the knee. *J Clin Anesth* 2002;14:87-91.
  129. Henderson CL, Warriner CB, McEwen JA, Merrick PM. A North American survey of intravenous regional anesthesia. *Anesth Analg* 1997;85:858-863.
  130. Lehman WL, Jones WW. Intravenous lidocaine for anesthesia in the lower extremity. A prospective study. *J Bone Joint Surg [Am]* 1984;66:1056-1060.
  131. Nusbaum LM, Hamelberg W. Intravenous regional anesthesia for surgery on the foot and ankle. *Anesthesiology* 1986;64:91-92.
  132. Al Metwalli R, Mowafi HA. A modification of the inter-cuff technique of IVRA for use in knee arthroscopy. *Can J Anaesth* 2002;49:687-689.
  133. Cuvillon P, Ripart J, Jeannes P, Mahamat A, Boisson C, L'Hermite J, Vernes E, de la Coussaye JE. Comparison of the parasacral approach and the posterior approach, with single- and double-injection techniques, to block the sciatic nerve. *Anesthesiology* 2003;98:1436-1441.
  134. Kilpatrick AW, Coventry DM, Todd JG. A comparison of two approaches to sciatic nerve block. *Anaesthesia* 1992;47:155-157.
  135. Taboada M, Alvarez J, Cortes J, Rodriguez J, Rabanal S, Gude F, Atanassoff A, Atanassoff PG. The effects of three different approaches on the onset time of sciatic nerve blocks with 0.75% ropivacaine. *Anesth Analg* 2004;98:242-247.
  136. Hadžić A, Vloka JD. A comparison of the posterior versus lateral approaches to the block of the sciatic nerve in the popliteal fossa. *Anesthesiology* 1998;88:1480-1486.
  137. McLeod DH, Wong DH, Claridge RJ, Merrick PM. Lateral popliteal sciatic nerve block compared with subcutaneous infiltration for analgesia following foot surgery. *Can J Anaesth* 1994;41:673-676.
  138. Singelyn FJ. Single-injection applications for foot and ankle surgery. *Best Pract Res Clin Anaesthesiol* 2002;16:247-254.
  139. Kaiser H, Niesel HC, Klimpel L. Influence of minimum current for peripheral nerve stimulation on the latency and success rate of sciatic blockade. *Reg Anesth* 1988;11:92-97.
  140. Davies MJ, McGlade DP. One hundred sciatic nerve blocks: A comparison of localization techniques. *Anaesth Intensive Care* 1993;21:76-78.
  141. Rosenblatt R. Continuous femoral anesthesia for lower extremity surgery. *Anesth Analg* 1980;59:631-632.
  142. Tetzlaff JE, Andrish J, O'Hara J Jr, Dilger J, Yoon HJ. Effectiveness of bupivacaine administered via femoral nerve catheter for pain control after anterior cruciate ligament repair. *J Clin Anesth* 1997;9:542-545.
  143. Singelyn F, Gouverneur JM. Postoperative analgesia after total hip arthroplasty: IV PCA with morphine, patient-controlled epidural analgesia, or continuous "3-in-1" block?: A prospective evaluation by our acute pain service in more than 1300 patients. *J Clin Anesth* 1999;11:550-554.
  144. Bailey SL, Parkinson SK, Little WL, Simmerman SR. Sciatic nerve block: A comparison of single versus double injection technique. *Reg Anesth* 1994;19:9-13.
  145. Cuvillon P, Ripart J, Jeannes P, Mahamat A, Boisson C, L'Hermite J, Vernes E, de la Coussaye JE. Comparison of the parasacral approach and the posterior ap-



- proach, with single- and double-injection techniques, to block the sciatic nerve. *Anesthesiology* 2003;98:1436-1441.
146. Casati A, Fanelli G, Beccaria P, Magistris L, Albertin A, Torri G. The effects of single or multiple injections on the volume of 0.5% ropivacaine required for femoral nerve blockade. *Anesth Analg* 2001;93:83-86.
  147. Kirchmair L, Entner T, Wissel J, Moriggl B, Kapral S, Mitterschiffthaler G. A study of the paravertebral anatomy for ultrasound-guided posterior lumbar plexus block. *Anesth Analg* 2001;93:477-481.
  148. Kirchmair L, Entner T, Kapral S, Mitterschiffthaler G. Ultrasound guidance for the psoas compartment block: An imaging study. *Anesth Analg* 2002;94:706-710.
  149. Marhofer P, Schrogendorfer K, Koinig H, Kapraal S, Weinstabl C, Mayer N. Ultrasonographic guidance improves sensory block and onset time of three-in-one blocks. *Anesth Analg* 1997;85:854-857.
  150. Marhofer P, Schrogendorfer K, Wallner T, Koinig H, Mayer N, Kapral S. Ultrasonography guidance reduces the amount of local anesthetic for 3-in-1 blocks. *Reg Anesth Pain Med* 1998;23:584-588.
  151. Neal JM, Hebl JR, Gerancher JC, Hogan QH. Brachial plexus anesthesia: Essentials of our current understanding. *Reg Anesth Pain Med* 2002;27:402-428.
  152. Fanelli G, Casati A, Beccaria P, Aldegheri G, Berti M, Tarantino F, Torri G. A double-blind comparison of ropivacaine, bupivacaine, and mepivacaine during sciatic and femoral nerve blockade. *Anesth Analg* 1998;87:597-600.
  153. Connolly C, Coventry DM, Wildsmith JA. Double-blind comparison of ropivacaine 7.5 mg ml<sup>-1</sup> with bupivacaine 5 mg ml<sup>-1</sup> for sciatic nerve block. *Br J Anaesth* 2001;86:674-677.
  154. Greengrass RA, Klein SM, D'Ercole FJ, Gleason DG, Shimer CL, Steele SM. Lumbar plexus and sciatic nerve block for knee arthroplasty: Comparison of ropivacaine and bupivacaine. *Can J Anaesth* 1998;45:1094-1096.
  155. Casati A, Borghi B, Fanelli G, Cerchierini E, Santorsola R, Sassoli V, Grispigni C, Tori G. A double-blinded, randomized comparison of either 0.5% levobupivacaine or 0.5% ropivacaine for sciatic nerve block. *Anesth Analg* 2002;94:987-990.
  156. Neal JM. Effects of epinephrine in local anesthetics on the central and peripheral nervous systems: Neurotoxicity and neural blood flow. *Reg Anesth Pain Med* 2003;28:124-134.
  157. Weber A, Fournier R, Van Gessel E, Riand N, Gamulin Z. Epinephrine does not prolong the analgesia of 20 mL ropivacaine 0.5% or 0.2% in a femoral three-in-one block. *Anesth Analg* 2001;93:1327-1331.
  158. Auroy Y, Narchi P, Messiah A, Litt L, Rouvier B, Samii K. Serious complications related to regional anesthesia: Results of a prospective survey in France. *Anesthesiology* 1997;87:479-486.
  159. Candido KD, Winnie AP, Covino BG, Raza SM, Vasireddy AR, Masters RW. Addition of bicarbonate to plain bupivacaine does not significantly alter the onset or duration of plexus anesthesia. *Reg Anesth* 1995;20:133-138.
  160. Gentili M, Bernard JM, Bonnet F. Adding clonidine to lidocaine for intravenous regional anesthesia prevents tourniquet pain. *Anesth Analg* 1999;88:1327-1330.
  161. Casati A, Magistris L, Fanelli G, Beccaria P, Cappelleri G, Aldegheri G, Torri G. Small-dose clonidine prolongs postoperative analgesia after sciatic-femoral nerve block with 0.75% ropivacaine for foot surgery. *Anesth Analg* 2000;91:388-392.
  162. Reinhart DJ, Stagg KS, Walker KG, Wang WP, Parker CM, Jackson HH, Walker EB. Postoperative analgesia after peripheral nerve block for podiatric surgery: Clinical efficacy and chemical stability of lidocaine alone versus lidocaine plus ketorolac. *Reg Anesth Pain Med* 2000;25:506-513.
  163. Ilfeld BM, Morey TE, Enneking FK. Continuous infraclavicular perineural infusion with clonidine and ropivacaine compared with ropivacaine alone: A randomized, double-blinded, controlled study. *Anesth Analg* 2003;97:706-712.
  164. Reinhart DJ, Wang W, Stagg KS, Walker KG, Bailey PL, Walker EB, Zaugg SE. Postoperative analgesia after peripheral nerve block for podiatric surgery: Clinical efficacy and chemical stability of lidocaine alone versus lidocaine plus ketorolac. *Reg Anesth Pain Med* 2000;25:506-513.
  165. Auroy Y, Benhamou D, Bargues L, Ecoffey C, Falissard B, Mercier FJ, Bouaziz H, Samii K, Mercier F. Major complications of regional anesthesia in France: The SOS regional anesthesia hotline service. *Anesthesiology* 2002;97:1274-1280.
  166. Pham-Dang C, Beaumont S, Floch H, Bodin J, Winer A, Pinaud M. [Acute toxic accident following lumbar plexus block with bupivacaine]. *Ann Fr Anesth Reanim* 2000;19:356-359.
  167. Breslin DS, Martin G, Macleod DB, D'Ercole F, Grant SA. Central nervous system toxicity following the administration of levobupivacaine for lumbar plexus block: A report of two cases. *Reg Anesth Pain Med* 2003;28:144-147.
  168. Mullanu C, Gaillat F, Scemama F, Thibault S, Lavand'homme P, Auffray JP. Acute toxicity of local anesthetic ropivacaine and mepivacaine during a combined lumbar plexus and sciatic block for hip surgery. *Acta Anaesthesiol Belg* 2002;53:221-223.
  169. Petitjeans F, Mion G, Puidupin M, Tourtier JP, Hutson C, Saissy JM. Tachycardia and convulsions induced by accidental intravascular ropivacaine injection during sciatic block. *Acta Anaesthesiol Scand* 2002;46:616-617.
  170. Odoom JA, Zuurmond WW, Sih IL, Bovill J, Osterlof G, Oosting HV. Plasma bupivacaine concentrations following psoas compartment block. *Anaesthesia* 1986;41:155-158.

171. Elmas C, Atanasoff PG. Combined inguinal paravascular (3-in-1) and sciatic nerve blocks for lower limb surgery. *Reg Anesth* 1993;18:88-92.
172. Misra U, Pridie AK, McClymont C, Bower S. Plasma concentrations of bupivacaine following combined sciatic and femoral 3 in 1 nerve blocks in open knee surgery. *Br J Anaesth* 1991;66:310-313.
173. Simon MA, Gielen MJ, Lagerwerf AJ, Vree TB. Plasma concentrations after high doses of mepivacaine with epinephrine in the combined psoas compartment/sciatic nerve block. *Reg Anesth* 1990;15:256-260.
174. Scott DB. Evaluation of the toxicity of local anesthetic agents in man. *Br J Anaesth* 1975;47:56-61.
175. Selander D, Sjostrand J. Longitudinal spread of intraneurally injected local anesthetics. An experimental study of the initial distribution following intraneural injections. *Acta Anaesthesiol Scand* 1978;22:622-634.
176. Singelyn FJ, Contreras V, Gouverneur JM. Epidural anesthesia complicating continuous 3-in-1 lumbar plexus blockade. *Anesthesiology* 1995;83:217-219.
177. Gentili M, Aveline C, Bonnet F. Total spinal anesthesia complicating posterior lumbar plexus block. *Ann Fr Anesth Reanim* 1998;17:740-742.
178. Cuvillon P, Ripart J, Lalourcey L, Veyrat E, L'Hemite J, Boisson C, Thouabtia E, Eledjam JJ. The continuous femoral nerve block catheter for postoperative analgesia: Bacteria colonization, infectious rate and adverse effects. *Anesth Analg* 2001;93:1045-1049.
179. Jöhr M. [A complication of continuous femoral nerve block.] *Reg Anaesth* 1987;10:37-38.
180. Kent KC, Moscucci M, Gallagher SG, DiMattia ST, Skillman JJ. Neuropathy after cardiac catheterization: Incidence, clinical patterns, and long-term outcome. *J Vasc Surg* 1994;19:1008-1013.
181. Klein SM, D'Ercole F, Greengrass RA, Warner DS. Enoxaparin associated with psoas hematoma and lumbar plexopathy after lumbar plexus block. *Anesthesiology* 1997;87:1576-1579.
182. Weller RS, Gerancher JC, Crews JC, Wade KL. Extensive retroperitoneal hematoma without neurologic deficit in two patients who underwent lumbar plexus block and were later anticoagulated. *Anesthesiology* 2003;98:581-585.
183. Hadžić A, Volka J. *Peripheral Nerve Blocks: Principles and Practice*. New York: McGraw Hill; 2003:218-233.
184. Kent KC, Moscucci M, Mansour KA, DiMattia S, Gallagher S, Kuntz R, Skillman JJ. Retroperitoneal hematoma after cardiac catheterization: Prevalence, risk factors, and optimal management. *J Vasc Surg* 1994;20:905-910.
185. Adam F, Jaziri S, Chauvin M. Psoas abscess complicating femoral nerve block catheter. *Anesthesiology* 2003;99:230-231.
186. Bernstein IT, Hansen BJ. Iatrogenic psoas abscess. Case report. *Scand J Urol Nephrol* 1991;25:85-86.
187. Hadžić A, Vloka JD, Kuroda MM, Koorn R, Birnbach DJ. The practice of peripheral nerve blocks in the United States. A national survey. *Reg Anesth Pain Med* 1998;23:241-246.
188. Selander D. Nerve toxicity of local anesthetics. In: Lofstrom JB, Sjostrand U, eds. *Local Anesthesia and Regional Blockade*. Amsterdam: Elsevier Science; 1988:77.
189. Selander D, Dhuner KG, Lundborg G. Peripheral nerve injury due to injection needles used for regional anesthesia. *Acta Anaesthesiol Scand* 1977;21:182-189.
190. Rice ASC, McMahon SB. Peripheral nerve injury caused by injection needles used in regional anesthesia: Influence of bevel configuration, studied in a rat model. *Br J Anaesth* 1992;9:433-438.
191. Lim EK, Pereira R. Brachial plexus injury following brachial plexus block. *Anesthesia* 1984;39:691-694.
192. Bashein G, Robertson TH, Kennedy WF. Persistent phrenic nerve paresis following interscalene brachial plexus block. *Anesthesiology* 1985;63:102-104.
193. Gillespie JH, Menk EJ, Middaugh RE. Reflex sympathetic dystrophy: A complication of interscalene block. *Anesth Analg* 1987;66:1316-1317.
194. Fremling MA, Mackinnon SE. Injection injury to the median nerve. *Ann Plast Surg* 1996;37:561-567.
195. Selander D, Mansson GL, Karlsson L, Svanvik J. Adrenergic vasoconstriction in peripheral nerves of the rabbit. *Anesthesiology* 1985;62:6-10.
196. Hadžić A, Dilberovic F, Shah S, Mornjakovic Z, Divanovic Kucuk-Alija, Zulic I, Selak I, Kulenovic A. Combination of intraneural injection and high injection pressure leads to severe fascicular injury and neurologic deficits in dogs. *Reg Anesth Pain Med* 2004;29:417-423.
197. Selander D. Peripheral nerve injury after regional anesthesia. In: Finucane BT, ed. *Complications of Regional Anesthesia*. Philadelphia: Churchill Livingstone; 1999:105-115.
198. Cheney FW, Domino KB, Caplan RA, Posner KL. Nerve injury associated with anesthesia: A closed claims analysis. *Anesthesiology* 1999;90:1062-1069.
199. Bradshaw E, McHale S. Bupivacaine and femoral nerve block. *Anaesthesia* 1989;44:174.
200. Frerk CM. Palsy after femoral nerve block. *Anaesthesia* 1988;43:167-168.
201. McNichol LR. Palsy after femoral nerve block (letter). *Anaesthesia* 1988;43:509.
202. Warner MA, Warner DO, Harper CM, Schroeder DR, Maxson PM. Lower extremity neuropathies associated with lithotomy positions. *Anesthesiology* 2000;93:938-942.
203. Gruson KI, Moed BR. Injury of the femoral nerve associated with acetabular fracture. *J Bone Joint Surg [Am]* 2003;85A:428-431.
204. Slater N, Singh R, Senasinghe N, Gore R, Goroszeniuk T, James D. Pressure monitoring of the femoral nerve during total hip replacement: An explanation for iatrogenic palsy. *J R Coll Surg Edinb* 2000;45:231-233.
205. Gombar KK, Gombar S, Singh B, Sangwan SS, Siwach RC. Femoral neuropathy: A complication of the lithotomy position. *Reg Anesth* 1992;17:306-308.
206. Dillavou ED, Anderson LR, Bernert RA, Mularski RA, Hunter GC, Fiser SM, Rappaport WD. Lower extremity iatrogenic nerve injury due to compres-

- sion during intraabdominal surgery. *Am J Surg* 1997;173:504-508.
207. Nercessian OA, Macaulay W, Stinchfield FE. Peripheral neuropathies following total hip arthroplasty. *J Arthroplasty* 1994;9:645-651.
  208. Barber FA, Click J, Britt BT. Complications of ankle arthroscopy. *Foot Ankle* 1990;10:263-266.
  209. Ferkel RD, Heath DD, Guhl JF. Neurological complications of ankle arthroscopy. *Arthroscopy* 1996;12:200-208.
  210. Lamy C, Stienstra JJ. Complications in ankle arthroscopy. *Clin Podiatr Med Surg* 1994;11:523-539.
  211. Middleton RW, Varian JP. Tourniquet paralysis. *Aust N Z J Surg* 1974;44:124-127.
  212. Dawson DM, Hallet M, Wilbourn AJ (eds). *Entrapment Neuropathies*. 3rd ed. Philadelphia: Lippincott-Raven; 1999:319-322.
  213. Saunders KC, Louis DL, Weingarden SI, Watkibus GW. Effect of tourniquet time on postoperative quadriceps function. *Clin Orthop* 1979;143:194-199.
  214. Sharrock NE, Savarese JJ. Anesthesia for orthopedic surgery. In: Miller RD, Cucchiara RF, Miller ED, Reves JG, Roizen MF, Savarese JJ, eds. *Anesthesia*. 5th ed. Philadelphia: Churchill Livingstone; 2000:2118-2139.
  215. Love BR. The tourniquet. *Aust N Z J Surg* 1978;48:66-70.
  216. Jankowski CJ, Keegan MT, Bolton CF, Harrison BA. Neuropathy following axillary brachial plexus blocks: Is it the tourniquet? *Anesthesiology* 2003;99:1230-1232.
  217. Finsen V, Kasset AM. Tourniquets in forefoot surgery: Less pain when placed at the ankle. *J Bone Joint Surg [Br]* 1997;79:99-101.
  218. Crosby ET, Reid DR, DiPrimio G, Grahovac S. Lumbosacral plexopathy from iliopsoas haematoma after combined general-epidural anaesthesia for abdominal aneurysmectomy. *Can J Anaesth* 1998;45:46-51.
  219. Ho KJ, Gawley SD, Young MR. Psoas haematoma and femoral neuropathy associated with enoxaparin therapy. *Int J Clin Pract* 2003;57:553-554.
  220. Neal JM. Assessment of lower extremity nerve block: Reprise of the four P's acronym. *Reg Anesth Pain Med* 2002;27:618-620.
  221. Horlocker TT, Wedel DJ, Benzon H, Brown DL, Enneking FK, Heit JA, Mulroy MF, Rosenquist RW, Rowlingson J, Tryba M, Yuan CS. Regional anesthesia in the anticoagulated patient: Defining the risks. *Reg Anesth Pain Med* 2004;29(2 suppl):1-12.
  222. Klein SM, Nielsen KC, Greengrass RA, Warner DS, Martin A, Steele SM. Ambulatory discharge after long-acting peripheral nerve blockade: 2382 blocks with ropivacaine. *Anesth Analg* 2002;94:65-70.