

## REGIONAL ANAESTHESIA

# Determination of spread of injectate after ultrasound-guided transversus abdominis plane block: a cadaveric study

T. M. N. Tran<sup>1</sup>, J. J. Ivanusic<sup>2</sup>, P. Hebbard<sup>1</sup> and M. J. Barrington<sup>1\*</sup>

<sup>1</sup>Department of Anaesthesia, St Vincent's Hospital, Melbourne, PO Box 2900, Fitzroy, VIC 3065, Australia.

<sup>2</sup>Department of Anatomy and Cell Biology, Faculty of Medicine, Dentistry and Health Sciences, University of Melbourne, Melbourne, Australia

\*Corresponding author. E-mail: michael.barrington@svhm.org.au

**Background.** The transversus abdominis plane (TAP) block is a new regional anaesthesia technique that provides analgesia after abdominal surgery. It involves injection of local anaesthetic into the plane between the transversus abdominis and the internal oblique muscles. The TAP block can be performed using a landmark technique through the lumbar triangle or with ultrasound guidance. The goal of this anatomical study with dye injection into the TAP and subsequent cadaver dissections was to establish the likely spread of local anaesthesia *in vivo* and the segmental nerve involvement resulting from ultrasound-guided TAP block.

**Methods.** An ultrasound-guided injection of aniline dye into the TAP was performed for each hemi-abdominal wall of 10 unembalmed human cadavers and this was followed by dissection to determine the extent of dye spread and nerve involvement in the dye injection.

**Results.** After excluding one pilot specimen and one with advanced tissue decomposition, 16 hemi-abdominal walls were successfully injected and dissected. The lower thoracic nerves (T10–T12) and first lumbar nerve (L1) were found emerging from posterior to anterior between the costal margin and the iliac crest. Segmental nerves **T10, T11, T12, and L1 were involved in the dye in 50%, 100%, 100%, and 93% of cases, respectively.**

**Conclusions.** This anatomical study shows that an ultrasound-guided TAP injection cephalad to the iliac crest is likely to involve the T10–L1 nerve roots, and implies that the technique **may be limited to use in lower abdominal surgery.**

*Br J Anaesth* 2009; **102**: 123–7

**Keywords:** anaesthetic techniques, regional

Accepted for publication: October 19, 2008

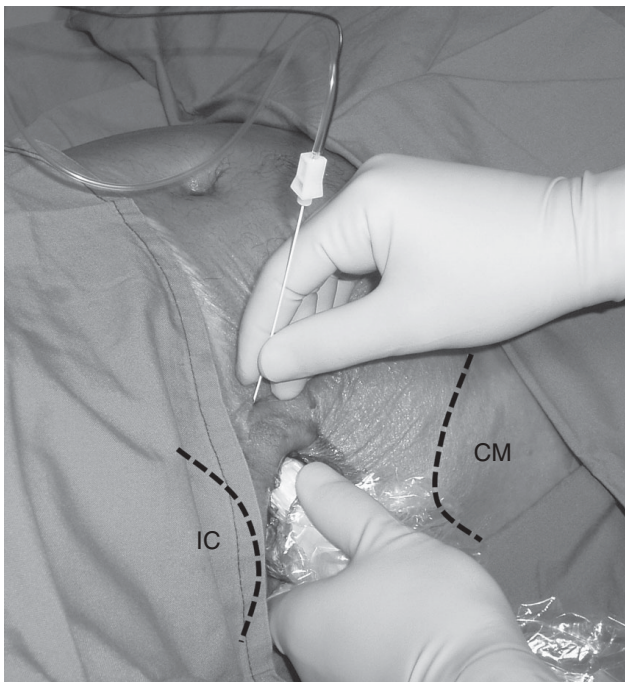
The transversus abdominis plane (TAP) block is a new regional anaesthesia technique that provides analgesia after abdominal surgery. The technique was first described as a landmark technique in 2001 by Rafi<sup>1</sup> and involves injection of local anaesthetic through the lumbar triangle into the TAP between the transversus abdominis and the internal oblique muscles. In this way, the injection targets the nerves of the anterolateral abdominal wall. The technique for accessing the TAP is evolving and an ultrasound-guided technique has been described, where the TAP can be identified in the lateral abdominal wall.<sup>2</sup> Using an ultrasound-guided technique, the needle path can be in-plane with the plane of the ultrasound which may aid accuracy and safety.

The ultrasound technique also facilitates different injection points according to the type of surgery with the three muscles of the lateral abdominal being readily identified lateral to the midline rectus abdominis muscles. Ultrasound also facilitates block of individual nerves such as selective ilioinguinal and iliohypogastric nerve block described in a cadaver study.<sup>3</sup> The clinical indications for the TAP block are also evolving and the landmark technique via the triangle of Petit has been used for postoperative analgesia after bowel, prostate, obstetric, and gynaecological surgery.<sup>4–7</sup> To date, the TAP block has not been compared with epidural analgesia, the current gold standard for postoperative analgesia.

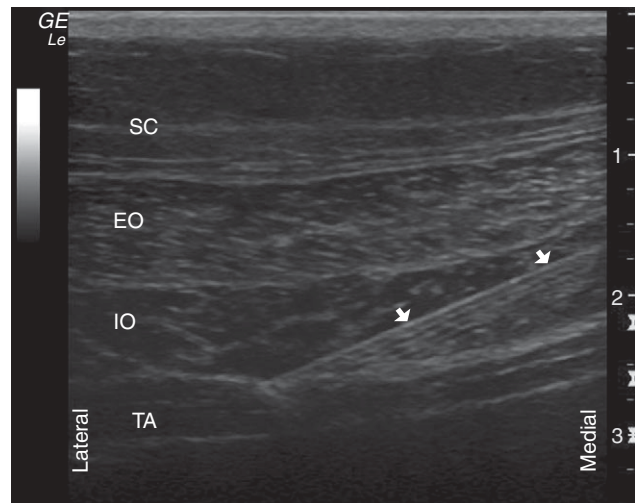
The goal of this anatomical study with dye injection into the TAP and subsequent cadaver dissections was to establish the likely spread of local anaesthesia *in vivo* and the segmental nerve involvement resulting from ultrasound-guided TAP block.

## Methods

After approval of the Human Research Ethics Committee (Project-Within-Program Application) of the University of Melbourne, 10 frozen, unembalmed human cadavers were obtained from the Department of Anatomy and Cell Biology. An ultrasound-guided injection of dye into the TAP was performed for each hemi-abdominal wall and was followed by dissection to determine the extent of dye spread and nerve involvement in the dye injection. All specimens were defrosted before the injections and dissections. A Logiq-e (GE Healthcare, Chalfont St Giles, Bucks, UK) ultrasound machine with a 12L-RS linear probe (7–13 MHz) covered with a protective plastic sheath was used for all procedures. The ultrasound probe was positioned on the lateral abdominal wall cephalad to the iliac crest and caudal to the costal margin (Fig. 1) and the initial image optimized by sliding anteriorly–posteriorly, tilting, or both in a cephalad-caudal direction until the three lateral abdominal wall muscles (lateral to rectus abdominis) and TAP were clearly imaged. Further image optimization was achieved by changing the depth, gain, and frequency, and reducing the ambient light. A 150 mm, 20 gauge needle (B.

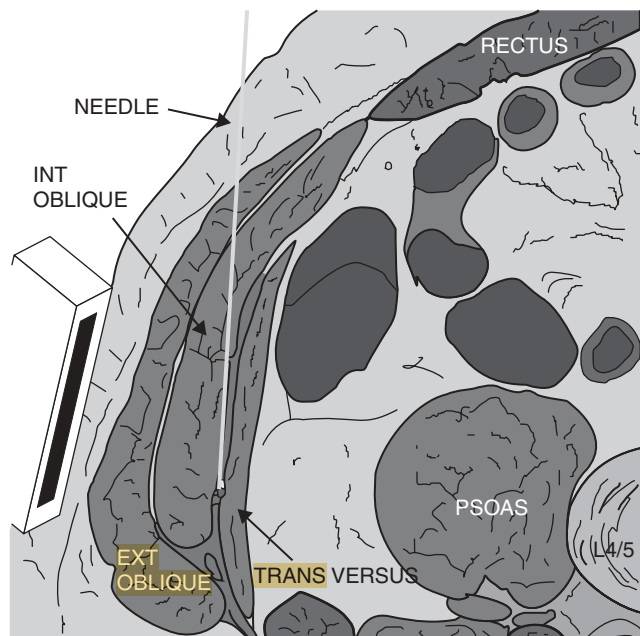


**Fig 1** Probe placement on the lateral abdominal wall cephalad to the iliac crest. Note that the needle was advanced anterior to posterior using an in-plane technique. IC, iliac crest; CM, costal margin.



**Fig 2** Transverse sonogram of lateral abdominal wall with in-plane image of needle. SC, subcutaneous tissue; EO, external oblique muscle; IO, internal oblique muscle; TA, transversus abdominis muscle; Arrows, needle shaft.

Braun Stimuplex, Melsungen, Germany) was then advanced from an anteromedial position in a posterior and lateral direction using an in-plane technique with the skin entry point separated from the probe to improve needle visibility in the long axis (Fig. 2, sonogram; Fig. 3, diagram). After a test dose of 1 ml dye to confirm correct needle tip placement in the TAP, 20 ml of aniline blue dye (0.25% in distilled water) was injected through the needle.

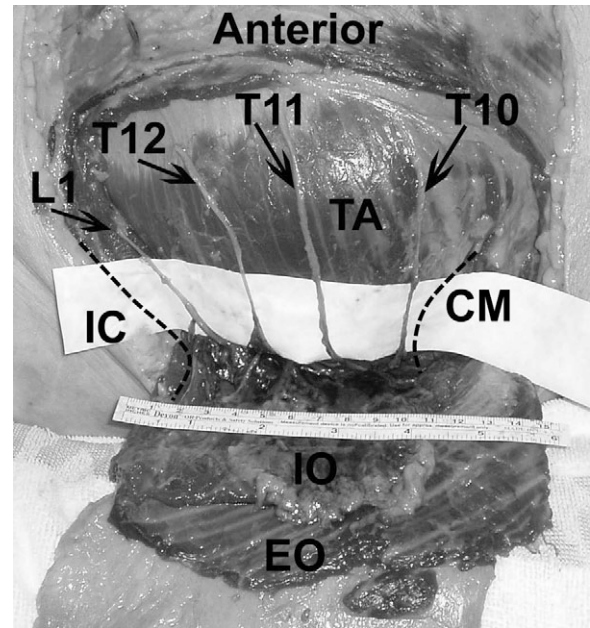


**Fig 3** Diagram shows needle trajectory in the TAP between the internal oblique and the transversus abdominis muscles. Ext Oblique, external oblique muscle; Int Oblique, internal oblique muscle; Transversus, transversus abdominis muscle. (Modified from source: Ecole Polytechnique Fédérale de Lausanne, Switzerland, Visible Human Web Server. URL: <http://visiblehuman.epfl.ch>).

After the dye injection, its extent of spread within the TAP was determined by dissection of the hemi-abdominal wall. A cephalad-caudal incision was made on the midclavicular line, extending from the costal margin to the iliac crest. A flap consisting of skin and superficial fascia was raised. This was done by transverse incisions at the levels of the costal margin and the iliac crest, extending from the midclavicular line to the midaxillary line. The external oblique muscle was subsequently exposed and an external oblique muscle flap was raised to expose the underlying internal oblique muscle. The internal oblique muscle flap was then carefully dissected from the transversus abdominis muscle to avoid damage to the thoracolumbar nerves in the TAP. Dye distribution was quantified using cephalad-caudal and circumferential measurements. Nerves between the costal margin and the iliac crest were carefully dissected to expose the main trunk, neglecting small communicating branches. The segmental origin of each nerve was determined by tracing posteriorly to its respective costal or sub-costal origins. The T10 segmental nerve was identified as the first nerve caudal to the costal margin (rib 10) and T11, T12, and L1 were identified by counting segmental nerves in a caudal direction, to the level of the iliac crest. To confirm correct identification of these segmental nerves, we subsequently identified the L1 segmental nerve as the first nerve that could be identified cephalad to the iliac crest, and counted T12, T11, and T10 in a cephalad direction, to the costal margin. T9 was identified as emerging from the costal margin, cephalad to T10, and confirmed by dissecting it proximally into the ninth intercostal space. Nerves that were covered in dye were then recorded. Descriptive statistics are reported as mean (SD) unless otherwise stated.

## Results

Twenty hemi-abdominal walls from 10 cadavers were dissected. One cadaver (two sides) was used as a pilot to determine the injection and dissection protocol. In another cadaver, the injection was unsuccessful on one side because of muscular atrophy and decomposition and on the other side the injection was successful (spread of dye measured in the TAP), but tissue decomposition rendered nerve identification impossible. This resulted in a total of 16 sides from eight cadavers where there was successful injection of dye and documentation of both nerves involved in, and spread of dye, within the TAP. The transversus abdominis, internal oblique, and external oblique muscles in the lateral abdominal wall were visualized in all sonograms (typical example shown in Fig. 2). Dissection into the TAP confirmed successful injection in 16 hemi-abdominal walls. Aniline blue dye was located within the TAP, with small needle puncture traces on the external and internal oblique muscles. Dye injectate was found localized in the TAP between the costal margin and the iliac crest in the region of the midaxillary line. Generally, dye spread was within a



**Fig 4** Nerves roots identified and involved in dye between the iliac crest and the costal margin. IC, iliac crest; CM, costal margin; TA, transversus abdominis muscle; IO, internal oblique muscle; EO, external oblique muscle; T10, 10th thoracic nerve root; T11, 11th thoracic nerve root; T12, 12th thoracic nerve root; L1, first lumbar nerve root.

narrow transverse band on the trunk and was limited by the lateral border of the rectus sheath, iliac crest, and costal margin; although in some cases, the dye was not observed immediately adjacent to the costal margin. Average dye distribution was 6.12 (2.25) cm in the cephalad-caudal dimension and 7.38 (1.47) cm circumferentially. The lower thoracic nerves (T10–T12) and first lumbar nerve (L1) were found emerging from posterior to anterior between the costal margin and the iliac crest (Fig. 4). We also identified the main branches of L1 (the iliohypogastric and in some cases ilioinguinal nerves). The number of hemi-abdomina in which each segmental nerve was identified and the nerves which were involved with dye injectate are detailed in Table 1. In almost all cases, T11 through to L1 were surrounded by injectate. T10 was surrounded by injectate in half of our sample. In the cases in which T10 was not involved in the injectate distribution, we noted that the injectate had not spread all the way to the costal margin. T9 was never surrounded by injectate.

**Table 1** The number of nerves identified by dissection and involved by dye (n) and the relative frequency (%). T10–T12, thoracic nerve roots; L1, lumbar nerve root

	Number of nerves identified by dissection	Number of nerves involved by dye (n)	Frequency of nerves involved by dye (%)
T9	9	0	0
T10	16	8	50
T11	16	16	100
T12	15	15	100
L1	14	13	93



## Discussion

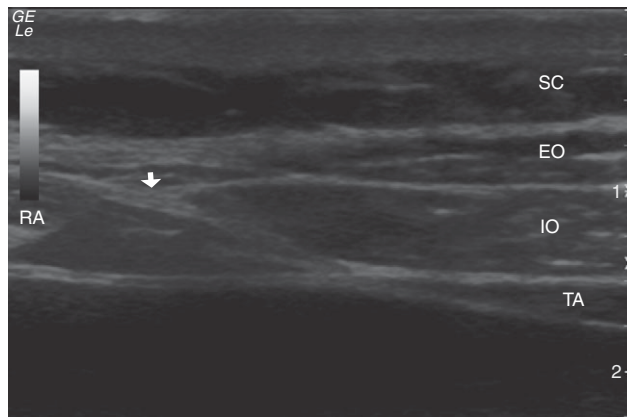
This anatomical study is the first of its type whereby the spread of ultrasound-guided injectate in the TAP between the transversus abdominis and internal oblique muscles and segmental nerve involvement has been investigated by anatomical dissection. The main finding of our study was that the injectate was reliably located within the TAP and that the spread of dye extended from the iliac crest to the lateral border of rib 10 in most cases. This resulted in dye involvement for segmental nerves T10 through to L1 (noting that T10 was only involved 50% of the time). On the basis of our findings, it is unlikely that spinal nerve roots higher than T10 will consistently be involved in an injection cephalad to the iliac crest. In addition, the T10 nerve root itself may not be involved after an injection at this site. The location of injection used in this study was chosen because it is similar to recent reports of ultrasound-guided nerve block for anaesthesia of the abdominal wall.<sup>2,3</sup> Recently, an ultrasound-guided subcostal TAP block has been described; however, the evidence supporting the use of ultrasound-guided TAP block is limited and there are no randomized or other controlled trials published from which to base clinical care.<sup>8</sup> Despite this, ultrasound-guided TAP block is a technique increasing in use, hence the relevance of this anatomical study.

Our finding of T10–L1 involvement after ultrasound-guided TAP injection of dye is consistent with previous correspondence by both Shibata and colleagues<sup>7</sup> and Hebbard.<sup>8</sup> Shibata and colleagues assessed the sensory block by pinprick in 26 patients after ultrasound-guided TAP block for laparoscopic gynaecological surgery. They reported a block over the T10–L1 dermatomes and suggested lower abdominal surgery as an indication for TAP block. Hebbard described the upper extent of the sensory block to ice after 21 ultrasound-guided TAP blocks in 12 patients (cephalad to the iliac crest) to be 52% of the distance from pubic symphysis to xiphoid process (approximately to the umbilicus). In contrast, a study by McDonnell and colleagues<sup>9</sup> reported a sensory block from T7 to L1 in three volunteers when a landmark technique was used to access the TAP through the lumbar triangle. In this current anatomical study, this would have been equivalent to a much wider spread of dye. We were unable to get the dye to spread cephalad to the costal margin using our injection technique. It is possible that there is a barrier to the spread of dye post-mortem and this may be related to contraction of fascial planes. Indeed, in the study of McDonnell and colleagues,<sup>9</sup> the authors only reported dye involvement as high up as the costal margin after three cadaveric injections of methylene blue. Assuming that the spread of dye originating from the lumbar triangle was predominantly along the lateral abdominal wall, then this would be unlikely to involve any segmental nerves cephalad to the T10 root. Even if the injectate spread to the anterior axillary line, the most

cephalad segmental nerve that would be involved would be T9. In the MRI component of the same study, they demonstrated injectate successfully located in the TAP plane, but there was no reference to nerves involved to support the sensory block demonstrated in the clinical component of their study. Recently, we have published the findings of dissections of hemi-abdominal walls of cadavers and reported that there is extensive communication between adjacent segmental thoracolumbar nerves. The majority of the large nerve trunk communications are lateral to the ascending branch of the deep circumflex iliac artery in the TAP. This would partly explain a more extensive sensory block than that explained by the spread of injectate alone, but spread more cephalad to segmental nerve T9 would not be possible because only segmental nerves T9–L1 are located in the TAP at the anterior axillary line.<sup>10</sup> These dissections also documented the existence of a fascial layer between the internal oblique and the transversus abdominis muscles with the nerves located deep to the fascial plane. Clearly, the presence of this fascia may influence the spread of injectate. As dissection into the TAP was ~40 min after injection, there is a possibility that the maximal extent of injectate spread was not achieved. Nevertheless, the current findings are consistent with the clinical findings reported by Shibata and colleagues<sup>7</sup> and Hebbard.<sup>8</sup> A further reason influencing the spread of injectate may be the technique used to locate the TAP. In this current study, an ultrasound technique was used in contrast to the landmark technique previously described.<sup>1</sup> The specific approach used for a TAP block may influence its effectiveness.

The clinical efficacy of Rafi's<sup>1</sup> landmark approach is well demonstrated in the series of studies by McDonnell and colleagues.<sup>4–6</sup> In a randomized controlled trial,<sup>4</sup> the TAP block was used successfully for analgesia after large bowel resection via a midline incision with patient-controlled morphine analgesia as the standard of care. In that study, neither the sensory block nor the dermatomes involved by the surgical incisions were reported. Nonetheless, it highlights the utility of TAP blocks in abdominal surgery, and is consistent with our finding that TAP infiltration involves segmental nerves (T10–L1) that innervate the lower anterior abdominal wall.

In most cases, we were able to follow L1 through the TAP and identify the iliohypogastric branch of L1, and a branch that continued as the ilioinguinal nerve. However, we noted that in one of the hemi-abdominal dissections, the L1 nerve did not penetrate transversus abdominis and enter the TAP until it reached a position close to the anterior superior iliac spine. As a result, this nerve was not surrounded by dye injected into the TAP with our posterolateral approach (Table 1). The path of the ilioinguinal nerve is known to be subject to variability. Jamieson and colleagues<sup>11</sup> has described the variability in position where the ilioinguinal nerve penetrates through the transversus abdominis muscle to run in the plane between the



**Fig 5** Transverse sonogram of the muscles and fascias at the linea semilunaris (arrow). RA, rectus abdominis muscle; SC, subcutaneous tissue; EO, external oblique muscle; IO, internal oblique muscle; TA, transversus abdominis muscle.

transversus abdominis and the internal oblique muscles. In 150 of 244 dissections, the nerve entered the TAP from 20% to 60% of the distance along the iliac crest from anterior to posterior superior iliac spines. In 24 of the 244 specimens, the ilioinguinal nerve joined the TAP only in the anterior 20% of the iliac crest. In addition, we have observed in our clinical practice that sensory block of the L1 dermatome is on occasions not completed after our technique of ultrasound-guided TAP block cephalad to the iliac crest. It is likely that penetration of the transversus abdominis muscle by L1 closer to the anterior superior iliac spine accounts for this clinical observation.

In an anatomical study by Eichenberger and colleagues,<sup>3</sup> the individual nerves (iliohypogastric and ilioinguinal) were identified close to the iliac crest using ultrasound and selectively targeted by a small volume of dye. In contrast, the TAP block utilizes a larger volume of injectate with the intention to block a larger number of segmental nerves. We would agree with Eichenberger that the three muscles of the lateral abdominal wall are readily identified with ultrasound. Figure 5 demonstrates a transverse sonogram including both the rectus abdominis and the three lateral muscles with the linea semilunaris in-between. The linea semilunaris consists of the aponeuroses of both the internal and external oblique muscles and the transversus abdominis muscle and it extends from the cartilage of rib 9 to the pubic tubercle. We have found that this sonogram is useful for locating the TAP, as in many patients the rectus abdominis muscle is displaced away from the midline. The knowledge that the segmental

nerves mostly lie in the TAP is the basis of the TAP block regardless of the exact technique and our dissections confirm the location of nerves T10–L1 in the TAP posterolaterally.

In conclusion, this anatomical study shows that an ultrasound-guided TAP injection cephalad to the iliac crest is likely to involve the T10–L1 nerve roots, and implies that the technique may be limited to use in lower abdominal surgery.

## Acknowledgement

The authors are grateful to Susie Kerby, Department of Anatomy and Cell Biology, University of Melbourne, for her technical assistance.

## References

- 1 Rafi AN. Abdominal field block: a new approach via the lumbar triangle. *Anaesthesia* 2001; **56**: 1024–6
- 2 Hebbard P, Fujiwara Y, Shibata Y, Royse C. Ultrasound-guided transversus abdominis plane (TAP) block. *Anaesth Intensive Care* 2007; **35**: 616–7
- 3 Eichenberger U, Greher M, Kirchmair L, Curatolo M, Moriggl B. Ultrasound-guided blocks of the ilioinguinal and iliohypogastric nerve: accuracy of a selective new technique confirmed by anatomical dissection. *Br J Anaesth* 2006; **97**: 238–43
- 4 McDonnell JG, O'Donnell B, Curley G, Heffernan A, Power C, Laffey JG. The analgesic efficacy of transversus abdominis plane block after abdominal surgery: a prospective randomized controlled trial. *Anesth Analg* 2007; **104**: 193–7
- 5 McDonnell JG, Curley G, Carney J, et al. The analgesic efficacy of transversus abdominis plane block after cesarean delivery: a randomized controlled trial. *Anesth Analg* 2008; **106**: 186–91
- 6 O'Donnell BD, McDonnell JG, McShane AJ. The transversus abdominis plane (TAP) block in open retropubic prostatectomy. *Reg Anesth Pain Med* 2006; **31**: 91
- 7 Shibata Y, Sato Y, Fujiwara Y, Komatsu T. Transversus abdominis plane block. *Anesth Analg* 2007; **105**: 883, author reply
- 8 Hebbard P. Subcostal transversus abdominis plane block under ultrasound guidance. *Anesth Analg* 2008; **106**: 674–5, author reply 5
- 9 McDonnell JG, O'Donnell BD, Farrell T, et al. Transversus abdominis plane block: a cadaveric and radiological evaluation. *Reg Anesth Pain Med* 2007; **32**: 399–404
- 10 Rozen WM, Tran TM, Ashton MW, Barrington MJ, Ivanusic JJ, Taylor GI. Refining the course of the thoracolumbar nerves: a new understanding of the innervation of the anterior abdominal wall. *Clin Anat* 2008; **21**: 325–33
- 11 Jamieson RW, Swigart LL, Anson BJ. Points of parietal perforation of the ilioinguinal and iliohypogastric nerves in relation to optimal sites for local anaesthesia. *Q Bull Northwest Univ Med Sch* 1952; **26**: 22–6