

Total Shoulder Arthroplasty as an Outpatient Procedure Using Ambulatory Perineural Local Anesthetic Infusion: A Pilot Feasibility Study

Brian M. Ilfeld, MD, MS*, Thomas W. Wright, MD†, F. Kayser Enneking, MD*†, Jennie A. Mace, MD*, Jonathan J. Shuster, PhD‡, Eugene H. Spadoni, PT§, Terese L. Chmielewski, PhD, PT§, and Krista Vandendorpe, PhD, PT§

Departments of *Anesthesiology, †Orthopaedics and Rehabilitation, ‡Statistics, and §Physical Therapy, University of Florida, Gainesville, Florida

We investigated the feasibility of converting total shoulder arthroplasty (TSA) into an outpatient procedure using ambulatory interscalene perineural ropivacaine infusion. Of the patients of the first phase ($n = 8$) who were required to remain hospitalized for at least 1 postoperative night, 5 met discharge criteria in the recovery room. Of the subsequent patients of the second phase ($n = 6$), all met discharge criteria in the recovery room after surgery, and 5 were discharged directly home. For all patients, postoperative pain was well controlled, oral opioid requirements

and sleep disturbances were minimal, range-of-motion consistently reached or exceeded the surgeon's expectations, and patient satisfaction was high. These results suggest that TSA may be performed on an outpatient basis using perineural local anesthetic infusion. Additional research is required to define the appropriate subset of patients and assess the incidence of complications associated with this practice before its mainstream use.

(Anesth Analg 2005;101:1319–22)

Total shoulder arthroplasty (TSA) results in severe postoperative pain that traditionally requires hospital admission to provide potent analgesia with IV opioids for both baseline pain and to enable effective rehabilitation (1–4). Perineural infusion or a continuous nerve block does not always require hospitalization (5), and provides site-specific analgesia

with minor, if any, side effects (6,7). Portable infusion pumps have been used to improve analgesia for outpatients after mild and moderately painful *ambulatory* shoulder surgery (7–11). This pilot study was designed to evaluate the feasibility of converting TSA into an ambulatory procedure using perineural interscalene local anesthetic infusion and portable infusion pumps.

Manufacturers donated the portable infusion pumps (Smiths Medical, St. Paul, MN) and catheters (Arrow International, Reading, PA) used for this investigation. Funding for this project provided by the University of Florida Department of Anesthesiology, Arrow International, and Smiths Medical. These two companies had no input into any aspect of study design; data collection, analysis, and interpretation; or manuscript preparation. Its contents are solely the responsibility of the authors and do not necessarily represent the official views of these entities.

Supported in part by General Clinical Research Center Grant M01-RR00082 and National Institutes of Medicine, National Institute of General Medical Sciences (Grant K23-GM077026).

Some of the results of this investigation were presented at the Annual Meeting of the American Society of Regional Anesthesia and Pain Medicine, Orlando, FL, March 12, 2004; and Toronto, Canada, April 22, 2005.

Accepted for publication April 25, 2005.

Address correspondence and reprint requests to Brian M. Ilfeld, MD, Department of Anesthesiology, P.O. Box 100254, 1600 SW Archer Rd., Gainesville, FL 32610-0254. Address e-mail to bilfeld@ufl.edu.

DOI: 10.1213/01.ANE.0000180199.52383.CE

Methods

The investigation was divided into two phases: the *Hospitalized* phase allowed for patient discharge as early as the day after surgery, postoperative day (POD) 1, whereas the *Ambulatory* phase allowed for discharge home directly from the postanesthesia care unit (PACU). The *Hospitalized* phase was prospectively designated to conclude after 5 patients had met all discharge criteria (Table 1) both in the PACU and POD 1, and subsequently completed their infusion successfully at home. Successful infusion was defined for both phases as a patient 1) receiving acceptable analgesia as measured using a numeric rating pain scale (NRS <4; scale of 0–10, 0 = no pain, 10 = worst imaginable pain) throughout POD 7 (12); 2) avoiding

Table 1. Discharge Criteria

Criteria	Details
Analgesia	Numeric rating pain score consistently ≤ 4
Opioids	Patient required < 5 mg of IV morphine (< 4 mg in PACU)
Mobility	Able to ambulate without assistance or light-headedness
Orals	Tolerating oral liquids without nausea requiring treatment
Oxygenation	Spo ₂ $> 92\%$ on room air at a respiratory rate < 20 /min
Vital signs	Temperature $< 38.5^{\circ}\text{C}$ Heart rate $<$ preoperative baseline + 10 (bpm) Systolic blood pressure $<$ preoperative baseline + 20 (mm Hg)
Nausea	No nausea, or minimal nausea not requiring treatment
Estimated blood loss ^a	Estimated blood loss $<$ weight (kg) \times 10 mL
Medical issues	No medical issues requiring admission

PACU = postanesthesia care unit.

^a Estimated blood loss was only a discharge criteria on postoperative day (POD) 0.

hospital readmission; and 3) achieving at least 50% of the surgeon's shoulder elevation and external rotation goals (defined below) in the PACU and on POD 3. The *Ambulatory* phase was designated to conclude after successful completion of 5, of a maximum of 10, patients.

Hospitalized Phase

After IRB approval, we prospectively enrolled patients scheduled for unilateral TSA. Subjects were required to 1) live within 2 h of the hospital; and 2) have a caretaker who would remain with them during the local anesthetic infusion and could return them to the hospital if necessary. Exclusion criteria included any contraindication to interscalene nerve block, any known heart or lung disease, baseline Spo₂ $< 96\%$, a history of opioid dependence or current chronic analgesic therapy, allergy to study medications, known hepatic or renal insufficiency, peripheral neuropathy, and morbid obesity (body mass index > 40 kg/m²).

After written, informed consent, interscalene catheters (StimuCath; Arrow International, Reading, PA) were placed using a technique described previously (8). Forty milliliters of ropivacaine, 0.2%, with epinephrine, 100 μg , was injected via the catheter with gentle aspiration every 3–5 mL. For the surgical procedure, patients received a standardized general anesthetic without opioids.

Postoperatively, a perineural bolus was administered for an NRS > 3 (20 mL of ropivacaine, 0.2%, with epinephrine, 50 μg), and an electronic, portable infusion pump (CADD-Legacy PCA; Smiths Medical, St. Paul, MN) with a 600-mL reservoir of ropivacaine, 0.2%, was attached to the catheter (basal rate = 7 mL/h, bolus = 3 mL, lockout = 60 min) (13). Patients received scheduled celecoxib, 100 mg twice daily, and acetaminophen, 975 mg every 6 h. Rescue opioid and route of administration were determined by pain severity: oral oxycodone 5 mg (NRS < 4), oral oxycodone 10 mg (NRS = 4–5), or IV morphine

2–4 mg (NRS > 5). The patient and caretaker were given verbal and written instructions on the use of the pump and catheter along with physician telephone and pager numbers.

In the PACU, both patients and their caretakers received instruction on rehabilitation exercises by a physical therapist. The primary indicator of functional outcome after TSA is range-of-motion (14). For the first 2–6 wk after surgery, patients undergo *passive* elevation and external rotation up to surgeon-defined maximums, or goals, to avoid damaging the rotator cuff (3,15). Prospectively determined discharge criteria (Table 1) were subsequently evaluated and patients discharged to the hospital's General Clinical Research Center (GCRC), and then home the following morning if they again met criteria for discharge.

Patients were telephoned beginning the night of surgery, and each evening thereafter through the night after catheter removal. On POD 3, patients returned to the GCRC to have their catheter site examined, local anesthetic reservoir replenished, and undergo a rehabilitation session with a physical therapist. In the evening of POD 6, patients' caretakers removed the catheters using a pair of nonsterile gloves, with a physician in telephone contact throughout.

Ambulatory Phase

One change was made to the protocol after the completion of the *Hospitalized* phase: upon arrival in the PACU, the perineural bolus (20 mL of ropivacaine, 0.2%, with epinephrine, 50 μg) was administered for an NRS > 0 instead of an NRS > 3 .

Results

Hospitalized Phase

Eight patients were enrolled in this phase and had an interscalene catheter placed successfully (Table 2).

Table 2. Population Data

	Hospitalized Phase (n = 8)	Ambulatory Phase (n = 6)
Age (yr)	62 ± 12	68 ± 8
Sex (female/male)	4/4	2/4
Height (cm)	173 ± 9	169 ± 9
Weight (kg)	88 ± 18	80 ± 19
Underlying etiology (osteoarthritis/failed previous TSA)	8/0	4/2
Surgery duration (min)	189 ± 85	174 ± 44
Estimated blood loss (mL)	305 (200–2400)	325 (100–600)

Values are reported as mean ± SD or median (minimum–maximum) for parametric and nonparametric data, respectively.
TSA = total shoulder arthroplasty.

One subject was erroneously included in the study (exclusion criteria: asthma), and was removed from the investigation. Five patients (63%) met all discharge criteria both in the PACU and on POD 1, and were discharged home on POD 1. Two patients (25%) did not meet discharge criteria in the PACU. The first because of an NRS = 7 that required 4 mg of IV morphine. This patient met discharge criteria the following morning and was discharged home on POD 1. The second patient had an estimated blood loss of 2400 mL (Table 1), and was discharged home on POD 2.

For all patients, pain was well controlled with <5 mg of IV morphine (Fig. 1, Table 3). Postoperative oral opioid requirements and sleep disturbances were minimal (Table 3). All patients reached at least 50% of the surgeon-defined range-of-motion goals (Table 3). All subjects underwent successful perineural infusion at home until their catheters were inadvertently dislodged (n = 1, POD 4) or removed (n = 6, POD 6).

Ambulatory Phase

Six patients were enrolled in this phase, all had an interscalene catheter placed successfully, and all met discharge criteria in the recovery room after surgery (Table 2). However, one patient was admitted overnight secondary to operating room delays resulting in surgery completion in the late evening. The remaining 5 patients were discharged directly from the recovery room. All 6 patients underwent successful ambulatory perineural infusion for 4–6 days. Postoperative pain was well controlled (Fig. 1), oral opioid requirements and sleep disturbances were minimal, range-of-motion consistently reached at least 50% of the surgeon-defined goals, and patient satisfaction was high (Table 3). All subjects underwent successful perineural infusion at home until their catheters were inadvertently dislodged (n = 1, POD 4) or removed (n = 5, POD 6).

There were no pump malfunctions or alarms and caretakers for patients in both groups reported no difficulty removing catheters at home.

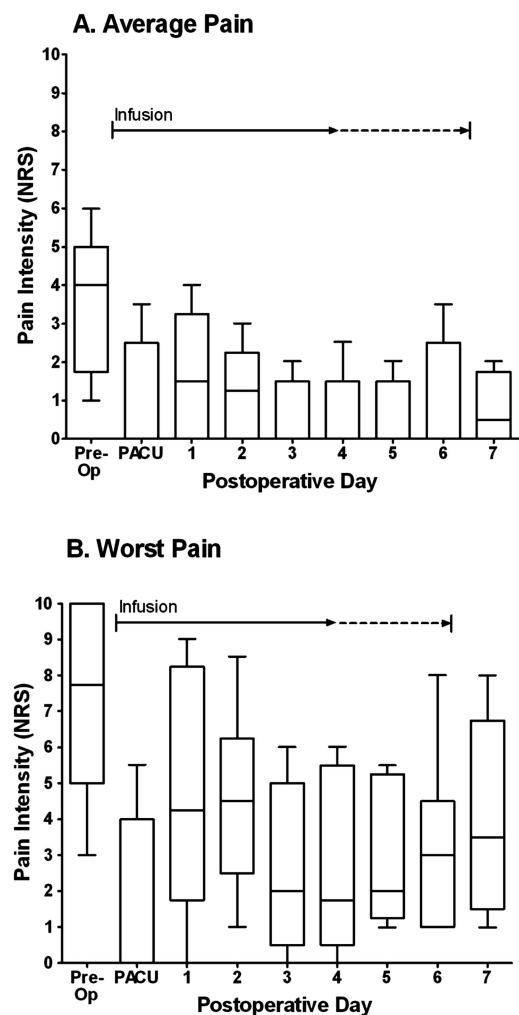


Figure 1. Pre- and postoperative *average* (A), and *worst* (B) pain for patients with an interscalene perineural ropivacaine infusion after total shoulder arthroplasty. Pain was evaluated with a numeric rating pain scale (NRS, 0–10, 0 = no pain and 10 = worst imaginable pain). Data include both phases of the study and are expressed as median (horizontal bar) with 25th–75th (box) and 10th–90th (whiskers) percentiles. For tightly clustered data (e.g., Panel A, postanesthesia care unit [PACU]), the median approximated the 10th and 25th percentile values. In these cases, the median is 0.0 and only the 75th and 90th percentiles are clearly noted.

Table 3. Opioid Requirements, Pain Scores During Physical Therapy, Sleep Disturbances, and Satisfaction Scores

	POD							
	0	1	2	3	4	5	6	7
Median oral opioid tablet consumption ^a	0	0.5	0	0	0	0	0	3.0
Percent of elevation goal achieved	100 (65-100)	80 (65-100)	—	85 (75-100)	—	—	—	—
Percent of external rotation goal achieved	100 (100-100)	100 (100-100)	—	100 (100-100)	—	—	—	—
Average NRS during physical therapy ^b	0.5 (0-3)	3 (1-4)	—	2 (0-4)	—	—	—	—
Worst NRS during physical therapy ^b	1 (0-8)	6 (3-9)	—	3 (1-4)	—	—	—	—
Patients reporting difficulty sleeping (<i>n</i>) ^c	2	1	0	0	1	0	1	—
Awakenings for each patient (median) ^c	0	0	0	0	0	0	0	—
Satisfaction ^d	—	10 (9.5-10.0)	—	—	—	—	—	10 (10-10)

Interscalene perineural ropivacaine, 0.2%, infusion provided from postoperative day (POD) 0 through the evening of PODs 4-6. All patients are included, with the exception of pain scores and shoulder range-of-motion for POD 1, for which only patients remaining hospitalized on this day are included.

— = Not applicable (data not collected).

^a Oral opioid tablets: oxycodone 5 mg.

^b NRS = numeric rating pain scale (0-10, 0 = no pain and 10 = worst imaginable pain); data presented as median (25th-75th percentiles).

^c As a result of surgical pain.

^d Satisfaction = 0-10 with 10 = very satisfied; data presented as median (25th-75th percentiles).

Discussion

For the patients of this pilot study who underwent TSA and ambulatory perineural local anesthetic infusion, postoperative pain was well controlled with baseline and breakthrough pain intensity below levels previously reported for much smaller ambulatory orthopedic procedures (16). Patients also achieved >50% of the surgeon-defined maximal elevation and external rotation without exception, and often reached 100% of this goal. This degree of comfort and shoulder mobility was achieved with minimal oral opioid requirements and sleep disturbances, leading to a very high rate of patient satisfaction.

Although this evidence demonstrates that TSA may be performed in the ambulatory environment, it does not define the appropriate subset of patients and incidence of complications associated with this practice (e.g., local anesthetic toxicity or infection). Additional research is required to define the appropriate subset of patients and determine the complication incidence associated with this practice before its mainstream use.

The authors gratefully acknowledge the invaluable assistance of the staff of both the Regional Anesthesia Block Room and General Clinical Research Center, including Doug Theriaque, MS, for figure compilation.

References

- Borgeat A, Tewes E, Biasca N, Gerber C. Patient-controlled interscalene analgesia with ropivacaine after major shoulder surgery: PCIA vs PCA. *Br J Anaesth* 1998;81:603-5.
- Borgeat A, Schappi B, Biasca N, Gerber C. Patient-controlled analgesia after major shoulder surgery: patient-controlled interscalene analgesia versus patient-controlled analgesia. *Anesthesiology* 1997;87:1343-7.
- Brems JJ. Rehabilitation following total shoulder arthroplasty. *Clin Orthop Relat Res* 1994;70-85.
- Cameron B, Galatz L, Williams GR Jr. Factors affecting the outcome of total shoulder arthroplasty. *Am J Orthop* 2001;30:613-23.
- Ilfeld BM, Enneking FK. Continuous nerve blocks at home: a review. *Anesth Analg* 2005;100:1822-33.
- Klein SM, Grant SA, Greengrass RA, et al. Interscalene brachial plexus block with a continuous catheter insertion system and a disposable infusion pump. *Anesth Analg* 2000;91:1473-8.
- Ilfeld BM, Morey TE, Wright TW, et al. Continuous interscalene brachial plexus block for postoperative pain control at home: a randomized, double-blinded, placebo-controlled study. *Anesth Analg* 2003;96:1089-95.
- Ilfeld BM, Morey TE, Wright TW, et al. Interscalene perineural ropivacaine infusion: a comparison of two dosing regimens for postoperative analgesia. *Reg Anesth Pain Med* 2004;29:9-16.
- Macaire P, Gaertner E, Capdevila X. Continuous post-operative regional analgesia at home. *Minerva Anestesiol* 2001;67:109-16.
- Capdevila X, Macaire P, Akin P, et al. Patient-controlled perineural analgesia after ambulatory orthopedic surgery: a comparison of electronic versus elastomeric pumps. *Anesth Analg* 2003;96:414-7.
- Ilfeld BM, Enneking FK. A portable mechanical pump providing over four days of patient-controlled analgesia by perineural infusion at home. *Reg Anesth Pain Med* 2002;27:100-4.
- Cepeda MS, Africano JM, Polo R, et al. What decline in pain intensity is meaningful to patients with acute pain? *Pain* 2003;105:151-7.
- Ilfeld BM, Morey TE, Enneking FK. Delivery rate accuracy of portable, bolus-capable infusion pumps used for patient-controlled continuous regional analgesia. *Reg Anesth Pain Med* 2003;28:17-23.
- Cohen NP, Levine WN, Marra G, et al. Indwelling interscalene catheter anesthesia in the surgical management of stiff shoulder: a report of 100 consecutive cases. *J Shoulder Elbow Surg* 2000;9:268-74.
- Brown DD, Friedman RJ. Postoperative rehabilitation following total shoulder arthroplasty. *Orthop Clin North Am* 1998;29:535-47.
- Rawal N, Hylander J, Nydahl PA, et al. Survey of postoperative analgesia following ambulatory surgery. *Acta Anaesthesiol Scand* 1997;41:1017-22.