

Letters to the Editor

A Personal Story Regarding Pain Control

To the Editor:

My father, Victor Herbert, MD, JD, a pioneer in research on megaloblastic anemia and world-renowned scientist, passed away November 19, 2002. He developed melanocytic lesions in his cervical spine for which he underwent an operation. Unfortunately, lesions developed in his brain. Despite chemotherapy, the lesions grew and Dad deteriorated clinically. He wished to receive palliative care at home.

Dad had generalized pain as well as local pain at the site of the cervical operation. He was treated with morphine and subsequently methadone by mouth. Lidocaine 5% patches were prescribed locally to the neck operative site. The last few weeks of his life, Dad spent most of his time in bed, but was able to sit, with help, in a wheelchair to eat and read. He was totally incontinent and had little sensation below the waist. He had minimal motor function in his legs. Despite outstanding nursing care, Dad developed a bedsore in the sacral region. The bedsore caused great pain and inhibited his ability to sit for more than a few minutes at a time.

As an anesthesiologist, I hoped that by applying the lidocaine patch over the lumbar spine, the anesthetic might provide some relief. To limit the total dosage of lidocaine, I cut the patch in half. During the day, half was applied to the neck and the other half was applied to the lumbar region on intact skin, well above the bedsore. The results were remarkable. Dad was able to sit for extended periods of time without pain. Anecdotally, he told me the patches helped significantly. There was no appreciable change in the neurologic signs or symptoms in his legs.

There may have been some local effect countering the pain sensation from below, a systemic or placebo effect, or there may have been a "spinal" effect if some of the anesthetic was able to get into the CNS. Perhaps further studies could explore this phenomenon.

In this case of a patient with a bedsore who had minimal use of the lower half of his body, applying a lidocaine patch proximal to the lesion improved the quality of life for my father without adverse effects. Should this therapy become widespread, I request the use of the lidocaine patch in this manner be called the "Victor Herbert patch" in his honor.

Robert A. Herbert, MD, JD
Los Gatos, CA

DOI: 10.1213/01.ANE.0000074688.43080.48

A New Technique for Pulmonary Arterial Catheter Insertion into Coronary Sinus Using Transesophageal Echocardiography

To the Editor:

The coronary sinus (CS) catheterization guided by transesophageal echocardiograph (TEE) was reported previously (1,2). We examined a new, easier technique for insertion of a 7.5F pulmonary arterial catheter (PAC) with oxymetry (Opticath™, Abbott Laboratories, Abbott Park, IL) into the CS guided by TEE in 11 subjects. After insertion of TEE probe, OPTICATH cath-eter tip was inserted into the right atrium via the right internal jugular vein and 1.5 mL of the saline was injected into the tip balloon (Fig. 1A). Twisting the catheter and advancing it forward, the tip balloon was guided to the orifice of the CS (Fig. 1B). The catheter was advanced into the CS, followed by balloon deflation and value of coronary sinus venous oxygen saturation (ScsO₂) rapidly drops on the monitor

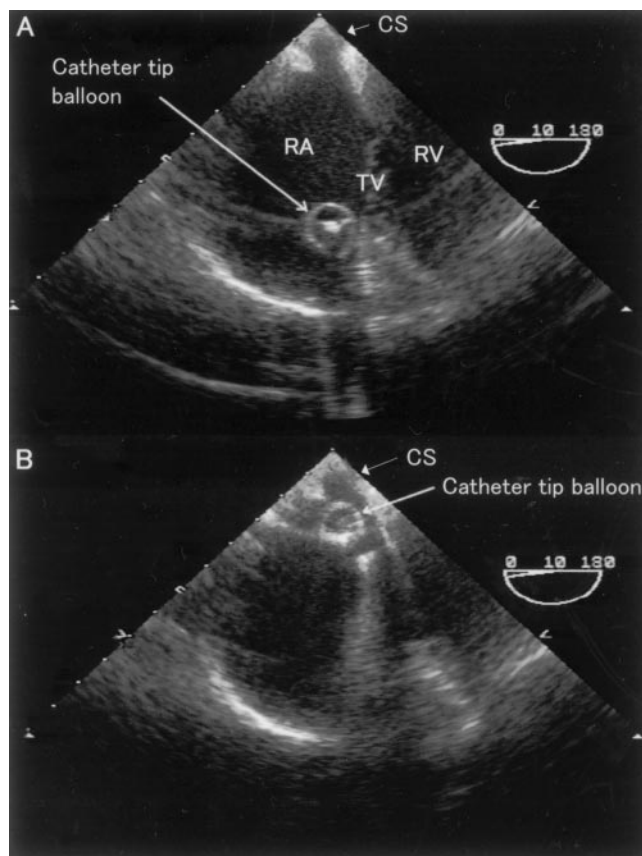


Figure 1. (A) The catheter tip was inserted into the right atrium and 1.5 mL of the saline was injected into the tip balloon. (B) The tip balloon was advanced to the orifice of the CS. CS = coronary sinus, RA = right atrium, RV = right internal jugular vein, TV = tricuspid valve.

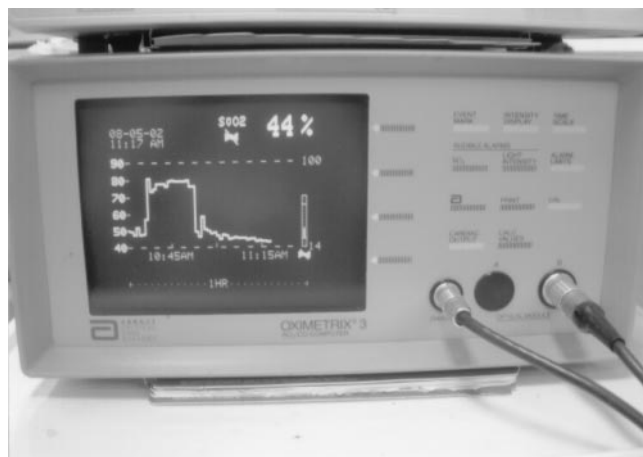

Figure 2. A rapid decrease of ScsO₂ on the monitor shows insertion of the catheter into the coronary sinus.

(Fig. 2). After this technique, the catheters were successfully inserted in all cases and the catheter was inserted into the CS within 30 min (median = 16 min; range, 2–29 min).

Using this technique, common PAC can be used for continuous monitoring of ScvO_2 , which shows the balance of whole myocardial oxygen supply and demand (3,4). Furthermore, other information could be obtained through this catheter, such as lactate production that reflects myocardial metabolic state.

Yoshihiro Ishikawa, MD
Tetsuya Miyashita, MD
Yasuhiro Koide, MD
Michihiro Sakai, MD
Tomio Andoh, MD
Yoshitsugu Yamada, MD

Department of Anesthesiology
Yokohama City University School of Medicine
Yokohama, Japan

References

1. Plotkin IM, Collard CD, Aranki SF, et al. Percutaneous coronary sinus cannulation guided by transesophageal echocardiography. *Ann Thorac Surg* 1998;66:2085–7.
2. Clements F, Wright SJ, de Bruijn N. Coronary sinus catheterization made easy for port-access minimally invasive cardiac surgery. *J Cardiothorac Vasc Anesth*. 1998;12:96–101.
3. Kumon K, Kuwabara M, Hirata T, et al. Continuous measurement of coronary sinus oxygen saturation after cardiac surgery. *Crit Care Med* 1987;15:595–7.
4. Crake T, Canepa-Anson R, Shapiro Le, Poole-Wilson PA. Continuous recording of coronary sinus oxygen saturation during atrial pacing in patients with coronary artery disease or with syndrome X. *Br Heart J* 1988;59:31–8.

DOI: 10.1213/01.ANE.0000067925.62656.A2

Mutism as a Complication of Total Intravenous Anesthesia by Propofol

To the Editor:

We read with interest the recent case report by Kati et al. (1). The authors describe a 56-year-old woman who developed somnolence and mutism for 11 days postoperatively, after total intravenous anesthesia with fentanyl, propofol, and vecuronium for a femur fracture fixation. The authors concluded that this neurologic complication may be attributed to an unknown effect of propofol.

We think another possible explanation for the symptoms described in the case may have been a presentation of central anticholinergic syndrome (CAS). The signs and symptoms of CAS are similar to those described with atropine overdose and consist of somnolence, confusion, amnesia, agitation, hallucinations, ataxia, delirium, stupor, or coma in addition to tachycardia, dry mouth, dry skin, visual disturbances, and dysarthria (2). CAS occurs when drugs occupy central cholinergic sites leading to insufficient release of acetylcholine (2). CAS has been linked to many drugs including atropine sulfate, hyoscine, promethazine, benzodiazepines, opioids, halothane, and ketamine (3). CAS has also been described after propofol anesthesia (4) and even after nitrous oxide withdrawal (5). In animal studies, it has been shown that fentanyl has strong affinity for muscarinic receptors, whereas morphine and alfentanil do not exhibit any affinity for muscarinic receptors (6).

Since the patient in the presented case received propofol, fentanyl, and atropine during anesthesia, we feel that CAS is a distinct possibility. CAS symptoms may last from hours to days (7).

The diagnosis of CAS is made by exclusion, after ruling out other causes of delayed recovery from anesthesia and by a positive therapeutic response to physostigmine, a centrally active anticholinesterase agent.

The incidence of CAS during the postoperative period has been reported to be up to 9.4% after general anesthesia and 3.3% after regional anesthesia with sedation (2). In a prospective study of 962 patients by Link et al. (8), 18 patients developed the syndrome, all of whom responded promptly to physostigmine administration. Katsanoulas et al. (9), reported two cases in which a delay in diagnosis of CAS resulted in unanticipated intensive care admission and acute lung injury.

We suggest that the diagnosis of CAS should be considered in all patients, including the one in the case report by Kati et al. (1), who demonstrate abnormal postanesthetic awakening. Additionally, physostigmine should be readily available (10) and administered perioperatively in situations where the possibility of this diagnosis is considered.

Venkatesh Srinivasa, MD

Peter Gerner, MD

Sunil Eappen, MD

Departments of Anesthesiology, Perioperative and Pain Medicine
Harvard Medical School
Brigham and Women's Hospital
Boston, MA

Dr. Kati does not wish to respond.

References

1. Kati I, Demirel CB, Anlar O, et al. An unusual complication of total intravenous anesthesia: mutism. *Anesth Analg* 2003;96:168–70.
2. Rupprecht J, Dworacek B. The central anticholinergic syndrome in the postoperative period. In: Nunn JF, Utting JE, Brown BR eds. *General anaesthesia*. 5th ed. London: Butterworths, 1989:1141–8.
3. Rupprecht J, Dworacek B. Central anticholinergic syndrome during postoperative period. *Ann Fr Anesth Reanim* 1990;9:295–304.
4. Kaiser-Stadler M, Altmayer P. Central anticholinergic syndrome after propofol anesthesia. *Anesthesiol Intensivmed Notfallmed Schmerzther* 1995;30:116–7.
5. Rupprecht J, Dworacek B, Ducardus R, et al. The involvement of the central cholinergic and endorphinergic systems in the nitrous oxide withdrawal syndrome in mice. *Anesthesiology* 1983;58:524–6.
6. Hustveit O. Binding of fentanyl and pethidine to muscarinic receptors in rat brain. *Jpn J Pharmacol* 1994;64:57–9.
7. Riis J, Lomholt B, Haxholdt O, et al. Immediate and long-term mental recovery from general versus epidural anesthesia in elderly patients. *Acta Anaesthesiol Scand* 1983;27:44–9.
8. Link J, Papadopoulos G, Dopjans D, et al. Distinct central anticholinergic syndrome following general anesthesia. *Eur J Anaesthesiol* 1997;14:15–23.
9. Katsanoulas K, Papaioannou A, Fraidakis O, Michaloudis D. Undiagnosed central anticholinergic syndrome may lead to dangerous complications. *Eur J Anaesthesiol* 1999;16:803–9.
10. Martin B, Howell PR. Physostigmine: going...going...gone? Two cases of central anticholinergic syndrome following anaesthesia and its treatment with physostigmine. *Eur J Anaesthesiol* 1997;14:467–70.

DOI: 10.1213/01.ANE.0000068119.81418.28

New Avenues of Epidural Research

To the Editor:

The case report by Kasai et al. (1) and the accompanying editorial by Rose (2) remind us that the potential for serious risk is inherent with every neuraxial procedure performed. Rose (2) has provided us with some commonsense guidelines to help us prevent such complications. We personally concur with his conclusions but wish to bring attention to two new avenues of research.

Techniques are being developed to help make neuraxial procedures safer, particularly in heavily sedated or anesthetized patients. Entry into the epidural or intrathecal space can be reliably demonstrated electrically (3,4). Previous studies (5–7) have demonstrated that a motor response evoked by 1 mA or less indicates the catheter is either in the subarachnoid space (SA) or close to a nerve root (subdural, 0.3 mA; SA, 0.4 mA; immediate proximity to a nerve root, 0.5 mA). These observations support the potential application of electrical epidural stimulation or Tsui test (3–8) as an adjunct method to identify the precise location of a needle or catheter in the epidural space.

A modification of the Tsui test can be used to help guide an insulated needle into the caudal or epidural space (9–10). In a porcine model, Tsui et al. (10) have demonstrated that the test can be used to reliably detect entry of an insulated Tuohy needle into the epidural space. By using supramaximal delivered currents and ensuring the subject has not been paralyzed, proximity to any motor neuron (nerve, nerve root, or spinal cord) can be reliably detected. This is done by sequentially reducing the current to a level where the motor response just disappears, while

advancing the Tuohy needle using a continuous loss-of-resistance (LOR) technique. Entry into the epidural space will be signaled by a LOR and the simultaneous recurrence of the motor response (at an appropriate myotomal level) with a delivered current well above 1 mA. If, at any time, a motor response occurs at a current below 1 mA, proximity to a nerve structure is assured and further advancement of the needle is not advised as it may risk injury. The use of a nerve stimulator to perform peripheral nerve blocks in anesthetized patients has not been demonstrated to enhance safety (11). However, epidural stimulation, unlike peripheral nerve localization, uses a supramaximal current sufficient to stimulate any motor nerve structure within several centimeters. The principle goal when performing a peripheral nerve block is to seek the minimal current sufficient to stimulate a motor nerve (generally <0.5 mA) (11,12). Although there is only a single published laboratory study examining this application, the test has the potential to monitor a motor response in clinical settings where paresthesia cannot be reported. This technique has potential to make neuraxial procedures safer and should not be overlooked.

Investigators in Europe have developed expertise in visualizing the epidural space with ultrasound (13,14). Real-time imaging with ultrasound may further enhance the safety of neuraxial procedures (15).

While we agree with Dr. Rose (2) that further research is necessary to verify the "broadly held belief that epidural analgesia is associated with better postoperative analgesia," we feel we also need to address more philosophical issues. For example, what is a reasonable risk? Furthermore, as Dr. Rose implies (2), how can we acquire a fully informed consent when we do not fully understand the nature of the risk? Research into the pathogenesis of spinal epidural hematoma formation, evolution, and incidence is desperately needed.

Scott A. Lang
University of Calgary
Department of Anesthesia
Foothills Hospital
Calgary, Alberta
Canada

Ban Tsui, MD, MSC, FRCP(C)
Department of Anesthesiology and Pain Medicine
University of Alberta Hospital
Edmonton, Alberta
Canada

Thomas Grau, MD
University of Heidelberg
Department of Anaesthesiology
Heidelberg, Germany

References

1. Kasai T, Yaegashi K, Hirose M, Tanaka Y. Spinal cord injury in a child caused by an accidentally dural puncture with a single shot thoracic epidural needle. *Anesth Analg* 2003;96:65–7.
2. Rose JB. Spinal cord injury in a child after single-shot epidural anesthesia. *Anesth Analg* 2003;96:3–6.
3. Tsui BC, Gupta S, Finucane B. Confirmation of epidural catheter placement using nerve stimulation. *Can J Anaesth* 1998;45:640–4.
4. Hayatsu K, Tomita M, Fujihara H, et al. The placement of the epidural catheter at the predicted site by electrical stimulation test. *Anesth Analg* 2001;93:1035–9.
5. Tsui BCH, Gupta S, Finucane B. Detection of subdural placement of epidural catheter using nerve stimulation. *Can J Anaesth* 2000;47:471–3.
6. Tsui BCH, Gupta S, Finucane B. Detection of subarachnoid and intravascular epidural catheter placement. *Can J Anaesth* 1999;46:7:675–8.
7. Tsui BCH, Guenther C, Emery D, Finucane B. Determination epidural catheter location using nerve stimulation with radiological confirmation. *Reg Anesth Pain Med* 2000; 25:306–9.
8. Lang SA, Korzeniewski P, Buie D, et al. Repeated failure of epidural analgesia: an association with epidural fat? *Reg Anesth Pain Med* 2002;27:494–500.
9. Tsui BCH, Tarkila P, Gupta S, Kearney R. Confirmation of caudal needle using nerve stimulation. *Anesthesiology* 1999;91:374–8.
10. Tsui BCH, Uwiera R, Emery D, Finucane B. Epidural needle using electrical guidance in a porcine model [abstract]. *Anesthesiology* 2002; 96:A723.
11. Benumof JL. Permanent loss of cervical spinal cord function associated with interscalene block performed under general anesthesia. *Anesthesiology* 2000;93:1541–4.
12. Lang SA. The art and science of using a peripheral nerve stimulator: how close is close enough [letter]? *Reg Anesth Pain Med* 2002;27:330–2.
13. Grau T, Leipold R, Conradi R, et al. Ultrasound imaging facilitates localization of the epidural space during combined spinal-epidural anesthesia. *Reg Anesth Pain Med* 2001;26:64–7.
14. Grau T, Leipold RW, Delorme S, et al. Ultrasound imaging of the thoracic epidural space. *Reg Anesth Pain Med* 2002;27:200–6.

15. Grau T, Leipold RW, Conradi R, et al. Die Darstellung von Duraperforationen und Bloodpatches mit Ultraschall. *Anesthesiol Intensivmed Notfallmed Schmerzther* 2002; 37:149–53.

DOI: 10.1213/01.ANE.0000067920.62656.FE

In Response:

We wish to thank Dr. Lang for his correspondence. We think epidural techniques will be safer if such new methods of epidural approach develop and gain popularity.

T. Kasai
K. Yaegashi
H. Hirose
Y. Tanaka
Department of Anesthesiology
Kyoto Prefectural University of Medicine
Kyoto, Japan

Fat and Bone Marrow Embolism During Percutaneous Vertebroplasty

To the Editor:

Chen et al. (1) report a case of pulmonary embolism leading to cardiac arrest during percutaneous vertebroplasty. Increased intraosseous pressure during insertion of cement is the causative factor for the passage of fat and bone marrow into the venous circulation and the right heart. Embolic material can be visualized using transesophageal echocardiography (TEE) (2–4).

In a sheep model (2) TEE revealed during vertebroplasty embolic material in the right atrium and the pulmonary artery. Online data registration showed within 2 ± 1 s after injection of bone cement a decrease of heart rate, mean arterial pressure, and an increase of pulmonary artery pressure. Whereas first echogenic particles were visible with TEE 6 ± 1 s after cement injection. A second, less severe, hemodynamic affection started after 18 ± 2 s. The first (immediate) reaction could be mediated by a reflex activity, increasing the pulmonary vascular tone. This is supported by a study of Jahn et al. (5), who found that a thoracic sympathetic blockade can improve the cardiovascular outcome after pulmonary embolism. The second (late) reaction is caused by occlusion of pulmonary vessels by fat and bone marrow, leading to reduced left ventricular filling and low output.

Vertebroplasty can cause pulmonary embolism of fat and bone marrow and a cardiac reflex response. A bone-venting hole connected to a vacuum suction (3,4) and epidural injection of local anesthetics may reduce the risk of cardiopulmonary complications.

Matthias J. Koessler, MD
Department of Anesthesiology and Intensive Care
Waldkrankenhaus St. Marien
Erlangen, Germany

Nikolaus Aebli, MD
Department of Orthopaedic Surgery,
Dunedin School of Medicine, Dunedin Hospital
Dunedin, New Zealand

Rocco P. Pitto, MD, PhD
Department of Orthopaedic Surgery,
University of Auckland, Middlemore Hospital
Auckland, New Zealand

References

1. Chen H-L, Wong C-S, Ho S-T, et al. A lethal pulmonary embolism during percutaneous vertebroplasty. *Anesth Analg* 2002;95:1060–2.
2. Aebli N, Krebs J, Davis G, et al. Fat embolism and acute hypotension during vertebroplasty: an experimental study in sheep. *Spine* 2002;27:460–6.
3. Koessler MJ, Fabiani R, Hamer H, Pitto RP. The clinical relevance of embolic events detected by transesophageal echocardiography during cemented total hip arthroplasty: a randomized clinical trial. *Anesth Analg* 2001;92:49–55.
4. Pitto RP, Koessler M, Draenert K. The John Charney Award: Prophylaxis of fat and bone marrow embolism during cemented total hip arthroplasty. *Clin Orthop* 1998;355: 23–34.
5. Jahn UR, Waurick R, Van Aken H, et al. Thoracic, but not lumbar, epidural anesthesia improves cardiopulmonary function in ovine pulmonary embolism. *Anesth Analg* 2001;93:1460–5.

DOI: 10.1213/01.ANE.0000067922.62656.GC

In Response:

We thank Koessler et al. for their interesting, concerned, and valuable comments on our article (1). Their experimental animal study demonstrated that embolic material in the right atrium and the pulmonary artery is always observed during vertebroplasty (2).

We completely agree with their comments that thoracic epidural sympathetic blockade can improve the cardiovascular outcome (3), and that a bone venting connected to a vacuum suction may reduce the risk of cardiovascular complications (4,5). Moreover, perhaps the experience of the surgeon plays the most important role in this complication. In this case, multiple vertebral punctures and injections of several batches of cement were performed by an inexperienced surgeon; this was his third procedure. Our experience is that these procedures were smooth and without any complication during operation under either IV sedation or general anesthesia. However, we suggest that intraoperative TEE is the paramount monitor for the patient receiving general anesthesia, and a thoracic epidural anesthesia may be a good anesthetic choice for high-risk patients.

Hsueh-Lin Chen, MD

Ching-Tang Wu, MD

Chih-Shung Wong, PhD, MD

Department of Anesthesiology

Tri-Service General Hospital and National Defense Medical Center
Taipei, Taiwan

References

1. Chen H-L, Wong C-S, Ho S-T, et al. A lethal pulmonary embolism during percutaneous vertebroplasty. *Anesth Analg* 2002;95:1060-2.
2. Aebli N, Krebs J, Davis G, et al. Fat embolism and acute hypotension during vertebroplasty: an experimental study in sheep. *Spine* 2002;27:460-6.
3. Jahn UR, Waurick R, Van Aken H, et al. Thoracic, but not lumbar, epidural anesthesia improves cardiopulmonary function in ovine pulmonary embolism. *Anesth Analg* 2001;93:1460-5.
4. Koessler MJ, Fabiani R, Hamer H, Pitto RP. The clinical relevance of embolic events detected by transesophageal echocardiography during cemented total hip arthroplasty; a randomized clinical trial. *Anesth Analg* 2001;92:49-55.
5. Pitto RP, Koessler M, Draenert K. The John Charnley Award: Prophylaxis of fat and bone marrow embolism during cemented total hip arthroplasty. *Clin Orthop* 1998;355:23-34.

Managing a Tachyarrhythmia in a Patient with Pheochromocytoma with Landiolol, a Novel Ultrashort-Acting β -Adrenergic Blocker

To the Editor:

Recently, short-acting β -adrenergic blockers, such as esmolol, have been recommended for treating pheochromocytoma-induced tachyarrhythmias. Landiolol hydrochloride (landiolol), is a novel ultrashort-acting β -adrenergic blocker that has higher β_1 -selectivity ($\beta_1/\beta_2 = 255$) and a shorter elimination $t_{1/2}$ (4 min in healthy subjects) than esmolol (1-3). Here, we report the management of a tachyarrhythmia due to pheochromocytoma in a 63-yr-old woman taking landiolol. After inserting an epidural catheter at T9/10, general anesthesia was induced with fentanyl 2 μ g/kg and propofol 100 mg, and maintained with nitrous oxide 2 L/min, oxygen 3 L/min, and 1-1.5% sevoflurane; 0.75% ropivacaine, 6 mL were administered intermittently via the epidural catheter. A tachyarrhythmia and paroxysmal hypertension over 240 mm Hg occurred during tumor manipulation. Although the intravenous administration of nicardipine attenuated the hypertension, the tachyarrhythmia deteriorated (Fig. 1A). Consequently, landiolol

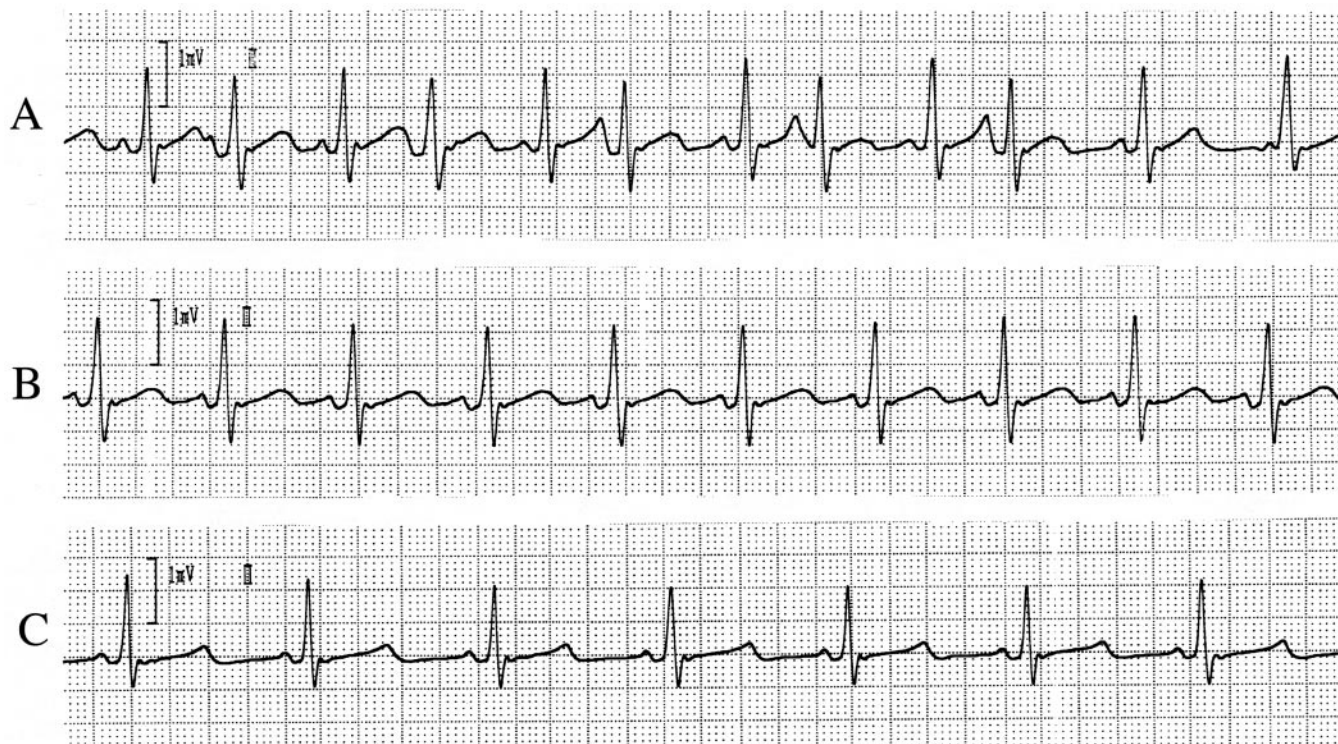


Figure 1. Electrocardiogram recorded at the following times: (A) before administering landiolol hydrochloride; (B) 1 min after administering landiolol hydrochloride 125 mg/kg/min for 1 min; (C) 4 min after B.

125 mg/kg/min IV was given for 1 min and then maintained at 40 mg/kg/min IV. One minute after starting the landiolol, her heart rate decreased to 88 bpm (Fig. 1B) and stabilized at 64 bpm after 5 min with normal sinus rhythm (Fig. 1C). After tumor vein ligation, the landiolol was discontinued and her hemodynamics were stable without hypotension. This case demonstrates that landiolol is useful for treating pheochromocytoma-induced tachyarrhythmia safely without hypotension.

Junichi Ogata, MD
Toru Yokoyama, MD
Takashi Okamoto, MD
Kouichiro Minami, MD, PhD

Department of Anesthesiology
University of Occupational and Environmental Health School of Medicine
Fukuoka, Japan

References

1. Nicholas E, Deutschman CS, Allo M, Rock P. Use of esmolol in the intraoperative management of pheochromocytoma. *Anesth Analg* 1988;67:1114–7.
2. Atarashi H, Kuruma A, Yashima M, et al. Pharmacokinetics of landiolol hydrochloride, a new ultra-short-acting beta-blocker, in patients with cardiac arrhythmias. *Clin Pharmacol Ther* 2000;68:143–50.
3. Muraki K, Nakagawa H, Nagano N, et al. Effects of ONO-1101, a novel beta-antagonist, on action potential and membrane currents in cardiac muscle. *J Pharmacol Exp Ther* 1996;278:555–63.

DOI: 10.1213/01.ANE.0000067919.62656.73

Is Desflurane a “Weak” Trigger of Malignant Hyperthermia?

To the Editor:

With great interest we read the report by Hoenemann et al. concerning a case of delayed onset of malignant hyperthermia (MH) during inhaled anesthesia with desflurane (1). This report seem to support the assumption that desflurane might be a “weak” trigger of MH compared to other volatile anesthetics. However, this report raises two relevant issues.

First, the onset of MH may be delayed also after administration of other trigger substances (2–5). In previous reports onset times of 9 (3) or 18 h (4), respectively, after isoflurane and succinylcholine administration have been described. Furthermore, a review of the database of the North American MH Registry presenting desflurane-related MH events showed that the onset times for MH after halothane were not significantly different from those after desflurane (6). Therefore, it must be stated that onset times are no clinical indicator for the trigger potency of anesthetics, and consequently it has to be clarified that desflurane is a trigger of MH like all other volatile anesthetics and must be avoided in all patients susceptible to MH.

Second, the authors stated that a causal link between desflurane and the observed symptoms was confirmed by postoperative testing. This is not correct. An *in vitro* contracture test (IVCT) according to the standard procedure of the European MH Group has been performed, but this test failed to give an unambiguous result due to technical problems. On the one hand, it would be interesting to know which problems occurred, because for our knowledge this is the first time that such problem was presented in the literature. On the other hand, it should be explained whether the authors recommended to perform the IVCT in this patient for a second time, or performed the IVCT in the direct family members, respectively.

Further studies are needed to investigate which factors might modify the onset and course of MH. First steps in this direction were made and it could be demonstrated that *in vitro* contracture test results depend on different malignant hyperthermia-associated ryanodine receptor gene mutations (7). Whether these observations are of relevance also under *in vivo* conditions, however, remain unclear until now.

Frank Wappler, MD
Marko Fiege, MD
Department of Anesthesiology
University Hospital Hamburg-Eppendorf
Hamburg, Germany

References

1. Hoenemann CW, Halene-Holtgraefe TB, Booke M, et al. Delayed onset of malignant hyperthermia in desflurane anesthesia. *Anesth Analg* 2003;96:165–7.
2. Bichel T, Canivet JL, Damas P, Lamy M. Malignant hyperthermia and severe hypoglycemia after reexposure to halothane. *Acta Anaesthesiol Belg* 1994;45:23–7.
3. Karger B, Teige K. Fatal malignant hyperthermia: delayed onset and atypical course. *Forensic Sci Int* 2002;129:187–90.
4. Short JA, Cooper CM. Suspected recurrence of malignant hyperthermia after postextubation shivering in the intensive care unit, 18 h after tonsillectomy. *Brit J Anaesth* 1999;82:945–7.
5. Souliere CR, Weintraub SJ, Kirchner JC. Markedly delayed postoperative malignant hyperthermia. *Arch Otolaryngol Head Neck Surg* 1986;112:564–6.
6. Allen GC, Brubaker CL. Human malignant hyperthermia associated with desflurane anesthesia. *Anesth Analg* 1998;86:1328–31.
7. Fiege M, Wappler F, Weissborn R, et al. Results of contracture test with halothane, caffeine, and ryanodine depend on different malignant hyperthermia-associated ryanodine receptor gene mutations. *Anesthesiology* 2002;97:345–50.

DOI: 10.1213/01.ANE.0000068644.31333.BD

In Response:

In this reply I would like to thank Drs. Wappler and Fiege for their comments on our case report on the delayed onset of malignant hyperthermia (MH) during inhaled anesthesia with desflurane (1). In fact, desflurane is a trigger of MH compared with other volatile anesthetics.

First, onset time is no clinical indicator for the trigger potency of volatile anesthetics, and we never mentioned this in our case report. Second, we did not confirm the MH by postoperative testing and he is correct. We are sorry about that misleading title.

The *in vitro* contracture test (IVCT) according to the standard procedure of the European MH Group and all the other tests have been performed or organized by Prof. Mortier (Abteilung für Neuropädiatrie, Kinderklinik der Ruhr-Universität, St. Josef-Hospital, Gudrunstr. 56, 44791 Bochum, Germany). He was so kind to give us all results at the end of the tests. I cannot make comments on the postoperative testing or on the statement of Dr. Wappler about technical problems. In fact, it was the first time that Prof. Mortier had such a problem with the IVCT, and he discussed all results with the patient and her family. To my knowledge, the family rejected the chance to perform a second IVCT.

Professor Mortier is a well-known specialist and his laboratory is listed as MH center on the homepage of the European MH Group (www.emhg.org). For any questions regarding this case and the postoperative testing, I would be happy to get all interested scientists in contact with Prof. Mortier.

Regarding the failed IVCT, I completely agree that further studies are necessary to investigate this problem, and it is of major interest which factors modify onset and course of MH.

Christian Hoenemann, MD
St. Marienhospital Vechta
Vechta, Germany

Reference

1. Hoenemann CW, Halene-Holtgraefe TB, Booke M, et al. Delayed onset of malignant hyperthermia in desflurane anesthesia. *Anesth Analg* 2003;96:165–7.

An Abbreviation of the ACC/AHA Algorithm for Perioperative Cardiovascular Evaluation for Noncardiac Surgery

To the Editor:

The recently published ACC/AHA Guideline Update for Perioperative Cardiovascular Evaluation for Noncardiac Surgery (1) provides an algorithm that can easily be followed in the decision-making process when presented with a patient possibly requiring further cardiac workup.

I would like to offer an alternative to this algorithm that utilizes the same thought process, but is easier to memorize. As with the algorithm, three assignments have to be made: clinical predictors (Table 1), functional capacity, and surgical risk (Table 2).

Each patient then gets a point score from each of the three columns in Table 3. The total score for the three columns is added. A point score of 4 or more would suggest the need for further

Table 1. Clinical Predictors

Major
Unstable coronary symptoms
Decompensated CHF
Significant arrhythmias
Severe valvular disease
Intermediate
Mild angina pectoris
Prior MI
Compensated or prior CHF
Diabetes mellitus
Renal insufficiency
Minor
Advanced age
Abnormal ECG
Rhythm other than sinus
Low functional capacity
History of stroke
Uncontrolled systemic hypertension

CHF = congestive heart failure; MI = myocardial infarction; ECG = electrocardiogram.

Table 2. Surgery-Specific Risk

High
Emergent major operations, particularly in the elderly
Aortic or other major vascular surgery
Peripheral vascular surgery
Anticipated prolonged surgical procedures associated with large fluid shifts and/or blood loss
Intermediate
Carotid endarterectomy
Head and neck surgery
Intraperitoneal and intrathoracic surgery
Orthopedic surgery
Prostate surgery
Low
Endoscopic procedures
Superficial procedures
Cataract surgery
Breast surgery

Table 3. Point Score Summary

Clinical predictors	Functional capacity	Surgical risk
Major	Poor	High
4 points	2 points	2 points
Intermediate	Moderate or better	Intermediate
2 points	0 points	1 point
Minor		Low
0 points		0 points

cardiac evaluation. A patient with 3 points or fewer could proceed safely to the operating room.

This table is best understood in the context of the referenced article, which should be read. The principle advantage of Table 3 is that it is easily memorized.

David K. Stinson, MD
Department of Anesthesiology
Champlain Valley Physicians Hospital
Plattsburgh, NY

Reference

1. Eagle KA, Berger PB, Calkins H, et al. ACC/AHA Guideline Update for Perioperative Cardiovascular Evaluation for Noncardiac Surgery: Executive Summary. *Anesth Analg* 2002;94:1052-64.

DOI: 10.1213/01.ANE.0000067924.62656.EB

Continuous Sciatic Nerve Block: How to Choose Among Different Proximal Approaches? Gluteal or Subgluteal Continuous Sciatic Nerve Block

To the Editor:

We read with great interest the review article by Liu and Salinas (1) on continuous peripheral nerve blocks. However, there are some practical issues that must be considered when choosing the best approach for catheter placement, such as patient comfort and simplicity of technique.

In particular, the authors chose the technique described by Sutherland (2) to place a gluteal sciatic catheter. After appropriate patient positioning, Sutherland inserted a first stimulating needle at the level of the midpoint between the greater trochanter and the ischial tuberosity, followed by a second insulated Tuohy needle, inserted through the gluteus muscle 5 cm proximal to the first one. Although several other approaches allow to block continuously the sciatic nerve without changing patient position (3,4), gluteal approaches may represent a useful alternative. Nonetheless, the technique described seems troublesome for both the anesthesiologist and the patient. Di Benedetto et al. (3,5) reported on a subgluteal approach, which allows to place the catheter using one single Tuohy needle inserted 4-5 cm below the greater trochanter-ischial tuberosity line (Figure 1). This technique has been demonstrated to be similarly effective, but easier and less painful to the patient as compared with a more proximal gluteal approach (probably due to the shallower depth at which the sciatic nerve is identified) (3,5-7). Although Drs. Liu and Salinas' review has attempted to provide a very useful overview on continuous peripheral nerve blocks, anesthesiologists must be aware that the choice of the technique cannot

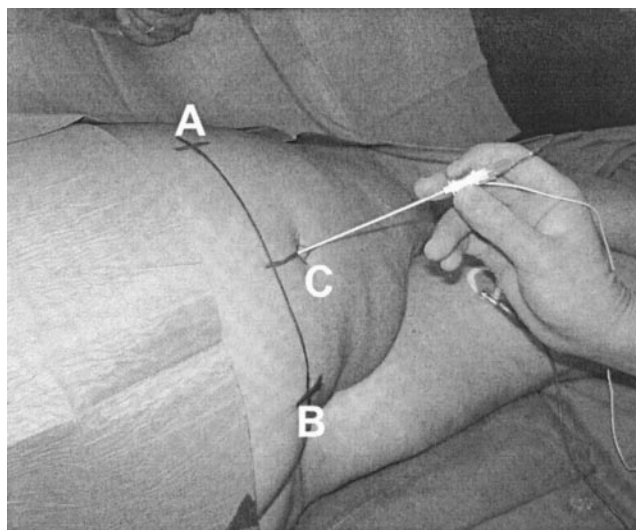


Figure 1. Landmarks to perform continuous subgluteal sciatic nerve block. A line is drawn from the greater trochanter (A) to the ischial tuberosity (B). From the midpoint of this line a second line is drawn perpendicularly and extending caudally for 4-5 cm. This point (C) represents the site for needle insertion. After eliciting the appropriate foot response with an 18-gauge insulated Tuohy needle, a 20-gauge epidural catheter can be threaded through the needle for no more than 4-5 cm beyond the tip of the Tuohy needle.

be based only on theoretical considerations. The literature is still far from reflecting the research that is being conducted in this area of regional anesthesia.

Pia di Benedetto, MD
Department of Anesthesiology
CTO Hospital
Rome, Italy

Guido Fanelli, MD
Department of Anesthesiology
University of Parma,
Parma, Italy

Jacques E. Chelly, MD, PhD, MBA
Department of Anesthesiology
University of Pittsburgh
Pittsburgh, PA

Andrea Casati, MD
Department of Anesthesiology
Vita-Salute University of Milano
Milan, Italy

References

1. Liu SS, Salinas FV. Continuous plexus and peripheral nerve blocks for postoperative analgesia. *Anesth Analg* 2003;96:263–72.
2. Sutherland ID. Continuous sciatic nerve infusion: expanded case report describing a new approach. *Reg Anesth Pain Med* 1998;23:496–501.
3. Casati A, Chelly JE, di Benedetto P, Fanelli G. Sacral plexus and sciatic nerve block. In: Chelly JE, Casati A, Fanelli G, eds. Continuous peripheral nerve block techniques. Segrate, Italy: Mosby, 2001:67–80.
4. Chelly JE, Greger J, Casati A, et al. Continuous lateral sciatic blocks for acute postoperative pain management after major ankle and foot surgery. *Foot Ankle Int* 2002;23:749–52.
5. di Benedetto P, Bertini L, Casati A, et al. A new posterior approach to the sciatic nerve block: a prospective, randomized comparison with the classic posterior approach. *Anesth Analg* 2001;93:1040–4.
6. di Benedetto P, Casati A, Bertini L. Continuous subgluteus sciatic nerve block after orthopedic foot and ankle surgery: comparison of two infusion techniques. *Reg Anesth Pain Med* 2002;27:168–72.
7. di Benedetto P, Casati A, Bertini L, et al. Postoperative analgesia with continuous sciatic nerve block after foot surgery: a prospective, randomized comparison between the popliteal and subgluteal approaches. *Anesth Analg* 2002;94:996–1000.

DOI: 10.1213/01.ANE.0000067923.62656.25

In Response:

We thank di Benedetto et al. for their interest in our review article (1), and specifically on the novel technique described by Sutherland for continuous sciatic perineural analgesia (2). Due to unforeseen circumstances, there was a substantial delay between delivery of the final version of the manuscript to the editorial office and publication. Otherwise, we would have certainly included their prospective, randomized trial comparing subgluteal to posterior popliteal approach for continuous sciatic analgesia in our overview (3).

We wish to also note several other studies that were published after finalization of our manuscript. Two prospective, randomized, blinded trials were published that demonstrated superior efficacy of continuous infraclavicular brachial plexus and sciatic nerve analgesia to systemic opioid-based analgesia in the ambulatory setting (4,5). An additional prospective, randomized, blinded trial demonstrated the suitability of either bupivacaine or ropivacaine for continuous axillary brachial plexus analgesia in the ambulatory setting (6). Finally, two open, randomized studies demonstrated the efficacy, pharmacokinetics, and safety of different ropivacaine infusions for continuous perineural analgesia (7,8).

Although these additional studies improve our state of knowledge, we agree with di Benedetto et al. that further well-designed clinical trials are needed to determine which surgical procedures gain benefit from continuous perineural analgesia, what are the optimal techniques/anatomic approaches for various continuous nerve blocks, and what are the optimal analgesic solutions and methods of delivery for each application.

Francis V. Salinas, MD
Spencer S. Liu, MD
Department of Anesthesiology
Virginia Mason Medical Center
Seattle, WA

References

1. Liu SS, Salinas FV. Continuous plexus and peripheral nerve blocks for postoperative analgesia. *Anesth Analg* 2003;96:263–72.

2. Sutherland ID. Continuous sciatic nerve infusion: expanded case report describing a new approach. *Reg Anesth Pain Med* 1998;23:496–501.
3. di Benedetto P, Casati A, Bertini L, et al. Postoperative analgesia with continuous sciatic nerve block after foot surgery: a prospective randomized comparison between the popliteal and subgluteus approaches. *Anesth Analg* 2002;94:996–1000.
4. Ilfeld B, Morey T, Enneking FK. Continuous infraclavicular brachial plexus block for postoperative pain control at home: a randomized, double-blinded, placebo-controlled study. *Anesthesiology* 2002;96:1297–304.
5. Ilfeld B, Morey T, Wang RD, Enneking FK. Continuous popliteal sciatic nerve block for postoperative pain control at home: a randomized, double-blinded, placebo-controlled study. *Anesthesiology* 2002;97:959–65.
6. Rawal N, Allvin R, Axelsson K, et al. Patient-controlled regional analgesia (PCRA) at home: controlled comparison between bupivacaine and ropivacaine brachial plexus analgesia. *Anesthesiology* 2002;96:1290–6.
7. di Benedetto P, Casati A, Bertini L. Continuous subgluteus sciatic nerve block after orthopedic foot and ankle surgery: comparison of two infusion techniques. *Reg Anesth Pain Med* 2002;27:168–72.
8. Ekatoedramis G, Borgeat A, Huledal G, et al. Continuous interscalene analgesia with ropivacaine 2 mg/ml after major shoulder surgery. *Anesthesiology* 2003;98:143–50.

Minimizing Risks for Donors Undergoing Right Hepatectomy for Living-Related Liver Transplantation

To the Editor:

We have read with interest the article by Lutz et al. (1) on living donor liver transplantation (LDLT). They point out that “anesthetic perioperative management is crucial for minimizing risks,” “In most of the donors, a thoracic epidural catheter was inserted preoperatively,” and “during surgery, the patients received epidurally bupivacaine 0.5%.”

Have the authors considered that liver dysfunction is present in the majority of adult patients after right hepatectomy? (2). If so, how to justify a technique that has a specific risk for perioperative epidural hematoma (3)?

Thoracic epidural anesthesia with 0.5% bupivacaine in patients who have a blood loss of more than 2,000 mL (4 donors) presents some serious concerns for intraoperative hemodynamic stability. This is of paramount importance to preserve hepatic function perioperatively.

At our institution, we performed 33 LDLTs under general anesthesia since January 2002. In the donor group, there was no need for intraoperative blood transfusion or blood salvage techniques; no epidural catheters were placed in the last 31 patients.

Advancement of LDLT will be mostly related to our ability to minimize risks to the donors. Although minimal, epidural anesthesia or analgesia involves recognized risks. There are other safe and effective alternatives we can offer to our patients.

Flavio Takaoka
Alexandre Teruya
Paulo Massarollo
Sérgio Mies
Transplantation Division
Hospital Israelita Albert Einstein
São Paulo, Brazil
takaoka@einstein.br or ytakaoka@uol.com.br

References

1. Lutz JT, Valentin-Gamazo C, Gorlinger K, et al. Blood-transfusion requirements and blood salvage in donors undergoing right hepatectomy for living related liver transplantation. *Anesth Analg* 2003;96:351–5.
2. Niemann CU, Roberts JP, Ascher NL, Yost CS. Intraoperative hemodynamics and liver function in adult-to-adult living liver donors. *Liver Transpl* 2002;8:1126–32.
3. Matot I, Scheinin O, Eid A, et al. Epidural anesthesia and analgesia in liver resection. *Anesth Analg* 2002;95:1179–81.

DOI: 10.1213/01.ANE.0000066401.03667.45

In Response:

We appreciate the interest in our article (1). Obviously, as in any patient undergoing central neuraxis blockade, benefits (2,3) and risks have to be considered carefully. Thoracic epidural anesthesia has been shown to minimize pulmonary complications after surgery (3). We offered epidural pain therapy to living liver donors for the same reasons as for other patients undergoing liver resections. In a study of 4185 patients, some of them with abnormal coagulation, we

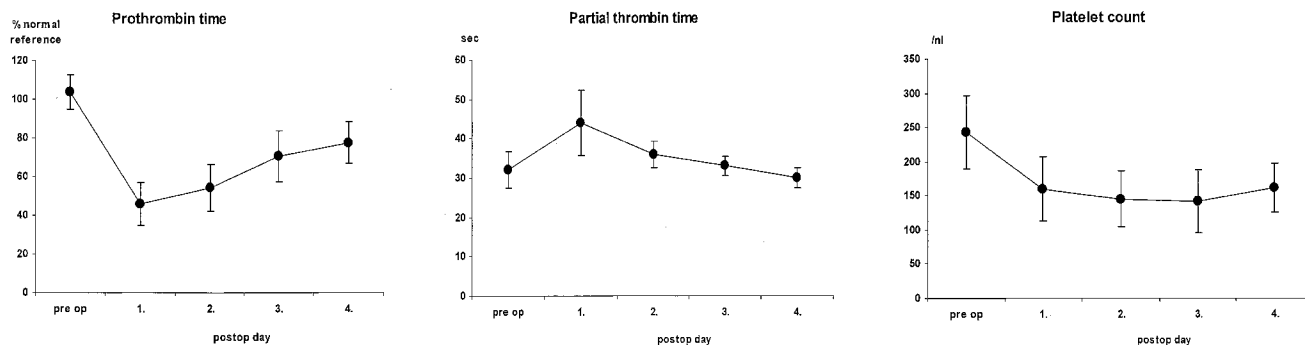


Figure 1. Coagulation tests (prothrombin time, partial prothrombin time, and platelet count) on the day of surgery and on days 1–4 postoperatively.

did not find a single epidural hematoma (4) and have extensive experience with this technique. Data from patients with previously inserted thoracic epidural catheters undergoing cardiopulmonary bypass while being fully heparinized suggest that epidural anesthesia can be safe even under these conditions (5).

Finally, coagulation tests in our donors confirm that this management is feasible, considering that epidural catheters were exclusively inserted in donors with normal preanesthesia coagulation tests and pulled postoperatively while coagulation tests were within normal limits (see Figure 1).

Obviously, there is no sound rationale to withhold an established therapy, epidural anesthesia, to living donors when considering it worthwhile for no donor patients undergoing liver resection.

Needless to say that we are used to administer epidural bupivacaine with respect to hemodynamic stability and perfusion pressures.

We congratulate the authors for not even being dependent on blood salvage techniques but have not seen these data published. However, considering that maximum safety of the donor clearly is the goal we do not understand why these techniques are not used by Takaoka et al.

J. T. Lutz, MD, DEAA

K. Görlinger, MD

J. Peters, MD

Klinik für Anästhesiologie und Intensivmedizin

C. Valentin-Gamazo, MD

M. Malago, MD

Klinik für Allgemein und Transplantationschirurgie
Universitätsklinikum Essen
Essen, Germany

References

1. Lutz JT, Valentin-Gamazo C, Görlinger K, et al. Blood-transfusion requirements and blood salvage in donors undergoing right hepatectomy for living related liver transplantation. *Anesth Analg* 2003;96:351–5.
2. Rigg JR, Jamrozik K, Myles PS, et al. Epidural anaesthesia and analgesia and outcome of major surgery: a randomised trial. *Lancet* 2002;359:1276–82.
3. Ballantyne JC, Carr DB, deFerranti S, et al. The comparative effects of postoperative analgesic therapies on pulmonary outcome: cumulative meta-analyses of randomized, controlled trials. *Anesth Analg* 1998;86:598–612.
4. Giebler RM, Scherer RU, Peters J. Incidence of neurologic complications related to thoracic epidural catheterization. *Anesthesiology* 1997;86:55–63.
5. Sanchez R, Nygard E. Epidural anesthesia in cardiac surgery: is there an increased risk? *J Cardiothorac Vasc Anesth* 1998;12:170–3.

The Quality of Epidural Anesthesia Is Crucial in the Assessment of Perioperative Outcome

To the Editor:

Peyton et al. (1) performed a subgroup analysis of high-risk patients of the MASTER trial (2) to eliminate previous criticisms (3,4). The authors additionally analyzed three centers with presumed expertise, which randomized more than 50% of patients, but again did not

provide details about the epidural technique and thus failed to eliminate the notion that limited experience might have influenced the results.

Although the meaning of comparing 32 patients with early epidural failure to the control group remains in doubt, the question still arises as to why the authors only deemed 32 catheters as a failure. Of the 447 patients with epidural anesthesia included in the intention-to-treat analysis in the MASTER trial, 36 patients never received epidural analgesia, 3 catheters were inserted postoperatively, and, most importantly, epidural analgesia was terminated after less than 72 h in 183 patients. These 225 noncompliant patients account for 50.3% of all patients in the epidural group and a major proportion was obviously included in the present analysis. The intention-to-treat analysis is thus significantly distorted, and a subgroup analysis of protocol-compliant patients would have been necessary to discern the influence of epidural anesthesia on outcome. It may thus be concluded the MASTER trial is still not the masterpiece it was intended to be.

Wiebke Gogarten, MD

Hartmut Buerkle, MD, PhD

Hugo Van Aken, MD, PhD

Department of Anaesthesiology and Intensive Care
University Hospital of Muenster
Muenster, Germany

References

1. Peyton, P.J. Myles PS, Silbert BS, et al. Perioperative epidural analgesia and outcome after major abdominal surgery in high-risk patients. *Anesth Analg* 2003;96:548–54.
2. Rigg JA, Jamrozik K, Myles PS, et al. Epidural anaesthesia and analgesia and outcome of major surgery: a randomised trial. *Lancet* 2002;359:1276–82.
3. Van Aken H, Gogarten W, Bruessel T, Brodner G. Epidural analgesia and anesthesia in major surgery. *Lancet* 2002;360:568.
4. Kehlet H, Holte K. Epidural analgesia and anesthesia in major surgery. *Lancet* 2002; 360:568–9.

DOI: 10.1213/01.ANE.0000067926.62656.79

In Response:

In their letter, Gogarten et al. question the effectiveness of the epidural regimens across the trial centers. In our original publication (1), we clearly demonstrated that patients in the epidural group had a working epidural block intraoperatively (evidenced by significantly more hypotension) and postoperatively (evidenced by significantly improved pain scores for 3 days).

Gogarten et al. claim that in determining the effect of epidural analgesia on postoperative outcome the most relevant comparison is that between control group and those patients who had a functioning epidural block for 72 h. They say that because those patients in whom the catheter was removed earlier than this were not excluded, “the intention-to-treat analysis is thus significantly distorted.” This interpretation of the concept of intention-to-treat analysis is wrong. Postoperative epidural management in the trial was consistent with typical clinical practice across the large number of institutions involved. Where epidural analgesia was ceased before 72 h, this took place for a wide variety of reasons consistent with sound clinical practice as listed in Table 2 of our original publication

(1). This is consistent with anesthetic practice in most parts of the world. It should be noted, for example, that the commonest morbid endpoint in our trial was sepsis, occurring in 45% of our high-risk patients across the trial—many anesthesiologists would remove an epidural catheter in these circumstances. Our mean duration of epidural analgesia was 74 h. The occurrence of inadequate analgesia and the attrition rate for epidural duration in the trial are consistent with the published experience of other large observational studies of the use of epidural analgesia (2,3), and so, as was our objective, it reflects routine clinical practice.

Distortion in interpretation of results from a trial can occur, however, where data are manipulated in *variance* to the intention to treat analysis. Attempts to stratify patients according to duration of epidural catheterization, as suggested by Gogarten et al., are a good example. Selecting only those patients in whom an epidural infusion was continuing at 72 h immediately introduces serious survivor bias into the comparison with the control group (for instance, those who die within 72 h of surgery do not have the opportunity of receiving 72 h of epidural analgesia). We rejected this approach early in our examination of our findings, especially since a quarter of deaths in the trial occurred in the first 48 h postoperatively. However even if these early deaths are excluded there is still no trend in favor of improved survival in the epidural group (deaths after 48 h:14 in control group, 18 in epidural group).

Philip J. Peyton
Paul S. Myles
John A. Rigg
Konrad Jamrozik
Brendan S. Silbert
Richard Parsons
Karen Collins

Department of Anesthesia
Austin & Repatriation Medical Centre
Melbourne, Australia

References

1. Rigg JRA, Jamrozik K, Myles PS, et al. Epidural anesthesia and analgesia and outcome of major surgery: a randomized trial. *Lancet* 2002;359:1276–82.
2. Liu S, Allen H, Olsson G. Patient-controlled epidural analgesia with bupivacaine and fentanyl on hospital wards. Prospective experience with 1030 surgical patients. *Anesthesiology* 1998;88:688–95.
3. Scott D, Beilby D, McClymont C. Postoperative analgesia using epidural infusions of fentanyl with bupivacaine. A prospective analysis of 1014 patients. *Anesthesiology* 1995;83:727–37.

It's a Disposable LMA, Just Cut It Shorter— for Fiberoptic Intubation

To the Editor:

For a difficult airway, the laryngeal mask is a conduit for fiberoptic endotracheal intubation (1). Users of this technique have recognized that the LMA is too long, or the ETT too short to ensure that the inflated ETT cuff will lie below the vocal cords (2). Substituting a longer nasal RAE tube (NRT) for the standard ETT gains depth (3) but then the fiberoptic bronchoscope (FOB) may be held too far back to reach the vocal cords, then, 2 cm cut from the proximal end of the NRT allows the FOB to reach the trachea (4).

We suggest that the disposable LMA can be improved for fiberoptic intubation by shortening the shaft, we found the optimum distance to be equal in centimeters to the model size number of the LMA (i.e., 5 cm for size 5 LMA, etc.). Since it is stiffer than the reusable LMA, the disposable LMA retains greater maneuverability. This is relevant in cases where there is restricted access and the handle of an intubating LMA may be an obstruction.

During an emergent pediatric intubation I.O. cut the shaft of a classic LMA to suit the child and found that it eased bronchoscope movement and passage of an endotracheal tube. She removed the LMA before proceeding with the case. Similar modifications in other difficult airway cases have confirmed this initial impression, and one case is briefly described here.

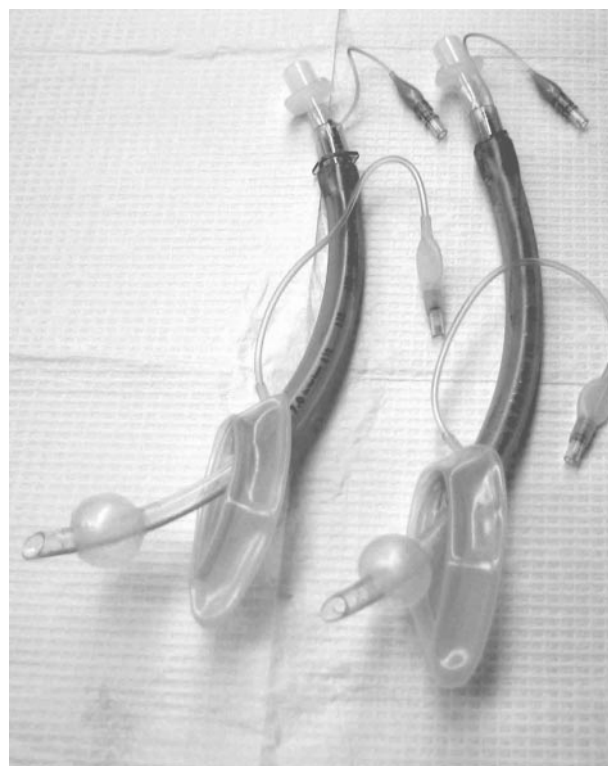


Figure 1. Fiberoptic examination and endotracheal tube placement through the laryngeal mask airway (LMA) is assisted by shortening the LMA tube.

A 63-year-old man with lung cancer was undergoing stereotactic brain biopsy. A head frame placed under local anesthesia included a transverse bar at the level of the nasal tip. This restricted airway access and mobility and intubation was expected to be difficult.

Before induction a disposable size #5 LMA was prepared by cutting 5 cm off the circuit end of the shaft and transferring the adapter to the new end (Fig.1). The LMA was inserted and the patient was easily ventilated four breaths preoxygenation before the fiberoptic bronchoscope with ET tube was entered. It was possible to visualize the position of the LMA in the larynx and the path of the endotracheal tube as it exited the LMA shaft through the vocal cords into the trachea. When in place, the ETT cuff was inflated and was seen to be clearly below the vocal cords. The bronchoscope was removed and the LMA was deflated and left in place throughout the neurosurgical procedure and was later used to assist in maintaining an airway during extubation.

This letter draws attention to what is an occasionally useful modification of the instrument in these particular and limited circumstances; it is not a modification recommended by the manufacturer. However, in North America this year, the disposable LMA has gained acceptance and has been added to emergency anesthesia carts, thus the procedure-related modification of the disposable LMA that is described here may have wide applicability, but will be limited to the single use of this disposable instrument.

Irene P. Osborn, MD
Robert Soper, MD
Department of Anesthesiology
Mount Sinai Medical Center
New York, NY

Dr Irene Osborn has been a consultant to the Laryngeal Mask Airway Company.

References

1. Benumof JL. Laryngeal mask airway and the ASA difficult airway algorithm. *Anesthesiology* 1996;84:686-99.
2. Asai T, Latto IP, Vaughan RS. The distance between the grill of the laryngeal mask airway and the vocal cords: is conventional intubation through the laryngeal mask safe? *Anesthesia* 1997;52:131-5.
3. Alfery DD. The laryngeal mask airway and the ASA difficult airway algorithm [letter]. *Anesthesiology* 1996;85:685.
4. Benumof JL. A new technique of fiberoptic intubation through a standard LMA. *Anesthesiology* 2001;95:1541.

DOI: 10.1213/01.ANE.0000067921.62656.B7

Remifentanyl Manual Versus Target-Controlled Infusion

To the Editor:

De Castro et al. (1) compared manual and target-controlled infusions (TCI) of remifentanyl in patients undergoing carotid endarterectomy. Unfortunately, their studies design may have prejudiced its outcome.

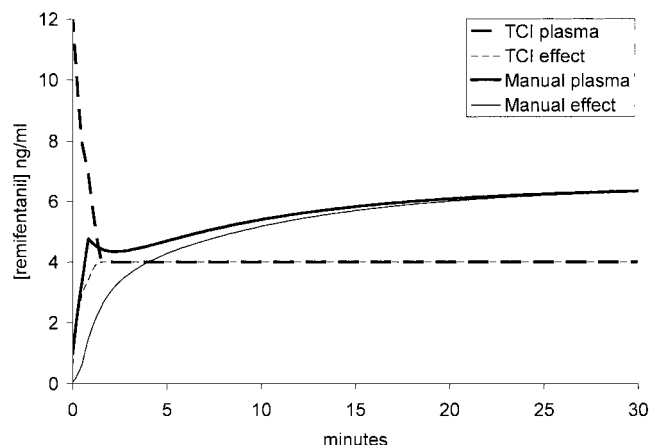


Figure 1. Simulation of the plasma and effect site concentrations achieved in the manual and target-controlled infusion groups. Note that in the absence of titrations the manual infusions achieve much higher concentrations from 4 min onward.

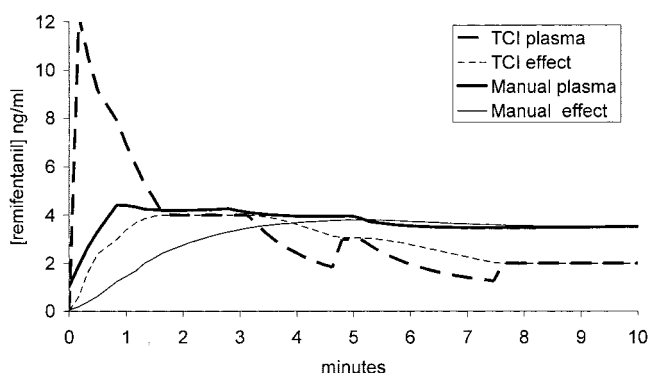


Figure 2. Simulation of the plasma and effect site concentrations achieved in the manual and target-controlled infusion groups; in each scheme two incremental decreases have been made at around 3 and 5 min. Note that the manual infusions achieve much higher concentrations from 4 min onward.

The manual and TCI schemes are not comparable; in particular, the titration steps in the manual scheme ($0.05 \mu\text{g} \cdot \text{kg}^{-1} \cdot \text{min}^{-1}$) were very small. Clearly TCI and manual schemes can never be the same but some prestudy simulations might have improved the study design. Simulations of their protocol using either no titrations (Fig. 1) or two downward titrations (Fig. 2) show that in each case the predicted remifentanyl concentrations are much higher in the manual scheme. This is reflected in the results with almost twice as much remifentanyl given to patients in the manually infused group. In light of this differential dosing, the finding of less hypotension with TCI is hardly surprising. The authors have demonstrated that remifentanyl causes dose-related hypotension in elderly arteriopathies. A less misleading title for the study might be "Reduce the dose of remifentanyl to minimize hypotension in the elderly"! TCI is a valuable and well-established technique for propofol anesthesia. Remifentanyl is simple to use and well suited to manual infusion schemes and the case for the Remifusor remains unproven. If remifentanyl TCI has a real clinical advantage then it must be demonstrated in more even-handed comparisons.

J. Robert Sneyd, MD

Peninsula Medical School
Plymouth, United Kingdom

Reference

1. De Castro V, Godet G, Mencia M, et al. Target-controlled infusion for remifentanyl in vascular patients improves hemodynamics and decreases remifentanyl requirement. *Anesth Analg* 2003;96:33-8.

DOI: 10.1213/01.ANE.0000074534.52751.C5

In Response:

We thank Dr. Sneyd for his interest and comments concerning the paper about TCI for remifentanyl in patients undergoing carotid endarterectomy.

To summarize his comments, remifentanyl should be reduced to minimize hypotension in the elderly (and arteriopathy). We do agree with this known statement, but should it be achieved blindly or in a more accurate way? We supposed TCI for remifentanyl could be an useful tool to minimize hemodynamic events related to drug administration by reducing dosing and smoothing its administration compared with manual infusion. The administration modalities used in the manual infusion group were in accordance with the laboratory's specifications and classical administration schemes. In order to make groups comparable at the induction of anesthesia, the effect-site concentration was fixed at 4 ng/mL in the TCI group, a concentration also achieved in the manual infusion group in the delay close to tracheal intubation, as shown in Figure 1 in Dr. Sneyd's letter. Then it should be kept in mind that adaptation of infusion is focused on the *common objective* of hemodynamic stability within 30% range of the patient's preoperative values of blood pressure and heart rate in both groups. Once this clinical effect is defined, the adequate drug concentration to achieve this effect should be the lowest, and the best administration modality the one that permits the finest adaptation. As mentioned and shown in Figure 2 in Dr. Sneyd's letter, the titration steps in the manual scheme are very small. The purpose was to adapt smoothly manual infusion to the patient's requirement like TCI does, even if it requires surely more than two adjustments. Dr. Sneyd also implicitly extrapolates the observation of higher concentrations of remifentanyl in the manual infusion group compared with TCI within the short period of induction to explain our result in total dose consumption of remifentanyl between groups. Even if it is convenient, this does not explain our result reflecting many adaptations of infusion (decrease but also increase) in both groups within the approximately 2 h of anesthesia. Certainly TCI should be improved, and its clinical impact compared with manual infusion remains to be evaluated, but we should not minimize its importance for elderly patients.

Victor De Castro, MD

Gilles Godet, MD

Department of Anesthesiology
Pitié-Salpêtrière Hospital
Paris, France

Tracheal Tube Advancement Over the Fiberoptic Bronchoscope: Size Does Matter

To the Editor:

We read with interest the article describing the use of a sleeve to facilitate tracheal tube advancement over the fiberoptic bronchoscope (1). Ayoub et al. used 7.5- and 8.0-mm ID tracheal tubes over a 3.8-mm OD bronchoscope, creating a huge gap in between. To obliterate this gap, Ayoub et al. used a sleeve to provide added thickness to the insertion cord.

The problem of tracheal tube “hang up” can be totally aborted, or at least its incidence extremely minimized, by properly matching the fiberscope and the tracheal tube sizes from the start. This obviates the need for use of additional devices that may be associated with potential problems. The sleeve described by the authors can be dislodged into the airway, especially if the bronchoscope is well lubricated, which is usually the case. Dislodgement of the sleeve beyond the lens can also lead to sudden loss of the view and make further visualization impossible unless an assistant pulls the sleeve back and holds it in position. In order to prevent dislodgement of the sleeve, the authors used a silk tie. If this tie becomes loose during the procedure, the sleeve can still be dislodged and if the tie is too tight it can damage the light bundles, the suction channel or the bending control wires. The manipulation of the insertion cord with the sleeve added to it may become more difficult through the curves of the airway than when using the insertion cord alone. Finally, poor lubrication between the sleeve and the scope can lead to intussusception of the outer plastic cover of the bronchoscope upon trying to remove the sleeve at the end of the procedure (2).

We should not abrogate the principles of good fiberoptic technique. With adequate preparation of the tracheal tube and choosing the largest scope in which the tube can easily fit, this problem should rarely be encountered. When it does occur, pulling the tube back and gently rotating it 90 degrees counterclockwise before readvancing will allow easy passage in almost all of the patients, as Schwartz et al. (3) reported, without the need to use any additional devices.

Mohammed I. El-Orbany, MD
M. Ramez Salem, MD
Ninos J. Joseph, BS
*Department of Anesthesiology
Advocate Illinois Masonic Medical Center
Chicago, Illinois*

References

1. Ayoub CM, Rizk MS, Yaacoub CI, et al. Advancing the tracheal tube over a flexible fiberoptic bronchoscope by a sleeve mounted on the insertion cord. *Anesth Analg* 2003;96:290–2.
2. Ovassapian A, Wheeler M. Fiberoptic endoscopy-aided techniques. In: Benumof JL, ed. *Airway management: principles and practice*. St. Louis: Mosby-Yearbook, 1996:310.
3. Schwartz D, Johnson C, Roberts J. A maneuver to facilitate flexible fiberoptic intubation. *Anesthesiology* 1989;71:470–1.

DOI: 10.1213/01.ANE.0000074536.41918.BB

In Response:

Thank you for referring to us the letter by El-Orbany et al. concerning our report “advancing the tracheal tube over a flexible fiberoptic bronchoscope by a sleeve mounted on the insertion cord” (1).

As they mentioned in their letter “with adequate preparation of the tracheal tube and choosing the largest scope in which the tube can easily fit, this problem should rarely be encountered. When it does occur, pulling the tube back and gently rotating 90 degrees counterclockwise before readvancing will allow easy passage in almost all of the patients, as Schwartz et al. (2) reported without the need to use any additional devices. However, in our department as well as in many other institutions all over the world, the 3.8-mm fiberoptic bronchoscope may be the only available size, and hence advancing the endotracheal tube may fail despite the 90-degree counterclockwise rotation. In this situation, advancing of the endotracheal tube into the trachea can be facilitated by other maneuvers such as the double setup endotracheal tube proposed by Rosenblatt (3), or as suggested in our report, by mounting a conical sleeve over

the insertion cord of the fiberoptic bronchoscope; the dislodgement of the sleeve is prevented by the proximal tight silk tie (1). The presence of the sleeve centralizes the tube in front of the glottis and decreases the likelihood of impingement on the arytenoids, which facilitates advancement of the endotracheal tube into the trachea.

Chakib M. Ayoub, MD
Marwan S. Rizk, MD
Chadi I. Yaacoub, MD
Anis S. Baraka, MD
Antoine M. Lteif, MD
*Department of Anesthesiology
American University of Beirut Medical Center
Beirut, Lebanon*

References

1. Ayoub CM, Rizk MS, Yaacoub CI, et al. Advancing the tracheal tube over a flexible fiberoptic bronchoscope by a sleeve mounted on the insertion cord. *Anesth Analg* 2003;96:290–2.
2. Schwartz D, Johnson C, Roberts J. A maneuver to facilitate flexible fiberoptic intubation. *Anesthesiology* 1989;71:470–1.
3. Rosenblatt WH. Overcoming obstruction during bronchoscope-guided intubation of the trachea with the double setup endotracheal tube. *Anesth Analg* 1996;83:175–7.

Propofol Reduces Idiopathic Prolonged QT Interval and QT Dispersion During Implantation of Cardioverter Defibrillator

To the Editor:

We have read with interest the recent publication by Weinbroum et al. (1), which demonstrates that halothane, isoflurane, and fentanyl increase the defibrillation energy thresholds, compared with subcutaneous lidocaine plus intermittent small dose IV propofol that minimized these thresholds, during the implantation of cardioverter defibrillator in humans.

However, we would like to draw the authors' attention to the statement, which refers to our report (2). In their discussion they quote: “Interestingly, although propofol may cause the prolongation of the QT interval during the implantation of an ICD—an event that did not occur in our study—this has not kept the drug from gaining the reputation as being safe for this procedure, even in patients with severe left ventricular dysfunction.”

Our report clearly indicates (see Results) that propofol decreases the QT interval and QT dispersion in patients with idiopathic prolonged QT interval and QT dispersion.

Furthermore, we conclude that: “propofol combined with local analgesics may be a safe alternative technique for patients with idiopathic prolonged QT interval and QT dispersion” (2).

Our decision to use midazolam as premedication and propofol for conscious sedation was influenced by our reported results on healthy ASA I-II patients that showed that neither midazolam nor propofol had any significant effect on QTc interval (3).

D. Michaloudis, MD
Department of Anesthesiology
E. Kanoupakis, MD, FESC
*Department of Cardiology
University Hospital
Iraklion, Crete, Greece*

References

1. Weinbroum AA, Glick A, Copperman Y, et al. Halothane, isoflurane, and fentanyl increase the minimally effective defibrillation threshold of an implantable cardioverter defibrillator: first report in humans. *Anesth Analg* 2002;95:1147–53.
2. Michaloudis D, Fridakis O, Kanoupakis E, et al. Idiopathic prolonged QT interval and QT dispersion: the effects of propofol during implantation of cardioverter-defibrillator. *Eur J Anaesth* 1999;16:842–7.
3. Michaloudis DG, Kanakoudis FS, Petrou AM, et al. The effects of midazolam or propofol followed by suxamethonium on the QT interval in humans. *Eur J Anaesth* 1996;13:364–8.

DOI: 10.1213/01.ANE.0000074532.84043.27

In Response:

We thank Drs. Michaloudis and Kanoupakis for their comments on our manuscript (1). In this study, we had prospectively compared the effects of three general anesthetics and the combination of local anesthesia plus propofol on the minimal energy requirement of an implantable cardioverter defibrillator (ICD) during its insertion. It was not our intention to examine the effect of propofol on the QT interval; rather, we cited the two cases that were reported by Michaloudis et al. (2), in which they demonstrated that the QT interval may be shortened after the administration of propofol. On the basis of the findings they describe in this case report, the differences in the QTc appear not to be of significant value. We believe that their report as well as those of others contribute to the validation of our conclusion that propofol is safe even in patients with severe cardiac dysfunction and electrophysiological disturbances. The results and conclusion of our study, that propofol was a safe and an applicable mode of anesthesia for a group of high-risk patients requiring the implantation of ICD, were the same as theirs (2).

Avi A. Weinbroum, MD

Ron Flaishon, MD

Department of Anesthesia and Critical Care
Tel Aviv Sourasky Medical Center
Tel Aviv, Israel

References

- Weinbroum AA, Glick A, Copperman Y, et al. Halothane isoflurane and fentanyl increase the minimally effective defibrillation threshold of an implantable defibrillator: first report in humans. *Anesth Analg* 2002;95:1147-53.
- Michaloudis D, Fraidakis O, Kanoupakis E, et al. Idiopathic prolonged QT interval and QT dispersion: the effect of propofol during implantation of cardioverter-defibrillator. *Eur J Anaesth* 1999;16:842-7.

Nebulization of Lidocaine with Varied Oxygen Flow Rates

To the Editor:

The delivery of lidocaine via small-volume nebulizers (SVN) can be used as topical anesthesia for use during flexible bronchoscopy in infants and children. Although the SVN is small and easy to use, the rate of nebulization at different gas flow rates is not well known. Since the total amount of nebulized lidocaine delivered to pediatric patients in relation to time and flow rates is important to prevent lidocaine toxicity (1), we recently conducted an *in vitro* study that evaluated the rate of nebulization of lidocaine with differential oxygen flow rates.

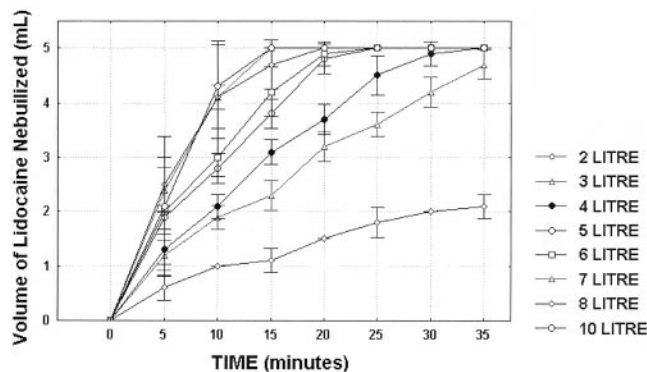


Figure 1. Rate of nebulization of lidocaine with varied oxygen flow rates.

Five SVNs (Misty-Neb Nebulizer, Allegiance, IL) were studied. Each SVN was filled with 5 mL of 4% lidocaine and connected to a pediatric facemask. The SVN was connected to the dispensing oxygen at flow rates of 2, 3, 4, 5, 6, 7, 8, and 10 L/min, respectively. The dispensing oxygen was temporarily stopped at 5-min intervals and the lidocaine was allowed to settle in the SVN to measure the residual volume.

On the basis of the results of this study (Fig. 1), the amount of lidocaine nebulized at different oxygen flow rates and time periods can be estimated. This information may be used to limit the possible maximum lidocaine delivered to the patient by adjusting gas flow rates and reducing time exposure. Other brands of SVN may need separate calibration, as this study only examined one particular brand.

Ban Ch. Tsui, MD, MSC, FRCP(C)

Stephan Malherbe, MB, ChB, MMed, FCA(SA)

Department of Anesthesiology and Pain Medicine
University of Alberta Hospital
Edmonton, Alberta, Canada

Reference

- Wu F, Razzaghi A, Sournay PF. Seizure after lidocaine for bronchoscopy. *Pharmacotherapy* 1993;13: 72-8.

DOI: 10.1213/01.ANE.0000074540.87625.5F

An Endotracheal/Tracheostomy Tube Technique for the Emergency Management of a Midtracheal Tracheoesophageal Fistula

To the Editor:

Tracheoesophageal fistula corresponding to the sixth-to-eighth tracheal ring level was identified by fiberoptic inspection in a 34-yr-old male trauma patient with tracheostomy. Clinical manifestations were inspiratory gas-mixture leak commencing at airway pressure ≥ 20 cm H₂O (mechanical ventilation's inspiratory phase) and gastric inflation, leading to a vicious cycle of inspiratory airway pressure elevation, and gas-mixture leak and gastric distention aggravation. The indwelling nasogastric tube was removed (1), and as an adjustable-insertion depth tracheostomy tube (TT) was not readily available, emergency airway management was by original 9.0-mm inner diameter (ID) TT replacement by a 10.0-mm ID TT, through which a 6.0-mm ID endotracheal tube (ETT) cut down to 22 cm was already passed so that its cuff's proximal end was protruding from the TT's distal orifice (Fig. 1). Following ETT-cuff inflation (with TT-cuff maintained deflated), gas mixture-leak was abolished and patient's lungs were effectively ventilated. Two days later, following weaning from mechanical ventilation, the fistula was surgically corrected by esophageal closure, and segmental tracheal resection and reconstruction (1); intra- and postoperative management were according to recently published guidelines (2); patient recovery was uneventful. In conclusion, our TT/ETT technique may constitute an effective alternative for the emergency/temporary management of gross inspiratory gas-mixture-leak-associated tracheoesophageal fistulae in tracheostomized patients.

Spyros D. Mentzelopoulos, MD, DEAA

Argyris S. Michalopoulos, MD, FCCM

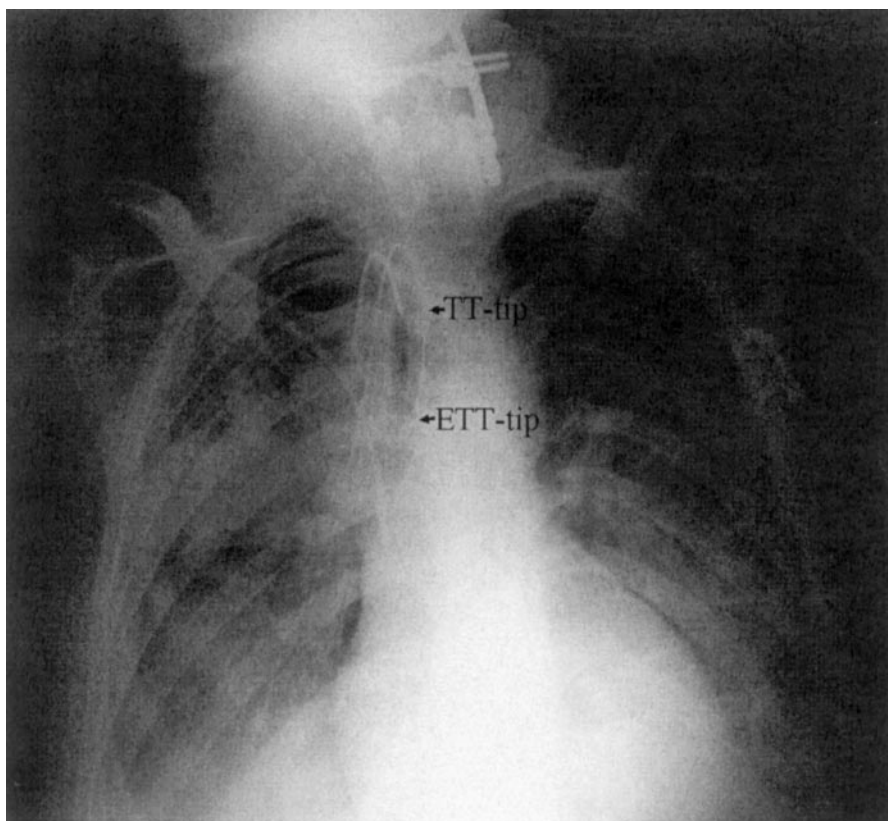
Department of Intensive Care Medicine
Henry Dynant General Hospital
Athens, Greece

References

- Dartavell P, Macchiarini P. Management of acquired tracheoesophageal fistula. *Chest Surg Clin N Am* 1996;6:819-36.
- Mentzelopoulos SD, Tzoufi MJ. Anesthesia for tracheal and endobronchial interventions. *Curr Opin Anaesthesiol* 2002;15:85-95.

DOI: 10.1213/01.ANE.0000074543.83384.24

Figure 1. Chest radiograph after placement of the 10.0-mm ID tracheostomy tube (TT)/6.0-mm ID endotracheal tube (ETT) airway device. The ETT tip is located just above the carina (as also confirmed by fiberoptic bronchoscopy). The lungs were effectively isolated after ETT-cuff inflation, because the tracheoesophageal fistula was located at the level of the TT tip.



Encourage the Use of Noncutting Needles for Diagnostic Lumbar Punctures

To the Editor:

I read with interest the article by Loughrey et al. (1) concerning spinal anesthesia after an epidural blood patch. Perhaps the use of 22-gauge cutting needles to perform diagnostic lumbar punctures (LPs) is another problem. Recently, I was surprised to learn that the nonanesthesiologist physicians doing diagnostic LPs at our hospital were not aware of the existence of noncutting needles and routinely used the 22-gauge Quincke needle supplied in the diagnostic LP kit. Although it takes a little longer to obtain the required amount of CSF using a smaller pencil-point needle, it will obviously result in a less frequent incidence of postdural puncture headache (PDPH) compared with the use of a 22-gauge cutting needle. We have updated our physicians on the advantages of noncutting needles and taped 24-gauge Sprotte needles to the top of our diagnostic LP kits. I would encourage anesthesiologists at other institutions where large cutting needles are used for diagnostic LPs to institute similar steps to reduce the incidence of PDPH after diagnostic LP.

Andrew Zimet, MD
North Valley Hospital
Whitefish, MT

Dr. Tsen does not wish to reply.

Reference

1. Loughrey J, Eappen S, Tsen L. Spinal anesthesia for cesarean delivery shortly after an epidural blood patch. *Anesth Analg* 2003;96:545-7.
- DOI: 10.1213/01.ANE.0000074544.61158.EA

Griggs Guide Wire Dilation Forceps Method Is Safer Than Suggested

To the Editor:

I have read the comparison single dilation technique percutaneous tracheostomy methods reported in your journal (1) and would like to make a couple of points concerning the Griggs guide wire dilation forceps (GWDF) method. The authors state that "overenthusiastic attempts at dilation using this method may result in overdistention or occult subtotal transection of the trachea," but do not reference this statement. In fact, we have undertaken just such an investigation (2) and believe the GWDF method to be safer than the authors suggest.

In a necessarily cadaveric study, we compared therapeutic dilation of the trachea with destructive dilation using the GWDF and found that the force to destroy the trachea was more than twice that required for a therapeutic dilation, giving a reasonable margin of safety. Moreover, we also measured the force required for dilation of the pretracheal tissues and found this to be more than that required for the therapeutic tracheal dilation. This therefore acts as a useful marker, in that dilation of the pretracheal tissue is performed first and the operator should then use less force for the subsequent therapeutic tracheal dilation.

Given that the instructions for use of the GWDF tell the operator to open the forceps 1.5 to 2 cm once in the trachea, we believe that the technique does provide a reasonable level of safety and that inadvertent destruction of the trachea is unlikely to happen if the correct technique is followed.

Malcolm Watters, MD
Consultant in Anaesthesia and Intensive Care Medicine
Great Western Hospital
Swindon, England

References

1. Ambesh S, Pandey C, Srivastava S, et al. Percutaneous tracheostomy with single dilatation technique: a prospective, randomized comparison of Ciaglia Blue Rhino versus Griggs' guidewire dilating forceps. *Anesth Analg* 2002;95:1739–45.
2. Watters M, Thorne G, Cox C, Monk C. Tracheal trauma from percutaneous tracheostomy using the Griggs method. *Anaesthesia* 2002;57:249–52.

DOI: 10.1213/01.ANE.0000074691.16768.3A

In Response:

We would like to thank Dr. Watters for his interest in our study (1) and for making couple of points concerning our questioned safety of Griggs guidewire dilating forceps (GWDF). Contrary to our findings, Dr. Watters, quoting his cadaver model study (2), has commented that use of GWDF is safer and is unlikely to cause inadvertent destruction of trachea.

We do not agree with his opinion. In our study, we performed percutaneous tracheostomy in 60 patients, 30 each with GWDF and Ciaglia Blue Rhino (CBR). Postprocedure endoscopy by a blinded operator revealed overdilation of tracheal stoma in seven patients in the GWDF group while no overdilation was seen in the CBR group. There was more overdilation with the more experienced operators and that was probably due to the overconfident or overenthusiastic attempt on stoma dilation. We have not cited any reference to support the overdilation of tracheal stoma with the GWDF, as it is the finding of our study (1). Although we agree with Dr. Watters

that dilation of pretracheal tissues requires comparatively less force than the force required to dilate the tracheal tissues, it is difficult to gauge the force required during clinical tracheal dilation, as it is a subjective phenomenon. Furthermore, it is difficult to know the exact extent of forceps opening (1.5–2 cm.) *in situ*, as it is not always possible to visualize stoma during its formation, especially in the patients with thick short neck who have abundance of pretracheal tissues and fat with deeply seated trachea. In conclusion, we would like to reiterate our remark that GWDF is associated with uncontrolled formation (under- or overdilation) of tracheal stoma, and one does not require a bad intention to cause overdilation of tracheal stoma with the GWDF.

Sushil P. Ambesh, MD

Chandra K. Pandey, MD

Anil Agarwal, MD

Department of Anaesthesiology

Sanjay Gandhi Postgraduate Institute of Medical Sciences

Lucknow, India

References

1. Ambesh SP, Pandey CK, Srivastava S, et al. Percutaneous tracheostomy with single dilatation technique: a prospective, randomized comparison of Ciaglia Blue Rhino versus Griggs' guidewire dilating forceps. *Anesth Analg* 2002;95:1739–45.
2. Watters M, Thorne G, Cox C, Monk C. Tracheal trauma from percutaneous tracheostomy using the Griggs method. *Anaesthesia* 2002;57:249–52.