Anterior Approach to the Sciatic Nerve Block: The Effects of Leg Rotation

Jerry D. Vloka, MD, PhD*, Admir Hadžić, MD, PhD*, Ernest April, PhD†, and Daniel M. Thys, MD*

*St. Luke's-Roosevelt Hospital Center, Columbia University College of Physicians and Surgeons, New York, New York; and †College of Physicians and Surgeons, Columbia University, New York, New York

In the anterior approach to the sciatic nerve block, the femur often obstructs the passage of the needle toward the sciatic nerve. In this study, by using a human cadaver model, we assessed how internal and external rotation of the leg influences the accessibility of the sciatic nerve with the anterior approach. Ten lower extremities from five adult cadavers were studied. Needles were used to simulate the anterior approach to the sciatic nerve block. The effect of leg rotation on the needle plane required to reach the sciatic nerve was studied with legs in the neutral position and then with internal and external rotation (45°) of the legs. During needle placement in the neutral position, the needle could not be fully advanced to the level of the sciatic nerve because of obstruction by the lesser trochanter in 80% of attempts. Medial redirection of the needle (10°–15°) allowed it to pass the lesser trochanter but brought the tip of the needle too medial to the sciatic nerve. Internal rotation of the leg facilitated passage of all needles inserted at the level of the lesser trochanter. We conclude that internal rotation of the leg may significantly facilitate needle insertion in the anterior approach to sciatic block.

(Anesth Analg 2001;92:460–2)

The anterior approach to the sciatic nerve block has several advantages over the posterior (1) or lithotomy (2) approaches. With the anterior approach, the block can be performed with the patient in the supine position, the limb need not be flexed (3,4), and both sciatic and femoral blocks can be placed with the patient in the same position (5). In the anterior approach, the needle is inserted through the anteromedial thigh, inferior to the inguinal ligament, and advanced posteriorly to the sciatic nerve sciatic nerve that lies directly behind the femur (Fig. 1). Ideally, the needle passes just medial to the femur and contacts the sciatic nerve. However, the needle often encounters the femur before reaching the sciatic nerve. Although the classical description of the block suggests that the needle simply should be "walked off" the bone in the event of needle-femur contact, this maneuver often results in displacement of the needle tip too medially and thus away from the nerve (4). Because rotation of the femoral shaft could change the configuration of the insertion plane required to reach the sciatic nerve, the purpose of this study was to determine whether internal and external rotation of the leg would improve the accessibility of the sciatic nerve by using the anterior approach.

Methods

We studied ten lower extremities from five adult cadavers. The cadavers had been embalmed for anatomical purposes with a solution of phenol (13%) as the principal fixative and glycerin (28%) to retain water content.

The cadavers were placed in the supine position with the lower extremity in the neutral position. The landmarks for the anterior approach to sciatic nerve block were drawn according to the classic description by Beck (3) (Fig. 1). Three lines were drawn: an inguinal ligament line between the anterio-superior iliac spine and the pubic tubercle (inguinal ligament), a transtrochanteric line that passed through the greater trochanter (identified by dissection) and parallel to the inguinal ligament, and a transecting line perpendicular to the inguinal ligament that passed through the intersection of the medial one third and the lateral two thirds of the inguinal ligament line. The transecting line was extended caudally, and the needle insertion

Accepted for publication October 24, 2000.

Address correspondence and reprint requests to Admir Hadžić, MD, PhD, Department of Anesthesiology, St. Luke's-Roosevelt Hospital Center, 1111 Amsterdam Avenue, New York, NY 10025. Address e-mail to ah149@columbia.edu.

0003-2999/01

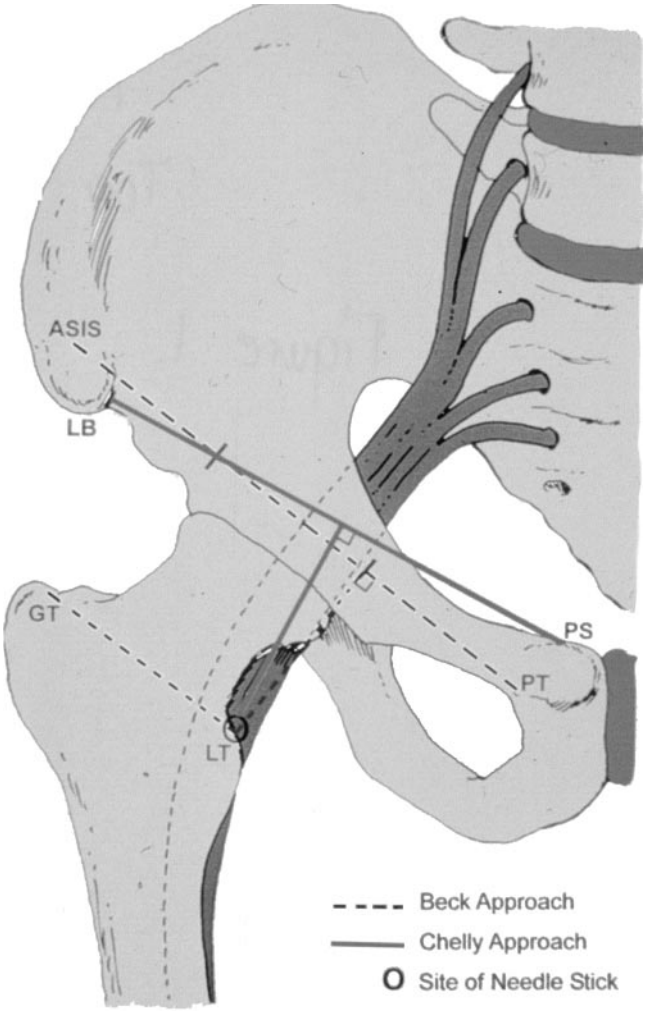

Figure 1. Anterior approach to sciatic nerve block: a diagram with landmarks. ASIS = anterior superior iliac spine; PT = pubic tubercle; PS = pubic spine; GT = greater trochanter; LT = minor (lesser) trochanter.

site was marked on the anterior thigh at the intersection of the transecting line and transtrochanteric lines. Needles (16-gauge, 15 cm long) were inserted at this site perpendicular to the horizontal plane until the needles either exited the posterior thigh or could not be advanced because of contact with the femur. The posterior thigh was then dissected to expose the sciatic nerve and to determine the number of needle-sciatic nerve and needle-bone contacts.

After exposing the sciatic nerve, the effect of leg rotation on the needle plane required to reach the sciatic nerve through the anterior approach was studied. Needles (16-gauge, 15 cm long) were inserted through the center of the exposed sciatic nerve and advanced in the posterior-anterior direction in the parasagittal plane until the needle tips exited the marked insertion site on the anterior thigh or encountered the femur (Fig. 2). This simulation of the needle path by using the anterior approach to sciatic nerve

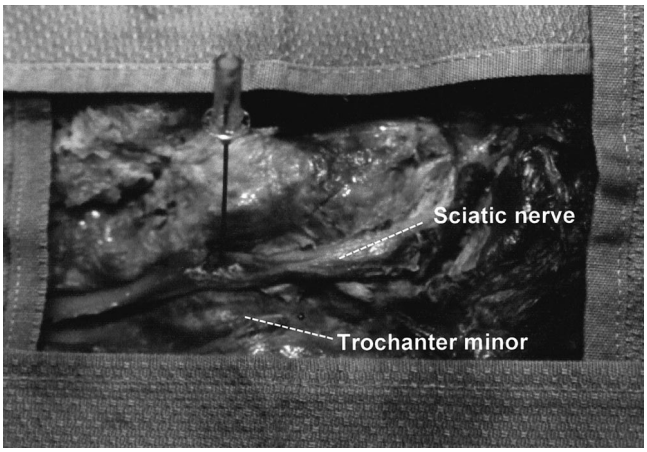

Figure 2. The needle is shown inserted retrogradely (posterior-anterior) through the sciatic nerve to demonstrate the insertion plane in the anterior approach to sciatic nerve block.

block was performed first at the level of the lesser trochanter. The needles were inserted in a retrograde direction (i.e., posterior to anterior) in a parasagittal plane to determine the part of the femur causing obstruction to the needle path. The insertions were first done with the feet forming a 90° angle to the horizontal plane, and then they were repeated with the feet rotated 45° internal and then 45° external in relation to the sagittal plane. The same experiment was then repeated but with insertion of the needles at a level 2 cm distal to the lesser trochanter. The number of needle-bone contacts and successful needle passes were recorded at each leg rotation.

Results

The majority of needles (80%) inserted anterior-posteriorly through the classic insertion point for sciatic nerve B contacted the lesser trochanter on the first attempt. Similarly, 80% of needles inserted through the center of the sciatic nerve in the posterior-anterior direction at the level of the lesser trochanter (with the foot forming a 90° angle to the horizontal plane) could not be advanced in the parasagittal plane toward the anterior thigh. This is because the bony prominence of the lesser trochanter intercepted the passage of the needle in both directions. Upon contacting the femur through Beck's insertion point (3), medial redirection of the needle allowed it to pass by the lesser trochanter but brought the tip of the needle too medially to the sciatic nerve and closer to the femoral artery. Consequently, none of the medial reinsertions of the needle resulted in needle-sciatic nerve contact.

The internal rotation of the leg by 45° facilitated passage of the needle inserted at the level of the lesser trochanter by opening the insertion plane, resulting in needle-nerve intersection in all 10 legs (100%). However, the external rotation resulted in contact with the

femur and prevented needle-nerve contact in all insertions (100%).

In contrast to the insertion at the lesser trochanter, needles inserted at the level 2 cm inferior to the lesser trochanter encountered the femur in 40% of cases in the neutral position. At this level, the internal rotation of the leg by 45° had an entirely opposite effect and obstructed passage of the needle in all but one leg (90%), whereas external rotation facilitated needle passage and resulted in needle-nerve contact in all legs (100%).

Discussion

Using a cadaver model, we confirmed the clinical impression that in the anterior approach to sciatic nerve block, the femur often obstructs the path of the needle. However, "walking off" the femur, as the classic description of anterior approach to sciatic nerve block by Beck (3) suggests, results in the needle tip being too medial to and away from the sciatic nerve. Thus, progressive medial reinsertion of the needle with slight lateral angulation is usually required to reach the sciatic nerve behind the femur. Unfortunately, multiple attempts and medial reinsertion of the block needle increases the risk of puncturing the femoral nerve, femoral artery, or both. Because of this, the anterior approach may be less desirable in patients with peripheral vascular disease or those treated with anticoagulants—the very patients in whom this block can have important advantages over neuraxial anesthesia.

Our study demonstrates that during needle advancement with the anterior approach to sciatic nerve block (anterior to posterior in the sagittal plane), the path of the needle is often obstructed by the lesser trochanter. However, slight withdrawal of the needle from its position where it contacts the femur, followed by internal rotation of the leg and reinsertion of the needle in the same plane, facilitates the needle passage toward the sciatic nerve. This finding has been confirmed in a clinical study by Chelly and Delauney (4). When internal rotation fails to facilitate further advancement of the needle, external rotation should be attempted because the needle may erroneously be inserted below the lesser trochanter, in which case the rotation has entirely the opposite effect. In this situation, the external rotation of the medial ridge of the trianglelike profile of the femoral shaft swings the ridge antero-laterally and opens the plane required for the block needle to pass medially to the femur. If these maneuvers fail, progressively more medial insertions should be attempted.

The identification of the greater trochanter in this study was done by dissection, because its identification is difficult to perform on embalmed cadavers. Although this may somewhat limit the clinical applicability of these findings, we believe that our landmarks were sufficiently close to those obtained by palpation in patients. Furthermore, our preliminary clinical data are in agreement with the anatomical findings.

In conclusion, if our results are applicable to clinical practice, the lesser trochanter often obstructs the path of the needle to the sciatic nerve in the anterior approach to sciatic nerve block. In this case, slight withdrawal followed by reinsertion of the needle in the same plane after internal rotation of the leg by 45° may significantly facilitate passage of the needle toward the sciatic nerve. When this is unsuccessful, our results further suggest that external rotation can also be helpful when the needle is erroneously inserted below the lesser trochanter, as may occur in patients with more obscure landmarks.

The authors thank Alan Santos, MD, for his editorial remarks and Drs. Chelly and Delauney for their kind contribution of anterior approach to sciatic nerve block diagram for this publication.

References

1. Labat G. Regional anesthesia: its technique and clinical applications. 2nd ed. Philadelphia: WB Saunders, 1928:45–55.
2. Raj PP, Parks RI, Watson TD, Jenkins MT. A new single-position supine approach to sciatic-femoral nerve block. Anesth Analg 1975;54:489–93.
3. Beck GP. Anterior approach to sciatic nerve block. Anesthesiology 1963;24:222–4.
4. Chelly JE, Delauney L. A new anterior approach to the sciatic nerve block. Anesthesiology 1999;91:1655–60.
5. Vloka JD, Hadžić A, Drobnik L, et al. Anatomical landmarks for femoral nerve block: a comparison of four needle insertion sites. Anesth Analg 1999;89:1467–70.