

Piriformis Syndrome

Anatomic Considerations, a New Injection Technique, and a Review of the Literature

Honorio T. Benzon, M.D.,* Jeffrey A. Katz, M.D.,† Hubert A. Benzon, B.A.,‡ Muhammad S. Iqbal, M.D.§

Background: Piriformis syndrome can be caused by anatomic abnormalities. The treatments of piriformis syndrome include the injection of steroid into the piriformis muscle and near the area of the sciatic nerve. These techniques use either fluoroscopy and muscle electromyography to identify the piriformis muscle or a nerve stimulator to stimulate the sciatic nerve.

Methods: The authors performed a cadaver study and noted anatomic variations of the piriformis muscle and sciatic nerve. To standardize their technique of injection, they also noted the distance from the lower border of the sacroiliac joint (SIJ) to the sciatic nerve. They retrospectively reviewed the charts of 19 patients who had received piriformis muscle injections, noting the site of needle insertion in terms of the distance from the lower border of the SIJ and the depth of needle insertion at which the motor response of the foot was elicited. The authors tabulated the response of the patients to the injection, any associated diagnoses, and previous treatments that these patients had before the injection. Finally, they reviewed the literature on piriformis syndrome, a rare cause of buttock pain and sciatica.

Results: In the cadavers, the distance from the lower border of the SIJ to the sciatic nerve was 2.9 ± 0.6 (1.8–3.7) cm laterally and 0.7 ± 0.7 (0.0–2.5) cm caudally. In 65 specimens, the sciatic nerve passed anterior and inferior to the piriformis. In one specimen, the muscle was bipartite and the two components of the sciatic nerve were separate, with the tibial nerve passing below the piriformis and the peroneal nerve passing between the two components of the muscle. In the patients who received the injections, the site of needle insertion was 1.5 ± 0.8 (0.4–3.0) cm lateral and 1.2 ± 0.6 (0.5–2.0) cm caudal to the lower border of the SIJ as seen on fluoroscopy. The needle was inserted at a depth of 9.2 ± 1.5 (7.5–13.0) cm to stimulate the sciatic nerve. Patients had comorbid etiologies including herniated disc, failed back surgery syndrome, spinal stenosis, facet syndrome, SIJ dysfunction, and complex regional pain syndrome. Sixteen of the 19 patients responded to the injection, their improvements ranged from a few hours to 3 months.

Conclusions: Anatomic abnormalities causing piriformis syndrome are rare. The technique used in the current study was successful in injecting the medications near the area of the sciatic nerve and into the piriformis muscle.

PIRIFORMIS syndrome is an uncommon and often undiagnosed cause of buttock and leg pain.¹⁻⁴ It may be caused by anatomic abnormalities of the piriformis muscle and the sciatic nerve resulting in irritation of the sciatic nerve by the piriformis muscle. Indeed, case reports of the syndrome secondary to anomalies of the piriformis muscle have been described.^{5,6}

The management of piriformis syndrome includes injection of the piriformis muscle with local anesthetic and steroid⁷⁻⁹ or with botulinum toxin.¹⁰ Some investigators also inject dilute local anesthetic and steroid in the area of the sciatic nerve.^{7,8} Whereas the older techniques of injection were done blindly,^{1,2} newer techniques involved the use of muscle electromyography⁹ or computed tomography (CT)¹⁰ to identify the piriformis muscle, and the use of a nerve stimulator to identify the sciatic nerve.^{7,8} A wider application of these techniques is hindered by the lack of ready availability of muscle electromyography and CT in most pain clinics.

In this article, we present the results of our anatomic dissections that are relevant to the etiology of piriformis syndrome and to the technique of piriformis muscle injection. We describe our technique of fluoroscopy-guided and nerve stimulator-guided injection of the sciatic nerve and the piriformis muscle based on our anatomy findings. Our technique of injection uses landmarks and equipment that are familiar to the anesthesiologist and ensure adequate placement. We present our initial clinical results, and also review the etiology, clinical manifestations, and management of piriformis syndrome.

Materials and Methods

Anatomy Cadaver Study

We examined the anatomic relationships of the sciatic nerve, piriformis muscle, and sacroiliac joint (SIJ) in 36 cadavers. Specifically, we looked at anatomic abnormalities of the piriformis muscle and the sciatic nerve, the distance from the lower border of the SIJ to the sciatic nerve, and the width of the sciatic nerve at its widest diameter. Both the right and left sides were studied if the area was adequately exposed for our study.

Retrospective Review of the Injection Technique

We retrospectively reviewed the charts of 19 patients who received the injection between October 2001 and September 2002. The first three patients received the injections before our cadaver study, whereas the remain-

* Professor of Anesthesiology and Chief, Division of Pain Medicine, † Associate Professor of Anesthesiology, ‡ Medical Student, Northwestern University Feinberg School of Medicine, § Fellow, Division of Pain Medicine, Department of Anesthesiology, Northwestern University Feinberg School of Medicine, Chicago, Illinois.

Received from the Department of Anesthesiology, Northwestern University Feinberg School of Medicine, Chicago, Illinois. Submitted for publication October 15, 2002. Accepted for publication January 13, 2003. Support was provided solely from institutional and/or departmental sources. Portions of this work have been presented at the annual meeting of the American Society of Anesthesiologists, Orlando, Florida, October 14–16, 2002.

Address reprint requests to Dr. Benzon: Department of Anesthesiology, Northwestern University Feinberg School of Medicine, 251 East Huron Street, Feinberg Pavilion, Suite 5-704, Chicago, Illinois 60611. Address electronic mail to: hbenzon@nmff.org. Individual reprints may be purchased through the Journal Web site, www.anesthesiology.org.

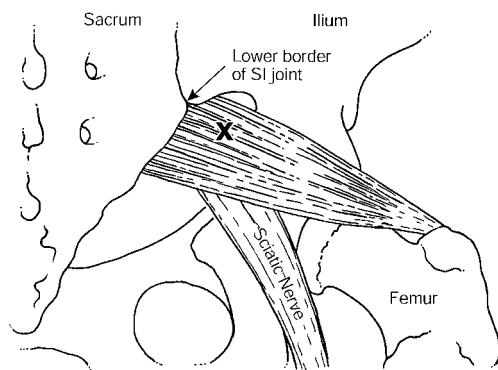


Fig. 1. Posterior view of the sacrum, ilium, and greater trochanter of the femur, showing the course of the piriformis muscle, sciatic nerve, and site of injection (X).

ing patients had their injections after the study was conducted. We noted the site of needle insertion in terms of the distance (lateral and caudal) from the lower border of the SIJ, the depth of needle insertion at which the motor response of the foot is elicited, the stimulus intensity needed to stimulate the sciatic nerve, and the evoked response of the foot. The Institutional Review Board of Northwestern University approved the study, which consisted of our technique of injection and the clinical response of the patients. Written informed consent for the procedure was obtained from every patient.

We selected the lower border of the SIJ as our reference point because of its anatomical relationship to the piriformis muscle and the sciatic nerve and its ease of visualization on fluoroscopy. The lower border of the SIJ is very familiar to pain management practitioners, because it is the most common site of injection in patients with SIJ dysfunction. The piriformis muscle is located in the greater sciatic foramen between the sacrum, SIJ, and the femur. The inferior border of the SIJ is located approximately at the level of S3 vertebra, or between the S2 and S3 vertebrae,¹¹ and the sciatic nerve is inferior to the piriformis muscle. The sciatic nerve and the piriformis muscle can therefore be reached by inserting the needle in the greater sciatic foramen, lateral and caudal to the lower border of the SIJ.

Before our cadaver study, we arbitrarily selected a site 1 cm lateral and 1 cm caudal to the lower border of the SIJ as the insertion point of the needle. We moved the needle laterally if the sciatic nerve was not located at a depth of 13 cm. After our cadaver study, which showed a more lateral location of the sciatic nerve in relation to the SIJ, we inserted our needle 2 cm lateral and 1 cm caudal to the SIJ. The patient is prone, the buttock area is prepped and draped, and the SIJ is identified by fluoroscopy. After local anesthetic infiltration, a 15-cm insulated needle, connected to a nerve stimulator, is inserted and advanced until a motor response of the foot is elicited (fig. 1). An evoked response of the foot with the nerve stimulator intensity at 0.2–0.6 mA indicates close proximity of the needle tip to the sciatic nerve. Any

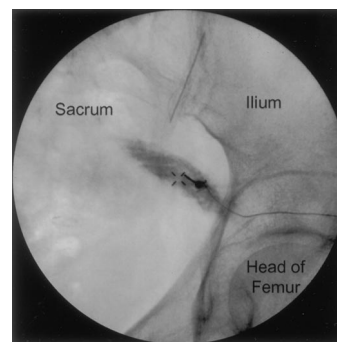


Fig. 2. Fluoroscopic view of the needle in the piriformis muscle, which is outlined by the injected radiopaque dye. The needle is inserted 1.5 ± 0.8 cm lateral and 1.2 ± 0.6 cm caudal to the lower border of the sacroiliac joint.

motor response (e.g., foot inversion, eversion, dorsiflexion, or plantar flexion) is accepted.¹² The needle is pulled back 3–5 mm until the elicited motor response disappears and steroid (40–60 mg methylprednisolone or 40 mg triamcinolone) in 5–6 ml normal saline is injected near the sciatic nerve. The needle is then pulled back another 3–8 mm to place the tip of the needle at the belly of the piriformis muscle. Iohexol (2–4 ml) is injected to outline the piriformis muscle (fig. 2), followed by the steroid (40 mg methylprednisolone or 40 mg triamcinolone) in 7–10 ml 1% lidocaine. After the procedure, the patient is brought to the recovery room for 1 h or until any leg numbness subsides, whichever period is longer.

We noted the response of the patients to the injection, any associated diagnoses, and previous treatments received before the injection. The indication for the piriformis/perisciatic injection was the presence of signs and symptoms of piriformis syndrome and incomplete relief from previous treatments. The patients had buttock pain that radiated to the hip or to the ipsilateral posterior thigh and leg and had positive Lasègue, Freiberg, and Pace signs.^{13–15} The criteria for response to the injection were relief of buttock and leg pain, increased activity, and improvement in Lasègue, Freiberg, and Pace signs.

Results

Cadaver Study

Both sides were suitable for study in 30 cadavers, whereas only one side was studied in six cadavers, for a total of 66 sciatic nerve/piriformis muscle studies. The distance from the lower border of the SIJ to the sciatic nerve was 2.9 ± 0.6 (1.8–3.7) cm laterally and 0.7 ± 0.7 (0.0–2.5) cm caudally. The width of the sciatic nerve, at its widest diameter, was 1.5 ± 0.3 (1.0–2.5) cm. The sciatic nerve was one solid nerve in 33 specimens and two distinct separate nerves in nine specimens, whereas the two components of the sciatic nerve were visible

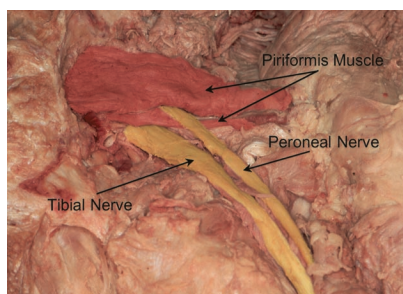


Fig. 3. Cadaver dissection showing the bipartite piriformis muscle. The tibial nerve passes below the piriformis muscle, whereas the common peroneal nerve passes through the piriformis muscle. The piriformis muscle is colored to delineate its margins, and the components of the sciatic nerve are colored to show their course.

within the sciatic nerve in 24 specimens. In 65 specimens, the sciatic nerve (or both of its components) passed anterior and inferior to the piriformis muscle. In one specimen, the piriformis muscle was bipartite and the two components of the sciatic nerve were separate with the tibial nerve passing below the piriformis and the peroneal nerve passing between the two components of the piriformis muscle (fig. 3).

Fluoroscopic-guided Injection to the Piriformis Muscle

Nineteen patients (6 men and 13 women) received piriformis muscle injection. Patient age ranged from 37–86 yr (mean \pm SD: 57.2 ± 14.7 yr). Ten patients received an injection to the left piriformis muscle, whereas nine had right-sided injections. Three patients received injections before the cadaver study. The results

of needle placements before and after cadaver dissection were combined because the sites of needle insertion were similar. The needle was inserted 1.5 ± 0.8 (0.4–3.0) cm lateral and 1.2 ± 0.6 (0.5–2.0) cm caudal to the lower border of the SIJ at a depth of 9.2 ± 1.5 (7.5–13) cm to stimulate the sciatic nerve. The stimulus intensity of the nerve stimulator was 0.4 ± 0.1 (0.2–0.6) mA. Ten eversion, four plantar flexion, three dorsiflexion, and two inversion foot responses were evoked. Six patients developed numbness in their feet lasting for 62 ± 30 (40–129) min. The total length of the needle that was pulled back before the piriformis muscle was injected was 0.8 ± 0.12 cm in the patients who developed foot numbness compared to 1.0 ± 0.2 cm in the patients who did not exhibit this response. The last eight patients in our study, in whom we pulled the needle back at least 1 cm before the dye was injected, had no numbness in their feet.

Clinical Experience

Sixteen of our 19 patients had comorbid diagnoses of buttock, leg, and back pain, including herniated disc with radiculopathy, failed back surgery syndrome, spinal stenosis, facet syndrome, SIJ dysfunction, and complex regional pain syndrome type I (table 1). Except for three patients who had pure piriformis syndrome, patients had received previous treatments including epidural steroid injections, facet injections, and SIJ injections. Sixteen of the 19 patients responded to the injection, with improvements ranging from a few hours to 3 months (table 1). The three patients with pure piriformis syndrome had good response and preferred not to have a botulinum toxin injection. One patient had a repeat perisciatic

Table 1. Patient Characteristics and Response to the Piriformis Muscle/Perisciatic Nerve Injection

Patient	Associated Diagnosis	Associated Treatments	Indication for Piriformis Injection	Response to Piriformis Injection
1	HNP, FBSS	ESI, NRB	Buttock and leg pain	None
2	SS, FS	ESI	Buttock pain	None
3	FBSS	ESI, NRB	Incomplete relief	100% relief, 3 months
4	HNP	NRB	Incomplete relief	75% relief, 1 month
5	None (PS)	None	Buttock pain	90% relief, 3 months
6	HNP	NRB	Incomplete relief	70% relief, 2 months
7	None (PS)	None	Buttock pain	70% relief, 2 months
8	SS	ESI	Incomplete relief	25% relief, 1 month
9	SS	ESI	Incomplete relief	None
10	None (PS)	None	Buttock pain	75% relief, 1 month
11	HNP, SS	ESI, NRB	Incomplete relief	80% relief, 1 month
12	FS	FJI, FNB	Incomplete relief	75% relief, 2 months
13	HNP, FBSS	ESI	Incomplete relief	80% relief, 1 month
14	HNP, FS	ESI, NRB	Incomplete relief	75% relief, 1 month
15	SS, CRPS	LPS	Buttock pain	100% relief, 3 hours
16	FBSS	ESI	Buttock pain	100% relief, 1 month
17	HNP, SIJD, FBSS	ESI, NRB	Buttock pain	75% relief, 1 month
18	HNP	NRB	Buttock pain	100%, 1 month
19	HNP, SS	ESI	Buttock pain	100%, 1 month*

* The injection was repeated at 1 month and patient 19 had continued relief for another 2 months.

CRPS = complex regional pain syndrome (type I); ESI = epidural steroid injection; FBSS = failed back surgery syndrome; FJI = facet joint injection; FNB = facet nerve block; FS = facet syndrome; HNP = herniated nucleus pulposus; NRB = nerve root block; PS = piriformis syndrome; SIJD = sacroiliac joint dysfunction; SS = spinal stenosis.

nerve/piriformis injection 1 month later and had continued relief for another 2 months. The other patients did not have a repeat injection and either tolerated residual buttock pain or were bothered by another cause or causes of their back and leg pain.

Discussion

Anatomic Abnormalities of the Piriformis Muscle and the Sciatic Nerve

The piriformis muscle originates from the anterior surface of the S2–S4 sacral vertebrae, the gluteal surface of the ilium near the posterior surface of the iliac spine, and the capsule of the SIJ.^{4,5} It runs laterally through the greater sciatic foramen, becomes tendinous, and inserts to the piriformis fossa at the medial aspect of the greater trochanter of the femur. The gluteal nerves, gluteal vessels, the sciatic nerve, and the posterior femoral cutaneous nerve pass below the piriformis muscle. The branches of the L5, S1, and S2 spinal nerves innervate the piriformis muscle.

There are six possible anatomical relationships between the sciatic nerve and the piriformis muscle^{1,16,17}: (1) the sciatic nerve passes below the piriformis muscle; (2) a divided nerve passes through and below the muscle; (3) a divided nerve passes through and above the muscle; (4) a divided nerve passes above and below the muscle; (5) an undivided nerve passes through the piriformis; or (6) an undivided nerve passes above the muscle. In 120 cadaver dissections, Beason and Anson¹⁶ found that the most common arrangement was the undivided nerve passing below the piriformis muscle (84%) followed by the divisions of the sciatic nerve between and below the muscle (12%). In 130 anatomic dissections, Pecina¹⁷ found that the undivided nerve passed below the muscle in 78% of his dissections and the divided nerve passed through and below the muscle in 21%. He noted the relation between high-level divisions of the sciatic nerve (*i.e.*, in the pelvis) and the common peroneal nerve passing through the piriformis muscle. Our study showed that both components of the sciatic nerve passed below the piriformis muscle in 98.5% (65 of 66 dissections) of the specimens studied. One of our dissections showed the muscle to be split: the tibial component of the sciatic nerve passed below the piriformis muscle, whereas the common peroneal nerve passed through the muscle (fig. 3).

Anomalies of the sciatic nerve and the piriformis muscle can cause sciatica. One case report described a patient whose sciatica was relieved after the lower head of the bipartite piriformis muscle was surgically cut.⁵ Another patient had a fascial constricting band around the sciatic nerve and a piriformis muscle lying anterior to the nerve.⁶ The patient's hip and buttock pain and sciatica improved after the fibrous band was resected and the piriformis muscle cut to restore the normal relationship

of the nerve and muscle. Previous authors have suggested entrapment of the sciatic nerve by the piriformis muscle and recommended surgical release of the muscle and its fascia as treatments for patients with piriformis syndrome.^{18–20}

Piriformis Syndrome: Pathophysiology, Signs and Symptoms, and Treatment

Piriformis syndrome, a term first coined by Robinson,¹³ affects 5–6% of patients referred for the treatment of back and leg pain.^{1,15} It is caused by trauma to the pelvis or buttock,^{1,21} hypertrophy of the piriformis muscle,^{5,8,9} anatomic abnormalities of the piriformis muscle or the sciatic nerve,^{5,6} differences in leg lengths (a minimum of 0.5-inch difference in leg lengths),⁴ or piriformis myositis.²² Some investigators consider piriformis syndrome to be a form of myofascial pain syndrome.¹⁰ A history of trauma is usually elicited in approximately 50% of cases of the syndrome.¹⁵ The trauma is usually not dramatic and may occur several months before the initial symptoms. It may also follow total hip replacement surgery.²⁰

The buttock pain and sciatica that are initially caused by trauma may lead to inflammation and spasm of the muscle.¹⁵ Inflammatory substances such as prostaglandin, histamine, bradykinin, and serotonin are released from the inflamed muscle and may irritate the sciatic nerve resulting in a pain-spasm-inflammation-irritation cycle.^{23,24} The inflamed, spastic, or stretched piriformis muscle may compress the sciatic nerve between the muscle and the pelvis,^{6,13} with the compression occurring between the tendinous portion of the muscle and the bony pelvis.⁶ In patients where the piriformis muscle is anterior to the sciatic nerve, the compression of the nerve occurs between the superior border of the piriformis and the superior margin of the greater sciatic foramen.⁶ Patients with entrapment of the sciatic nerve may have neurologic deficits and abnormal electrodiagnostic findings.⁵ Sciatica after laminectomy may result from impingement of the nerve roots by scar tissue resulting in "shortening" of the sciatic nerve rendering it prone to repeated tension and trauma by the piriformis muscle.¹⁸

The differential diagnoses of piriformis syndrome include the causes of low back pain and sciatica. Usually mistaken for a herniated disc, the patient with piriformis syndrome usually does not have neurologic deficits.¹⁵ Spinal stenosis, facet syndrome, SIJ dysfunction, trochanteric bursitis, myofascial pain syndrome, pelvic tumor, endometriosis, and conditions irritating the sciatic nerve should be considered in the differential diagnoses of the syndrome. These conditions can often be eliminated by obtaining a complete medical history and conducting a thorough physical examination.¹ The diagnosis of piriformis syndrome is usually made after exclusion of these possibilities. Isolated involvement of the piriformis muscle is uncommon and usually occurs as a part of soft

tissue injuries resulting from rotation and/or flexion movements of the hip and torso.² Our patients showed the concomitant presence of the syndrome with other causes of back and leg pain (table 1). A thorough physical examination usually identifies the active cause of the patient's pain so that appropriate treatment can be instituted.

Parziale¹ listed six cardinal features of the syndrome: (1) history of trauma to the sacroiliac and gluteal region; (2) pain in the region of the SIJ, greater sciatic notch, and piriformis muscle, extending down the leg and causing difficulty walking; (3) acute exacerbation of pain by stooping or lifting and moderately relieved by traction; (4) palpable, sausage-shaped mass over the piriformis muscle, which is tender to palpation; (5) positive Lasègue sign¹³; and (6) possible gluteal atrophy. The patient with piriformis syndrome usually reports buttock pain with or without radiation to the ipsilateral leg¹; the buttock pain usually extends from the sacrum to the greater trochanter.^{1,2,5} Whereas Hallin⁴ emphasized the rare occurrence of pain in the lower back, Parziale¹ noted varying degrees of paralumbar pain. If the piriformis muscle irritates the sciatic nerve, the patient may present with gluteal pain radiating to the ipsilateral leg.⁹ The pain may radiate to the posterior thigh down to the knee if there is involvement of the posterior cutaneous nerve of the thigh.^{2,4} The pain is usually aggravated by prolonged sitting (e.g., driving or biking) or on rising from a seated position.^{1,2} Pain occurs with bowel movements because of the proximity of the piriformis muscle to the lateral pelvic wall and is worse after sitting on hard surfaces with a wallet in the back pocket. The patient may also present with dyspareunia.¹ There may be a history of limp, with the patient dragging the lower leg on the affected side,²⁰ and the patient may report numbness in the foot.⁴

The physical examination may reveal a pelvic tilt and uneven scapulas⁴ or tenderness in the buttock from the medial edge of the greater sciatic foramen to the greater trochanter.¹ A spindle-shaped mass may be felt in buttock and there may be piriformis tenderness on rectal and pelvic examinations.^{1,2} The pain is aggravated by hip flexion, adduction, and internal rotation. Lasègue sign is pain on voluntary flexion, adduction, and internal rotation of the hip.^{13,24} Freiberg sign, or pain on forced internal rotation of the extended thigh,¹⁴ is due to stretching of the piriformis muscle and pressure on the sciatic nerve at the sacrospinous ligament. Pace sign is pain and weakness on resisted abduction of the hip when the patient is seated (*i.e.*, when the hip is flexed).^{15,20} These signs are better understood when one realizes that the function of the piriformis muscle is to externally rotate the hip joint when the thigh is extended at the hip joint and an abductor of the flexed thigh.^{2,25} Neurologic signs are usually negative.¹ Although findings of the straight leg test may be normal,

there may be limitation and pain during testing and numbness in the areas supplied by the sciatic nerve if the sciatic nerve is irritated.

Although the diagnosis of piriformis syndrome was once thought to be exclusively clinical,^{19,20} recent reports show the diagnostic value of electromyography, CT, and magnetic resonance imaging. Electromyography can detect myopathic and neuropathic changes including a delay in the H reflex with the affected leg in a flexed, adducted, and internally rotated position as compared with the same H reflex in the normal anatomic position.²⁶ A 3-SD prolongation of the H reflex has recently been recommended as the physiologic criterion for piriformis syndrome. This finding suggests entrapment of the nerve by the hip abductor and external rotator, *i.e.*, the piriformis muscle, under which it passes. CT of the soft tissues of the pelvis may show an abnormal uptake by the piriformis muscle²⁷ or an enlarged muscle,²⁴ whereas magnetic resonance imaging confirms the enlarged piriformis muscle but with normal intensity.²⁴

The management of piriformis syndrome includes physical therapy combined with the use of antiinflammatory drugs, analgesics, and muscle relaxants to reduce inflammation, spasm, and pain.^{1,2,28} Abnormal biomechanics caused by posture, pelvic obliquities, and leg-length inequalities need to be corrected.¹ Physical therapy involves stretching of the piriformis muscle with flexion, adduction, and internal rotation of the hip^{1,2} followed by pressure applied to the muscle. Ultrasound treatments have been found to reduce the pain.^{4,29} When the symptoms decrease, strengthening of the hip abductors is added to the regimen.¹ Vapocoolant spray with soft-tissue stretch of the area has also been recommended.³⁰

Patients who do not respond to conservative therapy are candidates for local anesthetic and/or steroid injections. Previous authors suggested that the injection should be made at the focal point of pain and irritability deep in the belly of the muscle,¹⁵ either at the medial aspect of the muscle^{1,2} or at the lateral aspect³¹ where firm compression of the sciatic nerve occurs.⁶ Caudal steroid and local anesthetic injections have also been found to be effective. In caudal injections, the injected solution diffuses along the nerve root sleeves and the proximal part of the sciatic nerve blocking the nerves that innervate the piriformis muscle.³²

Surgery may be considered in recalcitrant cases or when there is documented anatomic abnormality of the piriformis muscle, which may be thinned, divided, or excised.^{1,2,19,33,34} The obturator internus, gemelli, and quadratus femoris muscles can compensate for the loss of piriformis function, because these muscles share common insertions with the piriformis muscle.^{1,13}

Techniques of Piriformis Muscle and Perisciatic Nerve Injections

The older techniques of piriformis injection were made blindly,^{1,2,15} whereas the newer techniques involve identification of the piriformis muscle with muscle electromyography⁹ or with the use of CT guidance.¹⁰ Fishman *et al.*⁹ used fluoroscopic guidance and electromyography to identify the piriformis muscle. In their technique, the patient is in the prone position and the expected position of the piriformis muscle is identified using the greater trochanter of the femur and lateral border of the sacrum and the SIJ as landmarks. Placement of the needle in the piriformis muscle is confirmed by muscle electromyography and injection of contrast media. The authors were not able to measure the needle depth needed to reach the piriformis muscle and did not describe the response of their patients to the injection. Although successful in identifying the piriformis muscle, their technique uses muscle electromyography, which is not readily available in most pain management centers. It seems that the site of needle insertion of Fishman *et al.*⁹ is lateral to our site of insertion. Their technique will not locate the sciatic nerve unless the needle is inserted more medially because the sciatic nerve is closer to the SIJ than the greater trochanter of the femur (fig. 1). It should be noted that Fishman *et al.*⁹ intended to inject the steroid into the piriformis muscle only and did not plan to make the injection near the sciatic nerve.

A newer technique identifies the position of the muscle using CT and inserts the needle using CT guidance.¹⁰ Local anesthetic (2 ml 0.5% bupivacaine) is injected into the muscle followed by the injection of 100 U botulinum toxin type A. However, a wider application of this technique is limited by the unavailability of CT equipment in most pain treatment centers. Another new technique is the perisciatic injection used by Hanania and Kitain.^{7,8} In this technique, the patient is in the lateral or semiprone position with the nondependent hip and knee flexed and the dependent extremity straight. After locating the sciatic nerve with a nerve stimulator, 40 mg methylprednisolone in 5–10 ml dilute local anesthetic is injected while the needle is withdrawn a few centimeters. The authors described six patients who were previously unresponsive or partially responsive to blind piriformis muscle injections or epidural steroid injections. Using this injection technique, their patients experienced pain relief for up to 18 months.

We inject the steroid into the piriformis and the area near the sciatic nerve. Injection into the piriformis muscle reduces the swelling and/or spasm of the muscle. We also inject the steroid and the diluent near the sciatic nerve regardless of whether there are signs of sciatic nerve entrapment, because there is probably some inflammation of the nerve in cases of piriformis syndrome. Steroids are antiinflammatory and the topical administration of methylprednisolone has been shown to specifi-

cally block nociceptive fiber transmission.^{35,36} We use no local or very dilute local anesthetic for perisciatic injection to minimize motor blockade, and use local anesthetic and not saline for our piriformis injection to relax the piriformis muscle and break the cycle of pain and spasm. Injection of the local anesthetic into the belly of the muscle is recommended to avoid leakage of the local anesthetic into the sciatic nerve resulting in sensory and motor blockade of the leg and foot; this is especially important if botulinum toxin is injected.

Our success in locating the sciatic nerve before our cadaver study, when we inserted our needle 1 cm lateral to the SIJ, was probably attributable to the wide diameter of the sciatic nerve. The difference in the distances between our cadaver and clinical studies may be due to the angle of the C-arm of the fluoroscopy in relation to the anatomical structures and the inexact measurements on fluoroscopy (*i.e.*, a 1-cm measurement on x-ray film is not exactly 1 cm anatomically). In our cadaver study, we measured the distance from the SIJ to the middle of the sciatic nerve whereas we may have been stimulating the edge of the sciatic nerve in our clinical study. The caudal location of the needle insertion, in relation to the lower border of the SIJ, depends on the needle being located in the greater sciatic notch. A 0.5–1.5-cm caudal location is ideal, because a more caudal insertion may locate the sciatic nerve but may miss the piriformis muscle.

It is interesting to note that some of our patients had sustained relief for up to 3 months even with the local anesthetic-steroid injections. The relatively prolonged relief observed in some of our patients and those in Hanania and Kitain's⁸ study may be attributable to the concomitant perisciatic injection of the steroid. However, our clinical results are retrospective data, and more conclusive results can be deduced from prospective, randomized studies comparing piriformis/perisciatic injections from conservative management (*i.e.*, physical therapy or with botulinum toxin injection).

Botulinum toxin may be used if the patient responds to the steroid and local anesthetic injection. The toxin blocks the release of acetylcholine at the neuromuscular junction³⁷ and has been used in the treatment of focal dystonias such as blepharospasm, spasmodic torticollis, spasmodic dysphonia, or hemifacial spasm.^{37,38} The injection of botulinum toxin results in prolonged relaxation of the muscle and the recovery of the muscle depends on neuromuscular sprouting and reinnervation of the muscle which takes several weeks to months. Botulinum injections have been employed in the treatment of myofascial pain syndrome,^{38,39} and piriformis syndrome.¹⁰ Doses of 100 mouse units botulinum toxin type A (Botox)¹⁰ in 4 ml bupivacaine and 5,000–10,000 U botulinum type B have been employed. Reported complications of botulinum toxin injection include brachial plexopathy,⁴⁰ polyradiculoneuritis,⁴¹ and local psoriasisiform dermatitis.⁴² Injection into the sciatic

nerve should be avoided if the toxin is to be used in piriformis injections.

A randomized study compared botulinum toxin type A with methylprednisolone in patients with "myofascial piriformis pain."¹⁰ In this study, the piriformis muscle injection was guided by CT and not accompanied by a perisciatic injection. Thirty days after the injection, the patients in both groups showed marked reduction in their pain scores with no significant difference between the two groups. The patients who had botulinum injection, however, had significantly lower pain scores at 60 days after the injection.¹⁰

In summary, we discussed the causes of piriformis syndrome including anatomic abnormalities of the piriformis muscle and the sciatic nerve. It seems from our cadaver study and from previous anatomy studies that anatomic causes of piriformis syndrome are rare. We reviewed the literature on piriformis syndrome and its signs, symptoms, and treatments. From our initial clinical experience, we conclude that pure piriformis syndrome is rare and usually coexists with other causes of back pain, buttock pain, and sciatica. The diagnosis of piriformis syndrome is made after a thorough physical examination and by exclusion of the other causes of sciatica. Finally, we presented a fluoroscopy-guided and nerve stimulator-guided technique of injection of the piriformis muscle and near the sciatic nerve. The wider application of our technique will hopefully result in better treatment of patients with piriformis syndrome and lead to controlled studies on the efficacy of injection techniques for this syndrome.

References

1. Parziale JR, Hudgins TH, Fishman LM: The piriformis syndrome. *Am J Orthop* 1996; 25:819-3
2. Barton PM: Piriformis syndrome: A rational approach to management. *Pain* 1991; 47:345-52
3. Durrani Z, Winnie AP: Piriformis syndrome: An undiagnosed cause of sciatica. *J Pain Symptom Manage* 1991; 6:374-9
4. Hallin RP: Sciatic pain and the piriformis muscle. *Postgrad Med* 1983; 74:69-72
5. Chen WS: Bipartite piriformis muscle: An unusual cause of sciatic nerve entrapment. *Pain* 1994; 58:269-72
6. Sayson SC, Ducey JP, Maybrey JB, Wesley RL, Vermilion D: Sciatic entrapment neuropathy associated with an anomalous piriformis muscle. *Pain* 1994; 59:149-52
7. Hanania M: New technique for piriformis muscle injection using a nerve stimulator (letter). *Reg Anesth Pain Med* 1997; 22:200-2
8. Hanania M, Kitain E: Perisciatic injection of steroid for the treatment of sciatica due to piriformis syndrome. *Reg Anesth Pain Med* 1998; 23:223-8
9. Fishman SM, Canceris OA, Bandman TB, Audette JF, Borsook D: Injection of the piriformis muscle by fluoroscopic and electromyographic guidance. *Reg Anesth Pain Med* 1998; 23:554-9
10. Porta M: A comparative trial of botulinum toxin type A and methylprednisolone for the treatment of myofascial pain syndrome and pain from chronic muscle spasm. *Pain* 2000; 85:101-5
11. Netter FH: *Atlas of Human Anatomy*. Summit, New Jersey, Ciba-Geigy, 1989, pp 461-508
12. Benzon HT, Kim C, Benzon HP, Silverstein ME, Jericho B, Prillaman K, Buenaventura R: Correlation between evoked motor response of the sciatic nerve and sensory blockade. *ANESTHESIOLOGY* 1997; 87:547-52
13. Robinson D: Piriformis syndrome in relation to sciatic pain. *Am J Surg* 1947; 73:355-8
14. Freiberg AH: Sciatic pain and its relief by operations on muscle and fascia. *Arch Surg* 1937; 34:337-50
15. Pace JB, Nagle D: Piriformis syndrome. *West J Med* 1976; 124:435-9
16. Beason LE, Anson BJ: The relation of the sciatic nerve and its subdivisions to the piriformis muscle. *Anat Record* 1937; 70:1-5
17. Pecina M: Contribution to the etiological explanation of the piriformis syndrome. *Acta Anat* 1979; 105:181-7
18. Mizuguchi T: Division of the piriformis muscle for the treatment of sciatica: Postlaminectomy syndrome and osteoarthritis of the spine. *Arch Surg* 1976; 111:719-22
19. Solheim LF, Siewers P, Paus B: The piriformis muscle syndrome: Sciatic nerve entrapment treated with section of the piriformis muscle. *Acta Orthop Scand* 1981; 52:73-5
20. Cameron HU, Nofzt F: The piriformis syndrome (editorial). *Can J Surg* 1988; 31:210
21. Thiele GH: Coccydynia and pain in the superior gluteal region. *JAMA*; 1937; 109:1271-5
22. Chen WS: Sciatica due to piriformis pyomyositis. *J Bone Joint Surg* 1992; 74-A:1546-8
23. Lynn B: Cutaneous hyperalgesia. *Br Med Bull* 1977; 33:103-8
24. Jankiewicz JT, Hennrikus WL, Houkom JA: The appearance of the piriformis muscle in computed tomography and magnetic resonance imaging: A case report and review of the literature. *Clin Orthop* 1991; 262:205-9
25. Wyant GM: Chronic pain syndromes and their treatment: III. The piriformis syndrome. *Can Anaesth Soc J* 1979; 26:305-8
26. Fishman LM, Zybert PA: Electrophysiologic evidence of piriformis syndrome. *Arch Phys Med Rehabil* 1992; 73:359-64
27. Karl RD, Yedinak MA, Hartshorne MF, Cawthon MA, Bauman JM, Howard WH, Bunker SR: Scintigraphic appearance of the piriformis muscle syndrome. *Clin Nucl Med* 1985; 10:361-3
28. Rich B, McKeag D: When sciatica is not disk disease. *Phys Sports Med* 1992; 20:105-15
29. Steiner C, Staubs, Gannon M, Buhlinger C: Piriformis syndrome: Pathogenesis, diagnosis and treatment. *J Am Osteopath Assoc* 1987; 87:318-23
30. Simons D, Travell J: Myofascial origins of low back pain. *Postgrad Med* 1983; 73:99-108
31. Kirkaldy-Willis WH, Hill RJ: A more precise diagnosis for low back pain. *Spine* 1979; 4:102-9
32. Mullin V: Caudal steroid injection for treatment of piriformis syndrome. *Anesth Analg* 1990; 71:705-7
33. Vandertop, WP, Bosma NJ: The piriformis syndrome: A case report. *J Bone Joint Surg* 1991; 73(A):1095-7
34. Hughes SS, Goldstein MN, Hichs DG, Pellegrini VD: Extrapelvic compression of the sciatic nerve. *J Bone Joint Surg* 1992; 74(A):1553-9
35. Devor M, Govrin-Lippman R, Raber P: Corticosteroids suppress ectopic neural discharge originating in experimental neuromas. *Pain* 1985; 22:127-37
36. Johannsson A, Hao J, Sjolund B: Local corticosteroid application blocks transmission in normal nociceptive C-fibers. *Acta Anaesthesiol Scand* 1990; 34:335-8
37. Jankovic T, Brin MF: Therapeutic uses of botulinum toxin. *N Engl J Med* 1991; 324:1186-93
38. Cheshire WP, Abashian SW, Mann JD: Botulinum toxin in the treatment of myofascial pain syndrome. *Pain* 1994; 59:65-9
39. Wheeler AH, Goolkasian P, Gretz SS: A randomized, double-blind, prospective pilot study of botulinum toxin injection for refractory, unilateral, cervicothoracic, paraspinal, myofascial pain syndrome. *Spine* 1998; 23:1662-7
40. Sampaio C, Castro-Caldas A, Sales-Luis ML, Alves M, Pinto I, Apolinario P: Brachial plexopathy after botulinum toxin administration for cervical dystonia (letter). *J Neurol Neurosurg Psychiatry* 1993; 56:220
41. Haug BA, Dressler D, Prange HW: Polyradiculoneuritis following botulinum toxin therapy. *J Neurol* 1990; 237:62-3
42. Bowden JB, Rapini RP: Psoriasiform eruption following intramuscular botulinum A toxin. *Cutis* 1992; 50:415-6