

Multimodal Analgesia for Perioperative Pain Management

Asokumar Buvanendran, MD

Professor, Department of Anesthesiology, Director of Orthopedic Anesthesia
Rush University Medical Center, Chicago, IL

Multimodal analgesia captures the effectiveness of individual agents in optimal dosages that maximize efficacy and attempts to minimize side effects from one analgesic (mainly opioids). This important concept employs the theory that agents with different mechanisms of analgesia that may have synergistic effects in preventing or treating acute pain when used in combination. These regimens must be tailored to individual patients, keeping in mind the procedure being performed, side effects of individual medications, and patients' pre-existing medical conditions.¹ The concept and theory of multimodal analgesia is not new; however several novel pharmacological agents have emerged and can be added to the drugs that can be used in this fashion. It is vital to realize that blocking the neuronal pathway during surgery with local anesthetics does not decrease the humeral biochemical responses that occur during surgery which have to be inhibited by administering systemic pharmacological therapy.² This abstract will only focus on the recent advances in pharmacological agents for multimodal therapy.

ACETAMINOPHEN

Oral acetaminophen has been used for several decades³ and Paracetamol, an intravenous formulation of acetaminophen, became available in 2002 and has been studied in Europe. Göröcs and colleagues administered a single dose of 1 gram of intravenous paracetamol (Perfalgan®) prior to the termination of surgery and observed high patient satisfaction and good tolerance of the drug in 601 patients undergoing minor outpatient surgical procedures.⁴ Nearly half of these patients (42.7 %) received the single dose of paracetamol as monotherapy for post-operative pain. Salihglu, et al. randomized 40 patients undergoing laparoscopic cholecystectomy to 1 gram paracetamol (after intubation and prior to incision) or saline infusion. Significant improvements in outcomes in the paracetamol group included lower VAS, lower morphine consumption, and shorter stay in the recovery room (32 ± 11 versus 48 ± 14 minutes).⁵ Approved by the United States FDA in November 2010, intravenous (IV) acetaminophen (Ofirmev®) has been studied and shown to be safe. IV acetaminophen endorses a quick onset with meaningful pain relief achieved 25 minutes after administration in patients undergoing laparoscopic surgery,⁶ 25-27 minutes after total hip arthroplasty. [7] Ender, et al. retrospectively evaluated the use of a fast-track protocol (which included IV acetaminophen) for cardiac surgery in 421 patients compared to matched controls that were not fast-tracked and did not receive IV acetaminophen.⁸ The oral administration of

acetaminophen can probably achieve the same results as IV acetaminophen in patients who have a functioning gastrointestinal system. However it is also to be noted that the analgesic effect is much more rapid than oral due to the pharmacokinetics.

Combinations of acetaminophen and non steroidal anti-inflammatory drugs (NSAIDs) have been investigated and may offer enhanced effects as based on current research. In 55 children undergoing hernia repair, 30 mg ketorolac and 20 mg/kg acetaminophen resulted in significantly lower post-operative fentanyl consumption, less sedation and vomiting.⁹ A systematic review of this subject determined that when used as a combination, NSAIDs and paracetamol "offer superior analgesia compared with either drug alone"¹⁰ and 18/21 studies included had positive results with regard to lowering visual analogue score (VAS) and/or use of rescue analgesics. The combination was more effective than paracetamol (85 % of studies) or NSAIDs (64 % of studies) as individual agents.

NONSTEROIDAL ANTI-INFLAMMATORY DRUGS (NSAIDS)

The use of NSAID use in the perioperative period has been well established taking into consideration the adverse effects of bleeding. The utility of COX-2 inhibitors in this scenario has been demonstrated to be a benefit.¹² Randomized, double-blind, placebo-controlled study to examine celecoxib 200mg versus placebo in patients undergoing major plastic surgery demonstrated the ability of celecoxib to reduce VAS and postoperative morphine consumption.¹¹

More recent formulations of NSAIDs include an intranasal (IN) ketorolac spray, IV ibuprofen, and topical diclofenac. Southworth and colleagues conducted a randomized, double-blind trial of varying dosages of IV ibuprofen (Caldolor®) versus placebo in 406 patients having an elective abdominal or orthopedic surgery.¹² Those receiving ibuprofen 800 mg every 6 hours consumed 22 % less morphine postoperatively. IV ibuprofen 400 mg every 6 hours appeared to attenuate postoperative pain for up to 24 hours, but had no benefit thereafter when compared to placebo. Aside from dizziness, IV ibuprofen was generally well-tolerated.

In a randomized, double-blind, placebo-controlled study comparing intranasal (IN) ketorolac to placebo in 40 patients undergoing third molar extraction, Grant and Mehlich demonstrated 31.5 mg IN ketorolac resulted in higher pain relief scores and greater patient satisfaction. 60 % of participants in the study group reported good to excellent pain control compared to 13 % in the placebo group.¹³ IN ketorolac 31.5mg every

6 hours for 48 hours, then up to four times daily (up to 5 days) in patients undergoing abdominal surgery decreased morphine use over 48 hours and resulted in higher quality of analgesia scores.¹⁴ The authors of this study indicated that pain relief occurred within 20 minutes of administration, which may be due to higher blood brain penetration of ketorolac via the nasal route (cribriform plate). The availability of IN ketorolac can now be used in the ambulatory setting after discharge home taking the same general precautions as IV formulation.

Topical diclofenac exists in several forms, including diclofenac epolamine 1% topical patch (FLECTOR Patch®), diclofenac sodium 1% topical gel (VOLTAREN Gel®), and diclofenac sodium 1.5% w/w liquid (PENNSAID®). A review by Massey and colleagues showed that topical NSAIDs are not only safe, but efficacious in the treatment of acute soft tissue injuries and localized regions of pain.¹⁵ They did find a difference between placebo and topical NSAIDs with regard to local skin irritation but the systemic side effects were less with topical. This research has even led to the National Institute for Health and Clinical Excellence (UK) to recommend topical NSAIDs, along with acetaminophen, as first line treatment for osteoarthritis pain.¹⁶

A review of diclofenac epolamine topical patch by McCarberg and Argoff discussed the benefits of a patch, as opposed to NSAID gels or creams.¹⁷ These included application of a defined dose of diclofenac, drug delivery over an extended period of time (typically 12 hours), and ease of application. Application of diclofenac sodium 1% gel versus placebo vehicle (identical composition to the gel component of the study drug) applied 4 times daily for 3 months was investigated by Barthel, et al for the treatment of osteoarthritis pain.¹⁸ Results of their study indicated superior analgesia from 1 to 12 weeks and improved function for the same duration. With regards to diclofenac 1.5 % w/w liquid, it has been shown to be as efficacious to oral diclofenac in treating arthritis pain.¹⁹ Gastrointestinal side effects were significantly less common with local skin reactions being more common. A prospective study by Shainhouse and colleagues established the safety of topical diclofenac 1.5% w/w²⁰ in a study where 793 subjects was followed for an average of 204 days; 144 subjects were followed for 1 year. Application of the study drug, 40 drops four times daily, resulted in local skin reactions (dry skin, contact dermatitis, or dermatitis with vesicles) in 45.1% of study participants. 24 volunteers indicated a similar overall experience when using diclofenac gel and diclofenac liquid. However, they found the gel to have a less desirable scent, found the consistency to be more greasy and sticky when compared to the diclofenac liquid.²¹ When side effects have limited oral NSAID use in a multimodal, it may be that IN, IV, and topical formulations of NSAIDs could prove to be of benefit in the perioperative period and should be considered as tools that are emerging for multimodal analgesia.

ANTICONVULSANTS

The use of adjunct agents to treat pain includes the use of anticonvulsants such as gabapentin and pregabalin. Clarke and colleagues studied the effects of varying doses of gabapentin given pre-operatively and post-operatively in addition to femoral/sciatic nerve blocks and celecoxib in 36 patients undergoing total knee arthroplasty. When administered pre- and post-operatively, gabapentin decreased morphine consumption on post-operative days (POD) 2 – 4 and increased the amount of active knee flexion on POD 2 – 3. This occurred without an increase in side effects.²² A randomized, double-blind, controlled trial of gabapentin in children undergoing spinal fusion determined that pre- and post-operative gabapentin resulted in decreased morphine consumption and improved pain scores through the early stages of recovery up to POD2.²³ However, this attenuation of opioid use and decreased verbal pain scores was temporary. An evaluation of gabapentin's ability to prevent not only acute, but chronic pain by Sen, et al. revealed that gabapentin 1200 mg administered preoperatively decreased morphine consumption, reduced incisional pain at 1, 3, and 6 months, and improved patient satisfaction compared to placebo.²⁴ Comparing varying dosages of gabapentin in lumbar laminectomy, Khan et al. concluded the timing of dosing (pre-operative versus post-operative) did not affect analgesic efficacy. Gabapentin administered 900 mg or 1200 mg pre- or post-operatively reduced morphine consumption in the first 24 hours post-op and VAS scores without increase in side effects. [25]

The use of similar anticonvulsant, pregabalin, has gained attention because of more favorable pharmacokinetics which includes improved bioavailability and faster achievement of therapeutic levels. 30 patients undergoing laparoscopic cholecystectomy were randomized to receive pregabalin 150 mg 1 hour pre-operatively or placebo by Agarwal, et al.²⁶ Fentanyl use and VAS scores were measured up to 24 hours postop. Both VAS scores and narcotic use were significantly lower in patients who had received pregabalin. No significant difference in side effects was noted. Mathiesen and colleagues studied a single pre-operative dose of pregabalin 300 mg versus pregabalin 300 mg + dexamethasone 8 mg in 120 patients undergoing total hip arthroplasty.²⁷ Although pain scores were unaffected, the two groups receiving pregabalin pre-op had significantly less morphine consumption at 24 hours post-op. They did notice that those receiving pregabalin had more sedation. A randomized, placebo-controlled, double-blind trial comparing pregabalin (300mg pre-operatively with a tapering dose post-operatively for 14 days) to placebo in 240 patients undergoing total knee arthroplasty has recently been published.²⁸ Immediate effects observed were decreased epidural drug consumption and increased sedation and confusion on POD 0 and 1. Long-term outcomes included reduced neuropathic pain at 3 and 6 months. A meta-analysis by Zhang et al. demonstrated that pregabalin administered pre-

operative, post-operative or both decreases 24 hour morphine consumption while having no effect on post-op pain scales.²⁹ Analysis also revealed that pregabalin administration led to lower rates of postoperative nausea and vomiting. It is important to note that this meta-analysis did not include any studies of prolonged (more than 2) doses of pregabalin.

TRPV1 AGONIST: CAPSAICIN

Capsaicin, the active component of chili peppers, selectively stimulates unmyelinated C fiber afferent neurons and causes the release of substance P. Following initial depolarization, continued release of substance P in the presence of capsaicin leads to the depletion of substance P and subsequent decrease in C fiber activation. It is a non-narcotic that acts at TRPV1 receptor as an agonist peripherally. It does not affect the A-delta and A-alpha fibers. Capsaicin causes calcium dependant desensitization.

An ultra-purified capsaicin (ALGRX 4975, 98% pure) has been investigated in a randomized, double-blind, placebo-controlled study of the analgesic efficacy of a single intra-operative wound instillation of 1000 mcg of capsaicin after open mesh groin hernia repair.³⁰ The VAS pain scores assessed as area under the curve was significantly lower during the first 3 days postoperatively, but this effect was not observed after 72 hours. The local application of capsaicin during hernia repair does not lead to loss of sensory function in patients³¹ and has been demonstrated in animal studies not to cause neurotoxicity.³² Further clinical trials have been carried out in patients undergoing total knee and hip arthroplasty but the entire data has not been published to date. When capsaicin is used in the perioperative setting, the clinician must administer capsaicin well before the end of anesthesia to allow for resolution of the acute burning sensation that occurs immediately after its application. The prolonged duration of analgesia obtained by capsaicin could be extremely valuable in facilitating earlier rehabilitation after painful orthopedic surgery procedures. In contrast to local anesthetic, capsaicin does not affect the motor or autonomic functions and therefore will not interfere with postoperative rehabilitation. The capsaicin patch (NGX-4010) though used for various neuropathic chronic pain conditions, may be useful in acute pain in a multimodal fashion. This needs further large scale randomized controlled trials.

NMDA RECEPTOR ANTAGONISTS:

NMDA receptor antagonists, including ketamine and memantine, have been studied as adjuncts for acute and chronic pain management. Ketamine has options for routes of administration, including IV or IN. Remérand and colleagues demonstrated that an IV bolus at the beginning of surgery followed by a 24 hour infusion decreased morphine consumption in patients undergoing total hip arthroplasty.³³ More interestingly, patients receiving ketamine decreased the incidence of chronic pain. At 6 months 21% of placebo and 8% of

ketamine-receiving patients had persistent pain. Loftus et al. found similar results, albeit in opiate-dependent patients undergoing lumbar spine surgery.³⁴ A ketamine infusion of 10 µg/kg/min was started at the beginning of surgery after a bolus of 0.5 mg/kg was administered and terminated at skin closure. Significant results included decreased post-op morphine requirements and lower pain scores at 6 weeks post-op.

Memantine was first synthesized in the 1960s and found to antagonize the NMDA receptor in the 1980's. The major site of action is the blockade of current flow through the NMDA receptor channel. Memantine is completely absorbed from the gastrointestinal tract with maximal plasma concentration occurring between 3-8 hours after oral administration. Food does not influence the bioavailability of memantine. Approximately 80% of the administered dose remains as the parent drug. The mean terminal elimination half-life is 60-100 hrs. The dose should be increased in 5 mg increments to 10 mg/day. The recommended maintenance dose is 10 mg twice daily (20 mg/day). There is not an established dose for the treatment of chronic pain states, but case reports and medication trials have started at 5-10 mg bid with increases at 1 week interval to 30 mg/day have been examined. Ketamine causes memory deficits; reproduces with impressive accuracy the symptoms of schizophrenia; is widely abused; and induces vacuoles in neurons at moderate concentrations and cell death at higher concentrations. Memantine, on the other hand, is well tolerated; although instances of psychotic side effects have been reported, in placebo-controlled clinical studies the incidence of side effects is remarkably low.

Memantine, an orally administered non-competitive NMDA receptor antagonist, may prove to be more useful than ketamine as an analgesia adjunct. In one study, daily doses of memantine 30mg decreased phantom pain by up to 80% at one month following upper extremity amputations (in combination with brachial plexus block.)³⁵ Unfortunately, in patients who have developed phantom pain the pain relief obtained is temporary. Once chronic pain from surgery is established like phantom limb pain, memantine has not been shown to provide analgesia for these patients.

Magnesium seems to exert its analgesic mechanism via inhibition of calcium influx, antagonism of NMDA receptors and prevention of enhanced ligand-induced NMDA signaling in a state of hypo-magnesemia. In addition magnesium may attenuate central sensitization after peripheral tissue injury or inflammation because of dorsal horn NMDA receptors. Magnesium sulfate is available as a 500 mg/ml preservative-free solution for injection. Magnesium administered intravenously lacks efficacy at 4g, however, 50mg administered intrathecally has been demonstrated to be effective.³⁶ Perioperative IV magnesium sulfate at very high doses has been reported to reduce postoperative morphine consumption but not postoperative pain scores. Recently, a dose finding study for IV magnesium determined that administration of magnesium at 40 mg/kg prior to induction, followed by a 10 mg/kg/hour infusion, resulted in a reduction

in perioperative analgesic requirements without any major hemodynamic consequences.³⁷ Higher infusion doses did not offer any advantage. However, since the magnesium ion poorly crosses the blood brain barrier in humans, it is not clear whether the therapeutic effect is related to NMDA antagonism in the central nervous system or peripheral. This needs to be investigated further.

ALPHA – 2 AGONISTS:

Use of alpha-2 agonists as an analgesia adjunct has gained interest with the clonidine and dexmedetomidine. Central and peripheral stimulation of the alpha-2 receptors is believed to be the basic mechanism behind analgesia. Clonidine's role in neuraxial blockade has been described by a number of studies. Recently, Lena and colleagues compared a clonidine/morphine spinal plus remifentanyl infusion to a sufentanil infusion for analgesia in 83 patients undergoing open heart surgery.³⁸ The clonidine/morphine spinal group had faster times to extubation, lower pain scores post-op, used less PCA morphine, and had improved patient satisfaction.

An infusion of dexmedetomidine, administered prior to induction through wound closure, decreased post-anesthesia care unit (PACU) opioid use in 80 patients undergoing laparoscopic bariatric surgery.³⁹ In addition to this, nausea and vomiting was decreased, and PACU stay shortened. As presumed higher doses of dexmedetomidine required significantly more rescue doses of phenylephrine intra-op, otherwise there were no differences in side effects compared to placebo. Ramadhyani and colleagues reviewed dexmedetomidine's use in IV regional anesthesia.⁴⁰ They concluded that when added to IV regional solutions, dexmedetomidine had the ability to prolong analgesia and extend the duration of motor and sensory blockade.

DUAL ACTING AGENT- TAPENTADOL:

Tapentadol is a novel central acting analgesic with dual mode of action.⁴¹ It has analgesic action via the mu-opioid receptor and norepinephrine reuptake inhibition. Combining both effects in a single molecule eliminates the potential for drug-drug interactions inherent in multiple drug therapy. The analgesic effects of tapentadol are independent of metabolic activation with minimal metabolites. Having limited protein binding, no active metabolites and no significant microsomal enzyme induction or inhibition, tapentadol has a limited potential for drug-drug interactions. The dual mode of analgesia is synergistic as demonstrated by pre-clinical work. The immediate release formulation of tapentadol is FDA approved and has been used in the USA since 2008 with 50, 75 and 100 mg. The drug is a schedule II and as such all precautions that need to be followed for other drugs in this category needs to be followed. The equipotent analgesics dose of 100 mg of tapentadol to oxycodone is 15 mg and needs to be administered 4-6 hours.

This compound though has opioid activity also has activity at the descending pathway and therefore may prove to be a very useful analgesic as more clinical experience is obtained in the postoperative setting. For equipotent doses of narcotics, tapentadol has decreased incidence of nausea and vomiting compared to oxycodone.⁴² The concept of obtaining equipotent analgesia with decreased postoperative nausea and vomiting can be of great benefit in treating postoperative pain and earlier discharge with significant cost savings.⁴³ However, further clinical trials need to be carried to demonstrate this phenomenon.

EMERGING TECHNOLOGIES IN PAIN MANAGEMENT

Transdermal fentanyl: The use of patient-controlled delivery has led to the development of other modalities that allow patient control in the delivery of opioid medications. Transdermal delivery systems such as IONSYS®, allow demand dosing of fentanyl at a predetermined interval. The fentanyl HCl iontophoretic transdermal system (ITS) is a patient-controlled approach to analgesic delivery that may avoid some of the problems associated with IV PCA. Fentanyl ITS is a compact, needleless, self-contained system that is preprogrammed to deliver fentanyl 40 mcg across the skin by means of an imperceptible low-intensity electrical current, a method known as iontophoresis. This needleless system is under further research before being released for human use. Inhaled fentanyl has been trialed in pediatric and adult patients. There are investigations into the encapsulated liposomal inhaled fentanyl for acute pain- the advantage of this being that it can provide rapid onset and sustained release.

Long acting local Anesthetics: A new developed liposomal long acting bupivacaine is considered for approval by the FDA. A single injection of the liposomal bupivacaine should last 72 hours and is currently considered for infiltration of the local surgical site. Regional analgesia with this product has yet to be established.

Cannabinoids: These compounds have been shown to potent analgesics in animal models. There have been several clinical trials, most of them demonstrating no significant analgesic effect superior to placebo.⁴⁴ In fact some of the trials demonstrated increase in VAS with nabilone (oral synthetic cannabinoid) when used in acute postoperative setting. However, these classes of drugs seem to be promising in chronic pain patients.

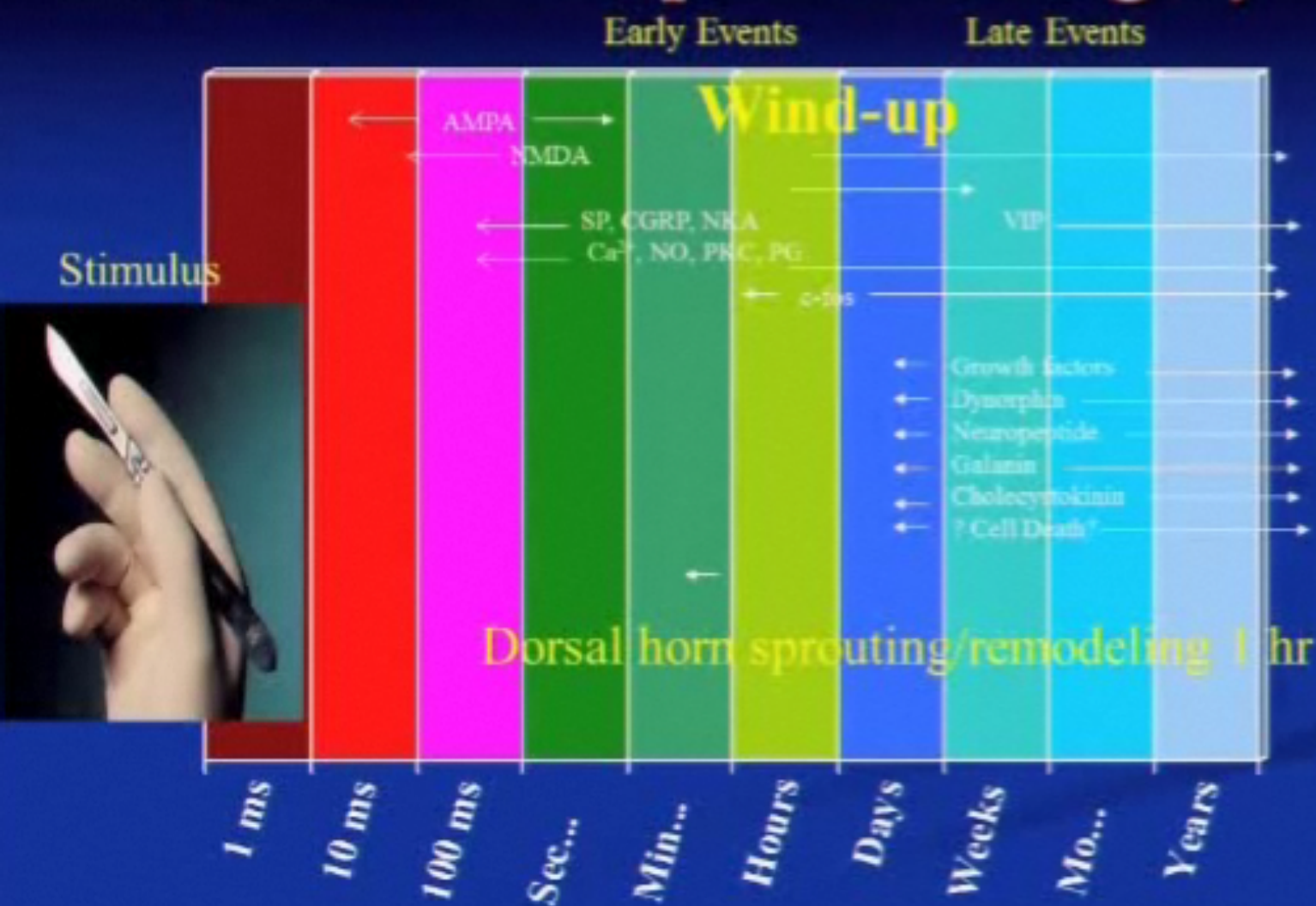
CONCLUSION

Acute postoperative pain is a predictable response. Recent research has demonstrated that un-treated acute postoperative pain can lead to chronic persistent pain. It is imperative that the health care provider managing acute postoperative pain understand the various options such as the multimodal analgesia so that acute pain can be treated and to prevent the development of chronic pain from surgery.

REFERENCES:

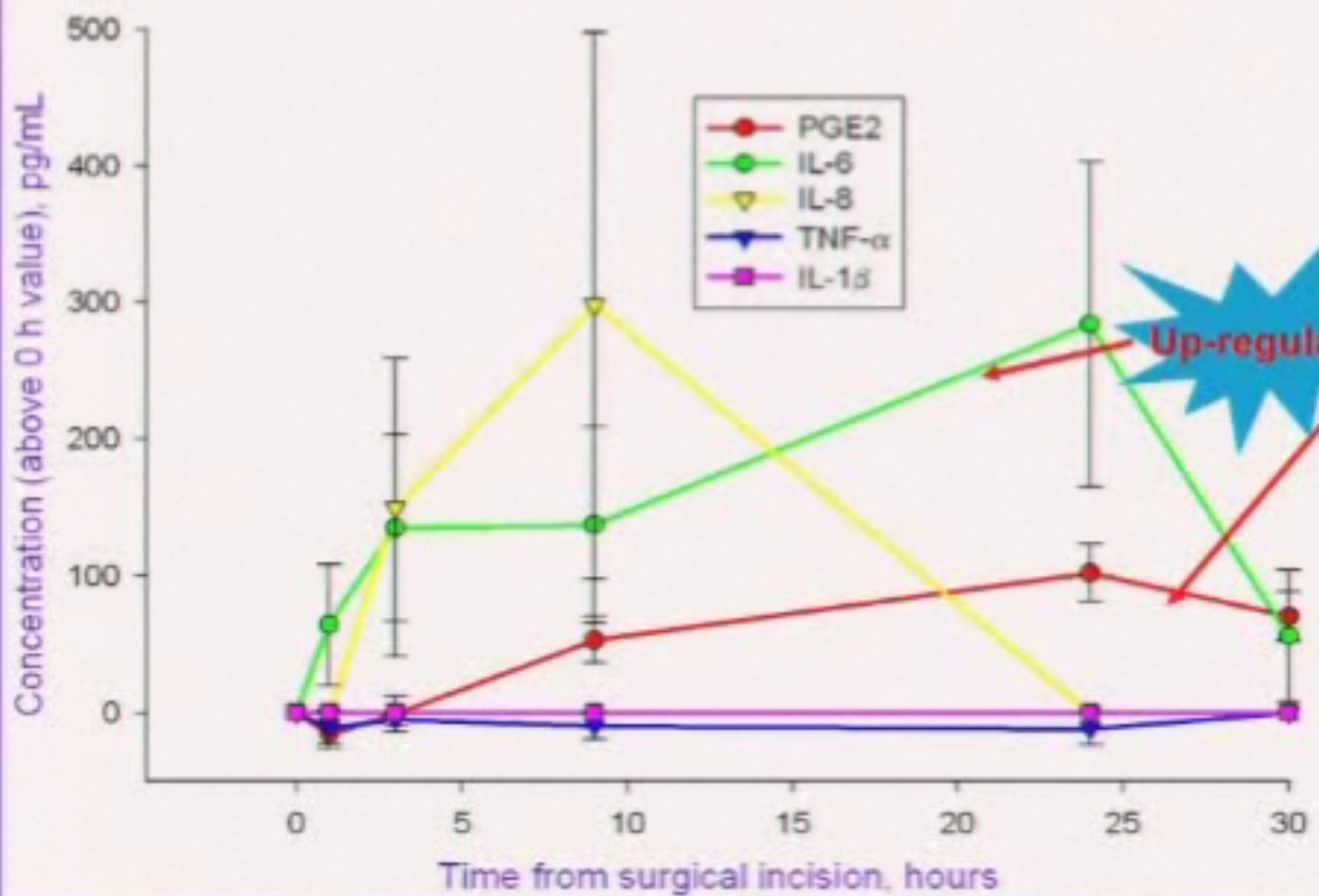
- Buvanendran A, Kroin JS: Multimodal analgesia for controlling acute postoperative pain. *Curr Opin Anesthesiol* 2009; 22:588-93.
- Buvanendran A, Kroin JS, Berger RA et al: Up regulation of prostaglandin E2 and interleukins in the central nervous system and peripheral tissue during and after surgery in humans. *Anesthesiology* 2006; 104: 403-410
- Graham GG, Scott KF: Mechanism of action of paracetamol. *Am J. Ther* 2005; 12: 46-55.
- Göröcs TS, Lambert M, Rinne T, et al. Efficacy and tolerability of ready-to-use intravenous paracetamol solution as monotherapy or as adjunct analgesic therapy for postoperative pain in patients undergoing elective ambulatory surgery: open, prospective study. *International Journal of Clinical Practice* 2009; 63: 112–120.
- Salihoglu Z, Yildirim M, Demiroglu S, et al. Evaluation of intravenous paracetamol administration on postoperative pain and recovery characteristics in patients undergoing laparoscopic cholecystectomy. *Surgical Laparoscopy, Endoscopy, and Percutaneous Techniques* 2009; 19:321–323.
- Wininger SJ, Miller H, Minkowitz HS, et al: A randomized, double-blind, placebo-controlled, repeated dose study of two intravenous acetaminophen dosing regimens for the treatment of pain after abdominal laparoscopic surgery. *Clin Ther* 2010; 32: 2348- 69.
- Sinatra RS, Jahr JS, Reynolds LW et al: Efficacy and safety of single and repeated administration of 1 gram of intravenous acetaminophen injection (paracetamol) for pain management after major orthopedic surgery. *Anesthesiology* 2005; 102: 822-831.
- Ender J, Borger MA, Scholz M, et al. Cardiac surgery fast-track treatment in a post-anesthetic care unit: six-month results of the Leipzig fast-track concept. *Anesthesiology* 2008; 109(1): 61-66.
- Hong JY, Won Han S, Kim WO, Kil HK. Fentanyl sparing effects of combined ketorolac and acetaminophen for outpatient inguinal hernia repair in children. *Journal of Urology* 2010; 183:1551–1555.
- Ong CK, Seymour RA, Lirk P, Merry AF. Combining paracetamol (acetaminophen) with nonsteroidal antiinflammatory drugs: a qualitative systematic review of analgesic efficacy for acute postoperative pain. *Anesthesia & Analgesia* 2010; 110:1170–1179.
- Sun T, Sacan O, White PF, et al. Perioperative vs postoperative celecoxib on patient outcome after major plastic surgery procedures. *Anesthesia & Analgesia* 2008; 106:950-958.
- Southworth S, Peters J, Rock A, et al. A multicenter, randomized, double-blind, placebo-controlled trial of intravenous ibuprofen 400 and 800 mg every 6 hours in the management of postoperative pain. *Clinical Therapeutics* 2009; 31(9):1922-1935.
- Grant GM, Mehlich DR. Intranasal ketorolac for pain secondary to third molar impaction surgery: a randomized, double-blind, placebo-controlled trial. *Journal of Oral and Maxillofacial Surgery* 2010; 68:1025–1031.
- Singla N, Fingla S, Minkowitz HS, et al. Intranasal ketorolac for acute postoperative pain. *Current Medical Research and Opinion* 2010; 26(8): 1915-23.
- Massey T, Derry S, Moore RA, et al. Topical NSAIDs for acute pain in adults. *Cochrane Database of Systemic Reviews* 2010; 16(6): 1-95.
- National Institute for Health and Clinical Excellence. Osteoarthritis: the care and management of osteoarthritis in adults. NICE clinical guideline 59. <http://www.nice.org.uk/nicemedia/pdf/CG59NICEguideline.pdf>. Accessed March 21, 2011.
- McCarberg BH and Argoff CE. Topical diclofenac epolamine patch 1.3% for treatment of acute pain caused by soft tissue injury. *International Journal of Clinical Practice* 2010; 64(11): 1546-1553.
- Barthel HR, Haselwood D, Longley III S, et al. Randomized controlled trial of diclofenac sodium gel in knee osteoarthritis. *Seminars in Arthritis and Rheumatism* 2009; 39(3): 203-212.
- Moen MD. Topical diclofenac solution. *Drugs* 2009; 69(18): 2321-2632.
- Shainhouse JZ, Grierson LM, and Naseer Z. A long-term, open-label study to confirm the safety of topical diclofenac solution containing dimethyl sulfoxide in the treatment of the osteoarthritic knee. *American Journal of Therapeutics* 2010; 17: 566-5763.
- Galer BS. A comparative subjective assessment study of PENNSAID and Voltaren Gel, two topical formulations of diclofenac sodium. *Pain Practice* 2010; 20: 1-9.
- Clarke H, Pereira S, Kennedy D, et al. Gabapentin decreases morphine consumption and improves functional recovery following total knee arthroplasty. *Pain Research & Management* 2009; 14:217–222.
- Rusy L, Hainsworth K, Nelson T, et al. Gabapentin use in pediatric spinal fusion patients: a randomized, double-blind, controlled trial. *Anesth Analg* 2010; 110:1393–1398.
- Sen H, Sizlan A, Yanarates O, et al. A comparison of gabapentin and ketamine in acute and chronic pain after hysterectomy. *Anesthesia & Analgesia* 2009; 109:1645–1650.
- Khan ZH, Rahimi M, Makarem, et al. Optimal dose of pre-incision/post-incision gabapentin for pain relief following lumbar laminectomy: a randomized study. *Acta Anaesthesiologica Scandinavica* 2011; 55:306-312.
- Agarwal A, Gautam S, Gupta D, et al. Evaluation of a single preoperative dose of pregabalin for attenuation of postoperative pain after laparoscopic cholecystectomy. *British Journal Anaesthesia* 2008; 101:700–704.
- Mathiesen O, Jacobsen LS, Holm HE, et al. Pregabalin and dexamethasone for postoperative pain control: a randomized controlled study in hip arthroplasty. *Br J Anaesth* 2008; 101:535–541.
- Buvanendran A, Kroin JS, Della Valle CJ, et al. Perioperative oral pregabalin reduces chronic pain after total knee arthroplasty: a prospective, randomized, controlled trial. *Anesthesia & Analgesia* 2010; 110:199–207.
- Zhang J, Ho KY, Wang Y. Efficacy of pregabalin in acute postoperative pain: a meta-analysis. *British Journal of Anaesthesia* 2011; Feb 26: 1-9.
- Aasvang EK, Hansen JB, Malmstrom J, et al. The effect of wound instillation of a novel purified capsaicin formulation on postherniotomy pain: a double-blind, randomized, placebo-controlled study. *Anesth Analg* 2008; 107:282-291.
- Aasvang EK, Hansen JB, Kehlet H: Late sensory function after intraoperative capsaicin wound instillation. *Acta Anaesthesiol Scand* 2010; 54: 224-31.
- Kissin I: Vanilloid-induced conduction analgesia: selective, dose-dependent, long lasting, with low level of potential neurotoxicity. *Anesth Analg* 2008; 107: 271-281.
- Remerand F, Tendre CL, Baud A, et al. The early and delayed analgesic effects of ketamine after total hip arthroplasty: a prospective, randomized, controlled, double-blind study. *Anesth Analg* 2009; 109(6): 1963-1971.
- Loftus RW, Yeager MP, Clark JA, et al. Intraoperative ketamine reduces perioperative opiate consumption in opiate-dependent patients with chronic back pain undergoing back surgery. *Anesthesiology*. 2010; 113(3):639-646.
- Schley M, Topfner S, Wiech K, et al. Continuous brachial plexus blockade in combination with the NMDA receptor antagonist memantine prevents phantom pain in acute traumatic upper limb amputees. *European J of Pain* 2007; 11: 299-308.
- Buvanendran A, McCarthy RJ, Kroin JS, et al. Intrathecal magnesium prolongs fentanyl analgesia: a prospective, randomized, controlled trial. *Anesth Analg*. 2002;95:661-666
- Koinig H, Wallner T, Marhofer P, et al. Magnesium sulfate reduces intra- and postoperative analgesic requirements. *Anesth Analg*. 1998; 87:206-210
- Lena P, Balarac N, Lena D et al: Fast track anesthesia with remifentanyl and spinal analgesia for cardiac surgery: the effect on pain control and quality of recovery. *Journal of Cardiothoracic and Vascular Anesthesia* 2008; 22: 536-542.
- Tufanogullari B, White PF, Peixoto MP et al: Dexmedetomidine infusion during laparoscopic bariatric surgery: the effect on recovery outcome variables. *Anesth Analg* 2008; 106: 1741-1748.
- Ramadhani U, Park JL, Carollo DS et al: Dexmedetomidine: clinical application as an adjunct for intravenous regional anesthesia. *Anesthesiology clinics* 2010; 28: 709-722.
- Afilalo M, Stegmann JU, Upmalis D et al: Tapentadol immediate release: a new treatment option for acute pain management. *J Pain Res* 2010; 8: 1-9
- Etropolski M, Kelly K, Okamoto A, Rauschkolb C: Comparable efficacy and superior gastrointestinal tolerability (nausea, vomiting, constipation) of tapentadol compared with oxycodone hydrochloride. *Adv Ther* 2011; April. (not yet in print)
- Kwong WJ, Ozer-Stillman I, Miller JD et al: Cost-effectiveness analysis of tapentadol immediate release for the treatment of acute pain. *Clin Ther* 2010; 32: 1768-81.
- Beaulieu P: Effects of nabilone, a synthetic cannabinoid, on postoperative pain. *Can J Anaesth* 2006; 53: 769-75.

Biochemical Response to Surgery



Central Compartment

CSF PGE2 and Cytokines



Surgical Pain and Central Sensitization

Recent article

- Incisional pain is associated with secondary punctate hyperalgesia that is ketamine sensitive with no spread in thermal sensitivity indicating induction of central sensitization.
- As such the postoperative analgesia needs to be continued until surgical healing is well established

Woolf C: Pain 2011

Meta-analyses: NSAIDs , COX-2 inhibitors & Acetaminophen

- 52 RCT were included:

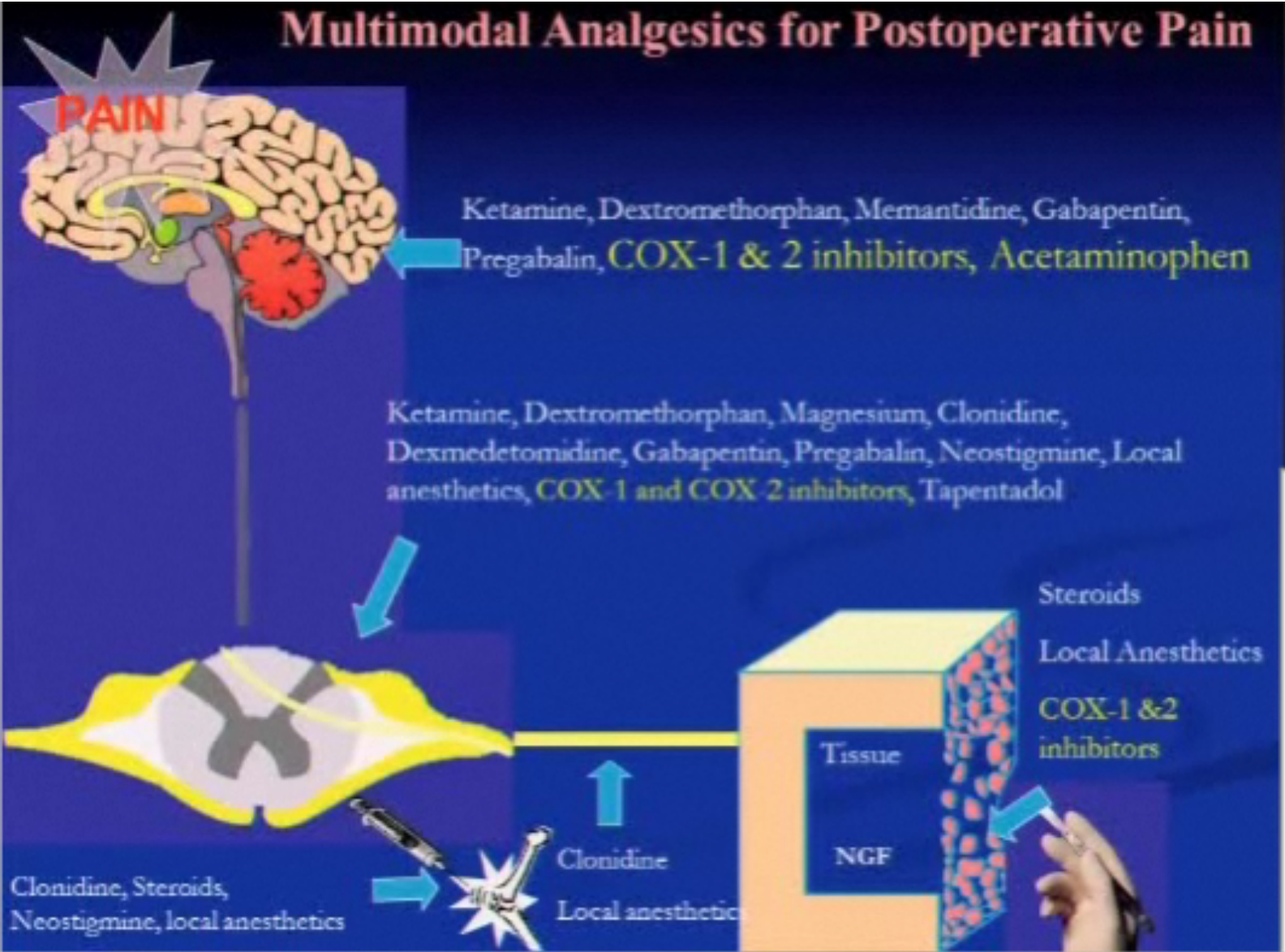
Results:

- 24 h morphine consumption: ↓ 20 - 40 %
- Postoperative VAS: ↓ 10-15 %
- Opioid related AE: ↓ 15 – 25 %

Adverse events:

- Severe bleeding: 0 to 1.7%
- Renal insufficiency in cardiac patients: 0 % to 1.4%

Multimodal Analgesics for Postoperative Pain



Periarticular Injection for TKA

- 64 patients, RCT:
 - Study: Ropivacaine (400 mg) + Ketorolac (30 mg) + morphine (5 mg) + epinephrine = volume 100 mls
 - Placebo
- Methods:
 - 20 mls: Injected prior to implant into the posterior part of the capsule and ligaments.
 - 20 mls: Injected into the quadriceps mechanism
 - 60 mls injected into the subcutaneous tissue
- Standard surgery and anesthetic
- Results:
 - Study: 24 hour PCA: 25 mg
 - Placebo: 24 hour PCA: 45 mg ($P < 0.001$)
- No long term benefit

Busch CA et al: JBJS 2006; 88: 959-963

Local infiltration analgesia in joint replacement: the evidence and recommendations for clinical practice

H. KEHLET^{1,2} and L. Ø. ANDERSEN³

Recent article

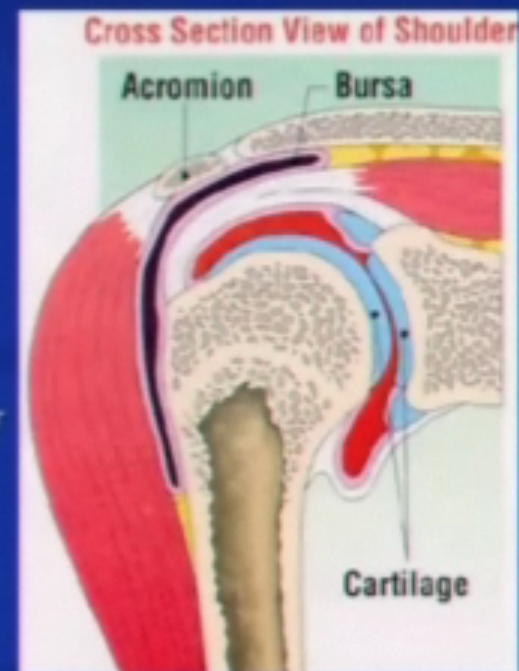
Review

- 14 clinical trials for TKA:
 - Relative small sample size ($n < 100$), non-RCT
 - ↓ pain scores in the immediate postop period
 - No long term benefit
 - The role of continuous catheters needs to be examined
- 6 clinical trials for THA:
 - Not uniform to make conclusion
 - When oral multimodal analgesia is used, probably local anesthetic infiltration **does not** add any benefit
 - No difference in hospital discharge time

Acta Anaesthesiol Scand 2011

Intra-Articular Injections into Shoulder

- From 1978, the concept of injection of steroids, Morphine, local anesthetics into the shoulder has been used for shoulder dislocation, bursitis and capsulitis.
- Reports of IA injection of local anesthetic, Morphine for shoulder scope surgery was reported in 2000 in *Reg Anesth and Pain Med* by Cleveland Clinic in 39 patients undergoing rotator cuff repair in a RCT demonstrating that 0.25% Bupivacaine and Morphine provided improved postoperative analgesia.

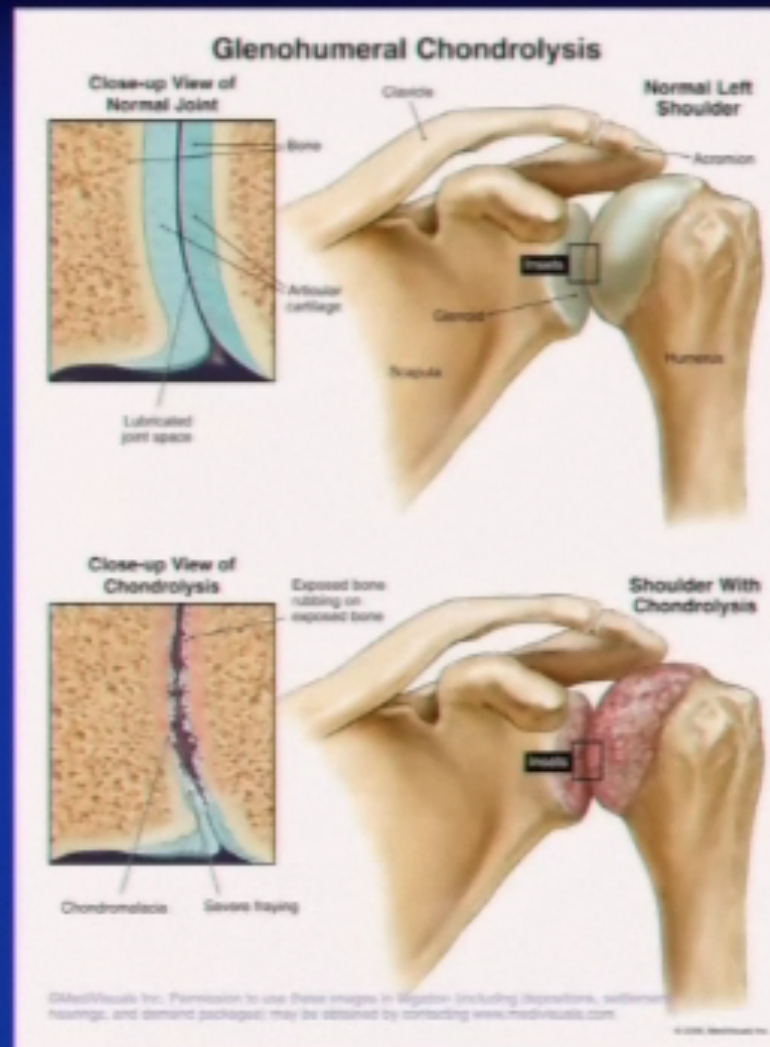

Glenohumeral Chondrolysis

- First published in 2007 by Hansen et al in Am J Sports Med.
- 12 cases of chondrolysis after shoulder surgery

Signs/Symptoms:

- ↑ pain
- Crepitus and ↓ ROM
- Glenohumeral joint space narrowing on X-ray



Severe chondrolysis after shoulder arthroscopy: A case series

J of Shoulder and
Elbow surgery 2009

David S. Bailie, MD^a, Todd Ellenbecker, DPT, MS, SCS, OCS, CSCS^{b,*}

23 patients who developed severe chondrolysis and ALL of them
had IA bupivacaine + epi infusion for 48 hours.

Young patients with shoulder chondrolysis following arthroscopic shoulder surgery treated with total shoulder arthroplasty

J of Shoulder
and Elbow
surgery 2008

Jonathan C. Levy, MD,^a Nazeem A. Virani, MD,^b Mark A. Frankle, MD,^c Derek Cuff, MD,^d
Derek R. Pupello, MBA,^b and Jeff A. Hamelin, PA-C,^c Fort Lauderdale, Tampa, and Venice, FL

Glenohumeral Chondrolysis After Shoulder Arthroscopy

Case Reports and Review of the Literature

Damon H. Petty,^{1,*} MD, Laith M. Jazrawi,² MD, Lance S. Estrada,³ MD,
and James R. Andrews,⁴ MD

From ¹Petty Orthopaedics and Sports Medicine, Nashville, Tennessee, ²NYU Hospital
for Joint Diseases, New York, New York, the ³University of Alabama, Birmingham, Department
of Orthopaedics, Birmingham, Alabama, and the ⁴American Sports Medicine Institute,
Birmingham, Alabama

Chondrolysis After Continuous Intra-Articular Bupivacaine Infusion: An Experimental Model Investigating Chondrotoxicity in the Rabbit Shoulder

Andreas H. Gomoll, M.D., Richard W. Kang, B.S., James M. Williams, Ph.D.,
Bernard R. Bach, M.D., and Brian J. Cole, M.D., M.B.A.



- 3 Groups: n=30
 - Saline pH at 5.9
 - Bupivacaine 0.25% with pH at 5.7
 - Bupivacaine 0.25% + Epi at pH 4.0
- A catheter was placed in the shoulder joint
- Randomized solution infused at 210 μ l/hr for 48h
- Histological staining was carried out on all shoulders

Chondrolysis After Continuous Intra-Articular Bupivacaine Infusion: An Experimental Model Investigating Chondrotoxicity in the Rabbit Shoulder

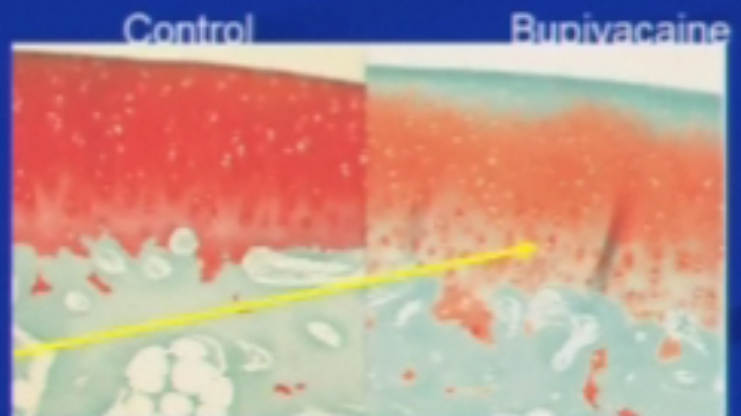
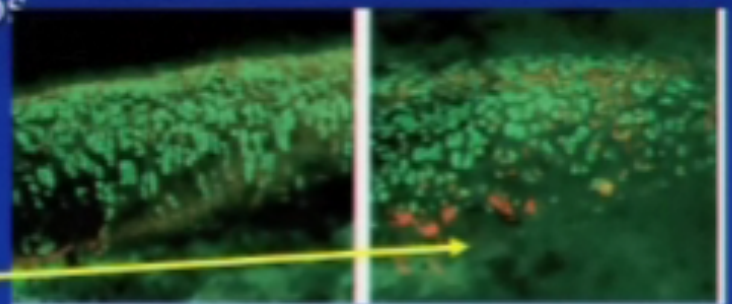
Andreas H. Gomoll, M.D., Richard W. Kang, B.S., James M. Williams, Ph.D.,
Bernard R. Bach, M.D., and Brian J. Cole, M.D., M.B.A.

- ↓ sulfate uptake in bup groups
an indication of **cell viability**

- Red indicates dead chondrocytes

- Live/Dead cell assay: ↓ cell viability by 32% in bup

- Loss of glycosaminoglycan matrix



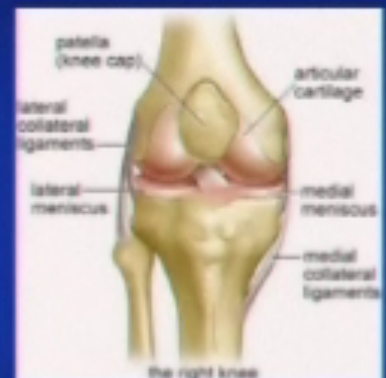Cartilage topography: Knee vs Shoulder

■ Knee topography with MRI evaluation:

■ Cartilage surface: 0.22 mm

■ Subchondral surface: 0.14 mm

Cohen Z et al: Osteoarthritis and cartilage 1999

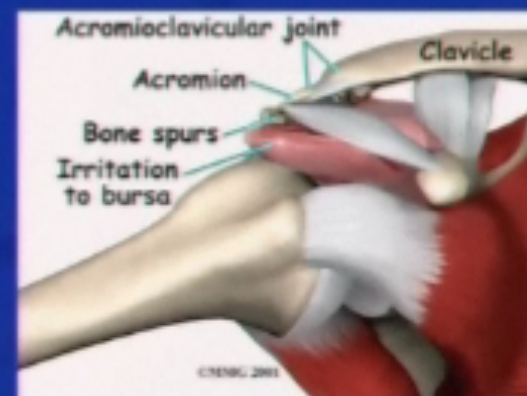


■ Shoulder topography with MRI evaluation:

■ Humerus: 1.2 mm

■ Glenoid cavity: 1.7 mm

Graichen H et al: Osteoarthritis & cartilage 2003

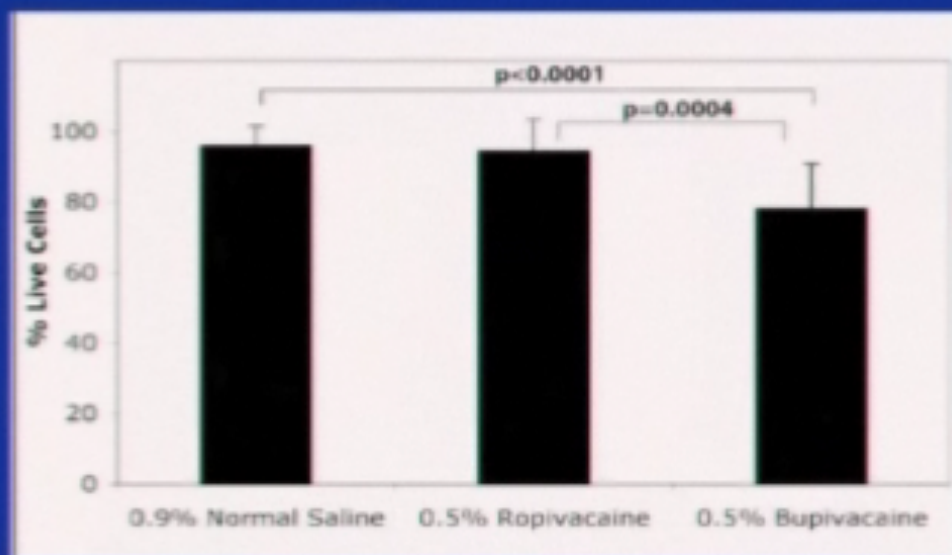


Comparison of Ropivacaine and Bupivacaine Toxicity in Human Articular Chondrocytes

JBJS 2008

By Samantha L. Piper, BA, and Hubert T. Kim, MD, PhD

Exposure of local anesthetics for 30 minutes to human chondrocytes.



Bupivacaine is toxic to cartilage when exposed possibly via a nitric oxide pathway

IA NSAID administration in the knee

- RCT n=80, IA ketorolac > 1 mg of morphine > saline in terms of analgesia

Calmet J et al: *Knee Surg Sports Traumatol Arthrosc* 2004.

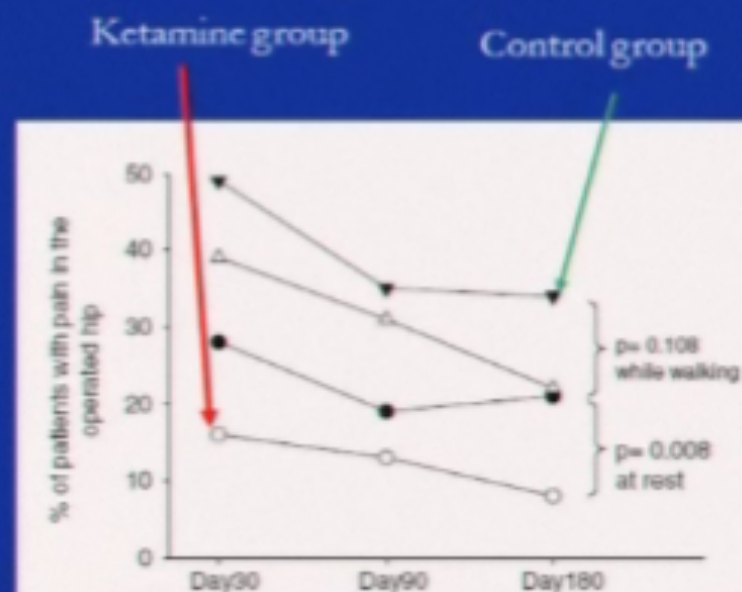
- Ketorolac administered IA has been demonstrated to reduce PGE₂ local tissue site (Synovial). However, there was an ↑ glycerol (a marker of cell damage) may indicate toxicity of NSAID on synovial tissue.

Ketamine as a Multimodal Agent

- In RCT, perioperative ketamine use:
 - Has led to opioid dose ↓ by 30%
 - ↓ of chronic post surgical pain syndromes
 - Lavand'homme P et al: *Anesthesiology* 2005; 103: 813-20
- Dose:
 - 0.1 - 0.5 mg/ kg bolus ± 0.1- 0.5 mg/kg/hr infusion
- Side effects:
 - < 10% of patients had complains of psycho-cognitive effects.

The Early and Delayed Analgesic Effects of Ketamine After Total Hip Arthroplasty: A Prospective, Randomized, Controlled, Double-Blind Study

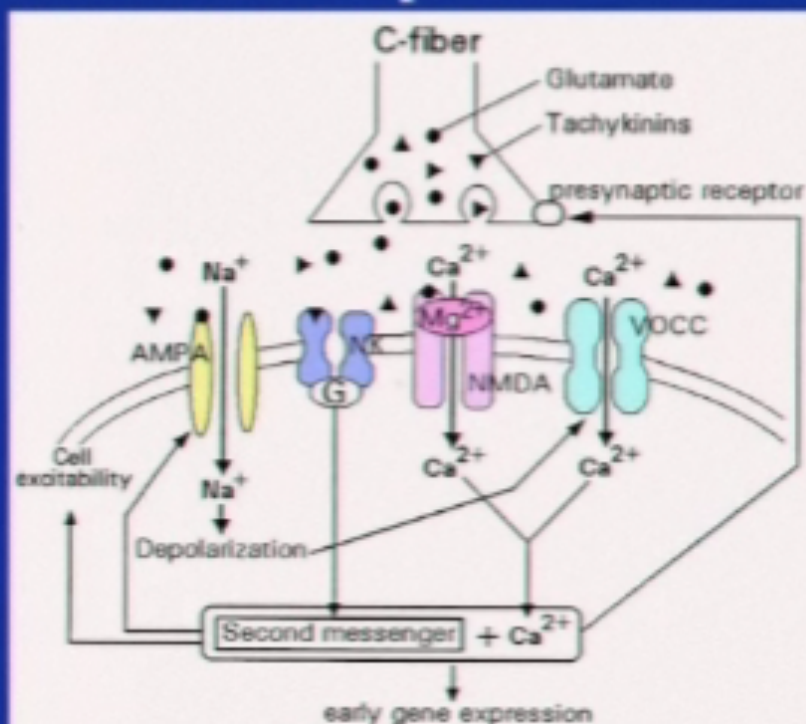
- RCT, 159 patients
- GA + postop multimodal analgesia
- Outcome:
 - ↓ Morphine consumption in ketamine group
 - Earlier rehabilitation milestone
 - ↓ Chronic pain 6 months



Remerand F et al: Anesth Analg 2009; 109: 1963

Role of Magnesium as NMDA antagonist

- Suggested mechanism include the inhibition of calcium influx antagonism of NMDA receptors
- Also inhibition of dorsal horn NMDA receptor



Herroeder S et al: Anesthesiology 2011

The Analgesic Effects of Perioperative Gabapentin on Postoperative Pain: A Meta-Analysis

Robert W. Hurley, M.D., Ph.D., Steven P. Cohen, M.D.,
Kayode A. Williams, M.D., Andrew J. Rowlingson, B.A., and
Christopher L. Wu, M.D.

Reg Anesth Pain Med 2006

- 12 RCT of 896 patients
- Dose of gabapentin: 300 – 1200 mg
- Outcome:
 - ↓ Pain scores at 24 hours
 - ↓ Opioid use in the postoperative period
 - ↑ Sedation in the postoperative period
 - No difference in serious adverse events
- Similar results in a review of gabapentinoids in 2007 by Elina Tiippana et al from Finland published in *Anesth & Analg*

Mechanism of Analgesia

- Gabapentin and Pregabalin bind to the alpha-2-delta sub-unit of the N-type voltage gated calcium channel
 - Same mechanism of action whether it is neuropathic pain or inflammatory pain (post-surgical)
- This binding results in ↓ release of
 - Substance P, Calcitonin Gene-related peptide
 - Glutamate
- Little effect on normal neuronal tissue, but only effective in sensitized neuronal tissue

Pregabalin and Dexamethasone for postoperative pain control: RCT in THA

- 120 patients, 3 groups received preop:
 - Placebo: Oral placebo + IV placebo
 - Pregabalin: 300 mg Pregabalin + placebo IV
 - Pregabalin +dex: 300 mg pregabalin + IV 8 mg dexamethasone
- Spinal anesthetic + Acetaminophen
- Post-op: PCA morphine + acetaminophen
- Outcome:
 - 24 hour morphine consumption
 - VAS
 - Nausea and vomiting

Pregabalin and Dexamethosone for postoperative pain control: RCT in THA

	Placebo	Pregabalin	Pregabalin + dex
24 h morphine (mg)	47 ± 28 * ↑	24 ± 14	25 ± 19
% vomiting	16	25	4.7 * ↓
Sedation (0-3 scale)	0.3	0.9 * ↑	0.45

No added analgesic benefit in combination therapy

Pregabalin and dexamethasone in combination with paracetamol for postoperative pain control after abdominal hysterectomy. A randomized clinical trial *Acta Anaesth Scand 2009*

O. MATHIESEN¹, M. L. RASMUSSEN², G. DIERKING², K. LECH², K. L. HILSTED¹, J. S. FOMEGAARD¹, G. LOSE³ and J. B. DAHL¹
¹Department of Anaesthesia, Copenhagen University Hospital, Glostrup, Denmark, ²Department of Anaesthesia, Regional Hospital Herning, Herning, Denmark and ³Department of Gynaecology, Copenhagen University Hospital, Glostrup, Denmark

No difference in Pain Scores or Opioid Consumption

Effect of Pregabalin on Preoperative Anxiety and sedation levels

108 Patients with dose from 75, 150, 300 mg preoperatively administered 1 hour before minor surgical procedures showed *no benefit in pain scores*

White PF et al: *Anesth Analg* 2008

Acetaminophen: Mechanisms of Action

- Exact mechanism of action still unclear¹
- Analgesic effect
 - Inhibits the synthesis of prostaglandins in the CNS (central acting) and peripherally blocks pain impulse generation²
 - Unlike NSAIDs, not a strong peripheral COX inhibitor¹
 - Proposed serotonergic (5-HT) mechanism³
- Antipyretic effect²
 - Inhibition of hypothalamic heat-regulating center
 - No anti-inflammatory effects

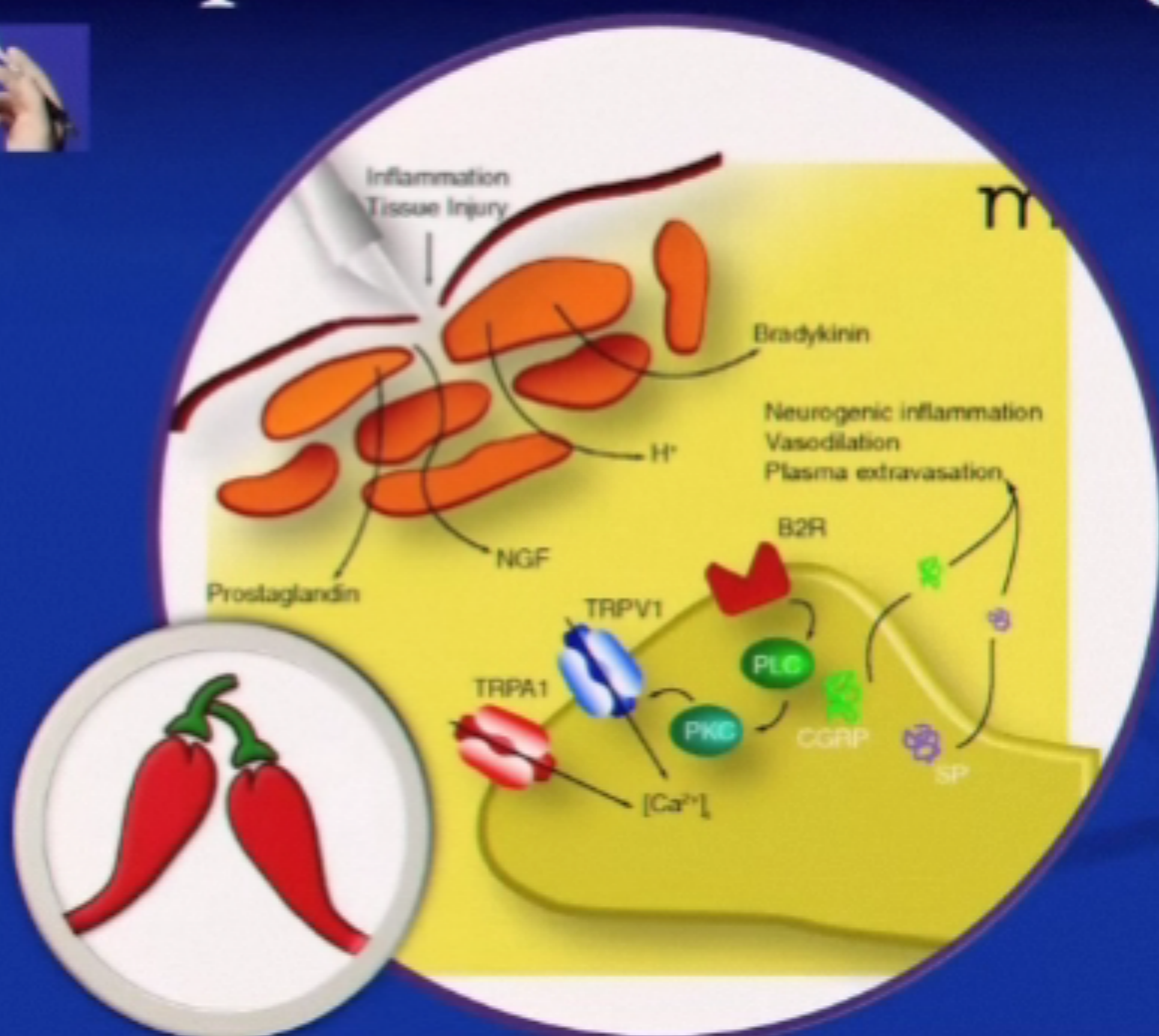
1. Aronoff DF, et al. *Clin Pharmacol Ther.* 2006;79:9-19.

2. Malaise et al. *Future Neurol* 2007;2:673-688.

3. Bonnefont J, et al. *Mol Pharmacol.* 2007;71:407-415.



Peripheral nerve endings



TRPV drugs: Capsaicin

- Cause release of substance P and depletion of it----- and the analgesia is via the calcium dependent desensitization
- Capsaicin was installed into the wound after hernia repair and sensory function tested 2 years postop for allodynia and hyperalgesia:
 - Capsaicin group: 25% ($p=0.2$)
 - Control group: 6%
- Long term safety clinical trials need to be carried out