Clinical Implications of Neuraxial Anesthesia in the Parturient with Scoliosis

James Y. Ko, MD, MPH

Lisa R. Leffert, MD

Scoliosis can pose challenges to the initiation and function of neuraxial anesthetics. We reviewed the available literature exploring neuraxial techniques in parturients with uncorrected or corrected (i.e., surgically instrumented) scoliosis. The 22 articles reported 117 attempted neuraxial procedures (uncorrected n = 24 and corrected n = 93). Of these procedures, 79% of uncorrected patients and 69% of corrected patients were successfully managed with neuraxial anesthesia. Procedures were typically more challenging in corrected patients; 90% of all reported difficulties in this subgroup involved epidural anesthetics. Complications were reported in 3 of 103 patients. We provide suggestions for optimizing efficacy of neuraxial techniques in these patients.

(Anesth Analg 2009;109:1930–4)

Scoliosis, defined as a lateral curvature of the spine, is present in approximately 2% of the general population,[1] with the prevalence in women twice that in men.[2] The cause of most scoliosis is unknown.[3] The decision to treat scoliosis through conservative means (e.g., bracing) as opposed to corrective surgery depends, in part, on the degree of curvature (described as the "Cobb angle") and the rate of curve progression.[4]

Whether corrected or uncorrected, the anatomic anomalies of scoliosis can hinder the placement and effective functioning of neuraxial anesthetics. Despite these difficulties, successful spinal and epidural anesthetics have been reported in parturients with scoliosis.[5–7] Epidural analgesia has also been described as an effective means of providing postoperative analgesia after scoliosis surgery.[8]

The incidence of operative delivery is higher in parturients with scoliosis than parturients without this diagnosis.[9] Neuraxial anesthesia is currently the technique of choice for operative deliveries.[10] Understanding the associated anatomic anomalies and challenges of neuraxial anesthesia in this patient population is essential to those providing analgesia/anesthesia for obstetric patients.

This review summarizes the literature describing neuraxial techniques in parturients with corrected (i.e., surgically instrumented or fused) and uncorrected scoliosis and presents strategies for addressing their anesthetic needs.

From the Division of Obstetric Anesthesia, Department of Anesthesia, Critical Care, and Pain Medicine, Massachusetts General Hospital, Boston, Massachusetts.

Accepted for publication August 7, 2009.

Supported by departmental funds.

Address correspondence and reprint requests to Lisa R. Leffert, MD, Division of Obstetric Anesthesia, Department of Anesthesia, Critical Care, and Pain Medicine, Massachusetts General Hospital, 55 Fruit St., Boston, MA 02114. Address e-mail to lleffert@partners.org.

DOI: 10.1213/ANE.0b013e3181bc3584

LITERATURE REVIEW

To identify relevant literature, we searched Ovid MEDLINE (1950–2008) using the following terms, alone and in combination: "scoliosis," "pregnancy," "epidural," "spinal," "neuraxial anesthesia," "Harrington rods," "spinal fusion," and "back surgery." Searches were limited to English-language articles. We retrieved appropriate articles and reviewed the associated bibliographies to identify additional relevant articles.

We identified 22 articles involving neuraxial analgesia/anesthesia in parturients with scoliosis (Table 1), including 19 case reports,[5–7,11–26] 2 retrospective reviews,[27,28] and 1 prospective observational study.[29] Overall, 117 neuraxial anesthetic procedures were attempted in 103 patients (24 procedures in uncorrected patients and 93 in corrected patients). Despite the difficulties described below, more than two-thirds of the patients in both groups were successfully managed with neuraxial techniques (Table 2).

In the uncorrected group, the success rates for epidural and intrathecal anesthetics (i.e., single-shot spinal and continuous spinal anesthesia) were similar (80% and 73%, respectively). The most common causes of block inadequacy in this group were patchy (8%), asymmetric (8%), or unilateral (8%) analgesia. The inability to place a neuraxial anesthetic (referred to as "failed placements") or multiple attempts at placement were each cited 4% of the time.

Of the 59 cases of block difficulty or inadequacy reported in corrected patients, 90% involved epidural anesthesia. The challenges in corrected patients included inability to place neuraxial block (22%), multiple placement attempts (13%), patchy analgesia (10%), excessive

Table 1. Reports of Neuraxial Anesthesia in Scoliotic Parturients

Author	Patients *n*	Total neuraxial procedures *n*	Total neuraxial procedures by anesthetic technique *n*				
			Epidural	Continuous spinal	Single shot spinal	Combined spinal epidural	Other
Uncorrected							
Carlson et al.[5]	1	1	1				
Bozeman and Chandra[11]	1	2	1		1		
Moran and Johnson[7]	1	2	1	1			
Douglas[6]	1	1			1		
Smith et al.[a29]	24	16	7	7		2	
Butwick and Carvalho[12]	1	2			1	1	
Corrected							
Hubbert[17]	17	18	17		1		
Feldstein and Ramanathan[14]	3	3	3				
Crosby and Halpern[27]	8	13	13				
Daley et al.[28]	18	21	21				
Howard and Anderson[16]	1	1	1				
Kardash et al.[18]	1	2			2		
Pascoe et al.[22]	1	2	1		1		
Silva and Popat[23]	1	2				2	
Lee et al.[19]	1	3	3				
Sudunagunta et al.[24]	1	1					1 CE
Ho et al.[15]	1	1	1				
Suelto and Shaw[25]	1	1					1 PVB
Yeo and French[26]	1	3			3		
Smith et al.[a29]	16	17		12	4	1	
Moeller-Bertram et al.[20]	1	3	2				1 CE
Okutomi et al.[21]	1	1		1			
Costello and Balki[13]	1	1			1		
Overall	103	117	72	21	15	6	3

CE = caudal epidural; PVB = paravertebral block.

[a] Study that included both uncorrected and corrected patients.

Table 2. Outcomes of Neuraxial Procedures

	Total	Epidural	Continuous spinal	Single shot spinal	Combined spinal epidural	Other[a]
Uncorrected						
Procedures	24	10	8	3	3	0
Successful	19	8	7	1	3	0
Complications	0	0	0	0	0	0
Corrected						
Procedures	93	62	13	12	3	3
Successful	64	41	9	9	2	3
Complications	2[b]	2[b]	0	0	0	0

[a] Two caudal epidurals, 1 paravertebral block.

[b] Two cases of persistent lower back pain of unclear etiology after epidural placement.

local anesthetic requirements (9%), and inadequate analgesia or unintentional dural puncture (4% each). Many of these difficulties did not ultimately preclude eventual adequate neuraxial blockade; in many instances, inadequacies were overcome through maneuvers such as repositioning and additional anesthetic administration. As such, 64 of 93 neuraxial procedures (69%) in the corrected group were ultimately successful. Within the corrected group, the success rate of spinal techniques was similar to that of epidural techniques (72% and 66%, respectively).

There was 1 reported case of postdural puncture headache (PDPH) after continuous spinal analgesia; however, it is unclear whether this parturient had corrected or uncorrected scoliosis, or whether this technique was chosen *a priori* or after unintentional dural puncture. The only other reported complications were 2 cases of persistent low back pain of unknown etiology in corrected patients after epidural analgesia.

DISCUSSION

Despite reports of successful neuraxial anesthesia in parturients with uncorrected and corrected scoliosis, our review of the literature suggests that rates of

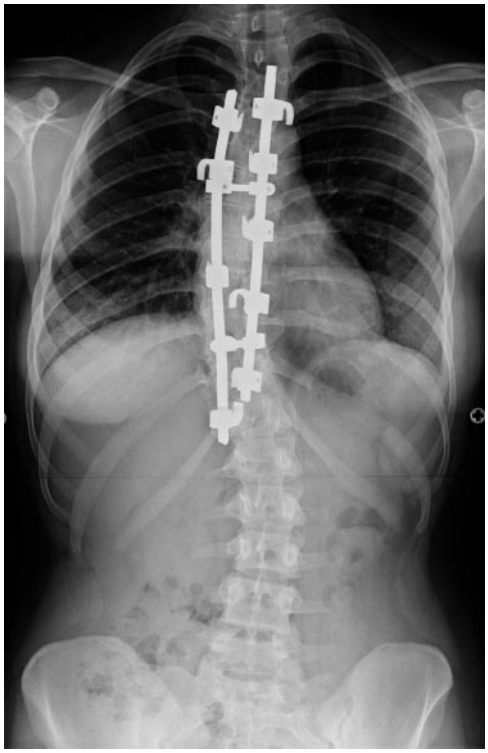

Figure 1. Thoracolumbar scoliosis with correction of the thoracic region with Harrington rods. The lumbar portion remains uncorrected, and the midline deviates toward the convexity of the curve in this region. The interlaminar space is slightly larger on the convex aspect of the curve.

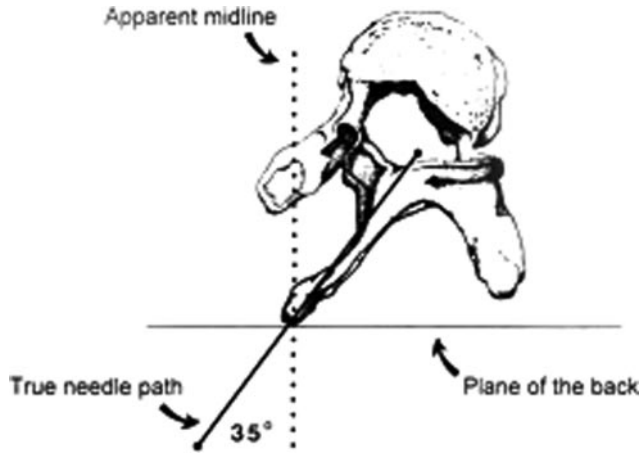

Figure 2. The neuraxial needle should be oriented toward the convexity of the scoliotic curve as it is advanced from the interspinous space toward the midpoint of the posterior epidural space (see arrow). Reproduced with permission from Crosby ET. Disorders of the vertebral column. In: Gambling DR, Douglas MJ, McKay RSF, eds. Obstetric anesthesia and uncommon disorders. 2nd ed. Cambridge: Cambridge University Press, 2008:139.

inadequate or failed analgesia/anesthesia in these patients are an order of magnitude higher than in the general parturient population.[30] However, alternatives for labor analgesia (i.e., systemic opioid analgesia) have been shown to provide less-effective pain control than neuraxial blocks.[31] In addition, the risk of maternal mortality in the setting of general anesthesia for cesarean delivery remains higher than that of neuraxial anesthesia, although the difference between the two is decreasing.[32] Therefore, it is important to identify strategies to minimize the challenges of neuraxial techniques in this population and to choose appropriate patients to receive these anesthetics.

In both corrected and uncorrected scoliosis, there is distortion or absence of the spinous processes, key landmarks for placement of neuraxial anesthetics. The rotation of uncorrected scoliosis distorts surface anatomy, and palpation is not always a reliable means of orientation; there is deviation of the midline of the epidural space toward the convex aspect of the scoliotic curve relative to the spinous processes (Fig. 1).[3] To facilitate neuraxial placement in uncorrected patients, we recommend that the needle be oriented toward the convexity of the curve where the interlaminar spaces are generally larger (Fig. 2).[3]

In corrected patients, distraction rod insertion involves decortication of vertebrae and removal of spinous processes along the extent of the curve.[33] Scar tissue and bone grafts can hinder the entry of neuraxial needles into the desired space.[27] Even if the surgical site is avoided, there is a higher incidence of retrolisthesis and spondylolisthesis caudal to the area of fusion because of an increased rate of degenerative change compared with nonscoliotic patients.[34] Furthermore, fusions can extend as low as L4 or L5 in 20% of patients, which limits the interspaces that may be more easily accessed.[3] Finally, postoperative adhesions or obliteration of the epidural space can interfere with local anesthetic spread and increase the chance of inadvertent dural puncture.[19,35] Epidural placement either above or below the site of previous surgery (e.g., caudal epidural anesthesia) has been shown to be an effective alternative.[20,24,36] Subarachnoid block at the L5-S1 level, the widest interlaminar space in the spine, may also be feasible.[18]

Operative and radiographic reports may be helpful in assessing the location and extent of vertebral involvement; however, such data may not reliably facilitate placement because, even in healthy volunteers, anesthesiologists incorrectly identify the lumbar interspaces by palpation 71% of the time.[37] Alternatively, ultrasonography may be a helpful tool in defining the relevant anatomy at the time of initiation of neuraxial anesthesia.[26,38–41]

To overcome unilateral blockade, which may result from rotation of the scoliotic spine, the patient can be placed in the lateral position with the less-blocked side in the dependent position.[42] In some cases, a technique using a large-volume/low-concentration local anesthetic solution may overcome a unilateral block. Augmentation of an asymmetric block by placement of an additional epidural catheter at the level of the unblocked dermatome has also been described.[43] However, this technique confers the theoretical risk of catheter intertwining with, shearing, or avulsing the *in situ* catheter.

Careful consideration of the timing and mode of anesthesia for labor and delivery in patients with corrected and uncorrected scoliosis is essential. Because spinal and epidural procedures may take longer in both corrected and uncorrected scoliosis patients, their utility in an urgent situation may be limited. We recommend placing the epidural catheter early in the course of labor and delivery to facilitate patient cooperation and allow ample time for troubleshooting the technique. We advocate confirming that the epidural catheter is correctly sited in the epidural space and that an adequate sensory level can be achieved if necessary. This may be done by initiating the block with incremental doses of dilute local anesthetic solution.

Alternatives to traditional epidural analgesia can also be considered. An intrathecal catheter can be placed using standard epidural equipment. There is inconsistent evidence that placing an intrathecal catheter after unintentional dural puncture with a large-bore needle may reduce the risk of PDPH.[44,45] Performance of sequential spinal analgesia blocks with small-gauge (24- to 27-gauge) pencil-point needles is also an option for labor analgesia (and possibly subsequent operative anesthesia) in this group and likely confers a decreased risk of PDPH. Combined spinal-epidural analgesia with morphine (100 μg) added to the intrathecal injection of bupivacaine and fentanyl can reduce the rate of breakthrough pain episodes during subsequent epidural analgesia by 50%.[46] Dural puncture with a 25-gauge spinal needle performed immediately before initiation of epidural anesthesia with bupivacaine and fentanyl seems to improve onset, sacral spread, and bilateral analgesia, even in the absence of intrathecal drug administration, and may help confirm correct placement of the epidural needle in the epidural space.[47] Regardless of the specific neuraxial anesthetic technique chosen, the increased incidence of block failure mandates developing plans for possible general anesthesia in these patients. We advocate anesthesia consultation well in advance of delivery. This also allows for review of operative reports and imaging, multidisciplinary planning, and patient education regarding the potential difficulties that may be encountered.

Our current understanding of neuraxial analgesia/anesthesia in patients with scoliosis is limited by the quality and quantity of the published data. There may be reporting bias; our data may overestimate (or underestimate) the true incidence of ineffective neuraxial anesthetics in this population. The choice of the specific neuraxial anesthetic technique used in the reported cases was made by the clinicians caring for these patients and may not be representative of other practice settings. Finally, the vocabulary used by the authors of these reports to describe inadequate anesthesia and analgesia (e.g., "patchy" and "asymmetric") and technically challenging procedures (e.g., "multiple attempts at placement" and "difficult placement") are not precisely defined and may lead to inappropriate classification of similar experiences. Although we anticipated that spinal techniques would be more effective in the corrected population than would epidural techniques, this conclusion cannot be drawn from these reported cases. Randomized controlled studies of neuraxial anesthesia in parturients with corrected and uncorrected scoliosis are required to further define efficacy and optimal techniques.

ACKNOWLEDGMENTS

The authors are indebted to Edward Lowenstein, MD, for his thoughtful comments and guidance in the preparation of the manuscript.

REFERENCES

1. Rinsky LA, Gamble JG. Adolescent idiopathic scoliosis. West J Med 1988;148:182–91
2. Carter OD, Haynes SG. Prevalence rates for scoliosis in US adults: results from the first National Health and Nutrition Examination Survey. Int J Epidemiol 1987;16:537–44
3. Preston R, Crosby ET. Musculoskeletal disorders. In: Chestnut DH, Polley LS, Tsen LC, Wong CA, eds. Obstetric anesthesia: principles and practice. 4th ed. Philadelphia: Mosby-Elsevier, 2009:1035–52
4. Maruyama T, Takeshita K. Surgical treatment of scoliosis: a review of techniques currently applied. Scoliosis 2008;3:6
5. Carlson DW, Englelman DR, Bart AJ. Epidural anesthesia for cesarean section in kyphoscoliosis. Anesth Analg 1978;57:125–8
6. Douglas MJ. Unusual regional block. Can J Anaesth 1995;42: 362–3
7. Moran DH, Johnson MD. Continuous spinal anesthesia with combined hyperbaric and isobaric bupivacaine in a patient with scoliosis. Anesth Analg 1990;70:445–7
8. Borgeat A, Blumenthal S. Postoperative pain management following scoliosis surgery. Curr Opin Anaesthesiol 2008;21:313–6
9. Cochran T, Irstam L, Nachemson A. Long-term anatomic and functional changes in patients with adolescent idiopathic scoliosis treated by Harrington rod fusion. Spine 1983;8:576–84
10. American Society of Anesthesiologists Task Force on Obstetric Anesthesia. Practice guidelines for obstetric anesthesia: an updated report by the American Society of Anesthesiologists Task Force on Obstetric Anesthesia. Anesthesiology 2007;106:843–63
11. Bozeman PM, Chandra P. Unilateral analgesia following epidural and subarachnoid block. Anesthesiology 1980;52:356–7
12. Butwick AJ, Carvalho B. Neuraxial anesthesia for cesarean delivery in a parturient with type 1 von Willebrand disease and scoliosis. J Clin Anesth 2007;19:230–3
13. Costello JF, Balki M. Cesarean delivery under ultrasound-guided spinal anesthesia, in a parturient with poliomyelitis and Harrington instrumentation. Can J Anaesth 2008;55:606–11
14. Feldstein G, Ramanathan S. Obstetrical lumbar epidural anesthesia in patients with previous posterior spinal fusion for kyphoscoliosis. Anesth Analg 1985;64:83–5
15. Ho AM, Ngan Kee WD, Chung DC. Should laboring parturients with Harrington rods receive lumbar epidural analgesia? Int J Gynaecol Obstet 1999;67:41–3
16. Howard R, Anderson W. Subdural catheterization and opiate administration in a patient with Harrington rods. Can J Anaesth 1990;37:712
17. Hubbert CH. Epidural anesthesia in patients with spinal fusion. Anesth Analg 1985;64:843
18. Kardash K, King BW, Datta S. Spinal anaesthesia for caesarean section after Harrington instrumentation. Can J Anaesth 1993;40:667–9
19. Lee YS, Bundschu RH, Moffat EC. Unintentional subdural block during labor epidural in a parturient with prior Harrington rod insertion for scoliosis. Case report. Reg Anesth 1995;20:159–62
20. Moeller-Bertram T, Kuczkowski KM, Ahadian F. Labor analgesia in a parturient with prior Harrington rod instrumentation: is caudal epidural an option? Ann Fr Anesth Reanim 2004;23: 925–6
21. Okutomi T, Saito M, Koura M, Hoka S. Spinal anesthesia using a continuous spinal catheter for cesarean section in a parturient with prior surgical correction of scoliosis. J Anesth 2006;20: 223–6

22. Pascoe HF, Jennings GS, Marx GF. Successful spinal anesthesia after inadequate epidural block in a parturient with prior surgical correction of scoliosis. Reg Anesth 1993;18:191–2
23. Silva TS, Popat MT. Combined spinal-epidural anesthesia in parturient with Harrington rods. Reg Anesth 1994;19:360
24. Sudunagunta S, Eckersall SJ, Gowrie-Mohan S. Continuous caudal analgesia in labour for a patient with Harrington rods. Int J Obstet Anesth 1998;7:128–30
25. Suelto MD, Shaw DB. Labor analgesia with paravertebral lumbar sympathetic block. Reg Anesth Pain Med 1999;24:179–81
26. Yeo ST, French R. Combined spinal-epidural in the obstetric patient with Harrington rods assisted by ultrasonography. Br J Anaesth 1999;83:670–2
27. Crosby ET, Halpern SH. Obstetric epidural anaesthesia in patients with Harrington instrumentation. Can J Anaesth 1989;36:693–6
28. Daley MD, Rolbin SH, Hew EM, Morningstar BA, Stewart JA. Epidural anesthesia for obstetrics after spinal surgery. Reg Anesth 1990;15:280–4
29. Smith PS, Wilson RC, Robinson AP, Lyons GR. Regional blockade for delivery in women with scoliosis or previous spinal surgery. Int J Obstet Anesth 2003;12:17–22
30. Katircioglu K, Hasegeli L, Ibrahimhakkioglu HF, Ulusoy B, Damar H. A retrospective review of 34,109 epidural anesthetics for obstetric and gynecologic procedures at a single private hospital in Turkey. Anesth Analg 2008;107:1742–5
31. Halpern SH, Leighton BL, Ohlsson A, Barrett JF, Rice A. Effect of epidural vs parenteral opioid analgesia on the progress of labor: a meta-analysis. JAMA 1998;280:2105–10
32. Hawkins JL, Chang J, Palmer SK, Callaghan WM, Gibbs CP. Anesthesia-related mortality in the United-States 1997–2002. Anesthesiology 2008;109:A206
33. Winter RB. Posterior spinal fusion in scoliosis: indications, technique, and results. Orthop Clin North Am 1979;10:787–800
34. Sponseller PD, Cohen MS, Nachemson AL, Hall JE, Wohl ME. Results of surgical treatment of adults with idiopathic scoliosis. J Bone Joint Surg Am 1987;69:667–75
35. LaRocca H, Macnab I. The laminectomy membrane. Studies in its evolution, characteristics, effects and prophylaxis in dogs. J Bone Joint Surg Br 1974;56B:545–50
36. Sharrock NE, Urquhart B, Mineo R. Extradural anaesthesia in patients with previous lumbar spine surgery. Br J Anaesth 1990;65:237–9
37. Broadbent CR, Maxwell WB, Ferrie R, Wilson DJ, Gawne-Cain M, Russell R. Ability of anaesthetists to identify a marked lumbar interspace. Anaesthesia 2000;55:1122–6
38. Arzola C, Davies S, Rofaeel A, Carvalho JC. Ultrasound using the transverse approach to the lumbar spine provides reliable landmarks for labor epidurals. Anesth Analg 2007;104:1188–92
39. Chen CP, Tang SF, Hsu TC, Tsai WC, Liu HP, Chen MJ, Date E, Lew HL. Ultrasound guidance in caudal epidural needle placement. Anesthesiology 2004;101:181–4
40. Grau T, Leipold RW, Conradi R, Martin E, Motsch J. Efficacy of ultrasound imaging in obstetric epidural anesthesia. J Clin Anesth 2002;14:169–75
41. McLeod A, Roche A, Fennelly M. Case series: ultrasonography may assist epidural insertion in scoliosis patients. Can J Anaesth 2005;52:717–20
42. Seow LT, Lips FJ, Cousins MJ. Effect of lateral posture on epidural blockade for surgery. Anaesth Intensive Care 1983;11: 97–102
43. Schachner SM, Abram SE. Use of two epidural catheters to provide analgesia of unblocked segments in a patient with lumbar disc disease. Anesthesiology 1982;56:150–1
44. Ayad S, Demian Y, Narouze SN, Tetzlaff JE. Subarachnoid catheter placement after wet tap for analgesia in labor: influence on the risk of headache in obstetric patients. Reg Anesth Pain Med 2003;28:512–5
45. Warwick WI, Neal JM. Beyond spinal headache: prophylaxis and treatment of low-pressure headache syndromes. Reg Anesth Pain Med 2007;32:455–61
46. Vasudevan A, Snowman CE, Sundar S, Sarge TW, Hess PE. Intrathecal morphine reduces breakthrough pain during labour epidural analgesia. Br J Anaesth 2007;98:241–5
47. Cappiello E, O'Rourke N, Segal S, Tsen LC. A randomized trial of dural puncture epidural technique compared with the standard epidural technique for labor analgesia. Anesth Analg 2008;107:1646–51