

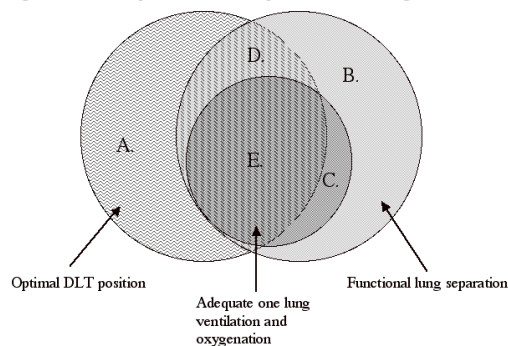
Objectives:

1. Explain common and uncommon causes of lung separation failure and present strategies for success
2. Describe the clinical implications of recent design modifications for double-lumen tubes and bronchial blockers
3. Discuss approaches to lung separation in patients with difficult airways

The big picture

“Making it work” in the context of one-lung anesthesia means that lung collapse is both complete and well tolerated by the patient. Although the concept is simple, a number of clinical details frequently make the difference between success and failure. During this lecture, the terms “lung isolation” and functional “lung separation” will be used interchangeably. Both imply the ability to ventilate one lung independent of the other (airtight seal) or to restrict passage of blood or fluids (watertight seal) from one lung to another. One-lung anesthesia requires not only functional lung separation but also adequate one-lung ventilation (OLV) and oxygenation. **Figure 1** depicts the three clinical endpoints integral to one-lung anesthesia:

Figure 1: Overlap of clinical endpoints in one-lung anesthesia



- Optimal position of double-lumen tube or bronchial blocker
- Functional lung separation
- Adequate ventilation and oxygenation

Various overlapping subsets of these conditions can and do occur. For example, adequate position of the double-lumen tube (DLT) or bronchial blocker (BB) does not ensure functional lung separation (condition A), and adequate OLV can sometimes be achieved without optimal DLT position (condition C). **Table 1** lists examples of causes and solutions for each clinical condition in Figure 1. By identifying the exact nature of the difficulties, the anesthesiologist can implement appropriate therapy without wasting time on DLT repositioning, cuff volume manipulations, or ventilation changes if they are not part of the problem.

Table 1: Clinical conditions during one-lung anesthesia

Area	Example	Typical Solution
A	• No airtight cuff seal	• More air in cuff or larger DLT
B	• Left DLT in too far occluding LUL orifice	• Position DLT optimally
C	• Right DLT cuff occluding RUL orifice	• Position DLT optimally
D	• Hypoxemia • Obstruction of the ventilating lumen of DLT	• 100% oxygen/CPAP/PEEP/TLV • Consider alternative lung separation technique
E	• No Problem!	

LUL = left upper lobe; RUL = right upper lobe; TLV = two lung ventilation

Design characteristics of double lumen tubes and bronchial blockers

Adult DLTs commonly come in sizes 35, 37, 39, and 41 French (F). Some manufacturers also provide 26, 28 and 32 F. The particular dimensions and design characteristics vary somewhat between manufacturers (Rusch, Portex, Kendall, Mallinckrodt, and Fuji Systems). The resting bronchial cuff volume (defined as the smallest cuff volume beyond which a 0.5 cc increase results in more than a 10 torr increase in cuff pressure) can differ between sizes (35 F = 3.7 cc; 41 F = 2.0 cc) (1). Inflation of the bronchial cuff beyond its resting volume (or even less than its resting volume if fitted tightly inside a bronchus), may result in dangerously high intracuff pressures and should be avoided (1,2).

In 1994, the left Bronchocath tube was redesigned: the bronchial curve was made tighter, an inverted cuff was placed closer to the tip of the bronchial lumen, and the bevel of the bronchial lumen tip was eliminated. The non-beveled tip made inserting the tube through the glottic opening difficult, despite adequate laryngoscopic views (3,4). In 2001, Mallinckrodt reintroduced a beveled edge on the tip of the tube.

The Univent tube, an alternative device for providing OLV, also underwent design modifications in 2001 (see <http://www.fujisys.co.jp/en/phycon/>). The manufacturer reports that the new Torque Control Blocker (TCB) Univent has a more flexible shaft that is easier to direct into the target bronchus and a blocker made from a softer medical grade silicone material that is more compliant. Typical cuff inflation volume is 5-6 cc.

The Arndt endobronchial blocker, or wire-guided endobronchial blocker (WEB), is a fairly recent addition to the armamentarium of lung separation devices (5-7). This system minimizes some of the traditional difficulties associated with the use of Fogarty embolectomy catheters as independent BBs and with Univent tubes. A patient's lungs can be conveniently be ventilated while the blocker is fiberoptically positioned through the Arndt multiport airway adapter. The guidewire loop that

protrudes through the blocker's tip is used to couple the blocker to the fiberoptic bronchoscope (FOB), which can be directed fiberoptically to the desired location in the bronchial tree. The blocker's 1.4 mm lumen can be used to insufflate oxygen or suction gas from the blocked lung after the wire loop is removed. The balloon of the blocker may be less likely to dislodge than that of a Fogarty catheter because of its elliptical shape and high-volume, low-pressure cuff. The smallest single lumen tube (SLT) for use with this blocker coaxially ( $\geq 7.5$  mm ID) has a corresponding outer diameter that compares favorably with that of the typical DLTs and Univent tubes used for small adults. This blocker is also latex free.

Since its introduction in 1999, Cook Critical Care has changed the color of the blocker catheter from blue to yellow to contrast with the blue balloon and facilitate recognition with the FOB. A spherical balloon in addition to the elliptical balloon is also available in the 9 F adult size. A 5 F pediatric blocker has been available since 2001 and can be used inside SLTs as small as 4.5 mm. A midsize 7 F catheter is also available to permit the use of a larger diameter FOB or a smaller diameter SLT for coaxial use. "Murphy eye" side holes have been introduced into the distal end of the 9 F adult catheter to circumvent suctioning difficulty if the end hole abuts the bronchial mucosa (George Arndt, personal communication, 2002), and the guidewire loop can now be reinserted if needed. Characteristics of available blockers are described in **Table 2** below:

**Table 2: Arndt Endobronchial Blockers**

Size (F)	Smallest SLT ID for coaxial use (mm)	Length (cm)	Cuff shape	Average cuff inflation volume (cc)
9	7.5	78 & 65	Elliptical Spherical	6 - 12 4 - 8
7	6.0	65	Spherical	2 - 6
5	4.5	65 & 50	Spherical	0.5 - 2.0

ID = inner diameter

(data from Cook Critical Care)

Cook Critical Care introduced the Cohen blocker in 2003. This device is similar to the Arndt blocker except that its distal tip is directed by way of a proximal control mechanism instead of coupling to a bronchoscope. The use of bronchial blockers in adults has recently been reviewed (8).

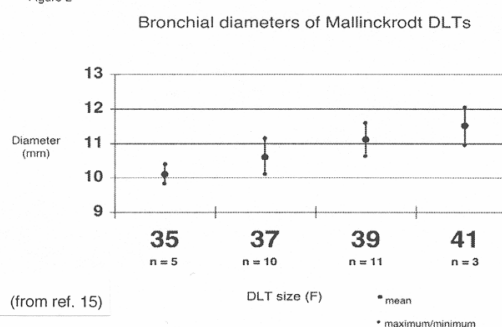
### Size selection of double-lumen tubes

Assuming that the main body of a DLT will fit through the glottic opening and the trachea, an appropriately sized DLT is the largest tube that will fit in the mainstem bronchus with only a small air leak detectable when the cuff is deflated (2). The presence of some air leak ensures that the tube is not tightly impacted in the bronchus. Thus, the goal is to select a DLT with a bronchial end that is 1-2 mm smaller in its outer diameter than the diameter of the intubated bronchus to allow for the size of the deflated cuff (2). Although many practitioners select 41 F and 39 F DLTs for tall and short men, respectively, and 39 F and 37 F DLTs for tall and short women, respectively, there is considerable interindividual variability in left mainstem diameters and relatively weak predictive value of gender and height (2,9,10). Since prediction is imprecise, measurement of the left mainstem diameter on chest x-ray (CXR) is appealing but practical only 50-69% of the time (2,11). Other alternatives include measuring left mainstem diameter on chest CT (12) or 3-dimensional CT scan reconstruction (13). Brodsky et al measured the more readily obtainable tracheal diameter on CXR at the level of the clavicles and used a previously described mean left bronchial to tracheal width ratio to calculate the left mainstem diameter (14). However, the confidence limits for this ratio may be too large to be useful clinically (11).

One critically important assumption is that we clinicians know the dimensions of the differently sized DLTs. Russell et al independently measured the dimensions of DLTs from 4 manufacturers and found marked variations even within the same tube size for each manufacturer (15)! See **Figure 2**. Thus, any effort to predict appropriate DLT size has this important limitation.

While attempting to select an appropriately sized DLT is important, it is equally important clinically to recognize when a DLT is too large (bronchial lumen will not fit in bronchus or forms an airtight seal with no air in the cuff) or too small (requires more than 3 cc of air in the bronchial cuff to create a seal) and adjust accordingly.

Figure 2



### Right-sided double-lumen tubes

The perceived or real difficulty in achieving adequate OLV with right-sided DLTs is evidenced by the fact that they are used much less frequently than are left-sided DLTs: 95% of Bronchocath sales are left-sided (Sherri Cowan, personal communication 2005). Use of left-sided DLTs is generally encouraged because of the greater margin of safety in positioning them (16). In the hands of practitioners familiar with the use of right-sided DLTs and facile with fiberoptic bronchoscopy, successful and reliable OLV is possible.

When right- and left-sided DLTs were compared for left-sided thoracic surgery in 40 patients, no right upper lobes collapsed and the difference in the time to place the tubes was clinically insignificant (3.37 vs. 2.08 min) (17). Although their routine use in thoracic surgery is controversial (18,19), right-sided DLTs are indicated when a patient requires a DLT but also has an anatomic abnormality of the left mainstem bronchus such as an exophytic or stenotic lesion or left tracheobronchial disruption. Regardless of the reasons for use, the right mainstem bronchial length must be at least 10 mm to accommodate the lateral aspect of the bronchial cuff (20). This length can be determined bronchoscopically or from a CXR or CT. Attempts to position a right-sided DLT in a patient whose right mainstem bronchus is too short are almost certainly doomed to failure.

### Fiberoptic placement and positioning of double-lumen tubes

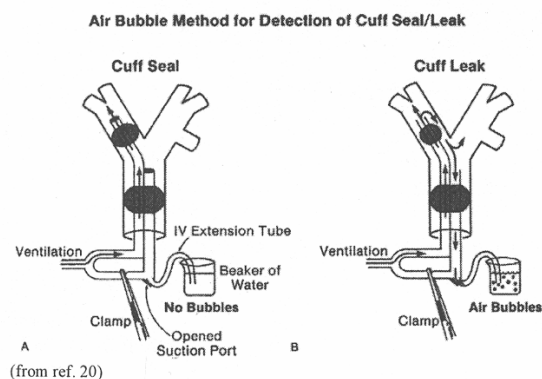
Precise positioning of a DLT is most reliably achieved with the benefit of a FOB. In comparisons of fiberoptic positioning of DLTs with conventional methods, over one-third of left DLTs were malpositioned after blind intubation and the inspection and auscultatory method (19). In a recent study of 200 patients, the incidence of malposition (0.5 cm deviation from ideal position) was 39.5% with 14% of them "critical" (20). Critical malpositions were those in which the left endobronchial limb allowed no clear view of the left upper or lower lobe bronchus, the right endobronchial limb allowed no clear view of the RUL bronchus, or there was intratracheal dislocation of more than one-half of the endobronchial cuff. Visually unassisted placement of left DLTs may result in initial intubation of the wrong bronchus 7-30% of the time (22,23,24,25).

Ovassapian described a reliable and reproducible method of placing left-sided tubes (and right-sided, with slight modification) on the first attempt (24). This technique involves first inserting the DLT through the glottis with direct laryngoscopy, rotating it 90° leftward, and advancing it only until the proximal edge of the tracheal cuff is past the vocal cords. This limited advancement ensures that the tip of the bronchial lumen is supracarinal. After the tracheal cuff is inflated, ventilation through both lungs is initiated. The FOB is then placed through the bronchial lumen and advanced until the carina and mainstem bronchi are clearly identified. The posterior membranous portion of the trachea and the characteristic trifurcation of the RUL bronchus are reliable anatomic landmarks to facilitate directional orientation. The FOB is then advanced into the left mainstem bronchus to a position just proximal to the left upper and left lower lobe bronchi. After deflation of the tracheal cuff, the entire DLT is slid over the FOB until its bronchial lumen comes into view beyond the tip of the FOB. Confirmation of a patent left upper and left lower lobe bronchus ensures that the DLT is not in too far. Finally, the FOB is passed through the tracheal lumen to check for a carinal or subcarinal position of the bronchial cuff and ensure patency of the right mainstem bronchus.

When 50 thoracic surgical patients with left-sided DLTs were positioned from supine to lateral, the tubes tended to move outward by an average of about 1 cm (26). Inflation of the endobronchial cuff before lateral positioning did not decrease the incidence or the amount of overall distance change. Because of the tendency for carinal shift and DLT movement upward with lateral positioning, there is an advantage to keeping the bronchial cuff at least 1 cm inside the left mainstem bronchus before turning laterally. In another study of 61 patients, the incidence of proximal repositioning was reduced significantly (43% vs. 16%) after turning from supine to lateral when the left Bronchocath was initially inserted with the proximal edge of its bronchial cuff 5 mm beyond the tracheal carina (27). Intraoperative use of a rigid neck collar to prevent head and neck movement will minimize *but still not prevent* DLT movement while positioning supine to lateral (28).

### Confirming lung separation

Of the techniques described to achieve a minimum occlusive seal (20,29,30), I routinely use the positive pressure test or bubble test depicted in **Figure 3**. There are a number of reasons to use a "just seal" technique to inflate the bronchial cuff of a



**Figure 3**

DLT or bronchial blocker (BB). First, a cuff that is inflated beyond a minimum occlusive pressure may result in tracheobronchial ischemic complications or even rupture (29,31). Second, an over-inflated bronchial cuff or BB is more likely to herniate over the tracheal carina and interfere with contralateral ventilation. Third is the ability to immediately and definitively verify lung separation. That "moment of truth" when the thoracoscopic port is inserted or the hemithorax is opened is thoroughly predictable. If lung collapse is slow or incomplete, documented lung separation assures the anesthesiologist that manipulation of the DLT or BB or their cuffs will not improve the situation. Attention can be focused on other maneuvers that will improve the surgical exposure: manual compression, suction, time, or intrahemithoracic CO<sub>2</sub> insufflation (32).

### Ventilation management

Traditional teaching is that for most patients, tidal volumes during OLV may be safely initiated at 10 cc/kg with a respiratory rate adjusted to maintain normal pCO<sub>2</sub> (20). However, the use of smaller (6 cc/kg) or larger (15 cc/kg) tidal volumes may be beneficial in some patients (33). In patients with COPD, the development of significant autoPEEP or dynamic pulmonary hyperinflation is an ever-present risk (34). A growing body of evidence suggests that lower tidal volumes and their associated lower plateau pressures may protect against acute lung injury during surgery for lung resection (35,36). The use of pressure-controlled ventilation (PCV) during OLV may potentially be superior to volume-controlled ventilation (VCV) in patients with significant lung pathology (37), and PCV with 4 cm H<sub>2</sub>O PEEP to the dependant lung provides lower airway pressures compared to VCV with no PEEP (38). Comparisons of desflurane (39) and sevoflurane (40) with isoflurane during OLV demonstrated that the choice of volatile anesthetic does not significantly influence arterial oxygenation.

Predicting which patients are at highest risk for intraoperative hypoxemia during OLV is useful for an informed decision about the need for OLV or to institute prophylactic nondependent lung CPAP (41). CPAP is most effectively applied to a fully inflated lung, since the opening pressure of atelectatic lung units may exceed 20 cm H<sub>2</sub>O. Factors associated with the development of desaturation with OLV include poor PaO<sub>2</sub> during TLV in the lateral position, good preoperative spirometry, right-sided surgery, and a significant proportion of ventilation or perfusion to the operative lung on preoperative ventilation-perfusion testing (41). Applying external PEEP to the dependent, ventilated lung as a first line intervention may be beneficial in some patients (42,43). A recruitment maneuver at the beginning of OLV also improves oxygenation (44).

The primary mechanism by which the lung becomes atelectatic is absorption atelectasis. This is achieved most rapidly with 100% oxygen rather than an air-oxygen mixture and when the amount of gas to be resorbed is the least (45). Thus, lung collapse will be most rapid if lung separation is initiated at end expiration (at FRC), especially when using a BB that has a small or absent lumen (20).

### Comparison of lung isolation techniques

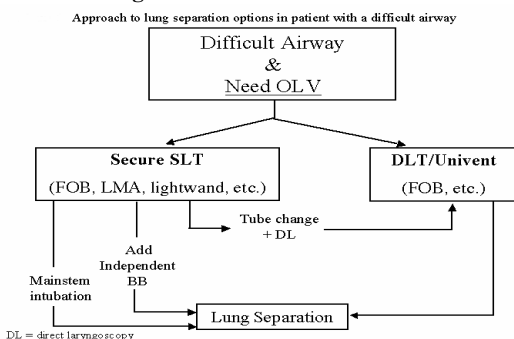
Campos et al prospectively compared the effectiveness of lung isolation with a left Bronchocath, TCB Univent tube, and the Arndt endobronchial blocker through a SLT in 64 elective right- and left-sided thoracic surgical cases (46). There were no statistically significant differences among the 3 groups in frequency of tube malpositions, number of required bronchoscopies, or overall quality of lung isolation as assessed by the surgeon (blinded to technique) once lung isolation was achieved. The Arndt blocker took slightly longer to place (3 min, 34 sec) compared to the DLT (2 min, 8 sec) or Univent (2 min, 38 sec) groups, inclusive of time to place the SLT, although 86- and 46-sec differences are hardly of clinical significance. Complete lung collapse took longer with the Arndt blocker (26 min, 2 sec) than with the DLT (17 min, 54 sec) or Univent (19 min, 28 sec) and more frequently required suction assistance.

More recently, Campos et al studied the success with which the occasional thoracic anesthesiologist (< 2 cases per month) correctly placed and positioned these same 3 devices in 66 patients with favorable airways (47). He found an astonishing overall 38% failure rate with no differences between devices. When successful, placement times averaged between 6 and 9 minutes regardless of the device used. Their observations suggested that unfamiliarity with tracheobronchial anatomy and lack of skill in fiberoptic bronchoscopy were most responsible for the difficulties.

Comparing a left Bronchocath DLT to the Arndt BB for port-access cardiac surgery, more laryngoscopy attempts (2.3 vs 1.1) and additional time (105 sec) to replace the DLT at the end of the case were trade offs for slightly better right lung deflation with the DLT (48).

### Lung separation and the difficult airway

In the patient with a difficult airway who requires lung separation, the concern for lung separation is secondary to securing the airway. One must not succumb to the temptation to take unorthodox approaches to airway management (e.g., asleep vs. awake) just because lung separation is also needed. Fortunately, there are several options for achieving lung separation once a SLT has been successfully placed. The Arndt blocker in particular represents a significant advance in the management of these patients and is especially useful when a nasal intubation is required (49). An algorithm for airway management options is presented in **Figure 4**.



**Fig 4 (from ref 51)**

### A. Upper and lower airway difficulties

Airway difficulties may arise from the upper airway (more common) or the lower airway. Upper airway anatomic or pathologic features that render conventional rigid laryngoscopy difficult for placement of SLTs are even more problematic for the placement of DLTs and Univent tubes because of their size and shape (50). Awake fiberoptic intubation with a SLT or DLT may be the best option in cases of known or anticipated difficult intubation (23,51,52).

Lower airway difficulties are encountered with anatomical variation or distortion of the tracheal or bronchial anatomy.

Distortion can occur with strictures, extraluminal compression, deviation, or intraluminal masses. These will influence the selection of the bronchus to be targeted and the choice of a BB or DLT. Lower airway difficulties can be detected or predicted by diagnostic bronchoscopy before intubation or by imaging studies performed preoperatively.

## **B. Options for lung separation**

**Double-lumen tubes.** The tracheal cuffs of DLTs are particularly vulnerable to being torn by a patient's teeth when a DLT is being placed with the aid of rigid laryngoscopy in patients with prominent dentition, a small mouth opening, or limited neck extension. Several proposed solutions to this problem include a retractable protective sheath (53), a lubricated Penrose drain (54), lubricated teeth guards (55), and manipulation of the tube during laryngoscopy (56).

Oral fiberoptic intubation with a DLT is well described in both awake and asleep patients (52,57,58). A patient's mouth opening and oropharyngeal size must be large enough to accommodate a DLT for orotracheal intubation. Awake placement requires good topical anesthesia, adequate conscious sedation, and assistance in maintaining soft tissue support. Soaking a DLT in a warm water bath just before intubation and using sufficient lubrication will minimize its rigidity (58). Concurrent direct laryngoscopy may be required to elevate the supraglottic tissues to facilitate passage of a DLT through the glottic opening after the fiberoptic scope is in the trachea (59).

**Univent tubes.** Some anesthesiologists consider a Univent tube easier to place and position than a DLT (60), particularly in patients with upper airway abnormalities (61). Others do not (4). The internal diameter of the ventilating lumen in a size 8.5 or 9.0 Univent tube will accommodate an adult 5.0 mm bronchoscope (60), which then precludes the need to change tubes after diagnostic bronchoscopy. Although it is also suitable for fiberoptic intubation, the Univent tube has several limitations. First, unlike the polyvinyl chloride of the SLT and DLT, the Univent tube is constructed of a polymeric silicone material that will not soften in a warm water bath. As such, its curved shape is fixed, and this may be a disadvantage when sliding it over a bronchoscope. Second, the fixed concavity often makes the leading edge of the tube impinge upon the vocal cords, impeding its passage into the trachea. A successful nasal intubation with a 7.0 Univent tube has been described, despite its size and rigidity (62).

**Arndt endobronchial blockers.** See earlier discussion.

**Single-lumen endotracheal tubes.** Using a SLT to intubate a mainstem bronchus is another option for achieving lung separation, and it is frequently the preferred technique for children who are too small for DLTs (63). Advantages of this approach include its simplicity and the rapidity with which lung separation can often be achieved, particularly when the right lung must be ventilated. Blind advancement of a SLT will rarely result in a left mainstem intubation, but rotating an in situ SLT 180 degrees while turning the patient's head to the right will improve the success rate of left mainstem intubation to about 92% (64). Fiberoptic guidance of a SLT into the appropriate mainstem bronchus is probably the easiest and most reliable technique. If significant amounts of blood or secretions preclude fiberoptic visualization, using fluoroscopy to visualize and direct the radiopaque bronchoscope is another option (65).

Disadvantages of the use of a SLT for lung separation include frequent exclusion of RUL ventilation when a SLT is in the right mainstem bronchus. Left upper lobe ventilation can also be excluded when the left mainstem bronchus is relatively short (66). Regardless of which lung is ventilated, neither independent suctioning nor application of CPAP to the nonventilated lung is possible. Lastly, if the nasotracheal route is used, most SLTs will not be long enough to provide a reliable mainstem intubation.

## **C. The patient with a tracheostomy**

Although the presence of a tracheostomy greatly simplifies airway management for most anesthetics, it presents an interesting challenge when lung separation is required. As with orotracheal intubation, use of a DLT (23), Univent tube (67), or BB through the tracheostomy stoma is an option, even though these tubes are not specifically designed for this use. Depending upon the details of a patient's anatomy such as stomal diameter, distance between the skin and the anterior tracheal wall, and stoma-to-carinal distance, DLTs and Univent tubes may be difficult to place and position precisely and atraumatically.

Another way to achieve lung separation in a patient with a tracheostomy is using a BB, either coaxially or alongside of a SLT or tracheostomy tube through the stoma (68) or through the mouth (69). Blind or fiberoptically directed mainstem intubation with a SLT inserted through the stoma is yet another option, although it has the usual limitations associated with mainstem intubations.

## **D. Extubation and postoperative intubation**

When the decision is made to leave a patient intubated after a procedure involving lung separation then some special considerations need to be addressed. The possibility of the recurrent need for lung separation should be considered a reason to leave a patient intubated. Occasionally, an airway that was not difficult initially may become difficult after a lengthy procedure involving large fluids shifts that contribute to upper airway or head and neck edema. An anticipated need for postoperative intubation should therefore affect a preoperative decision about the lung separation technique. If a SLT with a BB was used for lung separation, then all that needs to be done at the end of the procedure is to remove it. If a Univent was used, then its blocker should be fully retracted, and the Univent can function as a SLT. To avoid the potential for the inappropriate use of the BB postoperatively by caregivers unfamiliar with the device, the blocker may be disabled.

If a DLT was used for lung separation, then the risks and benefits of changing to a SLT must be carefully weighed. The main advantage to leaving the tube in place is that the hazards associated with a tube change with a difficult airway are avoided. In this case, one can leave the tube positioned and ventilate both lungs through both lumens. Alternatively, the tube can be withdrawn to the point at which the tip of the bronchial lumen is just above the carina, which will position the tracheal cuff below

the vocal cords (70). Increased flow resistance leading to obstructed expiratory flow or increased work of breathing is probably not clinically significant with 37 F or larger Rusch or Sheridan DLTs (71).

If the DLT is to be changed, it should be done under direct vision if possible. If adequate laryngeal exposure is not possible with a rigid laryngoscope, an airway exchange catheter (AEC) may be used to exchange a SLT for a DLT preoperatively or DLT for a SLT postoperatively. Cook Critical Care manufactures AECs specifically designed for DLT exchanges. These differ from conventional AECs in that they are longer (100 cm) and have centimeter markings that extend to 50 cm. Eleven and 14 F sizes will fit inside small and large DLTs, respectively. An extra firm variety colored green became available in 2002.

### Keys to success in one-lung anesthesia

- Understand the physical details of DLTs and BBs and select them appropriately
- Use the FOB! – optimize conditions (antisialagogue, suction), know the tracheobronchial anatomy, and practice
- Employ a “just seal” test every time – avoid trouble and identify problems early

### References

1. Hannallah MS, et al. *Anesth Analg* 1993; 77:1222-1226
2. Hannallah MS, et al. *J Cardiothorac Vasc Anesth* 1995; 9:119-121
3. Brodsky JB, et al. *J Cardiothorac Vasc Anesth* 1995; 9:785
4. Campos JH, et al. *Anesth Analg* 1996; 83:1268-1272
5. Arndt GA, et al. *Anesthesiology* 1999; 90:1484-1486
6. Arndt GA, et al. *Can J Anaesth* 1999; 46:87-89
7. Arndt GA, et al. *Acta Anaesthesiol Scand* 1999; 43:356-358
8. Campos JH. *Anesth Analg* 2003; 97:1266-1274
9. Slinger P. *J Cardiothorac Vasc Anesth* 1995; 9:117-118
10. Brodsky JB, et al. *J Clin Anesth* 2005; 17:267-270
11. Hampton T, et al. *Anaesth Intensive Care* 2000; 28:540-542
12. Chow MYH, et al. *Anesth Analg* 1999; 88:302-305
13. Eberle B, et al. *J Cardiothorac Vasc Anesth* 1999; 13:532-537
14. Brodsky JB, et al. *Anesth Analg* 1996; 82:861-864
15. Russell WJ, et al. *Anaesth Intensive Care* 2003; 31:50-53
16. Benumof JL, et al. *Anesthesiology* 1987; 67:729-738
17. Campos JH, et al. *Anesth Analg* 2000; 90:535-540
18. Campos JH, et al. *J Cardiothorac Vasc Anesth* 2002; 16:246-248
19. Cohen E. *J Cardiothorac Vasc Anesth* 2002; 16:249-252
20. Benumof JL. *Anesthesia for Thoracic Surgery*, 2nd ed. Philadelphia: WB Saunders, 1995: 330-89
21. Pennefather SH, et al. *Br J Anaesth* 2000; 84:308-310
22. Klein U, et al. *Anesthesiology* 1998; 88:346-350
23. Brodsky JB et al. *J Cardiothorac Vasc Anesth* 2003; 17:289-298
24. Ovassapian A. *Fiberoptic Endoscopy and the Difficult Airway*, 2nd ed. Philadelphia: Lippincott-Raven 1996: 117-156
25. Brodsky JB, et al. *Anaesth Intensive Care* 1995; 23:583-586
26. Desiderio DP, et al. *J Cardiothorac Vasc Anesth* 1997; 11:595-598
27. Fortier G, et al. *Can J Anaesth* 2001; 48:790-794
28. Yoon TG, et al. *Can J Anesth* 2005; 52:413-417
29. Guyton DC, et al. *J Cardiothorac Vasc Anesth* 1997; 11:599-603
30. Hannallah MS, et al. *Anesth Analg* 1993; 77:990-994
31. Fitzmaurice BG, et al. *J Cardiothorac Vasc Anesth* 1999; 13:322-329
32. Brock H, et al. *Anaesthesia* 2000; 55:10-16
33. Szegedi LL, et al. *Brit. J of Anaesth* 2002; 88(1):56-60
34. Ducros L, et al. *J Cardiothorac Vasc Anesth* 1999; 13:35-39
35. Licker M, et al. *Anesth Analg* 2003; 97:1558-1565
36. Slinger P. *Anesth Analg* 2003; 97:1555-1557
37. Tugrul M, et al. *Br J Anaesth* 1997; 79:306-310
38. Senturk NM, et al. *J Cardiothorac Vasc Anesth* 2005; 19:71-75
39. Wang JY, et al. *Anaesthesia* 2000; 55:167-173
40. Abe K, et al. *Anesth Analg* 1998; 86:1266-1270
41. Slinger PD, et al. *J Cardiothorac Vasc Anesth* 2000; 14:202-211
42. Slinger PD, et al. *Anesthesiology* 2001; 95:1096-1102
43. Valenza F, et al. *European J Anaesth* 2004; 21:938-943
44. Tusman, et al. *Anesth Analg* 2004; 98:1604-9
45. Nunn JF. *Nunn's Applied Respiratory Physiology*, 4th ed. Oxford: Butterworth-Heinemann, 1993:496
46. Campos JH, et al. *Anesth Analg* 2003; 96:283-289
47. Campos JH, et al. *Anesthesiology* 2006; 104:261-266
48. Grocott HP, et al. *J Cardiothorac Vasc Anesth* 2003; 17:725-727
49. Campos JH. *Anesthesiology* 2002; 97:1295-1301
50. Wilson RS. *Chest Surg Clin N Am* 1997; 7:735-751
51. Klapfta JM, et al. *Probl Anesth*. 2001; 13:69-77
52. Patane PS, et al. *J Cardiothorac Anesth* 1990; 4:229-231
53. Coppa GP, et al. *Anesth Analg* 1998; 86:675
54. Marymont J, et al. *J Cardiothorac Vasc Anesth* 1999; 13:371
55. Erb JM. *Anesth Analg* 1998; 87:1217
56. Fortier G, et al. *Anesth Analg* 1999; 89:1064
57. Ovassapian A. *J Bronchol* 1994; 1:1-8
58. Ovassapian A, et al. (abstract) 12th World Congress of Anesthesiologists 2000; 1.4.06
59. Benumof JL. *J Cardiothorac Vasc Anesth* 1998; 12:131-132
60. Gayes JM. *J Cardiothorac Vasc Anesth* 1993; 7:103-107
61. Slinger P. *J Cardiothorac Vasc Anesth* 1993; 7:108-112
62. Gozal Y, et al. *Anesthesiology* 1996;84:477
63. Hammer GB, et al. *Anesth Analg* 1999; 89:1426-1429
64. Kubota H, et al. *Anesthesiology*. 1987; 67:587-589
65. Klapfta JM, et al. *Anesthesiology* 1997; 87:1248-1250
66. Lammers CR, et al. *Anesth Analg* 1997; 85:946-947
67. Andros TG, et al. *Anesthesiology* 1993; 79:1127-1128
68. Dhamee MS. *J Cardiothorac Vasc Anesth* 1997; 11:124-125
69. Veit AM, et al. *Anesth Analg* 1996; 82:1292-1293
70. Cohen E, et al. *Curr Opin Anesthesiol* 1999; 12:29-35
71. Slinger PD, et al. *J Cardiothorac Vasc Anesth* 1998; 12:142-144