

# Gas Embolism During Hysteroscopic Surgery?: Three Cases and a Literature Review

Benjamin S. Storm, MD, EDIC,\* Stine Andreassen, MD, PhD,† Anders Hovland, MD, PhD,‡§ and Erik W. Nielsen, MD, PhD, EDIC\*§

During a period of 1 month, 3 episodes of probable or actual venous air embolism occurred during hysteroscopic surgery. All patients developed the same symptoms of ventilatory and hemodynamic decompensation, beginning with a reduction in end-tidal carbon dioxide, arterial desaturation, and cyanosis on the upper trunk, and rapidly progressed to hypotension and 2 cardiac arrests. While entrainment of some air is common during hysteroscopy, life-threatening embolism is a rare but serious complication for which an anesthetist needs to be vigilant and prepared. If even a small drop in end-tidal carbon dioxide occurs, venous air embolism should be suspected and the operation should be discontinued. (A&A Case Reports. 2017;9:140–3.)

Subclinical air embolism occurs frequently during uterine surgery.<sup>1–3</sup> Symptoms vary, from a brief and transient drop in end-tidal carbon dioxide (EtCO<sub>2</sub>) to a decrease in oxygen saturation (SpO<sub>2</sub>) to severe organ dysfunction and death. Over a 1-month period, 3 women undergoing hysteroscopic surgery experienced likely air embolism, 1 of whom experienced a myocardial infarction and 2 of whom experienced cardiac arrests, with 1 death and 1 severe neurological sequela. Before these events, the risk of hysteroscopy-associated venous air embolism (VAE) and the importance of monitoring EtCO<sub>2</sub> were underappreciated in Norwegian Anesthesiological and Gynecological Societies. As a result of these 3 events, we focused educational efforts on hysteroscopy-related VAE and changed the clinical practice at our institution. In this article, we present the 3 cases, describe the pathophysiology and management of air embolism, and propose changes in surgical practice and perioperative monitoring to minimize the adverse consequences of air embolism.

The patients or their relatives gave written consent for publication.

## CASE DESCRIPTIONS

All patients received total intravenous (IV) anesthesia delivered by a targeted-controlled infusion pump system. The set plasma target for propofol was 3–4 µg/mL; for remifentanyl, 3–6 µg/mL. Using a Dräger Primus ventilator (Drägerwerk AG, Lübeck, Germany), pressure-controlled positive-pressure ventilation (P<sub>insp</sub> 10/P<sub>exp</sub> 0–3) was delivered through

a laryngeal mask airway device (LMAD) with 50% oxygen in air. EtCO<sub>2</sub>, airway pressure, and tidal volume were registered by the ventilator.

In a supine-to-mild Trendelenburg position, the cervix of each patient was dilated, and a resectoscope (Karl Storz, Tuttlingen, Germany) was inserted and connected to a peristaltic pump-driven active inflow and outflow irrigation and distension system (Hysteromat E.A.S.I., Karl Storz, Tuttlingen, Germany). Saline pressurized to 65–100 mm Hg was used as irrigation fluid. All procedures occurred in the same operating room using the same surgical equipment. There were 3 different surgical teams. All 3 gynecologists were experienced surgeons. After the first event, the anesthesia machine was replaced. The same anesthesia machine was used in patients 2 and 3.

## Case 1

A healthy 46-year-old woman underwent hysteroscopic transcervical endometrial resection. After induction of anesthesia and insertion of the LMAD, the EtCO<sub>2</sub> was stable at 4.8 kPa (36 mm Hg). Initially, the hysteroscope did not deliver enough water to dilate the uterine cavity. When an inadvertent disconnection of the water supply hose was discovered, the hose was reattached. The resectoscope, as was routine, was inserted and removed several times to allow for evacuation of debris. After approximately 5 minutes of surgery, the EtCO<sub>2</sub> dropped to 2 kPa (15 mm Hg). A few minutes later, SpO<sub>2</sub> dropped from 100% to 90%, and airway pressures increased markedly. The patient developed a distinct cyanosis of the upper body. Soon thereafter, she was found to have pulseless electrical activity (PEA) that progressed to ventricular fibrillation. Return of spontaneous circulation occurred after 9 minutes of standard guideline-driven cardiopulmonary resuscitation (CPR) with compressions, 2 cardioversion attempts, epinephrine, mechanical chest compressions with the LUCAS system (Physio-Control, Lund, Sweden), and endotracheal intubation. EtCO<sub>2</sub> was 2.5 kPa (19 mm Hg), SpO<sub>2</sub> 90% with a F<sub>IO2</sub> of 1.0, and systolic arterial blood pressure of 120 mm Hg. Echocardiogram during CPR interruptions showed a poorly contracting heart with an ejection fraction of 10%–15%. Because of transient improvements with epinephrine boluses, an adrenaline infusion was commenced. But severe lung edema followed, and when the blood pressure declined, the LUCAS was

From the Departments of \*Anesthesia and Intensive Care, †Gynecology and Obstetrics, and ‡Cardiology, Nordland Hospital, Bodø, Norway; and §Institute of Clinical Medicine, University of Tromsø, Nord University, Bodø, and University of Oslo, Norway.

Accepted for publication March 2, 2017.

Funding: None.

The authors declare no conflicts of interest.

Supplemental digital content is available for this article. Direct URL citations appear in the printed text and are provided in the HTML and PDF versions of this article on the journal's website ([www.cases-anesthesia-analgesia.org](http://www.cases-anesthesia-analgesia.org)).

Address correspondence to Benjamin Storm, MD, EDIC, Department of Anesthesia and Intensive Care, Nordland Hospital, Nordlandssykehuset, PO Box 1480, 8092 Bodø, Norway. Address e-mail to [benjamin.storm@gmail.com](mailto:benjamin.storm@gmail.com)

Copyright © 2017 International Anesthesia Research Society  
DOI: 10.1213/XAA.0000000000000549

restarted. EtCO<sub>2</sub> remained around 1.2 kPa (9 mm Hg) during resuscitation. Severe hypercapnia developed, pH decreased to 6.88, and lactate increased to 10 mmol/L.

The patient was transferred to a tertiary hospital for extracorporeal membrane oxygenation (ECMO). A coronary angiography was normal. The response to treatment was poor, and ECMO was stopped after a few hours. The autopsy did not establish a definite cause of death.

## Case 2

A 68-year-old woman with stable chronic lymphatic leukemia and nonspecific hay fever symptoms underwent transcervical polyp extirpation. After induction of anesthesia and insertion of the LMAD, the EtCO<sub>2</sub> was stable around 5.0 kPa (37.5 mm Hg).

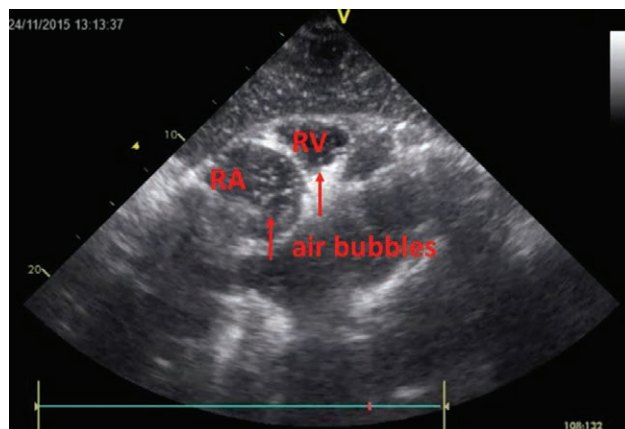
Ten minutes into the surgery, there was a sudden drop in EtCO<sub>2</sub> to 1 kPa (7.5 mm Hg) and simultaneous development of bradycardia and hypotension. Airway pressure increased, SpO<sub>2</sub> decreased (to 60%), and cyanosis became apparent in the upper body. The operation was terminated. Ephedrine 10 mg IV was administered. Airway pressure and blood pressure returned to baseline within 3 minutes. But the patient still required FiO<sub>2</sub> of 1.0 to maintain an SpO<sub>2</sub> of 90%, and EtCO<sub>2</sub> did not return to baseline for another 30 minutes. The patient woke up neurologically intact. Postoperatively, she developed a non-ST elevation myocardial infarction with a troponin-I increase to 2033 ng/L, discrete electrocardiograph changes with minor ST segment depressions in I and II and T-wave inversions in V3–V6. A postoperative echocardiogram revealed a myxoma in the right atrium (incidental finding). No intercardiac air was visualized nor sought for.

## Case 3

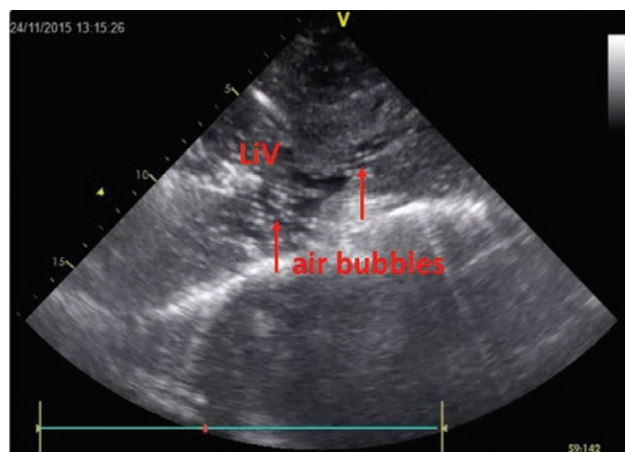
A 40-year-old female was scheduled for transcervical endometrial resection due to menorrhagia and removal of an intrauterine device (IUD). After induction of anesthesia and insertion of the LMAD, the EtCO<sub>2</sub> was stable, at around 4.5 kPa (34 mm Hg).

Due to problems caused by the inlet pump, the uterine cavity was not filled with water. The IUD was identified and removed. At the same time, the patient became cyanotic. There was a rapid drop in EtCO<sub>2</sub> to 0.8 kPa (6 mm Hg), a drop in SpO<sub>2</sub> to 30%, and an increase in airway pressure. She progressed rapidly to PEA. The LMAD was immediately exchanged for an endotracheal tube, FiO<sub>2</sub> was set to 1.0, and CPR commenced. To exclude ventilator malfunctioning, the patient was connected to a bag-mask system. Return of spontaneous circulation was achieved after 20 minutes of standard CPR with LUCAS and epinephrine boluses and infusion to a total of 6 mg. An intermittent complete atrioventricular block was treated with external pacing.

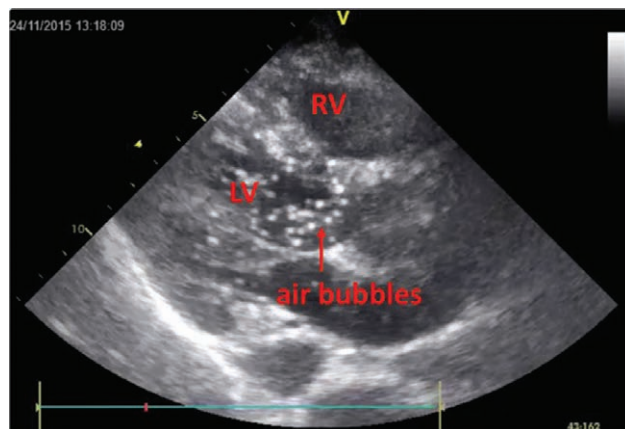
A transthoracic echocardiogram showed vast amounts of bubbles in the inferior vena cava, the liver veins, right atrium, right ventricle, pulmonary artery, and apical hypokinesia. With increasing heart contractility, air bubbles were also seen in the left atrium, ventricle, and aorta (Figures 1, 2, and 3; Supplemental Digital Contents, Supplemental Videos 1, 2, and 3, <http://links.lww.com/AACR/A104>, <http://links.lww.com/AACR/A105>, and <http://links.lww.com/AACR/A106>).



**Figure 1.** Subcostal view. Air in RA and RV. RA indicates right atrium; RV, right ventricle.



**Figure 2.** Subcostal view. Air in LiV and vena cava inferior. LiV indicates liver veins.



**Figure 3.** Parasternal long axis view. Air in LV. LV indicates left ventricle; RV, right ventricle.

Despite infusion of 8 L of crystalloid, the hemoglobin increased to 19 g/dL, and stroke volume variation was 26%. Troponin-I was 31,629 ng/L. Twelve hours postoperatively, oxygenation and ventilation worsened dramatically, and the patient was transferred to a tertiary hospital for acute ECMO. An echocardiogram

VIDEO+

before cannulation showed air in the liver veins and the inferior vena cava. ECMO was weaned after 5 days. The tracheal tube was removed after 9 days. Magnetic resonance imaging of her **cerebrum revealed multiple infarctions** globally, and she was discharged to a rehabilitation center with **severe neurological deficits**.

After the third adverse event, the Norwegian Board of Health Supervision examined the cases. No technical faults in the equipment were found. Logs from the anesthesia machines verified a **significant drop in EtCO<sub>2</sub> before** the onset of **hypoxia** or **circulatory arrest** in all 3 patients (Figure 4).

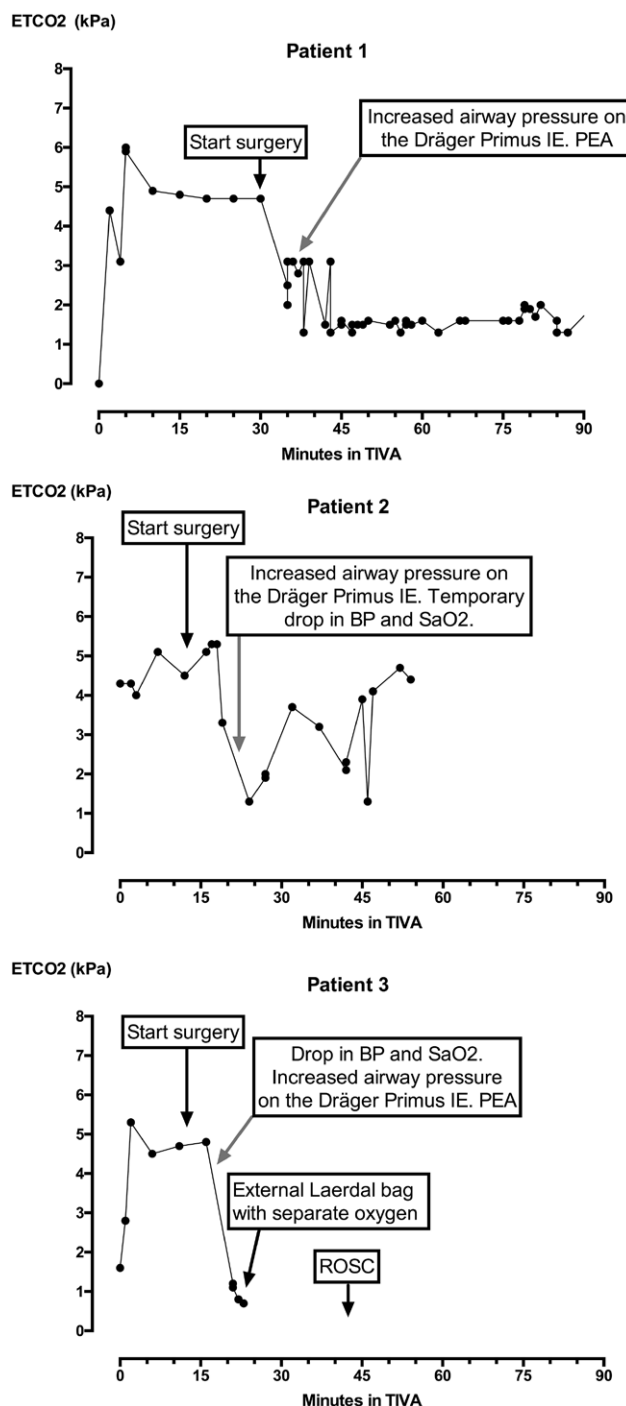
We reviewed the literature and found several case reports on VAE during hysteroscopy<sup>4,5</sup> as well as a **review article in UpToDate.com**.<sup>6</sup> A US **Food and Drug Administration** warning from 2000 described the problem as a known but **underappreciated complication to hysteroscopy**.<sup>7</sup> The very specific symptoms of VAE described in the literature were almost identical to the symptoms of our patients, and VAE was therefore considered highly probable.

## DISCUSSION

Fatal and nonfatal VAE is described in neurosurgical, laparoscopic, orthopedic, gynecological, and hysteroscopic surgery, as well as in association with central venous access devices and intraosseous cannulas.<sup>1,4,6</sup> In a **study of 23 women undergoing hysteroscopy**, **air bubbles** were found in the **right atrium of all women** during the procedure.<sup>2</sup>

The mechanism behind VAE is complex and multifactorial. **Air can be entrained** into incised or open **veins with sub-atmospheric** pressure. This is the case if the **operative site** or the central venous access site **lies above heart level**.<sup>4</sup> During hysteroscopic procedures, **air-free saline** distends the uterus with a **pressure up to 100 mm Hg**, greatly **exceeding the venous pressure** in all body positions. It is not uncommon for a substantial amount of the **pressurized irrigation fluid** to be **absorbed via the veins** into the body.<sup>8</sup> Should the fluid, the tubing, or the hysteroscope **contain air**, then this air can be **delivered** to and **absorbed** by the uterus. This can happen if there is a **disconnection** of the **irrigation fluid supply tubing** without interruption of the pump, or if the tubing is erroneously connected. Per our scrub nurses, the **Hysteromat pump** often had **unexplained problems** with **delivery of irrigation fluid**. As the operation team was not expecting air delivery from the pump, any changes in pressure or accidental blending of air went unnoticed. Any contribution of air from the Hysteromat pump therefore remains speculative. **Air under pressure** can enter opened veins. **Uterine veins open after cervical dilations** and even more than after curettage. The **hysteroscope acts like a piston**, and with repeated instrumentation, **air can be pumped** into the **uterine cavity**.<sup>3,7</sup>

Despite a potentially higher risk for air entrainment due to the above-mentioned causes in this procedure, a **critical amount of air is required** to cause clinically relevant symptoms. In a study by Leibowitz et al,<sup>2</sup> **all women had transient air detected in the right heart** during **hysteroscopy**. A continuous flow of bubbles was noted in 85% of all patients, but only 30% experienced a **desaturation** in conjunction with the embolism.<sup>2</sup> The potential for bubble formation depends on solubility of the gas entering the blood. Ambient **nitrogen** is



**Figure 4.** EtCO<sub>2</sub> log from the anesthesia machine. All patients had a sudden drop in EtCO<sub>2</sub>. EtCO<sub>2</sub> indicates end-tidal carbon dioxide.

**far less soluble in blood than carbon dioxide or oxygen**, and hence has a **greater bubble formation capability**.<sup>9,10</sup> Larger amounts of bubbles may cause a **physical occlusion** of the **right ventricle outflow tract** and pulmonary artery, leading to pulmonary hypertension and right heart failure. **Acute reduction of left heart preload** can give PEA.<sup>1,11</sup> Very **large** amounts of **bubbles** may **overwhelm** the **filtering capacity** of the **lung capillary bed**, and **pass** through to the **left heart**, causing **systemic air emboli**, even in patients **without** a persistent **foramen ovale**.<sup>2</sup>



Air triggers a host inflammatory response that causes bronchoconstriction, pulmonary capillary leakage, and systemic hemoconcentration, as seen in our third case.<sup>12–14</sup>

Air entering the right heart can be accurately diagnosed perioperatively by continuous echocardiography or the undemanding precordial Doppler ultrasonic device.<sup>5,15</sup> A sensitive and easy method of monitoring gas embolism is to follow Etco<sub>2</sub> meticulously. Even minor obstructions of the blood flow to the lungs cause a reduction of Etco<sub>2</sub>, often before any other clinical symptom develops.<sup>4,5</sup> A retrospective review of the anesthesia machine logs revealed that all patients experienced a drop in Etco<sub>2</sub> and increased airway pressures before circulatory collapse (Figure 4). Due to low resolution of the log (5 minutes), we are unable to pinpoint the exact timing of events.

Should signs or symptoms of air embolism develop, the surgery should be discontinued. Ventilation with 100% oxygen facilitates washout of nitrogen. If the patient's condition permits, transport to a pressure chamber for emergent recompression and hyperbaric oxygen treatment will reduce bubble size and facilitate their elimination. As with decompression sickness, even delayed recompression may be of value to reduce long-term neurological sequela.<sup>16</sup>

These 3 events prompted us to rediscover hysteroscopy-related VAE and change the clinical practice at our institution. Patients are now positioned in slight reverse Trendelenburg position. Instead of a dual-pump irrigation fluid system, only inlet fluid is now actively pressurized and only to 60 mm Hg (from 100 mm Hg). The outflow of irrigation fluid is passive. The surgeons now emphasize fewer insertions of the hysteroscope into the cervix. The low Etco<sub>2</sub> alarm is set at 0.5 kPa (4 mm Hg) below the patient baseline. If the alarm is triggered, the surgeon is notified, and surgery is immediately paused until Etco<sub>2</sub> returns to baseline. The log sample rate has been decreased from 5-minute to 1-minute intervals, and if an Etco<sub>2</sub> alarm is triggered, sampling is even more frequent.

Fortunately, we have not experienced new episodes of detrimental VAE, but should it occur, our plan is to stop surgery and perform a transthoracic or transesophageal echocardiogram to confirm the diagnosis.

Pump irrigation systems are commonly used for hysteroscopy worldwide. Despite this, the occurrence of VAE using a pump system have not, to our knowledge, been compared to using gravity fall. One could speculate that the risk of delivery of air through the irrigation system could be reduced even further by changing from pump pressurization of the irrigation fluid to a delivery facilitated by gravity fall (to attain a fluid pressure of 100 mm Hg, the irrigation fluid would need to hang 1.35 m above the uterus). To our knowledge, this is feasible and still standard practice at some hospitals.<sup>17</sup> In the future, we would like to see irrigation lines fitted with air detectors, as seen in other medical devices such as heart-lung machines, dialysis machines, and IV infusion pumps. Such detectors have a very high sensitivity for air admixture and could alert personnel to irrigation line malfunctions.

In conclusion, perioperative air embolism is underrecognized, often subclinical, but sometimes fatal. All surgeons

and anesthesiologists need to be alert for early symptoms of VAE during hysteroscopic surgery, use appropriate monitoring, and be prepared to handle devastating consequences if they arise. ■■

## DISCLOSURES

**Name:** Storm S. Benjamin, MD, EDIC.

**Contribution:** This author helped participate in resuscitation and air evacuation of two of the patients, and write the manuscript.

**Name:** Andreasen Stine, MD, PhD.

**Contribution:** This author helped operate on one of the patients.

**Name:** Hovland Anders, MD, PhD.

**Contribution:** This author helped conduct the echocardiography during resuscitation.

**Name:** Erik W. Nielsen, MD, PhD, EDIC.

**Contribution:** This author gave anesthesia to one of the patients.

**This manuscript was handled by:** Raymond C. Roy, MD.

## REFERENCES

1. Austin LS, VanBeek C, Williams GR. Venous air embolism: an under-recognized and potentially catastrophic complication in orthopaedic surgery. *J Shoulder Elbow Surg.* 2013;22:1449–1454.
2. Leibowitz D, Benshalom N, Kaganov Y, Rott D, Hurwitz A, Hamani Y. The incidence and haemodynamic significance of gas emboli during operative hysteroscopy: a prospective echocardiographic study. *Eur J Echocardiogr.* 2010;11:429–431.
3. Munro MG, Christianson LA. Complications of hysteroscopic and uterine resectoscopic surgery. *Clin Obstet Gynecol.* 2015;58:765–797.
4. Mirski MA, Lele AV, Fitzsimmons L, Toung TJ. Diagnosis and treatment of vascular air embolism. *Anesthesiology.* 2007;106:164–177.
5. Sabovich I, Abel M, Lee CJ, Spinelli AD, Abramowicz AE. Air embolism during operative hysteroscopy: TEE-guided resuscitation. *J Clin Anesth.* 2012;24:480–486.
6. O'Dowd L, Kelly M. Air embolism. Available at: <http://www.uptodate.com/contents/air-embolism>. Accessed July 15, 2016.
7. Brill A, Loffer F. FDA summary of consensus opinion scientific panel on gynecare versapoint. September 22, 2000. Available at: [http://www.fda.gov/ohrms/dockets/ac/01/briefing/3753b2\\_02.htm](http://www.fda.gov/ohrms/dockets/ac/01/briefing/3753b2_02.htm). Accessed July 15, 2016.
8. Olsson J, Berglund L, Hahn RG. Irrigating fluid absorption from the intact uterus. *Br J Obstet Gynaecol.* 1996;103:558–561.
9. Kunkler A, King H. Comparison of air, oxygen and carbon dioxide embolization. *Ann Surg.* 1959;149:95–99.
10. Langø T, Mørland T, Brubakk AO. Diffusion coefficients and solubility coefficients for gases in biological fluids and tissues: a review. *Undersea Hyperb Med.* 1996;23:247–272.
11. Gordy S, Rowell S. Vascular air embolism. *Int J Crit Illn Inj Sci.* 2013;3:73–76.
12. Kapoor T, Gutierrez G. Air embolism as a cause of the systemic inflammatory response syndrome: a case report. *Crit Care.* 2003;7:R98–R100.
13. Smith RM, Van Hoesen KB, Neuman TS. Arterial gas embolism and hemoconcentration. *J Emerg Med.* 1994;12:147–153.
14. Huang KL, Lin YC. Activation of complement and neutrophils increases vascular permeability during air embolism. *Aviat Space Environ Med.* 1997;68:300–305.
15. Chan BC, Chan FH, Lam FK, Lui PW, Poon PW. Fast detection of venous air embolism in Doppler heart sound using the wavelet transform. *IEEE Trans Biomed Eng.* 1997;44:237–246.
16. Gill AL, Bell CN. Hyperbaric oxygen: its uses, mechanisms of action and outcomes. *QJM.* 2004;97:385–395.
17. Umrani S, Clark TJ, Saridogan E, et al; British Society for Gynaecological Endoscopy/European Society for Gynaecological Endoscopy Guideline Development Group for Management of Fluid Distension Media in Operative Hysteroscopy. BSGE/ESGE guideline on management of fluid distension media in operative hysteroscopy. *Gynecol Surg.* 2016;13:289–303.