

## CLINICAL THERAPEUTICS

# Endovascular Repair of Abdominal Aortic Aneurysm

Roger M. Greenhalgh, M.D., and Janet T. Powell, M.D., Ph.D.

*This Journal feature begins with a case vignette that includes a therapeutic recommendation. A discussion of the clinical problem and the mechanism of benefit of this form of therapy follows. Major clinical studies, the clinical use of this therapy, and potential adverse effects are reviewed. Relevant formal guidelines, if they exist, are presented. The article ends with the authors' clinical recommendations.*

A 72-year-old man who was a previous smoker had had transient ischemic attacks that were successfully managed with the use of carotid endarterectomy. Since about 10% of patients with cerebral arterial disease have occult abdominal aortic aneurysms,<sup>1</sup> abdominal ultrasonography was performed, which revealed an infrarenal abdominal aortic aneurysm 5.7 cm in diameter. Computed tomography (CT) confirmed the diagnosis.

The patient was assessed for the feasibility of open repair of the aneurysm under general anesthesia. Electrocardiography showed an old myocardial infarction; the forced expiratory volume in 1 second was within the normal range, at 2.4 liters per second, and the serum creatinine level was 86  $\mu$ mol per liter. The patient was taking an angiotensin-converting-enzyme inhibitor for hypertension, as well as low-dose aspirin.

The patient was considered fit for open repair on the basis of his medical condition, but review of his CT scan also indicated anatomical suitability for endovascular repair. This raised the question of whether the repair should be completed by means of the endovascular method or the open method.

## THE CLINICAL PROBLEM

The incidence of abdominal aortic aneurysm varies on the basis of age and sex; approximately 1.7% of women and 5% of men have an aortic diameter of 3.0 cm or more by the age of 65 years.<sup>2</sup> The prevalence of aneurysms greater than 3 cm in diameter increases by 6% per decade thereafter. A major risk factor for the development of abdominal aortic aneurysm is smoking, and more than 90% of patients with such aneurysms have been smokers. After the cessation of smoking, the risk of developing an aneurysm declines each year, to approximately one thirtieth of the original risk.<sup>3</sup>

Abdominal aortic aneurysm is frequently asymptomatic and often detected incidentally on abdominal imaging for another purpose. Although some aneurysms may become symptomatic (manifesting with abdominal or back pain), in many cases the first clinical manifestation is rupture.<sup>4</sup> The risk of rupture is low for aneurysms 5.5 cm or less in diameter, but above this threshold the risk increases markedly.<sup>5</sup> After an aneurysm ruptures, only approximately 25% of patients reach the hospital alive, and only 10% reach the operating room alive.<sup>4</sup> Even then, the operative mortality rate is in excess of 40%; this mortality rate has improved little over the years.<sup>6</sup> Fifty percent of patients with aneurysms 5.5 cm or more in diameter, who were not fit for operation, died within 2 years after the aneurysm was

From Imperial College London Vascular Surgery Research Group, London. Address reprint requests to Dr. Greenhalgh at the Vascular Surgery Research Group, Imperial College London, Charing Cross Hospital, Fulham Palace Rd., London W6 8RF, United Kingdom, or at r.greenhalgh@imperial.ac.uk.

N Engl J Med 2008;358:494-501.  
Copyright © 2008 Massachusetts Medical Society.

discovered.<sup>4</sup> Operations for rupture are among the most expensive. In one report from the United Kingdom in 2003, the median cost for management of an uncomplicated rupture was over £6000 more than for elective repair.<sup>7</sup>

In addition to the risk of rupture, patients with abdominal aortic aneurysms have an increased risk of other cardiovascular events, including death from cardiovascular causes. In one longitudinal study, of 110 deaths occurring in patients with aneurysms, only 6 were due to rupture.<sup>8</sup>

---

#### PATHOPHYSIOLOGY AND EFFECT OF THERAPY

---

Abdominal aortic aneurysms are more common in patients with atherosclerosis than in those without the disease, and there is a positive correlation between the presence of aneurysm and other cardiovascular disorders. For example, the screening for aneurysms in patients with intermittent claudication shows the incidence of aneurysm (10%) to be twice that in the general population.<sup>1</sup> Although hypertension has not been identified as a consistent risk factor in epidemiologic studies, a large, population-based, retrospective study has suggested that the risk of aortic rupture is reduced in patients who are taking angiotensin-converting-enzyme inhibitors.<sup>9</sup> Similarly, a post-hoc finding in the Endovascular Aneurysm Repair (EVAR) trial 2<sup>10</sup> was that statin therapy is associated with a halving of the rate of aneurysm rupture, and two small, retrospective studies have indicated that the use of statins reduces aneurysm growth rates.<sup>11,12</sup>

There are also important familial factors in the development of abdominal aortic aneurysm. Screening has shown that the incidence of aneurysm is increased from 5% in the general population to 20 to 30% among male siblings of patients with aneurysm.<sup>13</sup> Monogenic disorders associated with an increased risk of abdominal aortic aneurysm, such as Marfan's syndrome (caused by a fibrillin-1 defect) and Ehlers-Danlos syndrome type IV (due to abnormal type III procollagen), are rare. However, there is probably an underlying polygenetic predisposition to abdominal aortic aneurysm in most patients with the disease. Proteolytic destruction of extracellular matrix, atrophy of smooth-muscle cells, and inflammation are the biologic mechanisms thought to control aneurysm expansion.<sup>14</sup> The beneficial effect of

statins may be due, at least in part, to a reduction in the expression of several key proteolytic enzymes, including matrix metalloproteinase 9, in the aortic wall.<sup>15</sup>

Aneurysm repair is a mechanical solution to the problem of progressive expansion of abdominal aortic aneurysm and the risk of rupture. Although open surgical repair, which has been the established approach, is very effective, it carries substantial risks from the extensive surgical procedure. Endovascular repair was developed to reduce the risks associated with open surgery and to provide a treatment option for patients who are not deemed to be surgical candidates.

Endovascular repair varies somewhat, depending on the specific device used (Fig. 1). The endograft is a Y-shaped graft, with two branches for the iliac arteries and a main trunk for the proximal aorta. In a typical design, the endograft is modular, having two or three separate components. One component is for use in the main aortic trunk and in one limb of the iliac artery, with an opening for the attachment of the second component, which is deployed in the contralateral iliac artery. A third component can act as an extension of the longer limb of the main system, for more accurate positioning.

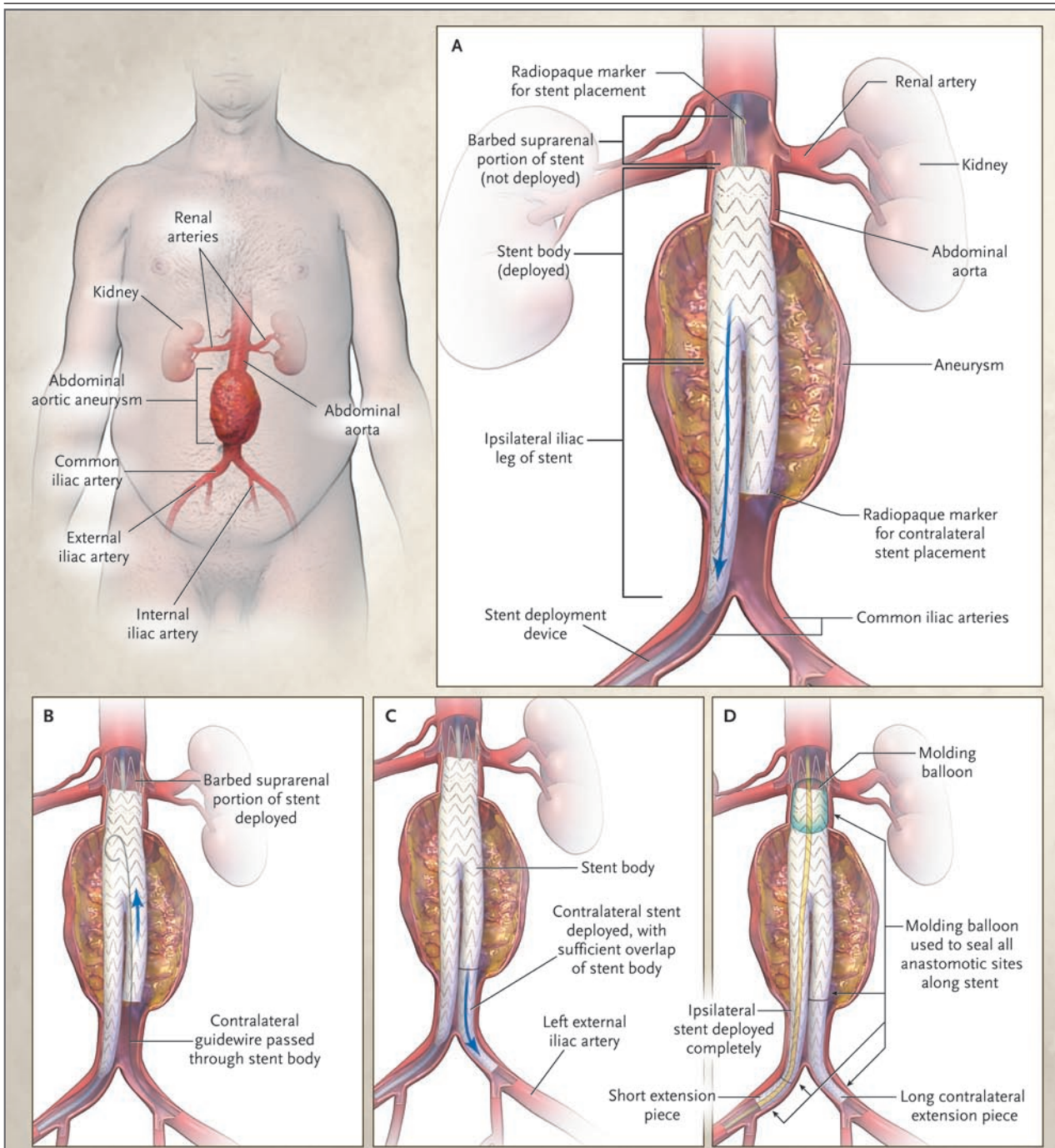
The endograft is made of a synthetic fabric and reinforced with stent struts that help to ensure rapid and stable expansion when it is deployed. The main component is inserted through the ipsilateral common femoral artery and is advanced into the infrarenal abdominal aorta (see the animated illustration, available with the full text of this article at [www.nejm.org](http://www.nejm.org)). The other, contralateral femoral artery is cannulated also. The proximal end of the endograft is deployed proximally to the neck of the aneurysm, and barbs or hooks are used to help achieve adequate fixation of the device and prevent distal migration. The ipsilateral distal end of the graft is deployed in the ipsilateral iliac artery, possibly including the separate extension component. The contralateral access site is used to deploy the contralateral iliac limb of the stent-graft. An endovascular balloon is inflated along the stent-graft to secure fixation of the anastomotic sites.

---

#### CLINICAL EVIDENCE

---

The EVAR trial 1<sup>16</sup> involved 1082 patients with abdominal aortic aneurysm who were healthy



**Figure 1. Endovascular Repair of an Abdominal Aortic Aneurysm, with the Use of an Endograft.**

Panel A shows the initial insertion of the endograft. The proximal end of the endograft is then deployed proximally to the neck of the aneurysm, and barbs or hooks are used to help achieve adequate fixation of the device and prevent distal migration (Panel B). The contralateral access site is used to deploy the contralateral iliac artery limb of the graft (Panel C). The ipsilateral distal end of the graft is deployed in the ipsilateral iliac artery, and an endovascular balloon is inflated along the stent-graft to secure fixation of the anastomotic sites (Panel D). Blue arrows indicate movement of the guidewire.

enough to be suitable candidates for surgery. They were randomly assigned to undergo either endovascular repair or open repair. The 30-day mortality rate was lower after endovascular repair (1.7%) than after open repair (4.7%,  $P < 0.001$ ). At 4 years, the aneurysm-related mortality rate in the endovascular-repair group was half that in the open-repair group ( $P = 0.04$ ), but there was no difference in mortality from any cause (26% for endovascular repair and 29% for open repair). Reinterventions were required more frequently in the endovascular-repair group (20%, vs. 6% in the open-repair group).

The Dutch Randomized Endovascular Aneurysm Management (DREAM) trial<sup>17</sup> had a design similar to that of EVAR 1 but was much smaller (351 patients). As in EVAR 1, the 30-day mortality rate was significantly lower among patients who had undergone endovascular repair than among those who had undergone open repair, but the overall survival rate was not different in the two groups at 2 years. Aneurysm-related death was more frequent with open repair, but reinterventions were required more often with endovascular repair.

In EVAR trial 2,<sup>18</sup> 338 patients with abdominal aortic aneurysm who were not candidates for open repair were randomly assigned to undergo either endovascular repair or no intervention in a setting of equal medical treatment in both groups. No benefit of endovascular repair was found during follow-up at any stage or by means of either intention-to-treat or per-protocol analyses. Complications and subsequent procedures were more frequent in the endovascular-repair group.

---

#### CLINICAL USE

---

The diagnosis of abdominal aortic aneurysm is usually made on ultrasonography and confirmed on CT or magnetic resonance imaging. In patients who are without symptoms, interventional management is generally recommended when the aneurysm exceeds 5.5 cm in diameter, becomes tender, or grows more than 1 cm in diameter per year.<sup>19,20</sup> These criteria are based on the trial protocols of the U.K. Small Aneurysm Trial<sup>21</sup> and the Aneurysm Detection and Management (ADAM) Veterans Affairs Cooperative Study.<sup>22</sup> Neither trial found any evidence that waiting until the criteria are met to perform open aneurysm repair, as com-

pared with intervening earlier, poses an increased risk to the patient.

Open surgical repair has been the established treatment option for abdominal aortic aneurysm. This form of therapy is associated with a greater use of intensive or critical care, a longer hospital stay, and more operative pain than endovascular repair and is always performed under general anesthesia. As noted in the Clinical Evidence section, open surgical repair is also associated with a higher 30-day mortality rate but with a lesser requirement for subsequent aneurysm-related procedures. Some patients are less suitable candidates for open repair because of coexisting medical conditions and a high surgical risk.

Endovascular repair has been used both in patients considered unfit and those considered fit for open repair. As noted in the Clinical Evidence section, however, the benefit of endovascular repair in patients who are not surgical candidates remains somewhat unclear. The EVAR trial 2, which did not confirm the expected benefit in that population, is the only trial that has been used to examine this issue. The analysis of data from the EVAR trial 1 has suggested that the fittest patients gain the greatest benefit, in terms of 30-day mortality rate, from treatment with endovascular repair rather than open repair.<sup>23</sup> All candidates for endovascular repair should undergo testing to evaluate known or suspected coexisting conditions, such as stress testing for coronary disease or pulmonary-function testing for chronic lung disease.

Endovascular repair is feasible only in patients who satisfy certain specific anatomical requirements, which are usually assessed by means of CT. Factors that influence the likelihood of technical success include the axial length of the aneurysm neck (the distance between the lowermost renal artery to the start of the aneurysm), the shape and angulation of the neck, the diameter of the iliac arteries (for access through the groin), and the potential length and condition of the distal iliac arteries that will be used as the distal sites of fixation of the stent-graft. It is important to take into account whether the iliac arteries have walls that are parallel or conical and whether thrombosis, calcification, or tortuosity is present near the intended final sites, since these factors can lead to a worse seal. Two series have suggested that as many as 54% of patients

with abdominal aortic aneurysms, or as few as 14%, met the routinely used anatomical criteria for endovascular repair.<sup>24,25</sup>

Preprocedural imaging is also vitally important in preparing the endograft. It is not possible to tailor the graft during the procedure, as in open repair. Instead, graft measurements must be determined precisely in advance of the operation. To do this satisfactorily, it is critical to be able to reconstruct the three-dimensional image of the CT scan. The imaging radiologist and interventionalist work together to define the vital measurements necessary to construct an endograft that will be optimally configured for the individual patient.

The endovascular repair procedure should be performed in an endovascular operating room or sterile angiography suite by a multidisciplinary staff that may include anesthesiologists, endovascular surgeons, and interventional radiologists. Either general or local anesthesia may be used. Fluoroscopy is used during the procedure to guide positioning of the endograft. The aorta is not clamped during deployment; the entire procedure is performed under systemic aortic pressure.

On completion of device implantation, CT angiography of the abdominal aorta is performed to confirm that the endograft is correctly placed and that the aneurysm has been completely excluded from the circulation. Most patients are hospitalized for 2 or 3 days.

CT angiography is usually repeated at 1 and 6 months after implantation and annually thereafter. If the procedure is successful, follow-up studies will typically show thrombosis of the aneurysm sac, with a gradual decrease in the diameter. The diameter of the aneurysm neck (at the most proximal end of the aneurysm) should be monitored carefully to be certain that no increase in diameter consistent with proximal extension of the aneurysm is detected.

In the EVAR trial 1, endovascular repair was more expensive than open repair (approximately £10,000 vs. £9,000 for the primary procedure and hospitalization, and approximately £13,000 vs. £10,000 for follow-up and subsequent procedures).<sup>16</sup> A similar difference in cost was noted in the DREAM trial (approximately €18,000 vs. €14,000 for the procedure and the first year of follow-up).<sup>26</sup> Much of this difference is accounted for by the cost of the endograft itself, which ranges from \$5,000 to \$10,000.

---

## ADVERSE EFFECTS

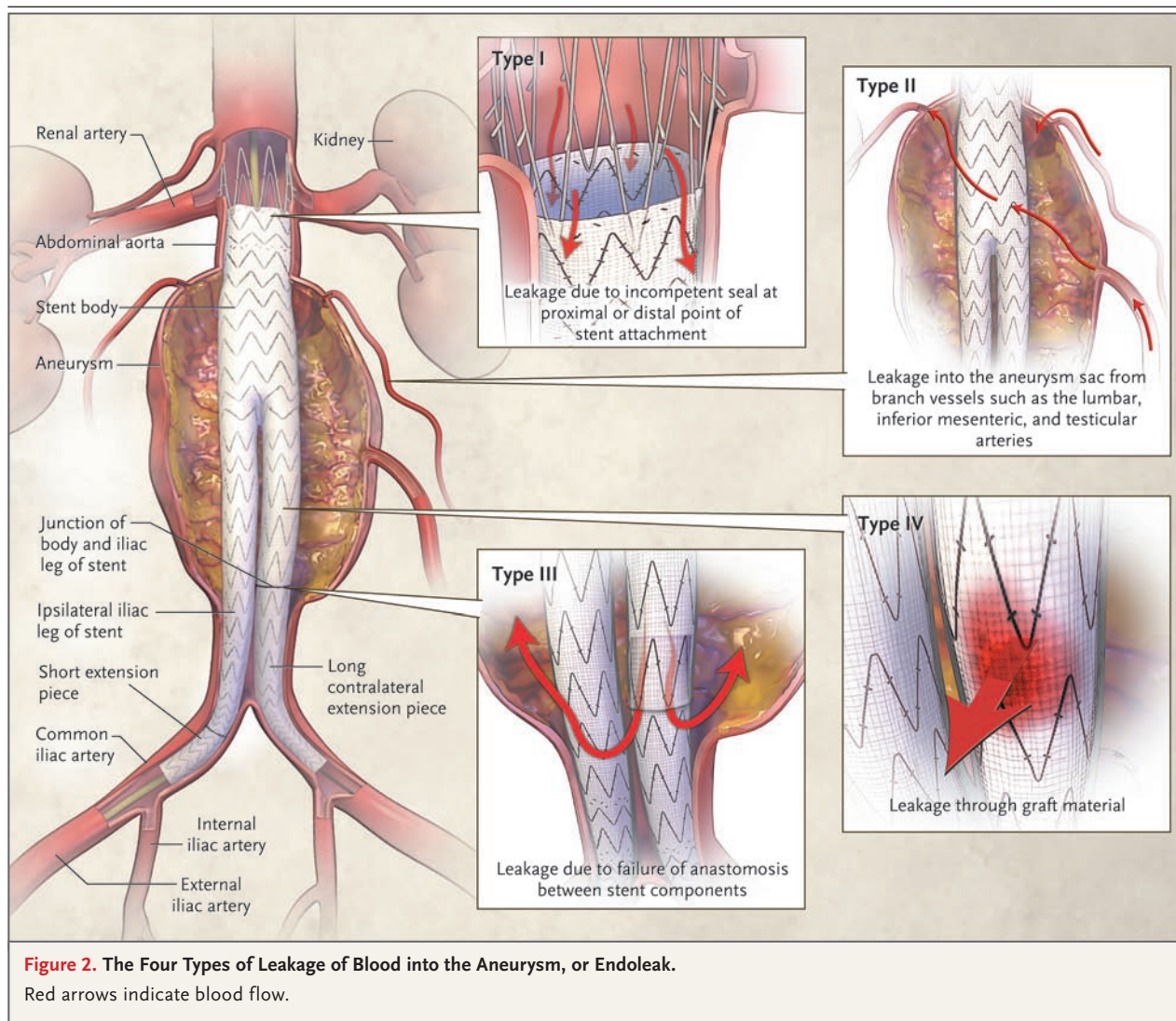
---

Endovascular repair of abdominal aortic aneurysm is a complex interventional procedure that is associated with a number of procedural risks. Vascular injury or perforation may occur during the procedure, sometimes leading to aneurysm rupture. In the EVAR trial 1, 4 of the 543 patients assigned to endovascular repair had aneurysm rupture, and the procedure was converted to an open repair.<sup>27</sup> Ischemic complications due to mechanical obstruction, thrombosis, or embolism can involve the legs and feet, colon, spinal cord, buttocks, or genitalia and have been reported in nearly 10% of patients, although rates may be lower with newer devices.<sup>28</sup> Renal complications may result from graft-related ischemia or the use of angiographic contrast dye.<sup>29</sup>

The effectiveness of endovascular repair depends on the sustained exclusion of blood flow from the aneurysm sac. In one large series, leakage of blood into the aneurysm, termed an endoleak, occurred in approximately 20% of patients with a mean follow-up of 15 months.<sup>30</sup> Endoleaks have been classified into four categories according to the site of leakage (Fig. 2). Type I endoleaks occur at the proximal or either distal anastomosis of the graft. Type II endoleaks occur as a result of collateral flow into the aneurysm from branch vessels such as the mesenteric or lumbar arteries. Type III endoleaks occur between the modular components of the endograft or through tears or defects in the graft. Type IV endoleaks occur through pores in the graft fabric. Although type II and IV endoleaks often resolve spontaneously, types I and III are potentially dangerous and require an additional procedure to repair.

Other complications that may require reintervention include graft migration (distal migration of the proximal anastomosis or proximal migration of either of the distal anastomoses), stenosis or occlusion of the graft or distal vessels, and expansion of either the proximal neck of the aneurysm or the iliac or common femoral arteries distal to the graft. In two large series, secondary procedures were required in 10% and 27% of patients at just over 2 years of follow-up.<sup>31,32</sup>

Given the incidence of endograft complications during the follow-up period, it is perhaps not unexpected that patients who do not undergo regular reevaluation are at greater risk of poor outcome. In a series of 302 patients, those who



had incomplete follow-up (more than two missed scheduled appointments) required urgent surgical intervention significantly more frequently than those with consistent follow-up (6.1% vs. 0.5%, at 30 months).<sup>33</sup>

#### AREAS OF UNCERTAINTY

The long-term durability of endovascular repair has not been definitively established. The major clinical trials have reported results for up to 4 years of follow-up.<sup>16-18</sup> Some observational studies report data from a longer follow-up period, but the procedures typically involved earlier devices, many of which have either been withdrawn from the market or replaced by newer models.<sup>34</sup>

The evolution of device design, although likely to improve the efficacy of endovascular repair, results in uncertainty about the long-term benefit and risk of the devices currently in use.

The ideal population of patients for endovascular repair is still being defined. Data from the EVAR trials suggest that the healthiest patients are the ones most likely to benefit from the procedure. At the same time, the healthiest patients are the ones most likely to tolerate open surgical repair with acceptable rates of postoperative complications and death. Thus, additional studies are needed to clarify the selection of patients.

Endovascular repair has also been used in the management of ruptured abdominal aortic aneurysms. Small series have shown that this approach

is feasible,<sup>35-37</sup> but well-designed trials will be necessary to determine whether endovascular management is a reasonable clinical option in the setting of aneurysm rupture.

#### GUIDELINES

The American College of Cardiology and the American Heart Association established guidelines in 2005 for the management of peripheral arterial disease that included recommendations for the management of abdominal aortic aneurysm.<sup>19</sup> These guidelines gave a class IIa recommendation (one for which the weight of evidence or opinion is in favor of usefulness or efficacy) to endovascular repair for patients at high surgical risk but only a class IIb recommendation (for which usefulness or efficacy is less well established by evidence or opinion) to endovascular repair in patients at low or average surgical risk. These recommendations are somewhat at odds with the trial data and clearly indicate the need for further studies to define the most appropriate population for this procedure.

#### RECOMMENDATIONS

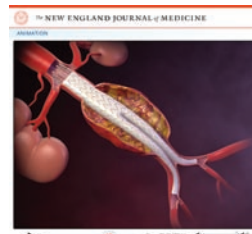The patient described in the vignette appears to be a suitable candidate for either endovascular or open repair. His only important coexisting medical conditions are a previous myocardial infarction and cerebrovascular disease. The CT scan should be reviewed carefully to be certain that

the patient's abdominal aortic anatomy is indeed amenable to an endovascular procedure.

This patient should then receive unbiased information about the findings of the trials, with a discussion of the advantages and disadvantages of both procedures. In essence, endovascular repair is associated with a lower early mortality rate but with a higher risk of subsequent need for reintervention and a less certain long-term outcome than with open repair. The patient should be warned that consistent and regular follow-up after the procedure will be essential, especially if he chooses endovascular repair. The technical demands of either an open or endovascular procedure make it important that, whichever approach he chooses, it should be performed by an experienced vascular surgeon or vascular interventionist at an established center.

Supported by the National Health Service Health Technology Assessment Programme.

Dr. Greenhalgh reports receiving grant support from Medtronic Vascular. No other potential conflict of interest relevant to this article was reported.



An animated illustration showing the deployment of an endovascular graft in an abdominal aortic aneurysm is available with the full text of this article at [www.nejm.org](http://www.nejm.org).

#### REFERENCES

- MacSweeney STR, O'Meara M, Alexander C, O'Malley MK, Powell JT, Greenhalgh RM. High prevalence of unsuspected abdominal aortic aneurysm in patients with confirmed symptomatic peripheral or cerebral arterial disease. *Br J Surg* 1993;80:582-4.
- Scott RA, Ashton HA, Kay DN. Abdominal aortic aneurysm in 4237 screened patients: prevalence, development and management over 6 years. *Br J Surg* 1991;78:1122-5.
- Wilkinson TBM, Quick CRG, Day NE. The association between cigarette smoking and abdominal aortic aneurysms. *J Vasc Surg* 1999;30:1099-105.
- Brown LC, Powell JT, UK Small Aneurysm Trial Participants. Risk factors for aneurysm rupture in patients kept under ultrasound surveillance. *Ann Surg* 1999;230:289-97.
- Lederle FA, Johnson GR, Wilson SE, et al. Rupture rate of large abdominal aortic aneurysms in patients refusing or unfit for elective repair. *JAMA* 2002;287:2968-72.
- Bown MJ, Sutton AJ, Bell PR, Sayers RD. A meta-analysis of 50 years of ruptured abdominal aortic aneurysm repair. *Br J Surg* 2002;89:714-30.
- Tang T, Lindop M, Munday I, Quick CR, Gaunt ME, Varty K. A cost analysis of surgery for ruptured abdominal aortic aneurysm. *Eur J Vasc Endovasc Surg* 2003;26:299-302.
- Newman AB, Arnold AM, Burke GL, O'Leary DH, Manolio TA. Cardiovascular disease and mortality in older adults with small abdominal aortic aneurysms detected by ultrasonography: the Cardiovascular Health Study. *Ann Intern Med* 2001;134:182-90.
- Hackam DG, Thiruchelvam D, Redelmeier DA. Angiotensin-converting enzyme inhibitors and aortic rupture: a population-based case-control study. *Lancet* 2006;368:659-65.
- Powell JT, Brown LC, Greenhalgh RM, Thompson SG. The rupture rate of large abdominal aortic aneurysms: is this modified by anatomical suitability for endovascular repair? *Ann Surg* 2008;247:173-9.
- Schouten O, van Laanen JH, Boesma E, et al. Statins are associated with a reduced infrarenal abdominal aortic aneurysm growth. *Eur J Vasc Endovasc Surg* 2006;32:21-6.
- Sukhija R, Aronow WS, Sandhu R, Kakar P, Babu S. Mortality and size of abdominal aortic aneurysm at long-term follow-up of patients not treated surgically and treated with and without statins. *Am J Cardiol* 2006;97:279-80.
- Baird PA, Sadovnick AD, Yee IM, Cole CW, Cole L. Sibling risks of abdominal aortic aneurysm. *Lancet* 1995;346:601-4.

14. Shimizu K, Mitchell RN, Libby P. Inflammation and cellular immune responses in abdominal aortic aneurysms. *Arterioscler Thromb Vasc Biol* 2006;26:987-94.
15. Golledge J, Powell JT. Medical management of abdominal aortic aneurysm. *Eur J Vasc Endovasc Surg* 2007;34:267-73.
16. EVAR Trial Participants. Endovascular aneurysm repair versus open repair in patients with abdominal aortic aneurysm (EVAR trial 1): randomised controlled trial. *Lancet* 2005;365:2179-86.
17. Blankensteijn JD, de Jong SECA, Prinsen M, et al. Two-year outcomes after conventional or endovascular repair of abdominal aortic aneurysms. *N Engl J Med* 2005;352:2398-405.
18. EVAR Trial Participants. Endovascular aneurysm repair and outcome in patients unfit for open repair of abdominal aortic aneurysm (EVAR trial 2): randomised controlled trial. *Lancet* 2005;365:2187-92.
19. Hirsch AT, Haskal ZJ, Hertzler NR, et al. ACC/AHA 2005 practice guidelines for the management of patients with peripheral arterial disease (lower extremity, renal, mesenteric, and abdominal aortic): a collaborative report from the American Association for Vascular Surgery/Society for Vascular Surgery, Society for Cardiovascular Angiography and Interventions, Society for Vascular Medicine and Biology, Society of Interventional Radiology, and the ACC/AHA Task Force on Practice Guidelines (Writing Committee to Develop Guidelines for the Management of Patients with Peripheral Arterial Disease): endorsed by the American Association of Cardiovascular and Pulmonary Rehabilitation; National Heart, Lung, and Blood Institute; Society for Vascular Nursing; TransAtlantic Inter-Society Consensus; and Vascular Disease Foundation. *Circulation* 2006;113(11):e463-e654.
20. Powell JT, Greenhalgh RM. Small abdominal aortic aneurysms. *N Engl J Med* 2003;348:1895-901.
21. Powell JT, Brown LC, Forbes JE, et al. Final 12-year follow-up of patients enrolled in the UK Small Aneurysm Trial. *Br J Surg* 2007;94:702-8.
22. Lederle FA, Wilson SE, Johnson GR, et al. Immediate repair compared with surveillance of small abdominal aortic aneurysms. *N Engl J Med* 2002;346:1437-44.
23. Brown LC, Greenhalgh RM, Howell S, Powell JT, Thompson SG. Patient fitness and survival after abdominal aortic aneurysm repair in patients from the UK EVAR trials. *Br J Surg* 2007;94:709-16.
24. Cotroneo AR, Iezzi R, Giancristofaro D, et al. Endovascular abdominal aortic aneurysm repair: how many patients are eligible for endovascular repair? *Radiol Med (Torino)* 2006;111:597-606.
25. Elkouri S, Martelli E, Gloviczki P, et al. Most patients with abdominal aortic aneurysm are not suitable for endovascular repair using currently approved bifurcated stent-grafts. *Vasc Endovascular Surg* 2004;38:401-12.
26. Prinssen M, Buskens E, de Jong SE, et al. Cost-effectiveness of conventional and endovascular repair of abdominal aortic aneurysms: results of a randomized trial. *J Vasc Surg* 2007;46:883-90.
27. Greenhalgh RM, Brown LC, Kwong GP, Powell JT, Thompson SG. Comparison of endovascular aneurysm repair with open repair in patients with abdominal aortic aneurysm (EVAR trial 1), 30-day operative mortality results: randomised controlled trial. *Lancet* 2004;364:843-8.
28. Maldonado TS, Ranson ME, Rockman CB, et al. Decreased ischemic complications after endovascular aortic aneurysm repair with newer devices. *Vasc Endovascular Surg* 2007;41:192-9.
29. Parmer SS, Carpenter JP, Endologix Investigators. Endovascular aneurysm repair with suprarenal vs infrarenal fixation: a study of renal effects. *J Vasc Surg* 2006;43:19-25.
30. van Marrewijk CJ, Buth J, Harris PL, Norgren L, Nevelsteen A, Wyatt MG. Significance of endoleaks after endovascular repair of abdominal aortic aneurysms: the EUROSTAR experience. *J Vasc Surg* 2002;35:461-73.
31. Brewster DC, Jones JE, Chung TK, et al. Long-term outcomes after endovascular abdominal aortic aneurysm repair: the first decade. *Ann Surg* 2006;244:426-38.
32. Becquemin JP, Kelley L, Zubilewicz T, Desgranges P, Lapeyre M, Kobeiter H. Outcomes of secondary interventions after abdominal aortic aneurysm endovascular repair. *J Vasc Surg* 2004;39:298-305.
33. Jones WB, Taylor SM, Kalbaugh CA, et al. Lost to follow-up: a potential underappreciated limitation of endovascular aneurysm repair. *J Vasc Surg* 2007;46:434-41.
34. Rutherford RB. Structural failures in abdominal aortic aneurysm stentgrafts: threat to durability and challenge to technology. *Semin Vasc Surg* 2004;17:294-7.
35. Larzon T, Lindgren R, Norgren L. Endovascular treatment of ruptured abdominal aortic aneurysms: a shift of the paradigm? *J Endovasc Ther* 2005;12:548-55.
36. Moore R, Nutley M, Cina CS, Motamedi M, Faris P, Abuznadah W. Improved survival after introduction of an emergency endovascular therapy protocol for ruptured abdominal aortic aneurysms. *J Vasc Surg* 2007;45:443-50.
37. Ockert S, Schumacher H, Böckler D, Megges I, Allenberg JR. Early and mid-term results after open and endovascular repair of ruptured abdominal aortic aneurysms in a comparative analysis. *J Endovasc Ther* 2007;14:324-32.

Copyright © 2008 Massachusetts Medical Society.

**COLLECTIONS OF ARTICLES ON THE JOURNAL'S WEB SITE**

The *Journal's* Web site ([www.nejm.org](http://www.nejm.org)) sorts published articles into more than 50 distinct clinical collections, which can be used as convenient entry points to clinical content. In each collection, articles are cited in reverse chronological order, with the most recent first.