

HOSTED BY



ELSEVIER

Contents lists available at ScienceDirect

Journal of Acute Disease

journal homepage: [www.jadweb.org](http://www.jadweb.org)Case report <http://dx.doi.org/10.1016/j.joad.2015.06.018>

## A case of acute ischemic colitis after endovascular abdominal aortic aneurysm repair

Grigorios Voulalas<sup>1\*</sup>, Chrisostomos Maltezos<sup>2</sup><sup>1</sup>Vascular Surgery Unit, A' Propaedeutic Surgical Clinic, Ahepa University Hospital of Thessaloniki, Thessaloniki, Greece<sup>2</sup>Vascular Surgery Clinic, KAT General Hospital, Athens, Greece

### ARTICLE INFO

#### Article history:

Received 16 Jun 2015

Received in revised form 19 Jun,

2nd revised form 22 Jun 2015

Accepted 26 Jun 2015

Available online 9 Oct 2015

#### Keywords:

Ischemic colitis

Endovascular abdominal aortic

aneurysm repair

Hypogastric arteries

Embolization

### ABSTRACT

Colonic ischemia is a recognized complication of either open or endovascular abdominal aortic aneurysm repair. The clinical difficulty in establishing the diagnosis, the severity of this complication and the patient's poor physiological status may lead to a fatal outcome. We presented a case of ischemic colitis in a patient with patent hypogastric arteries that occurred after an endovascular abdominal aortic aneurysm repair as well as a review of the available literature. The patient's preoperative, intraoperative and postoperative data were recorded. A thorough search through the Google data and Medline to review similar cases or any analyses that referred to ischemic colitis after endovascular abdominal aneurysm repair was conducted. A 76-year-old male was admitted to our department for an elective endovascular repair of an 8 cm in diameter abdominal aortic aneurysm. A Zenith bifurcation graft was implanted. The whole procedure was uneventful and the final angiogram showed an accurate deployment of the endograft without endoleaks and patency of both hypogastric arteries. During the 1st postoperative day, the patient developed symptoms of acute abdomen in combination with metabolic acidosis and oliguria. He underwent an exploratory laparotomy, which revealed necrosis of the sigmoid. A Hartmann's procedure was performed; the patient was transferred to the intensive care unit where he deceased after 24 h. Postoperative ischemic colitis has been described after open abdominal aneurysm repair. The description of this complication has been reported since the early phase of endovascular abdominal aneurysm repair development with a current incidence of 1.5%–3.0%. Possible mechanisms that may contribute to ischemic colitis in spite of the presence of patent hypogastric arteries include attheroembolization, shock, vasopressive drugs and inferior mesenteric artery occlusion.

## 1. Introduction

Physiologically, the arterial circulation to the gut is served by three unpaired anterior branches of aorta, namely, celiac trunk, superior mesenteric artery and inferior mesenteric artery (IMA). The main collateral channels between the superior mesenteric artery and IMA occur in the region of the splenic flexure and middle colic arteries through the marginal artery of Drummond and the arch of Riolan. In the presence of an IMA occlusion, another important collateral circulation is between internal iliac artery and the left colic artery via the superior hemorrhoidal arteries.

Colon ischemia is a devastating complication following aorto-iliac surgery. Severity varies from mucosal to transmural ischemia with a mortality rate that reaches to 100% in some reports<sup>[1]</sup>. Three forms of ischemic colitis are described: (1) mucosal ischemia which is transient; (2) mucosal and muscularis involvement which may result in healing with fibrosis and stricture formation and (3) transmural ischemia or infarction, which results in gangrene and perforation. Following open repair, the incidence of clinically significant colonic ischemia ranges from 1%–3% after elective surgery and 10% in cases of rupture<sup>[2,3]</sup>. Stokmans *et al.* reported an incidence of bowel ischemia of 0.5% in symptomatic and 0.2% in asymptomatic abdominal aortic aneurysms in patients undergoing an endovascular procedure<sup>[4]</sup>. Neary *et al.* showed that the overall incidence of colonic infarction in a total number of 405 patients was 2.2% after open aorto-iliac surgery, whereas in patients operated on an elective basis, the

\*Corresponding author: Grigorios Voulalas, Vascular Surgery Unit, A' Propaedeutic Surgical Clinic, Ahepa University Hospital of Thessaloniki, Thessaloniki, Greece.

E-mail: [grigoriosvoulalas@yahoo.com](mailto:grigoriosvoulalas@yahoo.com)

Peer review under responsibility of Hainan Medical College.

incidence was 0.8% and the mortality rate associated with colonic infarction was 89%<sup>[5]</sup>.

Endovascular abdominal aortic aneurysm repair (EVAR) has been proven to be an attractive and alternative method to open surgery and has a lower rate of postoperative morbidity and mortality in carefully selected patients. However, ischemic complications such as colon ischemia have been reported since the early phase of EVAR with a current incidence of 1.5%–3.0%<sup>[6]</sup>.

Several possible mechanisms have been advocated. EVAR may be complicated by difficult iliac artery anatomy, making it necessary to occlude the flow to one or both hypogastric arteries in order to ensure proper seal around the aorto-iliac endograft. Hypogastric artery occlusion may also be necessary for successful endovascular repair of common iliac or external iliac artery aneurysms. Endovascular aneurysm repair with extension of the stent graft to the external iliac artery and embolization of the hypogastric artery can be associated with more complications and worse long-term results compared with simple endovascular aneurysm repair<sup>[7]</sup>. The reported side effects associated with bilateral hypogastric artery occlusion include buttock claudication, impotence and more serious sequelae such as colonic and spinal cord ischemia<sup>[8]</sup>. Papazoglou *et al.* reported 13.1% incidence of buttock claudication but no colonic ischemia after selective hypogastric artery coverage without coil embolization<sup>[9]</sup>. However, the causes of colonic ischemia development in spite of the presence of patency of both hypogastric arteries still remain ambiguous. Possible mechanisms that have been advocated include embolization, shock, use of vasopressive drugs and hypotension. Hypoperfusion of the left colon due to systemic hypotension may contribute to ischemic colitis than occlusion of hypogastric arteries<sup>[10]</sup>. Other factors have also been independently associated with colonic ischemia.

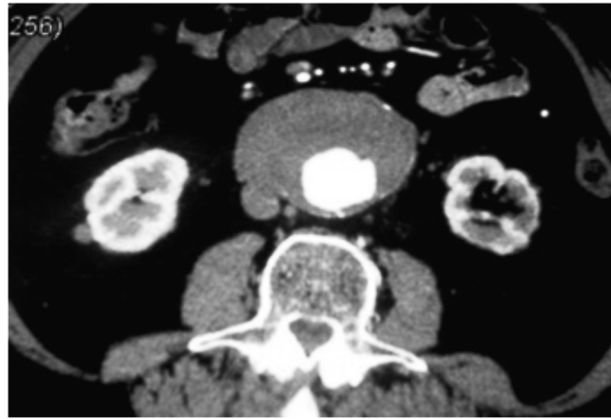
Over the past 2 years, we performed nearly 200 EVAR procedures with a bifurcation endoprosthesis implantation. We presented the case of a male patient who developed colonic ischemia after EVAR.

## 2. Case report

A 76-year-old male was admitted to our department for an elective repair of abdominal aortic aneurysm that was found accidentally during an ultrasound examination for prostatic hypertrophy. His personal history included coronary artery disease for which he was treated with percutaneous transluminal coronary angioplasty 4 years ago, arterial hypertension, hyperlipidemia, psoriasis vulgaris, anemia of unknown etiology and chronic obstructive pulmonary disease (all under medication).

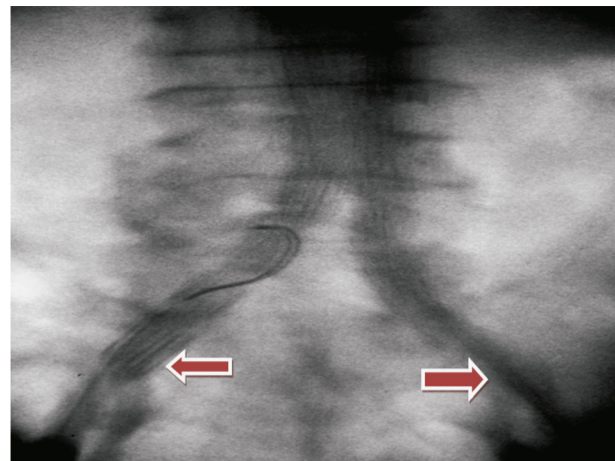
A computed tomographic angiography of the abdominal aorta was performed, which showed the presence of an infrarenal aortic aneurysm, 8 cm in diameter (Figure 1). Taking into consideration the comorbidities, it was suggested that an endovascular approach would be more appropriate for him since the aneurysm had all the anatomic prerequisites for EVAR. In addition, the patient preferred to be treated by the endovascular method. Since no other contraindications existed, we performed endovascular implantation of a Zenith bifurcation endoprosthesis under regional anesthesia.

The intraoperative period was uneventful with no apparent difficulty in the deployment of the main body and the catheterization of the contralateral limb. The final angiogram



**Figure 1.** CT angiography showing an infrarenal aortic aneurysm, 8 cm in diameter.

confirmed the accurate position of the stent graft, the patency of the renal and hypogastric arteries bilaterally while it corroborated the absence of any kinds of endoleak (Figure 2). Post-



**Figure 2.** Intraoperative final angiography showing patency of both hypogastric arteries.

operatively, the patient had palpable peripheral pulses bilaterally.

Although an uncomplicated postoperative period was expected, he developed oliguria and metabolic acidosis in arterial blood gases 24 h after the procedure with no signs of acute abdomen. A couple of hours later, he presented with leukocytosis, fever and symptoms of acute abdomen with inability to raise his left lower limb, anuria and deterioration of the acidosis as well as an increase in creatinine phosphokinase and lactate dehydrogenase values in peripheral blood samples. The aggravated clinical status of the patient led to an urgent exploratory laparotomy which revealed necrosis of the sigmoid. A Hartmann's procedure was performed and the patient was transferred to the intensive care unit where he deceased after 24 h suffering from multiple organ dysfunction.

## 3. Discussion

Although EVAR is associated with less morbidity and mortality in comparison with open aneurysm repair, ischemic complications are not exceptional. The reported side effects associated with bilateral hypogastric artery occlusion include buttock claudication, impotence and more serious complications

such as colonic and spinal cord ischemia. Ischemic complications such as colon ischemia have been reported since the early phase of EVAR with a current incidence of 1.5%–3.0%<sup>[6]</sup>. There are reports of 0.5% incidence of ischemic colitis after either open or endovascular abdominal aneurysm repair, whereas other mention a 0.2% after EVAR and a 3% after open repair<sup>[11–13]</sup>. The spectrum of ischemia in the colon when evaluated at endoscopy ranges from mild edema to pseudomembranes formation.

Dadian *et al.* reported 8 cases of colon ischemia in 278 patients after EVAR with an incidence of 2.9%<sup>[14]</sup>. They performed embolization of one or both hypogastric arteries (109 and 13 patients respectively) and they concluded that unilateral and bilateral hypogastric artery interruptions during EVAR didn't appear to cause colon ischemia. In opposition, there was evidence of microembolization in the patients that developed colon ischemia. They also proposed that widespread atheroembolization was associated with a poorer prognosis than isolated colon ischemia. However, Hosaka *et al.* mentioned that unilateral occlusion of hypogastric arteries followed by EVAR is a relatively safe technique, whereas bilateral hypogastric artery embolization can lead to severe ischemic complications<sup>[15]</sup>.

Maldonado *et al.* reported 4 cases of colonic ischemia in 311 patients treated with EVAR<sup>[6]</sup>. One of the patients had unilateral hypogastric artery embolization before the original surgery. Therefore, they presumed that mechanisms that may contribute to pelvic ischemia include interruption of hypogastric arterial circulation and atheroembolization.

Mehta *et al.* reviewed a series of 154 patients in whom hypogastric arteries were interrupted as a part of either open ( $n = 47$ ) or endovascular ( $n = 107$ ) repair, and found no patients with ischemic colitis that required laparotomy<sup>[16]</sup>. These authors concluded that hypogastric artery embolization as part of EVAR can be done safely without significant risk for severe pelvic ischemia. Chun *et al.* marked that buttock claudication was reported in 38% of cases, whereas new onset erectile dysfunction occurred in 10% of cases when embolization of hypogastric artery was performed before EVAR<sup>[17]</sup>. Yano *et al.* reported high rates of bowel ischemia with hypogastric artery exclusion after EVAR, attributed to stenosis of the ipsilateral femoral artery<sup>[18]</sup>. Most authors agreed that when bilateral hypogastric artery embolization is planned, EVAR should be delayed by 2–4 weeks. In spite of this, Angiletta *et al.* described a case where there was postoperative paraplegia, buttock ischemia and ischemic colitis development despite the sequential hypogastric artery embolization<sup>[19]</sup>.

Although, hypogastric artery interruption by either embolization or occlusion due to anatomic variations in order to ensure proper seal around the bifurcation stent graft can cause colonic ischemia sensibly-in spite of the fact that this notion has not been adopted by some authors, the causes of colonic ischemia development even when both hypogastric arteries remain patent are still under debate. Lee *et al.* suggested shock, use of vaso-pressive drugs and atheroembolization as the presumed causes of colonic ischemia, whereas Becquemin *et al.* showed that aneurysm rupture, length of operation (> 4 h) and preoperative renal insufficiency were independently associated with postoperative colonic ischemia<sup>[20,21]</sup>.

In another study, Perry *et al.* revealed that the strongest predictor of colonic ischemia development was ruptured due to abdominal aortic aneurysm<sup>[22]</sup>, an observation that comes in

agreement with that of Becquemin *et al.*<sup>[21]</sup>. In the setting of elective repair, they showed that open repair was the strongest predictor of the development of colonic ischemia. However, when the entire cohort was analyzed, the female gender increased the risk of developing colonic ischemia by 60%. The colonic ischemia mortality rate was 37.8%. Their study demonstrated a similar risk after EVAR (0.5%) compared with open abdominal aneurysm repair (1.9%). When routine postoperative colonoscopy is performed, the incidence reaches 5%–9% after elective surgery and 15%–60% following rupture<sup>[23]</sup>.

Microembolization is a major cause of both small and large bowel ischemia after EVAR<sup>[24]</sup>. The presence of a shaggy aorta and a history of smoking are independent predictors of embolic complications associated with EVAR<sup>[25]</sup>. To prevent it, Zhang *et al.* recommended the following: (1) a careful review of preoperative images should be conducted in order to identify thrombus or atheroma in the neck of the aneurysm; (2) perform only minimal manipulations during stent graft deployment; (3) a direct deployment of the stent graft immediately inferior to the renal arteries should be performed, rather than dragging it down from above and (4) an open repair of the aneurysm should be considered if a large amount of thrombus is present in the proximal aneurysm neck<sup>[1]</sup>.

Taking into consideration the fact that colonic ischemia development in spite of the presence of patent hypogastric arteries can be attributed to thrombus or atheroma embolization, the treatment of embolizing abdominal aneurysms with endovascular stent grafts should often be considered exceedingly high risk, because of the well-founded concern that the unstable plaque or thrombus will dislodge as a result of catheter and wire manipulations before deployment.

To come to a conclusion, colonic ischemia can be a devastating complication after EVAR even when both hypogastric arteries remain patent after the procedure. Therefore, we should not be complacent since the lower index of suspicion may result in more advanced presentations of colonic ischemia at the time of diagnosis.

## Conflict of interest statement

The authors report no conflict of interest.

## References

- [1] Zhang WW, Kulaylat MN, Anain PM, Dosluoglu HH, Harris LM, Cherr GS, et al. Embolization as cause of bowel ischemia after endovascular abdominal aortic aneurysm repair. *J Vasc Surg* 2004; **40**: 867-72.
- [2] Van Damme H, Creemers E, Limet R. Ischaemic colitis following aortoiliac surgery. *Acta Chir Belg* 2000; **100**: 21-7.
- [3] Björck M, Tröng T, Bergqvist D. Risk factors for intestinal ischaemia after aortoiliac surgery: a combined cohort and case-control study of 2824 operations. *Eur J Vasc Endovasc Surg* 1997; **13**: 531-9.
- [4] Stokmans RA, Tejjink JA, Cuypers PW, Rimbau V, van Sambeek MR. No differences in perioperative outcome between symptomatic and asymptomatic AAAs after EVAR: an analysis from the ENGAGE Registry. *Eur J Vasc Endovasc Surg* 2012; **43**(6): 667-73.
- [5] Neary P, Hurson C, Briain DO, Brabazon A, Mehigan D, Keaveny TV, et al. Abdominal aortic aneurysm repair and colonic infarction: a risk factor appraisal. *Colorectal Dis* 2007; **9**: 166-72.

- [6] Maldonado TS, Rockman CB, Riles E, Douglas D, Adelman MA, Jacobowitz GR, et al. Ischemic complications after endovascular abdominal aortic aneurysm repair. *J Vasc Surg* 2004; **40**: 703-10.
- [7] Kalteis M, Gangl O, Huber F, Adelsgruber P, Kastner M, Lugmayr H. Clinical impact of hypogastric artery occlusion in endovascular aneurysm repair. *Vascular* 2014; <http://dx.doi.org/10.1177/1708538114560462>.
- [8] Pavlidis D, Hörmann M, Libicher M, Gawenda M, Brunkwall J. Buttock claudication after interventional occlusion of the hypogastric artery—a mid-term follow-up. *Vasc Endovasc Surg* 2012; **46**(3): 236-41.
- [9] Papazoglou KO, Sfyroeras GS, Zambas N, Konstantinidis K, Kakkos SK, Mitka M. Outcomes of endovascular aneurysm repair with selective internal iliac artery coverage without coil embolization. *J Vasc Surg* 2012; **56**(2): 298-303.
- [10] Kim H, Kwon TW, Cho YP, Moon KM. Report of a case of ischemic colitis with bilaterally patent internal iliac arteries after endovascular abdominal aneurysm repair. *J Korean Surg Soc* 2012; **82**(3): 200-3.
- [11] Quinney BE, Parmar GM, Nagre SB, Patterson M, Passman MA, Taylor S, et al. Long-term single institution comparison of endovascular aneurysm repair and open aortic aneurysm repair. *J Vasc Surg* 2011; **54**(6): 1592-8.
- [12] Wisniewski B, Barnes M, Jenkins J, Boyne N, Kruger A, Walker PJ. Predictors of outcome after elective endovascular abdominal aortic aneurysm repair and external validation of a risk prediction model. *J Vasc Surg* 2011; **54**(3): 644-53.
- [13] de la Motte L, Jensen LP, Vogt K, Kehlet H, Schroeder TV, Lonn L. Outcomes after elective aortic aneurysm repair: a nationwide Danish cohort study 2007-1010. *Eur J Endovasc Vasc Surg* 2013; **46**(1): 57-64.
- [14] Dadian N, Ohki T, Veith FJ, Edelman M, Mehta M, Lipsitz EC, et al. Overt colon ischemia after endovascular aneurysm repair: the importance of microembolization as an etiology. *J Vasc Surg* 2001; **34**: 986-96.
- [15] Hosaka A, Kato M, Kato I, Isshiki S, Okubo N. Outcome after concomitant unilateral embolization of the internal iliac artery and contralateral external-to-internal iliac artery bypass grafting during endovascular aneurysm repair. *J Vasc Surg* 2011; **54**(4): 960-4.
- [16] Mehta M, Veith FJ, Ohki T, Cynamon J, Goldstein K, Suggs WD, et al. Unilateral and bilateral hypogastric artery interruption during aortoiliac aneurysm repair in 154 patients: a relatively innocuous procedure. *J Vasc Surg* 2001; **33**(Suppl 2): S27-32.
- [17] Chun JY, Mailli L, Abbasi MA, Belli AM, Gonsalves M, Munneke G, et al. Embolization of the internal iliac artery before EVAR: is it effective? Is it safe? Which technique should be used? *Cardiovasc Intervent Radiol* 2014; **37**(2): 329-36.
- [18] Yano OJ, Morrissey N, Eisen L, Faries PL, Soundararajan K, Wan S, et al. Intentional internal iliac artery occlusion to facilitate endovascular repair of aortoiliac aneurysms. *J Vasc Surg* 2001; **34**: 204-11.
- [19] Angiletta D, Marinazzo D, Guido G, Greco L, Regina G. Spinal cord, bowel, and buttock ischemia after endovascular aneurysm repair. *Ann Vasc Surg* 2011; **25**(7): 980.e15-9.
- [20] Lee C, Dougherty M, Calligaro K. Concomitant unilateral internal iliac artery embolization and endovascular infrarenal aortic aneurysm repair. *J Vasc Surg* 2006; **43**: 903-7.
- [21] Becquemin JP, Majewski M, Fermani N, Marzelle J, Desgrandes P, Allaire E, et al. Colon ischemia following abdominal aortic aneurysm repair in the era of endovascular abdominal aortic repair. *J Vasc Surg* 2008; **47**: 258-63.
- [22] Perry RJT, Martin MJ, Eckert MJ, Sohn VY, Steele SR. Colonic ischemia complicating open vs endovascular abdominal aortic aneurysm repair. *J Vasc Surg* 2008; **48**: 272-7.
- [23] Champagne BJ, Darling RC 3rd, Daneshmand M, Kreienberg PB, Lee EC, Mehta M, et al. Outcome of aggressive surveillance colonoscopy in ruptured abdominal aortic aneurysm. *J Vasc Surg* 2004; **39**: 792-6.
- [24] Hoshina K, Hosaka A, Takayama T, Kato M, Ohkubo N, Okamoto H, et al. Outcomes after open surgery and endovascular aneurysm repair for abdominal aortic aneurysm in patients with massive neck atheroma. *Eur J Vasc Endovasc Surg* 2012; **43**(3): 257-61.
- [25] Toya N, Baba T, Kanaoka Y, Ohki T. Embolic complications after endovascular repair of abdominal aortic aneurysms. *Surg Today* 2014; **44**(10): 1893-9.