



reviews

Jugular Wave Recognition Breakthrough*

X' Descent vs the X Descent and Trough

Jules Constant, MD

Irrational nomenclature and concentrating on ascents and peaks of waves have made recognition of jugular waves an occult art. By agreeing to call atrial relaxation X and the systolic fall in atrial pressure due to the descent of the base X', we can begin to teach the easy recognition of jugular contours. Next, it is necessary to realize that the artifacts seen on electronically derived jugular pulse tracings are not to be expected when observing the neck pulsations with the naked eye. Finally, it can be shown that the easiest way to recognize jugular waves is by timing only descents as being either systolic or diastolic according to their relation to either the patient's radial pulse or heart sounds. It is almost unknown that only a single systolic descent due to the descent of the base is usual in the normal adult jugular. (CHEST 2000; 118:1788-1791)

Key words: atrial fibrillation; C wave; jugular waves; right atrial pressure; venous pulse; X descent; X'; X trough

The nomenclature for jugular contours is confused in the literature, as shown by the fact that the same name has been applied to phenomena with different physiological bases, and a multitude of names have been applied to the presystolic and systolic descents. This has made the recognition of jugular contours an occult art reserved for those who, after years of practice, manage to ignore the confusion in the literature. This review is an attempt to show that when a rational nomenclature is embraced, the recognition of jugular contours can be widely taught.

THE X DESCENT

Because jugular contours reflect right atrial contours, an analysis of the latter is relevant to understanding jugular waves. Atrial contraction or systole signaled by the P wave produces a rise in atrial pressure. Rises in atrial pressure are not given names. Only waves and falls in the pressure or descents are given names. Atrial relaxation produces

a fall in atrial pressure, and the wave produced by the rise and fall of atrial pressure is known universally as the A wave. The fall due to atrial relaxation (atrial diastole) has been called X by at least 14 authors, not named at all by at least 13, and called Z by 1 author.¹ Since the majority of authors who did name it called it X, there is no reason for changing this, especially when we learn that X was the name given to it by Mackenzie in his 1902 book, *The Study of Pulse*, which became the most widely quoted source of pulse contour material in the world literature for many decades.²

THE C WAVE AND X' DESCENT

Ventricular contraction pushes up the tricuspid valve and raises pressure in the right atrium to a slight degree. Rises in atrial pressures are not named. However, when the right ventricle contracts, it pushes the tricuspid valve up, producing a slight rise; and then, because it draws the floor of the atrium down, it produces a prominent fall in pressure. The resulting slight rise and fall produces a small wave, the C wave. In the right atrium, this mechanism is always the cause of the C wave; but in the jugulars, the carotid expansion at the same time as the right atrial C wave produces an artifactual bulge of varying

*From the State University of New York at Buffalo, Buffalo, NY. Manuscript received December 22, 1999; revision accepted March 29, 2000.

Correspondence to: Jules Constant, MD, 57 Tillinghast Place, Buffalo, NY 14216-3408

degrees that can be seen as an artifact in the jugular pulse tracing, but which cannot be seen with the naked eye. One can obtain various amplitudes of jugular C waves by merely varying the pressure or the site of the pickup.

Cineangiograms and echocardiograms demonstrate that the base of the ventricle (floor of the atrium) descends toward the apex with ventricular systole. Physiologists have called this *the descent of the base*, meaning the descent of the AV ring. Since the atrial walls are attached to the surrounding structures, pulling down of the atrial floor causes a fall in atrial pressure. In the jugulars, this systolic fall in venous pressure has been called by physiologists the *systolic collapse of the venous pulse*. Several other explanations for the systolic jugular descents, such as atrial relaxation during ventricular systole and loss of thoracic blood secondary to left ventricular ejection, cannot be defended for the explanation of right atrial events.

The letters given to designate this systolic venous collapse during the descent of the base is remarkably varied and confusing. At least 14 authors have avoided the problem by not naming it at all.¹ At least seven authors combine it with atrial relaxation and call it X.¹ It is called X' by eight authors.¹ There were at least 16 authors who thought it unnecessary to give a separate name to the two descents, despite the fact that they have entirely separate mechanisms.¹

HISTORY OF THE X'

In 1907, an article by Mackenzie on jugular pulse tracings showed a systolic descent in a patient with first degree AV block.³ This descent was obviously not related to atrial events. Because he had labeled atrial relaxation X, he knew that he could not give the systolic jugular descent the same name, so he hit on a compromise term of X'. In describing the mechanism for this systolic fall in jugular pressure, he reflected his confusion by stating that "dragging down of the auricular ventricular septum during ventricular systole is the major cause of the X." He did not use the term X' in his explanation. He stated that how much of the X descent is due to descent of the base is unknown, except in AV block, and he never used the term X' again and labeled all subsequent systolic depressions as X. He was apparently unable to completely contradict the statement in his book of 1902, in which he had written that "the great fall X is due to diastole of the auricle."² Perhaps he was too much under the influence of the great French cardiologist Potain, who in 1867 had published the first simultaneous jugular, carotid, and

apical pulse tracings⁴ (20 years before Mackenzie's publication), and ascribed the systolic jugular descent to atrial diastole.

In 1925, Thomas Lewis, another powerful influence in cardiology, used the letter X' to label the descent of the base in his book *Mechanisms and Graphic Registration of the Heartbeat*.⁵ Braunwald's chapter on physical examination in his edited textbook *Heart Disease* does describe the X' descent in the text, but his illustration designates the "systolic dip" as X.⁶ In the third chapter by Craig, the term X' is used not only in an illustration but also in the text. He described the X' descent as one of the most prominent features of the jugular venous pressure tracing. Although there are several books since 1925 showing an X', I could find only six articles that separated the terminology for the effect of atrial relaxation from that of the descent of the base. The first was by Ronald Gibson of London, who reintroduced the term to his colleague Paul Wood as well as to me in 1959, after he noticed a systolic descent in a patient with atrial fibrillation. He published it in abstract form in 1973.⁷ The other five articles appeared in 1974,¹ and 1978,⁸ 1989,^{9,10} and 1993.¹¹

THE X' IN ATRIAL FIBRILLATION

For the vast majority of physicians who name the atrial relaxation descent X, it is especially convenient to use the term X' when atrial fibrillation eliminates any atrial contribution to the jugular contours. In atrial fibrillation, a Y descent is usually dominant. The X' is attenuated presumably due to the poor right ventricular contraction, partly resulting from the absence of the atrial booster pump at the end of diastole (absent "atrial kick") and partly due to varying degrees of tricuspid regurgitation that is usually present, especially if there is any elevation of venous pressure. This points to the desirability of teaching physicians to observe and name descents rather than waves; otherwise, they have to be burdened with learning the terminology for the diastolic wave preceding the systolic collapse (the H wave).

Paul Wood believed that the systolic descent must be due to atrial relaxation because it disappeared in atrial fibrillation. However, that there is a systolic descent in atrial fibrillation is easily confirmed by any laboratory that does jugular pulse tracings routinely. Mackenzie in his 1913 book, *Diseases of the Heart*,¹² showed a systolic descent in atrial fibrillation that he labeled X'. He showed another tracing of the same patient at another time, still in fibrillation, in which the X' had disappeared.¹² Sir Thomas Lewis clarified the problem in his 1925 book, where he noted "in cases where the heart is engorged and the veins

over-inflated, the first depression corresponding to the X' descent in normal curves becomes more or less filled and the jugular assumes a prominent plateau form."⁵ With high venous pressure, the X' disappears in the presence of atrial fibrillation. It is probable that Paul Wood was misled by seeing atrial fibrillation patients mostly when they were in severe heart failure.

TROUGH LABELING

The practice of placing the letters X and Y on the troughs began with Mackenzie and is often carried on in the present literature. This has resulted in some authors confusing the issue completely by actually defining the X and Y as representing only troughs rather than descents.^{6,7} Waves consist of rises and falls, so one must label them on their peaks; but descents are only downward movements, so they should have their labels on the slopes of the descents, and not at their nadirs or troughs.

CONTOUR RECOGNITION BY NECK INSPECTION

With nomenclature clarified, it is now easy to describe how to recognize jugular wave contours. Since the jugular X' descent is the largest, most rapid movement in the normal jugular, it is easier to time this descent than to look for waves. The X' descent in the normal jugular is obviously systolic, and a systolic event can be timed with either the radial pulse or heart sounds. The radial pulse is more synchronous with the X' descent than is the carotid, presumably because both have equal delays. On auscultation, the X' falls onto the S₂. In sinus rhythm, if the X' is dominant, you know that the A wave is dominant. Any descent that occurs after the radial pulse or after the S₂ is, of course, a Y descent, which is also a rapid movement. In sinus rhythm, the wave preceding the X' is the A wave, and that preceding the Y descent is the V wave.

DIFFERENTIATING A JUGULAR FROM A CAROTID PULSE

Unfortunately, the carotid pulsations in the neck can easily be confused with jugular pulsations. However, in sinus rhythm, the differentiation is easy because the X' descent ends at the S₂ and is simultaneous with the radial pulse, whereas the carotid descent begins with the S₂. If a patient is in atrial fibrillation and has no X' descent but only a dominant Y, then a summary of these differences can be of help:

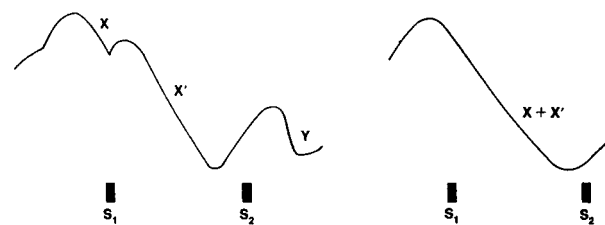


FIGURE 1. On the left is a normal jugular pulse tracing. On the right is the jugular pulse usually seen by the naked eye in the normal adult, *ie*, one descent, the X-plus-X' but mainly the X'.

1. The carotids are palpable with firm pressure. The normal jugular is rarely palpable with firm pressure.
2. The carotid descent is slow, whereas the jugular X' descent is rapid. If the fastest and greatest movement is a collapse or descent, it is a jugular pulse.
3. Firm pressure just above the clavicle obliterates all but the jugular pulsation with the highest pressure, but does not affect carotid pulsations.
4. Inspiration may exaggerate jugular pulsations, but if anything, diminishes carotid pulsations.
5. Sitting up makes the carotids appear higher in the neck, but the jugulars appear lower in the neck.
6. Sudden abdominal compression makes the jugular momentarily more visible but has no effect on the carotids.

There is a tendency to teach physicians to look in the neck for the waves recorded by a jugular pulse tracing. However, it is impossible to learn jugular recognition and diagnosis from pulse tracings because of two artifacts. First, the C wave can be grossly exaggerated on a pulse tracing that may not be able to eliminate a huge carotid artifact. The C wave is virtually invisible to the naked eye. Secondly, the V wave, which is too small to be seen in most adults, is also exaggerated by pulse transducers that are sensitive to change in pressure over time, *ie*, the faster the rate of rise of the V upstroke, the higher will the tracing climb on the recording (Fig 1).

In conclusion, in order to make clinical use of jugular waves, we must teach physicians to observe descents and not waves, and to avoid using X to mean two different phenomena, *ie*, reserve it only for the atrial relaxation descent, and to use X' for the venous collapse due to descent of the base.

When the descents are recognized and their waves are inferred from what came before the descents, the physician can learn how to recognize and diagnose jugular abnormalities by reading appropriate explanations.¹³

REFERENCES

- 1 Constant J. The X prime descent in jugular contour nomenclature and recognition. *Am Heart J* 1974; 88:372-379
- 2 Mackenzie J. The study of the pulse. New York, NY: Maxmillan, 1902; 22-23
- 3 Mackenzie J. The interpretation of the pulsations in the jugular veins. *Am J Med Sci* 1907; 134:12
- 4 Potain PCE. On the movement and sounds that take place in the jugular veins. In: Willius FA, Keys TE, eds. *Cardiac classics*. St. Louis, MO: CV Mosby, 1941; 5333
- 5 Lewis T. The mechanisms and graphic registration of the heart beat. 3rd ed. London, UK: Shaw, 1925
- 6 Braunwald E, ed. *Heart disease*. Philadelphia, PA: WB Saunders, 1980
- 7 Feest TG, Sutton CG, Gibson RV, et al. Signs of pericardial constriction in rupture of ventricular septum [abstract]. *Br Heart J* 1973; 34:1176
- 8 Sivaciyan V, Ranganathan N. Transcutaneous Doppler venous flow velocity recording. *Circulation* 1978; 57:930-935
- 9 Ranganathan N, Sivaciyan V. Abnormalities in jugular venous flow velocity in pulmonary hypertension. *Am J Cardiol* 1989; 63:719-724
- 10 Ranganathan N, Sivaciyan V, Prysak M, et al. Changes in jugular venous flow velocity after coronary bypass grafting. *Am J Cardiol* 1989; 63:725-729
- 11 Ranganathan N, Sivaciyan V. Jugular venous flow velocity pattern application to bedside recognition of jugular venous pulse contour and right heart hemodynamics. *Am J Noninvasive Cardiol* 1993; 7:75-88
- 12 Mackenzie J. *Diseases of the heart*. London, UK: Frowde, Hodder, Stoughton, 1913; 153
- 13 Constant J. *Bedside cardiology*. 5th ed. Philadelphia, PA: Lippincott, Williams & Wilkins, 1999



The Clinical World Congress on Diseases of the Chest

CHEST 2001, brought to you by the American College of Chest Physicians, is the only medical meeting focusing


on clinical chest and critical care medicine and cardiothoracic surgery. The educational programs are diverse in scope, topic, and delivery. Targeted sessions, designed for the clinician and the researcher, give you the unique opportunity to:

- *increase your medical knowledge*
- *maximize the care you provide your patients*
- *improve your practice management*
- *learn how research is making a difference in chest medicine*
- *network with other health professionals*

800-343-2227 • 847-498-1400

www.chestnet.org

*Philadelphia, PA
November 4-8*



Abstract Deadline May 4, 2001

Jugular Wave Recognition Breakthrough*

Jules Constant

Chest 2000;118; 1788-1791

DOI 10.1378/chest.118.6.1788

This information is current as of September 30, 2009

Updated Information & Services	Updated Information and services, including high-resolution figures, can be found at: http://www.chestjournal.org/content/118/6/1788.full.html
References	This article cites 7 articles, 2 of which can be accessed free at: http://www.chestjournal.org/content/118/6/1788.full.html#ref-list-1
Open Access	Freely available online through CHEST open access option
Permissions & Licensing	Information about reproducing this article in parts (figures, tables) or in its entirety can be found online at: http://www.chestjournal.org/site/misc/reprints.xhtml
Reprints	Information about ordering reprints can be found online: http://www.chestjournal.org/site/misc/reprints.xhtml
Email alerting service	Receive free email alerts when new articles cite this article. Sign up in the box at the top right corner of the online article.
Images in PowerPoint format	Figures that appear in CHEST articles can be downloaded for teaching purposes in PowerPoint slide format. See any online article figure for directions

A M E R I C A N C O L L E G E O F



C H E S T

P H Y S I C I A N S[®]