

Restoring the Right Ventricle



Anton Vonk Noordegraaf, MD, PhD

Harm Jan Bogaard, MD, PhD

Amsterdam, The Netherlands

In recent years, imaging the right ventricle in pulmonary arterial hypertension has taught us three important lessons.¹ First, the adaptation of the right ventricle to its load determines a patient's symptoms and prognosis. Second, right ventricular (RV) function in pulmonary arterial hypertension is best described by means of a volumetric assessment. Third, although small reductions in pulmonary vascular resistance (PVR) have unpredictable effects on RV volume and function, a normalization of PVR (such as achieved through lung transplantation) leads to reversal of RV reverse remodeling and full RV functional recovery. Together, these lessons suggest that restoration of RV function and volume should be considered as the ultimate treatment goal.

Monocentric MRI studies have clearly shown that the modest reductions in PVR achieved with monotherapy and dual combination therapy improve PVR to a certain extent, but they do not guarantee a restoration of RV function and volume.² An explanation for this observation is that a modest reduction of PVR (< 300 dynes) usually leads to improved cardiac output but may not necessarily result in a reduction in pulmonary artery pressure, which keeps the amount of work of the right ventricle unaltered. When the cardiac output goes up

FOR RELATED ARTICLE, SEE PAGE 376

AFFILIATIONS: From the Amsterdam UMC.

FINANCIAL/NONFINANCIAL DISCLOSURES: The authors have reported to *CHEST* the following: A. V. N. received speakers fees from Actelion, MSD, Pfizer, Bayer, and GlaxoSmithKline in the past 10 years; and he has served as a member of the scientific advisory board of Morphogen-XI. H. J. B. received speakers fees from Actelion, Pfizer, and GlaxoSmithKline in the past 10 years.

CORRESPONDENCE TO: Anton Vonk Noordegraaf, MD, PhD, Amsterdam UMC, Location Vumc, De Boelelaan 1117, 1081 HV Amsterdam, The Netherlands; e-mail: a.vonk@amsterdamumc.nl

Copyright © 2019 American College of Chest Physicians. Published by Elsevier Inc. All rights reserved.

DOI: <https://doi.org/10.1016/j.chest.2019.10.022>

but the RV afterload continues to be high, patients may benefit from an improved exercise capacity but continue to be at risk of further RV functional decline. When the right ventricle continues to follow its fatal path to failure, prognosis is unaltered. This paradox of apparent clinical improvement but unaltered prognosis has been described previously by Sniderman and Fitchett.³ In other words, it seems that when the PVR is lowered by a certain minimal amount, or when the PVR is reduced below a certain absolute threshold, not only will cardiac output be restored but pulmonary artery pressure will drop as well. Indeed, it was shown in the article by van de Veerdonk et al⁴ that most patients who had a significant drop in PVR had improved RV function and reduced RV volume.

With the development of > 10 effective PAH agents in recent years, the goal of sufficient PVR reduction and RV functional restoration seems within reach. However, this goal will be reached probably only when these medications are used in combination. The first piece of evidence that adding a second drug reduces RV volume in patients undergoing monotherapy was provided > 10 years ago, when van Wolferen et al⁵ showed that addition of sildenafil to bosentan improved RV function and reduced dilatation. More recently, upfront dual combination therapy was shown to be superior over monotherapy in preventing clinical worsening.⁶ The next step is upfront triple combination therapy including IV or subcutaneous prostacyclin analogues. Indeed, Sitbon et al⁷ showed that upfront triple combination therapy in selected patients resulted in dramatic hemodynamic and functional improvements. However, no data were available on how this strategy affects RV imaging.

In this issue of *CHEST*, the article by D'Alto et al⁸ shows, for the first time to our knowledge, in a multicenter approach, that reverse remodeling of the right ventricle can occur if patients are treated by using upfront combination treatment and that this can be visualized by means of echocardiography. Although the data are uncontrolled and the study may have been hampered to a certain degree by selection bias, the data encouragingly show that upfront triple combination therapy allows for restoration of RV structure and function in the majority of patients, despite their severely compromised

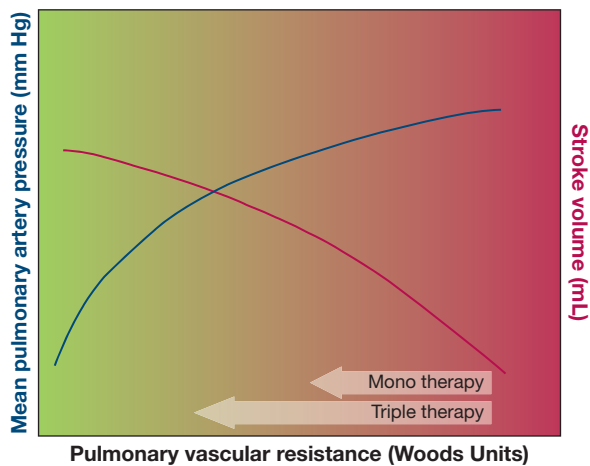


Figure 1 – A modest reduction in pulmonary vascular resistance will increase stroke volume but will only produce a small decrease in pulmonary artery pressure. As a consequence, the amount of work for the right ventricle (stroke volume \times mean pulmonary artery pressure) remains unaltered (red zone), leading to a clinical improvement but unaltered prognosis. In the case of a significant drop in pulmonary vascular resistance ($> 40\%$), pulmonary artery pressure will drop, resulting in a reduction in right ventricular work (green zone) and load, leading to reverse remodeling of the right ventricle.

hemodynamic profile at baseline. Importantly, the data suggest that restoration of RV function requires a minimal reduction in PVR of $> 40\%$ of the baseline value. Although prognostic data are lacking in this article, it has been clearly established that patients with stabilized or reduced RV volumes have an excellent prognosis.⁹

To summarize, it suffices to paraphrase the words of Sniderman and Fitchett³: a modest reduction in PVR

will improve walking distance, a significant reduction in PVR will restore RV function (Fig 1). In future years, we need to determine the threshold reduction in PVR (either absolute or relative) that results in clinically relevant improvements in outcome. With that information, we can further optimize our upfront treatment strategies to restore RV function.

References

1. Vonk Noordegraaf A, Chin KM, Haddad F, et al. Pathophysiology of the right ventricle and of the pulmonary circulation in pulmonary hypertension: an update. *Eur Respir J*. 2019;53(1). pii: 1801900.
2. van de Veerdonk MC, Kind T, Marcus JT, et al. Progressive right ventricular dysfunction in patients with pulmonary arterial hypertension responding to therapy. *J Am Coll Cardiol*. 2011;58(24): 2511-2519.
3. Sniderman AD, Fitchett DH. Vasodilators and pulmonary arterial hypertension: the paradox of therapeutic success and clinical failure. *Int J Cardiol*. 1988;20(2):173-181.
4. van de Veerdonk MC, Huis In T Veld AE, Marcus JT, et al. Upfront combination therapy reduces right ventricular volumes in pulmonary arterial hypertension. *Eur Respir J*. 2017;49(6).
5. van Wolferen SA, Boonstra A, Marcus JT, et al. Right ventricular reverse remodelling after sildenafil in pulmonary arterial hypertension. *Heart*. 2006;92(12):1860-1861.
6. Galiè N, Barberà JA, Frost AE, et al. AMBITION Investigators. Initial use of ambrisentan plus tadalafil in pulmonary arterial hypertension. *N Engl J Med*. 2015;373(9):834-844.
7. Sitbon O, Jaïs X, Savale L, et al. Upfront triple combination therapy in pulmonary arterial hypertension: a pilot study. *Eur Respir J*. 2014;43(6):1691-1697.
8. D'Alto M, Badagliacca R, Argiento P, et al. Risk reduction and right heart reverse remodeling by upfront triple combination therapy in pulmonary arterial hypertension. *Chest*. 2020;157(2):376-383.
9. van de Veerdonk MC, Marcus JT, Westerhof N, et al. Signs of right ventricular deterioration in clinically stable patients with pulmonary arterial hypertension. *Chest*. 2015;147(4):1063-1071.