

## Organising pneumonia

Jean-François Cordier

Organising pneumonia is a characteristic pathological entity defined by the presence in the interstitium of the lung of dense, eosinophilic, fibrocellular plugs (fig 1).<sup>1,2</sup> The lesions occur predominantly within the alveolar septa but are often associated with buds of granulation tissue occupying the terminal airway lumen (fig 1). This pathological pattern is characteristic for any disorder or cause, but reflects the underlying process resulting in the disease. It may also be a feature of the

lesion and may be an accessory finding in other inflammatory disorders such as chronic bronchitis. However, organising pneumonia is the particular pathological hallmark of a characteristic clinicoradiological entity called cryptogenic organising pneumonia. This terminology is preferred to the other name used for this condition—namely, idiopathic bronchiolitis obliterans with organising pneumonia (BOOP)—which may be confused with other types of bronchiolar disorders, particularly constrictive bronchiolitis obliterans which is mainly characterised by airflow obstruction.

The term organising pneumonia is preferred to the other name used for this condition—namely, idiopathic bronchiolitis obliterans with organising pneumonia (BOOP)—which may be confused with other types of bronchiolar disorders, particularly constrictive bronchiolitis obliterans which is mainly characterised by airflow obstruction.

This terminology is preferred to the other name used for this condition—namely, idiopathic bronchiolitis obliterans with organising pneumonia (BOOP)—which may be confused with other types of bronchiolar disorders, particularly constrictive bronchiolitis obliterans which is mainly characterised by airflow obstruction.

### Definition of organising pneumonia

Because organising pneumonia is a characteristic pathological entity, it may result from a variety of causes. Pathologists may report features of organising pneumonia in association with conditions such as

infectious pneumonia, lung abscess, empyema, lung cancer, bronchiectasis, broncholithiasis, chronic pulmonary fibrosis, aspiration pneumonia (giant cells and foreign bodies usually present), adult respiratory distress syndrome, pulmonary infarction, and middle lobe syndrome.<sup>3,4</sup>

Organising pneumonia may be classified into three types according to its cause: organising pneumonia of infectious cause; organising pneumonia of non-infectious cause but occurring in a specific and relevant context; and idiopathic organising pneumonia. Several possible causes and/or associated disorders may coexist in the same patient. There are no clear distinguishing clinical and radiological features between cryptogenic and secondary organising pneumonia.<sup>5</sup>

ORGANISING PNEUMONIA OF INFECTION CAUSE is a distinct entity of organising pneumonia. Indeed, the concept of organising pneumonia as a distinct pathological entity emerged at the beginning of the 20th century with its recognition at the time in patients dying from bacterial pneumonia.<sup>5–10</sup> It was interpreted as the

entity. Organising pneumonia has since been found in association with many other infections, mainly bacterial, but also in association with viral and fungal infections (table 1). In bacterial infections organising pneumonia oc-

Table 1 Causes of organising pneumonia

	Reference
<i>Chlamydia pneumoniae</i>	169, 170
<i>Coxiella burnetii</i>	171
<i>Legionella pneumophila</i>	86, 125, 172–176
<i>Mycoplasma pneumoniae</i>	86, 125, 177
<i>Nocardia asteroides</i>	178, 179
<i>Pseudomonas aeruginosa</i>	62
<i>Serratia marcescens</i>	62, 180
<i>Staphylococcus aureus</i>	62
Streptococcus group B (newborn treated by extracorporeal oxygenation)	181
<i>Streptococcus pneumoniae</i>	6, 7, 182
Herpes virus	62
Human immunodeficiency virus	183–185
Influenza virus	125, 186
Parainfluenza virus	187
<i>Plasmodium vivax</i>	188
<i>Cryptococcus neoformans</i>	189
<i>Penicillium janthinellum</i>	190
<i>Pneumocystis carinii</i> (in AIDS)	62, 191, 192

Service de  
Pneumologie, Hôpital  
Louis Pradel,  
Université Claude  
Bernard, 69394 Lyon  
Cedex, France  
J-F Cordier

Correspondence to:  
Professor J-F Cordier

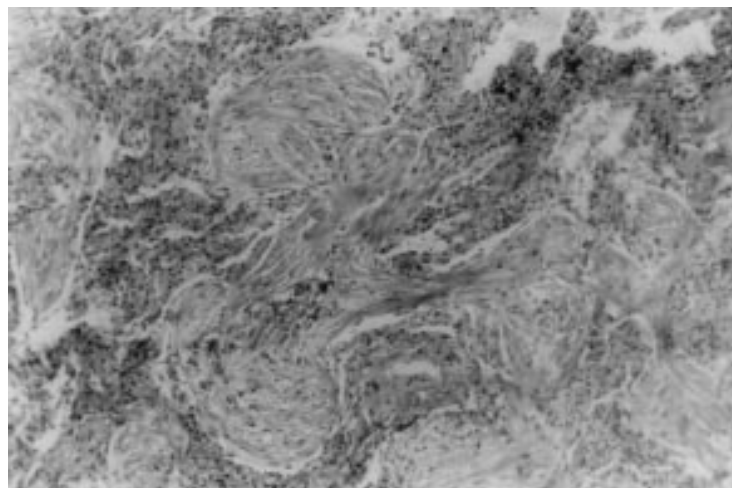


Figure 1 Buds of granulation tissue in the terminal airway lumen defining organising pneumonia.

Table 2 Drugs identified as causing organising pneumonia

	Reference
5-aminosalicylic acid*	69, 70
Acebutolol	193
Acramin FWN	194–196
Amiodarone	5, 193, 197–202
Amphotericin	203
Bleomycin	83, 137, 204–212
Busulphan	213, 214
Carbamazepine†	215
Cephalosporin (cefradin)	216
Cocaine	217
Gold salts‡	218, 219
Hexamethonium	220
Interferon alpha	220
L-tryptophan	221
Mesalazine	222
Minocycline	223
Nilutamide	224
Paraquat	225
Phenytoin	226
Sotalol	227
Sulfasalazine*	69, 228–230
Tacrolimus	231
Ticlopidine**	232
Vinabarbital-aprobarbital	233

\*In patients treated with this drug for ulcerative colitis or Crohn's disease which may themselves be associated with organising pneumonia. †In the course of lupus syndrome induced by the drug. ‡In patients with rheumatoid arthritis which may itself be associated with organising pneumonia. \*\*In a patient with temporal arteritis.

curs mostly in non-resolving pneumonia where, despite control of the infectious organism by antibiotics, the inflammatory reaction remains active with further organisation of the intra-alveolar fibrinous exudate. Rheumatic pneumonia occurring during the course of rheumatic fever was recognised as a typical organising pneumonia with intra-alveolar buds described as “bourgeons conjonctifs” or Masson's bodies.<sup>11 12</sup>

With drug induced organising pneumonia it is sometimes difficult to determine causality since organising pneumonia may also be associated with the underlying disease (a connective tissue disease, for example). Resolution of organising pneumonia after stopping the drug is obviously the best clue to establish causality. In many cases, however, it is not possible to determine whether the drug is responsible or not—for example, in patients with cancer or haematological malignancies who may be treated with several drugs that are able to induce organising pneumonia.<sup>5</sup> Serious diagnostic pitfalls may occur with drug induced organising pneumonia—for example, bleomycin induced organising pneumonia which may present as pulmonary nodules resembling metastases in patients treated for aggressive and potentially metastatic cancers (table 2).

It has long been known that radiation therapy to the chest may induce radiation pneumonitis, an inflammatory reaction within the radiation field with some pathological features of organising pneumonia.<sup>13 14</sup> However, a syndrome similar to cryptogenic organising pneumonia has been identified recently in women receiving radiation therapy to the breast after removal of a malignant tumour.<sup>15–22</sup> It differs strikingly from usual radiation pneumonitis in that the pulmonary infiltrates occur or migrate outside the radiation fields and in the good response to corticosteroid

treatment. The pathological findings are typical of organising pneumonia. Bronchoalveolar lavage (BAL) fluid differential cell counts show an increase in lymphocytes in particular, but also in neutrophils, eosinophils, and mast cells. Although corticosteroid treatment is usually necessary, spontaneous improvement may occur.<sup>20</sup> Interestingly, unilateral breast irradiation, whether or not it results in pneumonitis, has been shown to induce bilateral lymphocytic alveolitis with activated CD4+ T cells<sup>23 24</sup>; however, this does not result in organising pneumonia in the majority of patients. An additional genetically determined host factor and/or trigger acting on radiation “primed” lymphocytes may be necessary to induce the organising pneumonia syndrome.<sup>15 19</sup>

#### ORGANISING PNEUMONIA OF UNKNOWN CAUSE OCCURRING IN A SPECIFIC CONTEXT

The connective tissue disorders often involve the pulmonary parenchyma. Infiltrative lung disease in this context varies and may include usual interstitial pneumonia, non-specific interstitial pneumonia, or organising pneumonia. The idiopathic inflammatory myopathies may cause a characteristic organising pneumonia syndrome.<sup>25–36</sup> Organising pneumonia also occurs in rheumatoid arthritis<sup>5 22 37–43</sup> and Sjögren's syndrome<sup>44 45</sup> but, in contrast, is uncommon in systemic lupus erythematosus<sup>40 46–49</sup> and systemic sclerosis.<sup>5 50 51</sup> In addition to organising pneumonia, bronchiolitis obliterans may occur in connective tissue disorders (particularly in rheumatoid arthritis).<sup>52</sup>

Pathological features of organising pneumonia may occur with Wegener's granulomatosis. These usually consist of small foci of organising pneumonia at the periphery of otherwise typical granulomatous lesions, but in some cases they are the major histological finding although the patients do not differ clinically or radiologically from those with classical Wegener's granulomatosis.<sup>53</sup> Organising pneumonia has been reported occasionally in polyarteritis nodosa.<sup>54</sup>

It is well established that both lung transplantation and bone marrow grafting may be complicated by constrictive mural bronchiolitis with airflow obstruction. This is generally interpreted as a manifestation of chronic rejection and graft versus host disease, respectively, and it often results in severe chronic obstructive respiratory failure. Less commonly, organising pneumonia occurs in transplanted lungs.<sup>55–61</sup> Organising pneumonia in this setting may result from preservation injury, infection or aspiration, or it may be a manifestation of lung rejection<sup>57 61 62</sup> and it may be associated with chronic rejection associated bronchiolitis obliterans.<sup>57</sup> In lung transplant patients the combination of constrictive obliterative bronchiolitis and organising pneumonia appears to be associated with a poorer prognosis than constrictive obliterative bronchiolitis alone.<sup>59</sup> Organising pneumonia also occurs after allogeneic bone marrow grafts<sup>63–66</sup> where it is considered to be a manifestation of graft versus host disease.<sup>63</sup>

Other disorders that have been reported to be associated with organising pneumonia include Sweet's syndrome,<sup>67, 68</sup> ulcerative colitis,<sup>69, 70</sup> Crohn's disease,<sup>69</sup> polymyalgia rheumatica,<sup>71, 72</sup> thyroiditis,<sup>43</sup> Behçet's disease,<sup>6</sup> mesangiocapillary glomerulonephritis,<sup>73</sup> myelodysplasia,<sup>74</sup> leukaemia, myeloproliferative disorders, cancer,<sup>63, 75-77</sup> common variable immunodeficiency,<sup>78</sup> and hepatitis C.<sup>79</sup> Since only single or small numbers of cases have been reported, it is unclear whether these represent a true association or whether the organising pneumonia results from other causes such as undiagnosed infection or drug induced reaction.

#### CRYPTOGENIC ORGANISING PNEUMONIA

Although organising pneumonia may result from numerous causes or occur in the context of systemic disorders, it remains cryptogenic

and solitary in many cases. The recognition of cryptogenic organising pneumonia (COP) as a clinicopathological entity was long delayed for several reasons: Pathologists used to consider organising pneumonia as a non-specific finding of little, if any, interest, and merely a consequence of previous unrecognised infection. When mentioned in pathological reports it was not accorded attention by clinicians. With the increased use of lung biopsies, organising pneumonia was identified more often but included in the vast group of interstitial lung disorders. COP was therefore only recognised as a distinct disorder in the early 1980s after the reports of Davison et al<sup>81</sup> and Epler et al.<sup>82</sup> Further studies in the 1980s<sup>83, 84</sup> described its characteristic features, and COP is now accepted as a rare but very characteristic clinicopathological entity in pulmonary medicine.

#### Clinical characteristics<sup>5, 40, 43, 63, 81-90</sup>

Men and women are affected equally in most series and are usually aged between 50 and 60 years (with a range from about 20 to 80). Occasional cases in adolescents have been reported.<sup>91</sup> No predisposing factors have been identified and, in particular, organising pneumonia is not related to smoking (most patients are non-smokers or ex-smokers). Seasonal cases (late February to early May) with biochemical cholestasis were found in one study,<sup>92</sup> but this has not been further reported.

The onset of symptoms is usually subacute with fever, non-productive cough, malaise, anorexia, and weight loss. Haemoptysis, bronchorrhoea, chest pain, arthralgia, and night sweats are uncommon. Severe haemoptysis is exceedingly rare.<sup>93</sup> Dyspnoea is usually mild and only on exertion but it is occasionally severe in some acute and life threatening cases. In most cases symptoms develop over a few weeks after a viral like illness and diagnosis of COP is usually made after 6±10 weeks. Physical examination may be normal, but sparse crackles are commonly found over affected areas.

#### Imaging<sup>5, 22, 81-83, 86, 87, 89, 92, 94-117</sup>

Although the imaging pattern of COP is heterogeneous, the radiographic and computed tomographic (CT) findings are often so characteristic that they suggest the diagnosis. Three main imaging patterns may be distinguished.

The most frequent and typical imaging profile of COP is of multiple patchy alveolar opacities with a peripheral and bilateral distribution (Fig 2). These opacities often migrate spontaneously. Their size is variable, ranging from a few centimetres to a whole lobe. On the CT scan the density of the opacities varies from ground glass to consolidation; an air bronchogram may be present in consolidated areas (Fig 3). This imaging pattern, although highly suggestive of COP, is not specific and the differential imaging diagnosis comprises conditions such as the chronic eosinophilic pneumonias (which can occur with COP), primary low

Figure 2 Typical imaging pattern of organising pneumonia with patchy alveolar opacities on chest radiograph.

Figure 3 Typical imaging pattern of organising pneumonia with patchy consolidation in the lower lobes containing air bronchograms on computed tomographic scan.

grade pulmonary lymphomas, and bronchiolo-alveolar carcinoma.

The two other common imaging patterns of COP are less characteristic. Some patients present with a diffuse bilateral interstitial pattern (Fig 4) usually associated with interstitial opacities and small superimposed alveolar opacities. These patients show a greater degree of interstitial inflammation in addition to intra-alveolar organisation on pathological examination. Since intra-alveolar organisation is a non-specific feature that may be found in a variety of interstitial disorders, some cases may overlap with the organising stage of diffuse alveolar damage, non-specific interstitial pneumonia, or cryptogenic organising alveolitis.

COP may also present on imaging as a solitary focal lesion associated usually with subacute or chronic inflammatory illness. This is often a pathological diagnosis after surgical

excision of a lesion suspected to be a lung cancer on a routine chest radiograph; it usually occurs in the upper lobes (Fig 5) and may cavitate. Some cases probably correspond to unresolved pneumonia.

Less common radiological findings in patients with COP include crescentic opacities surrounding areas of ground glass attenuation, multiple or cavitary nodules or masses, pneumatocele, peripheral irregular subpleural bands in parallel with the pleural surface, and bronchial dilatation (in association with opacities). Large nodules may have irregular or spiculated margins and a relatively broad pleural tag.<sup>118</sup> Pleural effusion is generally uncommon although it was present in 22% of patients in one series.<sup>2</sup>

#### Lung function tests

The most common finding on lung function testing in patients with COP is a mild or moderate restrictive ventilatory defect. Airflow obstruction may be present in smokers but is not a characteristic of COP (in contrast with the often severe airflow obstruction found in constrictive bronchiolitis obliterans). The transfer factor for carbon monoxide is reduced, but the transfer coefficient may be normal. Mild hypoxaemia at rest and/or on exercise is common. Hypoxaemia is occasionally severe and correlates with right to left shunting as shown by increased alveolar-arterial oxygen difference while breathing 100% oxygen (unpublished personal data). Severe hypoxaemia in COP may reflect widespread and severe pulmonary disease or shunting in more limited lesions, or both.

**Bronchoalveolar lavage and laboratory findings**  
Bronchoalveolar lavage may be used to exclude other disorders or causes of COP, particularly infections. The differential white cell count may show a characteristic mixed pattern with increased lymphocytes (20±40%), neutrophils (about 10%), and eosinophils (about 5%), sometimes with some plasma cells or mast cells.<sup>5 84 89 120±122</sup> The lymphocyte CD4/CD8 ratio is decreased.<sup>80 120 123 124</sup>

There are no specific laboratory findings in COP. The erythrocyte sedimentation rate and C reactive protein levels are increased, with the erythrocyte sedimentation rate being >60 mm in about 30% of patients.<sup>5 81 84 89 124</sup> There is a moderate leucocytosis, with an increased proportion of neutrophils.

#### Diagnosis of cryptogenic organising pneumonia

The diagnosis of COP relies on finding typical pathological and clinicoradiological features and the exclusion of any recognised cause or associated disorder. Pathological examination of lung specimens shows intra-alveolar buds of granulation tissue associated with fibroblasts, myofibroblasts, and loose connective tissue. Inflammatory cells may be present in the granulation tissue, especially during the early stages of the process (see below). The buds may extend from one alveolus to the next through the pores of Kohn (which were initially

Figure 4 Diffuse interstitial pattern of organising pneumonia with interstitial and small alveolar opacities on computed tomographic scan.

Figure 5 Solitary focal mass in the right upper lobe. This pattern may be diagnosed as lung cancer.



described in this condition), giving a rather characteristic "butterfly" pattern. Foamy macrophages are conspicuous in empty alveoli. The lung structure is not disorganised. Bronchiolar lesions consist of similar plugs of granulation tissue inside the airway lumen in continuity with lesions in the alveoli and with only limited inflammation in the bronchiolar wall. The plugs of granulation tissue in organising pneumonia occupy the more distal air spaces.<sup>40 125 126</sup> This distribution is strikingly distinct from another type of bronchiolocentric lesion consisting of bronchiolitis obliterans with organising pneumonia limited to the alveoli adjacent to the involved bronchioles, thus giving a miliary pattern on the chest radiograph (Cordier and Loire, unpublished data).

For COP to be diagnosed the organising pneumonia should be the main pathological feature and not merely an accessory to other well defined lesions such as vasculitis, eosinophilic pneumonia, hypersensitivity pneumonitis, or non-specific interstitial pneumonia.<sup>1 127</sup> Furthermore, a careful search for a possible cause of organising pneumonia is necessary, including special stains to detect infectious agents.

Because the pulmonary lesions are often migratory and may resolve spontaneously, a chest radiograph just before the biopsy is necessary.

Video-assisted thoracoscopic lung biopsy is the currently preferred technique for diagnosing organising pneumonia since it provides quite large lung specimens which allow the diagnosis to be made with confidence and makes it easy to search for other pathological features. Transbronchial lung biopsy specimens may show organising pneumonia in many cases<sup>128-130</sup> but they do not adequately allow the exclusion of associated lesions or disclose clues to a cause for the process. We consider therefore that the diagnosis of organising pneumonia by transbronchial biopsy may be accepted only in typical cases and requires careful patient follow up to prompt a surgical biopsy if the initial diagnosis has to be reconsidered because the evolution of the illness is unusual. Most cases require a surgical lung biopsy specimen to be taken before starting treatment.

The diagnosis of COP without a biopsy is seldom justified. It may be considered in patients who are critically ill (particularly older patients) or if the clinical diagnosis is considered as highly probable by an experienced physician. Particularly careful follow up would be necessary in such patients and lack of improvement with corticosteroids or relapses despite relatively high doses of corticosteroids (over 25 mg per day) should lead the clinician to suspect other diagnoses, particularly lymphomas.<sup>131</sup>

#### Treatment and prognosis of organising pneumonia

Spontaneous improvement occurs occasionally in organising pneumonia<sup>91 97 118</sup> and slow improvement has been reported in some patients

after prolonged treatment with erythromycin.<sup>132</sup> However, corticosteroids are the current standard treatment, although the ideal dose and duration necessary for complete healing are less certain.<sup>97 90 133</sup> The response to corticosteroids is impressive, although much less dramatic than in idiopathic chronic eosinophilic pneumonia. Clinical manifestations improve within 48 hours but complete resolution of radiographic pulmonary infiltrates usually takes several weeks (usually without significant sequelae). Most patients show a marked improvement after one week of treatment.

Although some authors recommend starting treatment with doses of prednisone of  $1 \pm 1.5$  mg/kg/day for  $1 \pm 3$  months,<sup>133 134</sup> in patients with typical COP we start with a lower dose of 0.75 mg/kg/day. Relapses involving the initial sites or different locations occur frequently as the dose of corticosteroid is reduced.<sup>5 79 81 82 84 89 92 109 135</sup> The final outcome is not significantly affected by the occurrence of relapses.<sup>135</sup> The severity of hypoxaemia at first presentation has been reported to be a determinant of subsequent relapses<sup>99</sup> but we could not confirm this finding.<sup>135</sup> The duration of treatment required varies considerably but is usually between six and 12 months. Some patients experience several relapses and require treatment for much longer. Because of the adverse effects of prolonged and high doses of corticosteroids, we try to withdraw them after a few months and only prolong treatment in patients with relapsing disease.

The prognosis in typical COP with patchy alveolar opacities is usually excellent following treatment with corticosteroids.<sup>82 84 88 89 98 136</sup> The prognosis of organising pneumonia secondary to a determined cause or associated with a specific condition such as a connective tissue disease is more difficult to determine because of the heterogeneity of reported cases. The prognosis in COP is usually better than that seen in secondary organising pneumonia, probably due to the nature of the underlying disorders.

There are reports of patients with severe and rapidly progressive COP<sup>37 138</sup> but interpretation of such reports is unclear. Of 10 patients with rapidly progressive organising pneumonia characterised by severe respiratory failure and organising pneumonia on the initial pulmonary biopsy, subsequent pathological examination of the lung at autopsy in six showed a brotic honeycomb pattern.<sup>137</sup> In another series of patients with acute and life threatening organising pneumonia, organising adult respiratory distress syndrome (ARDS) was considered likely.<sup>138</sup> Some cases with a poor outcome may represent an uncommon evolution of otherwise typical organising pneumonia, but most are likely to be either acute interstitial pneumonia or organising ARDS, widespread organising pneumonia resulting in respiratory failure, organising pneumonia associated with other chronic disease or lung injury either aggravated by lung biopsy or associated with delayed treatment.<sup>5 63 137-140</sup> Some patients with severe disease requiring assisted ventilation may

improve completely with corticosteroids.<sup>140</sup> Factors that appear to be associated with a poor outcome in COP include a predominantly interstitial pattern on imaging, lack of a lymphocytosis on the BAL fluid differential cell count, associated disorders,<sup>36</sup> and a finding on histological examination of scarring and remodelling of the lung parenchyma in addition to organising pneumonia.<sup>141</sup>

Cytotoxic drugs, especially cyclophosphamide and azathioprine, are occasionally used to treat COP,<sup>90 134 137 139 142</sup> but they have not been evaluated. The cytotoxic drugs are usually given in addition to corticosteroids so whether the observed improvement is due to the prolonged course of corticosteroids or to the cytotoxic drug is not known. Cyclophosphamide may be considered in severely ill patients who show no improvement with corticosteroid treatment within a few days and in patients who fail to improve despite a prolonged course of corticosteroids. In such acute and severe cases our usual practice is to give one to three intravenous boluses of cyclophosphamide, as in the initial treatment of Wegener's granulomatosis.<sup>43</sup>

#### Pathogenesis of organising pneumonia

Organising pneumonia is the pathological hallmark of a distinct type of lung injury and repair rather than a disease with one defined aetiology. The histopathophysiology underlying organising pneumonia can be seen as a blueprint of a pulmonary type of wound healing<sup>9</sup> that results in a serious lung disorder.<sup>144 145</sup>

Organising pneumonia was described initially as a failure of resolution of acute pneumonia. Laennec<sup>146</sup> defined the usual pathological course of acute lobar pneumonia, later identified as pneumococcal pneumonia, as a sequence of congestion, hepatisation (when the appearance of the lung resembled the liver), followed by resolution without sequelae. The corresponding histological sequence comprised oedema rich in pneumococci and inflammatory cells, fibrin deposition within alveoli and, finally, liquefaction of fibrin by neutrophils and macrophages. Resolution of pneumonia did not occur in all cases, however, particularly before the era of antibiotics. Organisation of the inflammatory fibrinous exudates in the alveoli was described precisely in such cases, with the identification of the fibroblast as the main cell type involved in the process of organisation.<sup>6 7 9 147</sup> Apart from a direct infectious cause, organising pneumonia has also been found in rheumatic pneumonia<sup>11 12 148 149</sup> as a result of pulmonary inflammation comparable to the inflammatory process of carditis. Massonet al<sup>1</sup> described the intra-alveolar bourgeois conjunctiva, also called Masson bodies, in rheumatic pneumonia. It was clearly shown that these were not specific to rheumatic pneumonia but were present in a number of inflammatory disorders.<sup>12</sup>

The process of intra-alveolar organisation has been studied mainly in experimental animal models and in human ARDS. It results from a sequence of alveolar injury, intra-alveolar clotting with deposition of fibrin, and subsequent colonisation by fibroblasts to pro-

duce a connective matrix.<sup>144 150</sup> The injury to both capillary endothelial cells and alveolar epithelial cells results in the leakage of plasma proteins, especially coagulation factors, into the alveolar lumen. Activation of the extrinsic pathway of the coagulation cascade is triggered by tissue factor and results in fibrin deposition. The metabolism of fibrin in the alveolar lumen and on alveolar surfaces results from the complex balance between the local procoagulant activity and the fibrinolytic processes. Increased procoagulant activity and decreased fibrinolytic activity result in the intra-alveolar coagulation of the exuded coagulation proteins, fibrin deposition, and alveolar damage. The migration and invasion of fibroblasts involves the cell surface matrix receptor CD44<sup>151</sup> and is blocked by anti-CD44 antibodies. In addition to building a provisional matrix for the continuation of the organisation process, the coagulation proteins and their degradation products exert a number of biological activities (especially chemotactic, activating, and proliferation promoting activities<sup>152a,154</sup>) on fibroblasts, smooth muscle cells, and inflammatory cells.

The histopathophysiology of COP is a model of a lung inflammatory process.<sup>144</sup> The first step consists of acute alveolar epithelial injury with cell necrosis and denudation of the basal laminae.<sup>155a,157</sup> Organisation begins with the formation of intra-alveolar fibrinoid inflammatory cell clusters rich in coagulation factors and further intra-alveolar migration of interstitial fibroblasts through gaps in the injured basal laminae. The proliferating fibroblasts colonise the fibrin strands. They undergo phenotypic modulation into myofibroblasts and organise into inflammatory buds with deposition of a loose connective matrix in which fibronectin and collagen III are abundant. The buds become progressively more fibrotic with concentric layers of myofibroblasts and connective tissue, thus giving the typical appearance of intra-alveolar buds.<sup>155 157a,159</sup> The alveolar architecture is remarkably preserved, with the intraluminal buds extending into some alveolar ducts and bronchioles. Alveolar collapse and mural incorporation of the buds may be present in some areas, depending on the degree of initial alveolar damage.

An experimental model of BOOP has been developed recently in CBA/J mice infected with reovirus 1/L.<sup>160</sup> Respiratory infection by reovirus 1/L does not give rise to BOOP in CD-1 and BALB/c mice, suggesting that genetic host factors are important determinants of the development of the fibrotic response of the BOOP type. In this model increased numbers of macrophages are observed in the lungs of the mice within the first week after inoculation with the virus, and these express reovirus proteins. Increased numbers of macrophages persist during the three week course of the pulmonary disease, but whether they continue to express reovirus proteins after infectious virions can no longer be detected is not known.

Tissue factor antigen is expressed in COP, mainly in hyperplastic type II pneumocytes.<sup>161</sup> Anti-adhesive glycoproteins have been studied

in organising pneumonia. Tenascin is present throughout the extracellular matrix of the intra-alveolar buds whereas SPARC is only observed intracellularly in @broblasts, and thrombospondin 1 forms a ring at the periphery of the buds, just beneath the epithelium from which it is probably produced. However, the role of these anti-adhesive proteins is still unclear.<sup>162</sup> Increased expression of interleukin-8 and @bronectin genes by alveolar macrophages have been reported in COP, suggesting that the inflammatory pulmonary process may be initiated and/or perpetuated by inflammatory cytokines produced in situ by alveolar macrophages.<sup>163</sup> Increased platelet-derived growth factor (PDGF) positive cells have been demonstrated by immunohistochemistry in organising pneumonia lesions and attributed to the local recruitment of monocytes into the foci of connective tissue proliferation.<sup>164</sup>

How corticosteroids induce the disappearance of the well organised @brotic intra-alveolar buds remains a mystery. Degradation of the connective matrix requires specific enzymes such as matrix metalloproteinases (MMP), gelatinases, and stromelysins. These enzymes may be produced by leucocytes and the @broblasts themselves. Cytokines may modulate the production of MMP-1 (collagenase) by @broblasts,<sup>165</sup> and the composition of the matrix itself may modulate the production of proteases by @broblasts.<sup>167</sup> Relaxin, a cytokine/growth factor, stimulates the expression of MMP-1 in a biphasic, dose dependent manner.<sup>168</sup> Thus, @broblasts may play a role in the degradation of the matrix they themselves previously built.

Taken together, the clinical, pathological, and biopathological data suggest that COP reflects the response to an initial injury of unknown cause(s) which causes pulmonary inflammation, which is further self-perpetuated in some patients to produce the characteristic buds of intra-alveolar granulation tissue associating (myo)@broblasts and connective matrix. The most intriguing feature of COP is its rapid resolution following treatment with corticosteroids, the mechanism of which is currently unknown.

#### Conclusion and research perspectives

Although rare, COP is now a well characterised entity with characteristic clinical and radiological features and pathological diagnostic criteria. Although treatment with corticosteroids is very effective, we are unable to predict which patients will relapse after reducing or stopping treatment, nor do we know the most appropriate dose with which to start treatment and how long patients should be treated. Some patients are probably overtreated whereas others would benefit from longer treatment. There may not be a single cause of COP but biopathological studies are needed to identify the mechanisms whereby a limited wound healing reaction switches to an idiopathic persistent inflammatory process which is nevertheless very responsive to corticosteroids.

The author thanks T Greenland for linguistic revision of the paper.

- Colby TV. Pathologic aspects of bronchiolitis obliterans organizing pneumonia. *Chest* 1992;102:38S-43S.
- Sulavik SB. The concept of "organizing pneumonia". *Chest* 1989;96:967-9.
- Bulmer SR, Lamb D, McCormack RJ, et al. Aetiology of unresolved pneumonia. *Thorax* 1978;33:307-14.
- Kwon KY, Myers JL, Swensen SJ, et al. Middle lobe syndrome: a clinicopathological study of 21 patients. *Hum Pathol* 1995;26:302-7.
- Lohr RH, Boland BJ, Douglas WW, et al. Organizing pneumonia. Features and prognosis of cryptogenic, secondary, and focal variants. *Arch Intern Med* 1997;157:1323-9.
- Floyd R. Organization of pneumonitic exudates. *Am J Med Sci* 1922;163:527-48.
- Milne LS. Chronic pneumonia (including a discussion of two cases of syphilis of the lung). *Am J Med Sci* 1911;142:408-38.
- Kidd P. Some moot points in the pathology and clinical history of pneumonia. *Lancet* 1912;i:1665-70.
- Menetrier P, Pascano A. Transformation @breuse de l'hpatisation pneumonique ou @brome vxgxtant intra-alvolaire post-pneumonique. *Bull Mem Soc Med Hop Paris* 1915;39:510-24.
- Symmers D, HoVman AM. The increased incidence of organizing pneumonia. *JAMA* 1923;81:297-8.
- Masson P, Riopelle JL, Martin P. Poumon rhumatismal. *Arch Anat Pathol* 1937;14:359-82.
- Herbut PA, Manges WE. The "Masson body" in rheumatic pneumonia. *Am J Pathol* 1944;21:741-51.
- Davis SD, Yankelevitz DF, Henschke CI. Radiation effects on the lung: clinical features, pathology, and imaging @ndings. *AJR* 1992;159:1157-64.
- Kaufman J, Komorowski R. Bronchiolitis obliterans. A new clinical-pathologic complication of irradiation pneumonitis. *Chest* 1990;97:1243-4.
- Bayle JY, Nesme P, Bxjui-Thivolet F, et al. Migratory organizing pneumonitis "primed" by radiation therapy. *Eur Respir J* 1995;8:322-6.
- Crestani B, Kambouchner M, Soler P, et al. Migratory bronchiolitis obliterans organizing pneumonia after unilateral radiation therapy for breast carcinoma. *Eur Respir J* 1995;8:318-21.
- Nirenberg A, Meikle GR, Goldstein D, et al. Metastatic carcinoma in@lstrating lung mimicking BOOP. *Australas Radiol* 1995;39:405-7.
- Van Laar JM, Holscher HC, Van Krieken JHJM, et al. Bronchiolitis obliterans organizing pneumonia after adjuvant radiotherapy for breast carcinoma. *Respir Med* 1997;91:241-4.
- Crestani B, Valeyre D, Roden S, et al, and the Groupe d'Etudes et de Recherche sur les Maladies Orphelines Pulmonaires (GERM@OP). Bronchiolitis obliterans organizing pneumonia syndrome primed by radiation therapy to the breast. *Am J Respir Crit Care Med* 1998;158:1929-35.
- Arbeter KR, Prakash UBS, Tazelaar HD, et al. Radiation-induced pneumonitis in the "nonirradiated" lung. *Mayo Clin Proc* 1999;74:27-36.
- Van Haecke P, Vansteenkiste J, Paridaens P, et al. Chronic lymphocytic alveolitis with migrating pulmonary in@lstrates after localized chest wall irradiation. *Acta Clin Belg* 1998;53:39-43.
- Flowers JR, Clunie G, Burke M, et al. Bronchiolitis obliterans organizing pneumonia: the clinical and radiological features of seven cases and a review of the literature. *Clin Radiol* 1992;45:371-7.
- Roberts CM, Foulcher E, Zaunders JJ, et al. Radiation pneumonitis: a possible lymphocyte-mediated hypersensitivity reaction. *Ann Intern Med* 1993;118:696-700.
- Martin C, Romero S, Sanchez-Paya J, et al. Bilateral lymphocytic alveolitis: a common reaction after unilateral thoracic irradiation. *Eur Respir J* 1999;13:727-32.
- Schwarz MI, Matthay RA, Sahn SA, et al. Interstitial lung disease in polymyositis and dermatomyositis: analysis of six cases and review of the literature. *Medicine* 1976;55:89-104.
- Tazelaar HD, Viggiano RW, Pickersgill J, et al. Interstitial lung disease in polymyositis and dermatomyositis. Clinical features and prognosis as correlated with histologic @ndings. *Am Rev Respir Dis* 1990;141:727-33.
- Chan WM, Ip M, Lau CS, et al. Anti-Jo1 syndrome presenting as cryptogenic organizing pneumonia. *Respir Med* 1995;89:639-41.
- Epler GR. Miscellaneous causes of bronchiolitis obliterans. In: Epler GR, ed. *Diseases of the bronchioles*. New York: Raven Press, 1994: 291-3.
- Hsue YT, Paulus HE, Coulson WF. Bronchiolitis obliterans organizing pneumonia in polymyositis. A case report with longterm survival. *J Rheumatol* 1993;20:877-9.
- Lakhanpal S, Lie JT, Conn DL, et al. Pulmonary disease in polymyositis/dermatomyositis: a clinicopathological analysis of 65 autopsy cases. *Ann Rheum Dis* 1987;46:23-9.
- Mahler DA. Dyspnea and muscle weakness in a 65 year-old woman. *Chest* 1992;102:1875-6.
- Takizawa H, Shiga J, Moroi Y, et al. Interstitial lung disease in dermatomyositis: clinicopathological study. *J Rheumatol* 1987;14:102-7.
- Akira M, Hara H, Sakatani M. Interstitial lung disease in association with polymyositis-dermatomyositis: long-term follow-up CT evaluation in seven patients. *Radiology* 1999;210:333-8.



- 34 Ikezoe J, Johkoh T, Kohno N, *et al*. High-resolution CT findings of lung disease in patients with polymyositis and dermatomyositis. *J Thorac Imaging* 1996;11:250-9.
- 35 Kalenian M, Zweiman B. Inflammatory myopathy, bronchiolitis obliterans/organizing pneumonia, and anti-Jo-1 antibodies: an interesting association. *Clin Diagn Lab Immunol* 1997;4:236-40.
- 36 Imasaki T, Yoshii A, Tanaka S, *et al*. Polymyositis and Sjogren's syndrome associated with bronchiolitis obliterans organizing pneumonia. *Intern Med* 1996;35:231-5.
- 37 Yousem SA, Colby TV, Carrington CB. Lung biopsy in rheumatoid arthritis. *Am Rev Respir Dis* 1985;131:770-7.
- 38 Hakala M, Paakko P, Sutinen S, *et al*. Association of bronchiolitis with connective tissue disorders. *Ann Rheum Dis* 1986;45:656-62.
- 39 Ippolito JA, Palmer L, Spector S, *et al*. Bronchiolitis obliterans organizing pneumonia and rheumatoid arthritis. *Semin Arthritis Rheum* 1993;23:70-8.
- 40 Katzenstein AL, Myers JL, Prophet WD, *et al*. Bronchiolitis obliterans and usual interstitial pneumonia. A comparative clinicopathologic study. *Am J Surg Pathol* 1986;10:373-81.
- 41 Rees JH, Woodhead MA, Sheppard MN, *et al*. Rheumatoid arthritis and cryptogenic organising pneumonitis. *Respir Med* 1991;85:243-6.
- 42 van Thiel RJ, van der Burg S, Groote AD, *et al*. Bronchiolitis obliterans organizing pneumonia and rheumatoid arthritis. *Eur Respir J* 1991;4:905-11.
- 43 Yamamoto M, Ina Y, Kitaichi M, *et al*. Clinical features of BOOP in Japan. *Chest* 1992;102:21-5S.
- 44 Matteson EL, Ike RW. Bronchiolitis obliterans organizing pneumonia and Sjogren's syndrome. *J Rheumatol* 1990;17:676-9.
- 45 Usui Y, Kimula Y, Miura H, *et al*. A case of bronchiolitis obliterans organizing pneumonia associated with primary Sjogren's syndrome who died of superimposed diffuse alveolar damage. *Respiration* 1992;59:122-4.
- 46 Gammon RB, Bridges TA, al-Nezir H, *et al*. Bronchiolitis obliterans organizing pneumonia associated with systemic lupus erythematosus. *Chest* 1992;102:1171-4.
- 47 Mana F, Mets T, Vincken W, *et al*. The association of bronchiolitis obliterans organizing pneumonia, systemic lupus erythematosus, and Hunner's cystitis. *Chest* 1993;104:642-4.
- 48 Min JK, Hong YS, Park SH, *et al*. Bronchiolitis obliterans organizing pneumonia as an initial manifestation in patients with systemic lupus erythematosus. *J Rheumatol* 1997;24:2254-7.
- 49 Nadorra RL, Landing BH. Pulmonary lesions in childhood onset systemic lupus erythematosus: analysis of 26 cases, and summary of literature. *Pediatr Pathol* 1987;7:1-18.
- 50 Bridges AJ, Hsu KC, Dias-Arias AA, *et al*. Bronchiolitis obliterans organizing pneumonia and scleroderma. *J Rheumatol* 1992;19:1136-40.
- 51 Wells AU, du Bois RM. Bronchiolitis in association with connective tissue disorders. *Clin Chest Med* 1993;14:655-66.
- 52 Lynch JP, Belperio J, Flint A, *et al*. Bronchiolar complications of connective tissue disorders. *Semin Respir Crit Care Med* 1999;20:149-68.
- 53 Uner AH, Rozum-Slota B, Katzenstein AL. Bronchiolitis obliterans-organizing pneumonia (BOOP)-like variant of Wegener's granulomatosis. A clinicopathologic study of 16 cases. *Am J Surg Pathol* 1996;20:794-801.
- 54 Robinson BW, Sterrett G. Bronchiolitis obliterans associated with polyarteritis nodosa. *Chest* 1992;102:309-11.
- 55 Abernathy EC, Hruban RH, Baumgartner WA, *et al*. The two forms of bronchiolitis obliterans in heart-lung transplant recipients. *Hum Pathol* 1991;22:1102-10.
- 56 Barberis M, Bauer D, Harari S, *et al*. Early infections and bronchiolitis obliterans-organizing pneumonia in single lung transplant recipients. *J Heart Lung Transplant* 1992;11:1012-4.
- 57 Chaparro C, Chamberlain D, Maurer J, *et al*. Bronchiolitis obliterans organizing pneumonia (BOOP) in lung transplant recipients. *Chest* 1996;110:1150-4.
- 58 de Hoyos AL, Patterson GA, Maurer JR, *et al*. Pulmonary transplantation. Early and late results. The Toronto Lung Transplant Group. *J Thorac Cardiovasc Surg* 1992;103:295-306.
- 59 Egan JJ, Sarker S, Hasleton PS, *et al*. Should cryptogenic organizing pneumonia be included in the classification of pulmonary allograft rejection? *J Heart Lung Transplant* 1996;15:1268-9.
- 60 Loire R, Brune J, Cordier JF, *et al*. Diversité anatomoclinique des bronchiolites oblitérantes après transplantation pulmonaire. Etude anatomique de 16 cas sur 64 transplantations. *Arch Anat Cytol Pathol* 1993;41:232-9.
- 61 Siddiqui MT, Garrity ER, Husain AN. Bronchiolitis obliterans organizing pneumonia-like reactions: a nonspecific response or an atypical form of rejection of infection in lung allograft recipients? *Hum Pathol* 1996;27:714-9.
- 62 Yousem SA, Duncan SR, Griffith BP. Interstitial and airspace granulation tissue reactions in lung transplant recipients. *Am J Surg Pathol* 1992;16:877-84.
- 63 Alasaly K, Muller N, Ostrow DN, *et al*. Cryptogenic organizing pneumonia. A report of 25 cases and a review of the literature. *Medicine* 1995;74:201-11.
- 64 Mathew P, Bozeman P, Krance RA, *et al*. Bronchiolitis obliterans organizing pneumonia (BOOP) in children after allogeneic bone marrow transplantation. *Bone Marrow Transplant* 1994;13:221-3.
- 65 Thirman MJ, Devine SM, O'Toole K, *et al*. Bronchiolitis obliterans organizing pneumonia as a complication of allogeneic bone marrow transplantation. *Bone Marrow Transplant* 1992;10:307-11.
- 66 Yousem SA. The histological spectrum of pulmonary graft-versus-host disease in bone marrow transplant recipients. *Hum Pathol* 1995;26:668-75.
- 67 Chien SM, Jambrosic J, Mintz S. Pulmonary manifestations in Sweet's syndrome: first report of a case with bronchiolitis obliterans organizing pneumonia. *Am J Med* 1991;91:553-4.
- 68 Reid PT, Alderdice J, Carson J, *et al*. Cryptogenic organizing pneumonia in association with Sweet's syndrome. *Respir Med* 1996;90:57-9.
- 69 Camus P, Piard F, Ashcroft T, *et al*. The lung in inflammatory bowel disease. *Medicine* 1993;72:151-83.
- 70 Swinburn CR, Jackson GJ, Cobden I, *et al*. Bronchiolitis obliterans organising pneumonia in a patient with ulcerative colitis. *Thorax* 1988;43:735-6.
- 71 Case records of the Massachusetts General Hospital (case 24-1986). *N Engl J Med* 1986;314:1627-35.
- 72 Stey C, Truninger K, Marti D, *et al*. Bronchiolitis obliterans organizing pneumonia associated with polymyalgia rheumatica. *Eur Respir J* 1999;13:929-9.
- 73 Rutherford PA, Veale D, Ashcroft T, *et al*. Mesangiocapillary glomerulonephritis as the presenting feature of cryptogenic organizing pneumonitis. *Nephrol Dial Transplant* 1992;7:1043-6.
- 74 Tenholder MF, Becker GL, Cervoni MI. The myelodysplastic syndrome and bronchiolitis obliterans. *Ann Intern Med* 1990;112:714-5.
- 75 Stemmelin GR, Bernaciak J, Casas JG. Bronchiolitis with leukemia. *Ann Intern Med* 1991;114:912-3.
- 76 Helton KJ, Kuhn JP, Fletcher BD. Bronchiolitis obliterans-organizing pneumonia (BOOP) in children with malignant disease. *Pediatr Radiol* 1992;22:270-4.
- 77 Battistini E, Dini G, Savioi C, *et al*. Bronchiolitis obliterans organizing pneumonia in three children with acute leukemias treated with cytosine arabinoside and anthracyclines. *Eur Respir J* 1997;10:1187-90.
- 78 Kaufman J, Komorowski R. Bronchiolitis obliterans organizing pneumonia in common variable immunodeficiency syndrome. *Chest* 1991;100:552-3.
- 79 Watanabe K, Senju S, Wen FQ, *et al*. Factors related to the relapse of bronchiolitis obliterans organizing pneumonia. *Chest* 1998;114:1599-606.
- 80 Cordier JF. Cryptogenic organizing pneumonitis. Bronchiolitis obliterans organizing pneumonia. *Clin Chest Med* 1993;14:677-92.
- 81 Davison AG, Heard BE, McAllister WAC, *et al*. Cryptogenic organizing pneumonitis. *Q J Med* 1983;52:382-94.
- 82 Epler GR, Colby TV, McLoud TC, *et al*. Bronchiolitis obliterans organizing pneumonia. *N Engl J Med* 1985;312:152-8.
- 83 Bartter T, Irwin RS, Nash G, *et al*. Idiopathic bronchiolitis obliterans organizing pneumonia with peripheral infiltrates on chest roentgenogram. *Arch Intern Med* 1989;149:273-9.
- 84 Cordier JF, Loire R, Brune J. Idiopathic bronchiolitis obliterans organizing pneumonia. Definition of characteristic clinical profiles in a series of 16 patients. *Chest* 1989;96:999-1004.
- 85 Dur P, Vogt P, Russi E. "Bronchiolitis obliterans organizing pneumonia" (BOOP): chronisch organisierende Pneumonie (COP). Diagnostik, Therapie und Verlauf. *Schweiz Med Wochenschr* 1993;123:1429-38.
- 86 Miyagawa Y, Nagata N, Shigematsu N. Clinicopathological study of migratory lung infiltrates. *Thorax* 1991;46:233-8.
- 87 Costabel U, Teschler H, Schoenfeld B, *et al*. BOOP in Europe. *Chest* 1992;102(suppl 1):14-20S.
- 88 Guerry-Force ML, Muller NL, Wright JL, *et al*. A comparison of bronchiolitis obliterans with organizing pneumonia, usual interstitial pneumonia, and small airways disease. *Am Rev Respir Dis* 1987;135:705-12.
- 89 Izumi T, Kitaichi M, Nishimura K, *et al*. Bronchiolitis obliterans organizing pneumonia. Clinical features and differential diagnosis. *Chest* 1992;102:715-9.
- 90 King TE Jr, Mortenson RL. Cryptogenic organizing pneumonitis. The North American experience. *Chest* 1992;102:8-13S.
- 91 Inoue T, Toyoshima K, Kikui M. Idiopathic bronchiolitis obliterans organizing pneumonia (idiopathic BOOP) in childhood. *Pediatr Pulmonol* 1996;22:67-72.
- 92 Spiteri MA, Klernerman P, Sheppard MN, *et al*. Seasonal cryptogenic organising pneumonia with biochemical cholestasis: a new clinical entity. *Lancet* 1992;340:281-4.
- 93 Mroz BJ, Sexauer WP, Meade A, *et al*. Hemoptysis as the presenting symptom in bronchiolitis obliterans organizing pneumonia. *Chest* 1997;111:1775-8.
- 94 Nishimura K, Itoh H. High-resolution computed tomographic features of bronchiolitis obliterans organizing pneumonia. *Chest* 1992;102:26-31S.
- 95 Ackerman LV, Elliott G, Alanis M. Localized organizing pneumonia: its resemblance to carcinoma. A review of its clinical roentgenographic and pathologic features. *AJR* 1954;71:988-96.
- 96 Alegre-Martin J, Fernandez de Sevilla T, Garcia F, *et al*. Three cases of idiopathic bronchiolitis obliterans with organizing pneumonia. *Eur Respir J* 1991;4:902-4.
- 97 Bellomo R, Finlay M, McLaughlin P, *et al*. Clinical spectrum of cryptogenic organising pneumonitis. *Thorax* 1991;46:554-8.
- 98 Chandler PW, Shin MS, Friedman SE, *et al*. Radiographic manifestations of bronchiolitis obliterans with organizing pneumonia vs usual interstitial pneumonia. *AJR* 1986;147:899-906.



- 99 Epstein DM, Bennett MR. Bronchiolitis obliterans organizing pneumonia with migratory pulmonary infiltrates. *AJR* 1992;158:515-7.
- 100 Giron J, Parizet C, Senac JP, et al. La bronchiolite oblitérante avec organisation pneumonique. A propos d'un cas et revue de la littérature. *J Radiol* 1991;72:95-100.
- 101 Kelkel E, Brambilla E, Pison C, et al. La bronchiolite oblitérante avec pneumonie organisée idiopathique. Analyse anatomo-clinique et discussion nosologique. A propos de 6 observations. *Ann Med Interne* 1990;141:661-7.
- 102 Louise dit Lemiere T, Carette MF, Roland J, et al. Bronchiolite oblitérante avec pneumonie organisée idiopathique. Suivi tomodensitométrique de deux cas atypiques. *Rev Imagerie Med* 1991;3:729-32.
- 103 Meister P, Pickl-Pfeffer S, Rabben U. Bronchiolitis obliterans mit organisierender Pneumonie(BOOP). Fallbericht und Diskussion des Krankheitsbildes. *Pathologe* 1989;10:43-7.
- 104 Muller NL, Staples CA, Miller RR. Bronchiolitis obliterans organizing pneumonia: CT features in 14 patients. *AJR* 1990;154:983-7.
- 105 Muller NL, Guerry-Force ML, Staples CA, et al. Differential diagnosis of bronchiolitis obliterans with organizing pneumonia and usual interstitial pneumonia: clinical, functional, and radiologic findings. *Radiology* 1987;162:151-6.
- 106 Nishimura K, Izumi T, Kitaichi M, et al. The diagnostic accuracy of high-resolution computed tomography in diffuse infiltrative lung diseases. *Chest* 1993;104:1149-55.
- 107 Patel U, Jenkins PF. Bronchiolitis obliterans organizing pneumonia. *Respir Med* 1989;83:241-4.
- 108 Teschler H, Costabel U, Greschuchna D, et al. Bronchiolitis obliterans mit organisierender Pneumonie. *Atenue Lungenkrkh Jahrgang* 1989;15:288-92.
- 109 Haddock JA, Hansell DM. The radiology and terminology of cryptogenic organizing pneumonia. *Br J Radiol* 1992;65:674-80.
- 110 Preidler KW, Szolar DM, Moelleken S, et al. Distribution pattern of computed tomography findings in patients with bronchiolitis obliterans organizing pneumonia. *Invest Radiol* 1996;31:251-5.
- 111 Voloudaki AE, Bouros DE, Froudarakis ME, et al. Crescentic and ring-shaped opacities. CT features in two cases of bronchiolitis organizing pneumonia (BOOP). *Acta Radiol* 1996;37:889-92.
- 112 Kohno N, Ikezoe J, Johkoh T, et al. Focal organizing pneumonia: CT appearance. *Radiology* 1993;189:119-23.
- 113 Bouchardy LM, Kuhlman JE, Ball WC, et al. CT findings in bronchiolitis obliterans organizing pneumonia (BOOP) with radiographic, clinical, and histologic correlation. *J Comput Assist Tomogr* 1993;17:352-7.
- 114 Haro M, Vizcaya M, Texido A, et al. Idiopathic bronchiolitis obliterans organizing pneumonia with multiple cavitory lung nodules. *Eur Respir J* 1995;11:1975-7.
- 115 Froudarakis M, Bouros D, Loire R, et al. BOOP presenting with haemoptysis and multiple cavitory nodules. *Eur Respir J* 1995;8:1972-4.
- 116 Linsen VMJ, van Noord JA. A large air-filled cyst in a patient with migratory infiltrates. *Chest* 1994;105:253-4.
- 117 Domingo JA, Perez-Calvo JL, Carretero JA, et al. Bronchiolitis obliterans organizing pneumonia. An unusual cause of solitary pulmonary nodule. *Chest* 1993;103:1621-3.
- 118 Akira M, Yamamoto S, Sakatani M. Bronchiolitis obliterans organizing pneumonia manifesting as multiple large nodules or masses. *AJR* 1998;170:291-5.
- 119 Patel AR. Cyclophosphamide therapy and interstitial pulmonary fibrosis. *Cancer* 1976;38:1542-9.
- 120 Costabel U, Teschler H, Guzman J. Bronchiolitis obliterans organizing pneumonia (BOOP): the cytological and immunocytological profile of bronchoalveolar lavage. *Eur Respir J* 1992;5:791-7.
- 121 Pesci A, Majori M, Piccoli ML, et al. Mast cells in bronchiolitis obliterans organizing pneumonia. Mast cell hyperplasia and evidence for extracellular release of tryptase. *Chest* 1996;110:383-91.
- 122 Poletti V, Castrilli G, Romagna M, et al. Bronchoalveolar lavage, histological and immunohistochemical features in cryptogenic organizing pneumonia. *Monaldi Arch Chest Dis* 1996;51:289-95.
- 123 Mukae H, Kadota JI, Kohno S, et al. Increase of activated T-cells in BAL fluid of Japanese patients with bronchiolitis obliterans organizing pneumonia and chronic eosinophilic pneumonia. *Chest* 1995;108:123-8.
- 124 Nagai S, Aung H, Tanaka S, et al. Bronchoalveolar lavage cell findings in patients with BOOP and related diseases. *Chest* 1992;102:32-7S.
- 125 Colby TV, Myers JL. Clinical and histologic spectrum of bronchiolitis obliterans, including bronchiolitis obliterans organizing pneumonia. *Semin Respir Med* 1992;13:119-33.
- 126 Colby TV, Lombard C, Yousem SA, et al. *Atlas of pulmonary surgical pathology*. Philadelphia: WB Saunders, 1991.
- 127 Kitaichi M. Differential diagnosis of bronchiolitis obliterans organizing pneumonia. *Chest* 1992;102:44-9S.
- 128 Azzam ZS, Bentur L, Rubin AH, et al. Bronchiolitis obliterans organizing pneumonia. Diagnosis by transbronchial biopsy. *Chest* 1993;104:1899-901.
- 129 Dina R, Sheppard MN. The histological diagnosis of clinically documented cases of cryptogenic organizing pneumonia: diagnostic features in transbronchial biopsies. *Histopathology* 1993;23:541-5.
- 130 Poletti V, Cazzato S, Minicuci N, et al. The diagnostic value of bronchoalveolar lavage and transbronchial lung biopsy in cryptogenic organizing pneumonia. *Eur Respir J* 1996;9:2513-6.
- 131 Boon ES, Graal MB, van Noord JA. Primary extranodal non-Hodgkin's lymphoma of the lung presenting with bilateral, patchy infiltrates dramatically improving after corticosteroid therapy. *Chest* 1993;104:1292-3.
- 132 Ichikawa Y, Ninomiya H, Katsuki M, et al. Long-dose/long-term erythromycin for treatment of bronchiolitis obliterans organizing pneumonia (BOOP). *Kurume Med J* 1993;40:65-7.
- 133 Epler GR. Heterogeneity of bronchiolitis obliterans organizing pneumonia. *Curr Opin Pulm Med* 1998;4:93-7.
- 134 Wright L, King TE. Cryptogenic organizing pneumonia (idiopathic bronchiolitis obliterans organizing pneumonia): an update. *Clin Pulm Med* 1997;4:152-8.
- 135 Lazor R, Vandevenne A, Pelletier A, et al, and the "Groupe d'Etudes et de Recherche sur les Maladies Orphelines Pulmonaires". Cryptogenic organizing pneumonia: characteristics of relapses in a series of 48 patients. *Am J Respir Crit Care Med* 1999;159:A65.
- 136 Costabel U, Guzman J, Teschler H. Bronchiolitis obliterans with organising pneumonia: outcome. *Thorax* 1995;50(suppl 1):S59-64.
- 137 Cohen AJ, King TE Jr, Downey GP. Rapidly progressive bronchiolitis obliterans with organizing pneumonia. *Am J Respir Crit Care Med* 1994;149:1670-5.
- 138 Nizami IY, Kissner DG, Visscher DW, et al. Idiopathic bronchiolitis obliterans with organizing pneumonia. An acute and life-threatening syndrome. *Chest* 1995;108:271-7.
- 139 Pérez de Llano LA, Soilan JL, Garcia Pais MJ, et al. Idiopathic bronchiolitis obliterans with organizing pneumonia presenting with adult respiratory distress syndrome. *Respir Med* 1998;92:884-6.
- 140 Schwarz MI. Diffuse pulmonary infiltrates and respiratory failure following 2 weeks of dyspnea in a 45-year-old woman. *Chest* 1993;104:927-9.
- 141 Yousem SA, Lohr RH, Colby TV. Idiopathic bronchiolitis obliterans organizing pneumonia/cryptogenic organizing pneumonia with unfavorable outcome: pathologic predictors. *Mod Pathol* 1997;10:864-71.
- 142 Purcell IF, Bourke SJ, Marshall SM. Cyclophosphamide in severe steroid-resistant bronchiolitis obliterans organizing pneumonia. *Respir Med* 1997;91:175-7.
- 143 Guillevin L, Cordier JF, Lhote F, et al. A prospective, multicenter, randomized trial comparing steroids and pulse cyclophosphamide versus steroids and oral cyclophosphamide in the treatment of generalized Wegener's granulomatosis. *Arthritis Rheum* 1997;40:2187-98.
- 144 Cordier JF, Peyrol S, Loire R. Bronchiolitis obliterans organizing pneumonia as a model of inflammatory lung disease. In: Epler GR, ed. *Diseases of the bronchioles*. New York: Raven Press, 1994: 313-45.
- 145 Cordier JF. The concept of organizing pneumonia. In: Desmoulière A, Tuchweber B, eds. *Tissue repair and fibrosis. The role of the myofibroblast*. Berlin: Springer, 1999: 149-56.
- 146 Laennec RTH. *Traité de l'auscultation médiate et des maladies des poumons et du coeur*. 2nd ed. Paris: Chaudet, 1826.
- 147 Auerbach SH, Mims OM, Goodpasture EW. Pulmonary fibrosis secondary to pneumonia. *Am J Pathol* 1952;28:69-87.
- 148 Grunow WA, Esterly JR. Rheumatic pneumonitis. *Chest* 1972;61:298-301.
- 149 Lustok MJ, Kuzma JF. Rheumatic fever pneumonitis: a clinical and pathologic study of 35 cases. *Ann Intern Med* 1956;44:337-51.
- 150 Fukuda Y, Ishizaki M, Masuda Y, et al. The role of intra-alveolar fibrosis in the process of pulmonary structural remodeling in patients with diffuse alveolar damage. *Am J Pathol* 1987;126:171-82.
- 151 Svee K, White J, Vaillant P, et al. Acute lung injury fibroblast migration and invasion of a fibrin matrix is mediated by CD44. *J Clin Invest* 1996;98:1713-27.
- 152 Gray AJ, Bishop JE, Reeves JT, et al. Partially degraded fibrin(ogen) stimulates fibroblast proliferation in vitro. *Am J Respir Cell Mol Biol* 1995;12:684-90.
- 153 Leavell KJ, Peterson MW, Gross TJ. The role of fibrin degradation products in neutrophil recruitment to the lung. *Am J Respir Cell Mol Biol* 1996;14:53-60.
- 154 Dabbagh K, Chambers RC, Laurent GJ. From clot to collagen: coagulation peptides in interstitial lung disease. *Eur Respir J* 1998;11:1002-5.
- 155 Basset F, Ferrans VJ, Soler P, et al. Intraluminal fibrosis in interstitial lung disorders. *Am J Pathol* 1986;122:443-61.
- 156 Myers JL, Katzenstein AL. Ultrastructural evidence of alveolar epithelial injury in idiopathic bronchiolitis obliterans organizing pneumonia. *Am J Pathol* 1988;132:102-9.
- 157 Peyrol S, Cordier JF, Grimaud JA. Intra-alveolar fibrosis of idiopathic bronchiolitis obliterans-organizing pneumonia. Cell-matrix patterns. *Am J Pathol* 1990;137:155-70.
- 158 Kuhn C, Boldt J, King TE Jr, et al. An immunohistochemical study of architectural remodeling and connective tissue synthesis in pulmonary fibrosis. *Am Rev Respir Dis* 1989;140:1693-703.
- 159 Kuhn C, McDonald JA. The roles of the myofibroblast in idiopathic pulmonary fibrosis. Ultrastructural and immunohistochemical features of sites of active extracellular matrix synthesis. *Am J Pathol* 1991;138:1257-65.
- 160 Bellum SC, Dove D, Harley RA, et al. Respiratory reovirus 1/L induction of intraluminal fibrosis. A model for the study of bronchiolitis obliterans organizing pneumonia. *Am J Pathol* 1997;150:2243-54.
- 161 Imokawa S, Sato A, Hayakawa H, et al. Tissue factor expression and fibrin deposition in the lungs of patients with idiopathic pulmonary fibrosis and systemic sclerosis. *Am J Respir Crit Care Med* 1997;156:631-6.

- 162 Kuhn C, Mason RJ. Immunolocalization of SPARC, tenascin, and thrombospondin in pulmonary fibrosis. *Am J Pathol* 1995;147:1759-69.
- 163 Carré PC, King TE Jr, Mortensen R, et al. Cryptogenic organizing pneumonia: increased expression of interleukin-8 and fibronectin genes by alveolar macrophages. *Am J Respir Cell Mol Biol* 1994;10:100-5.
- 164 Aubert JD, Pare PD, Hogg JC, et al. Platelet-derived growth factor in bronchiolitis obliterans-organizing pneumonia. *Am J Respir Crit Care Med* 1997;155:676-81.
- 165 Edwards DRG, Murphy G, Reynolds JJ, et al. Transforming growth factor beta modulates the expression of collagenase and metalloproteinase inhibitor. *EMBO J* 1987;6:1899-904.
- 166 Postlethwaite AE, Lachman LB, Mainardi CL, et al. Interleukin 1 stimulation of collagenase production by cultured fibroblasts. *J Exp Med* 1983;157:801-6.
- 167 Emonard H, Takiya C, Dreze S, et al. Interstitial collagenase (MMP-1), gelatinase (MMP-2) and stromelysin (MMP-3) released by human fibroblasts cultured on acellular sarcoid granulomas (sarcoid matrix complex, SMC). *Matrix* 1989;9:382-8.
- 168 Unemori EN, Pickford LB, Salles AL, et al. Relaxin induces an extracellular matrix-degrading phenotype in human lung fibroblasts in vitro and inhibits lung fibrosis in a murine model in vivo. *J Clin Invest* 1996;98:2739-45.
- 169 Case records of the Massachusetts General Hospital (case 48-1990). *N Engl J Med* 1990;323:1546-55.
- 170 Diehl JL, Gisselbrecht M, Meyer G, et al. Bronchiolitis obliterans organizing pneumonia associated with chlamydial infection. *Eur Respir J* 1996;9:1320-2.
- 171 Janigan DR, Marrie TJ. An inflammatory pseudotumor of the lung in Q fever pneumonia. *N Engl J Med* 1983;308:86-8.
- 172 Sato P, Madtes DK, Thorning D, et al. Bronchiolitis obliterans caused by *Legionella pneumophila*. *Chest* 1985;87:840-2.
- 173 Chastre J, Raghu G, Soler P, et al. Pulmonary fibrosis following pneumonia due to acute legionnaires' disease. Clinical, ultrastructural, and immunofluorescent study. *Chest* 1987;91:57-62.
- 174 Case records of the Massachusetts General Hospital (case 32-1978). *N Engl J Med* 1978;299:347-54.
- 175 Hernandez FJ, Kirby BD, Stanley TM, et al. Legionnaires' disease. Postmortem pathologic findings of 20 cases. *Am J Clin Pathol* 1980;73:488-95.
- 176 Winn WCJ, Myerowitz RL. The pathology of the legionella pneumonias. A review of 74 cases and the literature. *Hum Pathol* 1981;12:401-22.
- 177 Rollins S, Colby TV, Clayton F. Open lung biopsy in *Mycoplasma pneumoniae* pneumonia. *Arch Pathol Lab Med* 1986;110:34-41.
- 178 Case records of the Massachusetts General Hospital (case 42-1991). *N Engl J Med* 1991;325:1155-65.
- 179 Camp M, Mehta JB, Whitson M. Bronchiolitis obliterans and *Nocardia asteroides* infection of the lung. *Chest* 1987;92:1107-8.
- 180 Goldstein JD, Godleski JJ, Balikian JP, et al. Pathologic patterns of *Serratia marcescens* pneumonia. *Hum Pathol* 1982;13:479-84.
- 181 Mayock DE, O'Rourke PP, Kapur RP. Bronchiolitis obliterans: a complication of group B streptococcal disease treated with extracorporeal membrane oxygenation. *Pediatrics* 1993;92:157-60.
- 182 Case records of the Massachusetts General Hospital (case 22-1973). *N Engl J Med* 1973;288:1173-80.
- 183 Allen JN, Wewers MD. HIV-associated bronchiolitis obliterans organizing pneumonia. *Chest* 1989;96:197-8.
- 184 Sanito NJ, Morley TF, Condoluci DV. Bronchiolitis obliterans organizing pneumonia in an AIDS patient. *Eur Respir J* 1995;8:1021-4.
- 185 Leo YS, Pitchon HE, Messler G, et al. Bronchiolitis obliterans organizing pneumonia in a patient with AIDS. *Clin Infect Dis* 1994;18:921-4.
- 186 Winterbauer RH, Ludwig WR, Hammar SP. Clinical course, management, and long-term sequelae of respiratory failure due to influenza viral pneumonia. *Johns Hopkins Med J* 1977;141:148-55.
- 187 Peramaki E, Salmi I, Kava T, et al. Unilateral bronchiolitis obliterans organizing pneumonia and bronchoalveolar lavage neutrophilia in a patient with parainfluenza 3 virus infection. *Respir Med* 1991;85:159-61.
- 188 Yale SH, Adlakha A, Sebo TJ, et al. Bronchiolitis obliterans organizing pneumonia caused by *Plasmodium vivax* malaria. *Chest* 1993;104:1294-6.
- 189 Carey CF, Mueller L, Fotopoulos CL, et al. Bronchiolitis obliterans-organizing pneumonia associated with *Cryptococcus neoformans* infection. *Rev Infect Dis* 1991;13:1253-4.
- 190 Bates C, Read RC, Morice AH. A malicious mould. *Lancet* 1997;349:1598.
- 191 Foley NM, Griffiths MH, Miller RF. Histologically atypical *Pneumocystis carinii* pneumonia. *Thorax* 1993;48:996-1001.
- 192 Liote H, Porte JM, Postal MJ, et al. Bronchiolite oblitérante, pneumocystose et infection par le VIH. *Rev Mal Respir* 1990;7:603-7.
- 193 Camus P, Lombard JN, Perrichon M, et al. Bronchiolitis obliterans organising pneumonia in patients taking acetylmol or amiodarone. *Thorax* 1989;44:711-5.
- 194 Moya C, Anto JM, Taylor AJ. Outbreak of organizing pneumonia in textile printing sprayers. *Lancet* 1994;343:498-502.
- 195 Romero S, Hernandez L, Gil J, et al. Organizing pneumonia in textile printing workers: a clinical description. *Eur Respir J* 1998;11:265-71.
- 196 Camus P, Nemery B. A novel cause for bronchiolitis obliterans organizing pneumonia: exposure to paint aerosols in textile workshops. *Eur Respir J* 1998;11:259-62.
- 197 Myers JL. Diagnosis of drug reactions in the lung. In: Churg A, Katzenstein ALA, eds. *The lung: current concepts*. Philadelphia: Williams and Wilkins, 1993: 32-53.
- 198 Myers JL, Kennedy JI, Plumb VJ. Amiodarone lung: pathologic findings in clinically toxic patients. *Hum Pathol* 1987;18:349-54.
- 199 Valle JM, Alvarez D, Antunez J, et al. Bronchiolitis obliterans organizing pneumonia secondary to amiodarone: a rare aetiology. *Eur Respir J* 1995;8:470-1.
- 200 Oren S, Turkot S, Goltzman B, et al. Amiodarone-induced bronchiolitis obliterans organizing pneumonia (BOOP). *Respir Med* 1996;90:167-9.
- 201 Jessurun GAJ, Hoogenberg K, Crijns HJGM. Bronchiolitis obliterans organizing pneumonia during low-dose amiodarone therapy. *Clin Cardiol* 1997;20:300-2.
- 202 Conte SCS, Pagan V, Murer B. Bronchiolitis obliterans organizing pneumonia secondary to amiodarone: clinical, radiological and histological pattern. *Monaldi Arch Chest Dis* 1997;52:24-6.
- 203 Roncoroni AJ, Corrado C, Besuschio S, et al. Bronchiolitis obliterans possibly associated with amphotericin B. *J Infect Dis* 1990;161:589.
- 204 Catterall JR, McCabe RE, Brooks RG, et al. Open lung biopsy in patients with Hodgkin's disease and pulmonary infiltrates. *Am Rev Respir Dis* 1989;139:1274-9.
- 205 Glasier CM, Siegel MJ. Multiple pulmonary nodules: unusual manifestation of bleomycin toxicity. *AJR* 1981;137:155-6.
- 206 Luna MA, Bedrossian CWM, Lichtiger B, et al. Interstitial pneumonitis associated with bleomycin therapy. *Am J Clin Pathol* 1972;58:501-10.
- 207 Nachman JB, Baum ES, White H, et al. Bleomycin-induced pulmonary fibrosis mimicking recurrent metastatic disease in a patient with testicular carcinoma: case report of the CT scan appearance. *Cancer* 1981;47:236-9.
- 208 O'Neill TJ, Kardinal CG, Tierney LM. Reversible interstitial pneumonitis associated with low dose bleomycin. *Chest* 1975;68:265-67.
- 209 Rosenow EC, Myers JL, Swensen SJ, et al. Drug induced pulmonary disease. An update. *Chest* 1992;102:239-50.
- 210 Santrach PJ, Askin FB, Wells RJ, et al. Nodular form of bleomycin-related pulmonary injury in patients with osteogenic sarcoma. *Cancer* 1989;64:806-11.
- 211 Yousem SA, Lifson J, Colby TV. Chemotherapy-induced eosinophilic pneumonia: relation to bleomycin. *Chest* 1985;88:103-6.
- 212 Zucker PK, Khouri NF, Rosenshein NB. Bleomycin-induced pulmonary nodules: a variant of bleomycin pulmonary toxicity. *Gynecol Oncol* 1987;28:284-91.
- 213 About I, Lauque D, Levenes H, et al. Opacités alvéolaires et pneumopathies au busulfan. *Rev Mal Respir* 1992;9:39-41.
- 214 Heard BE, Cooke RA. Busulphan lung. *Thorax* 1968;23:187-93.
- 215 Schmidt J, Moinard J, Milési AM, et al. Pneumopathie organisée avec bronchiolite oblitérante (BOOP) et syndrome lupique induits par la carbamazépine. *Rev Med Interne* 1995;16(suppl 1):146.
- 216 Dreis DF, Winterbauer RH, Van Norman GA, et al. Cephalosporin-induced interstitial pneumonitis. *Chest* 1984;86:138-40.
- 217 Patel RC, Dutta D, Schonfeld SA. Free-base cocaine use associated with bronchiolitis obliterans organizing pneumonia. *Ann Intern Med* 1987;107:186-7.
- 218 McCormick J, Cole S, Lahiri B, et al. Pneumonitis caused by gold salt therapy: evidence for the role of cell-mediated immunity in its pathogenesis. *Am Rev Respir Dis* 1980;122:145-52.
- 219 Sepuya SM, Grzybowski S, Burton JD, et al. Diffuse lung changes associated with gold therapy. *Can Med Assoc J* 1978;118:816-8.
- 220 Doniach I, Morrison B, Steiner RE. Lung changes during hexamethonium therapy for hypertension. *Br Heart J* 1954;16:101-8.
- 221 Mar KE, Sen P, Tan K, et al. Bronchiolitis obliterans organizing pneumonia associated with massive L-tryptophan ingestion. *Chest* 1993;104:1924-6.
- 222 Tanigawa K, Sugiyama K, Matsuyama H, et al. Mesalazine-induced eosinophilic pneumonia. *Respiration* 1999;66:69-72.
- 223 Piperno D, Donnè C, Loire R, et al. Bronchiolitis obliterans organizing pneumonia associated with minocycline therapy: a possible cause. *Eur Respir J* 1995;8:1018-20.
- 224 Pfitzenmeyer P, Foucher P, Piard F, et al. Nitlutamide pneumonitis: a report on eight patients. *Thorax* 1992;47:622-7.
- 225 Copland GM, Kolin A, Shulman HS. Fatal pulmonary intra-alveolar fibrosis after paraquat ingestion. *N Engl J Med* 1974;291:290-2.
- 226 Angle P, Thomas P, Chiu B, et al. Bronchiolitis obliterans with organizing pneumonia and cold agglutinin disease associated with phenytoin hypersensitivity syndrome. *Chest* 1997;112:1697-9.
- 227 Faller M, Quoix E, Popin E, et al. Migratory pulmonary infiltrates in a patient treated with sotalol. *Eur Respir J* 1997;10:2159-62.
- 228 Gabazza EC, Taguchi O, Yamakami T, et al. Pulmonary infiltrates and skin pigmentation associated with sulfasalazine. *Am J Gastroenterol* 1992;87:1654-7.
- 229 Hamadeh MA, Atkinson J, Smith LJ. Sulfasalazine-induced pulmonary disease. *Chest* 1992;101:1033-7.

- 230 Williams T, Eidus L, Thomas P. Fibrosing alveolitis, bronchiolitis obliterans, and sulfasalazine therapy. *Chest* 1982; **81**:766-8.
- 231 Przepiorka D, Abu-Elmagd K, Huarding A, *et al.* Bronchiolitis obliterans organizing pneumonia in a BMT patient receiving FK506. *Bone Marrow Transplant* 1993; **11**:502
- 232 Alonso-Martinez JL, Elejalde-Guerra JI, Larrinaga-Linero D. Bronchiolitis obliterans-organizing pneumonia caused by ticlopidine. *Ann Intern Med* 1998; **129**:71-2.
- 233 Bense L, Wiman LG, Steiner E, *et al.* Pulmonary side effects after treatment with barbiturates. *Eur J Respir Dis* 1986; **69**:61-2.