

CLINICAL PRACTICE

Infective Endocarditis

Bruno Hoen, M.D., Ph.D., and Xavier Duval, M.D., Ph.D.

This Journal feature begins with a case vignette highlighting a common clinical problem. Evidence supporting various strategies is then presented, followed by a review of formal guidelines, when they exist. The article ends with the authors' clinical recommendations.

A 55-year-old man with a history of mitral regurgitation seeks care after an episode of transient weakness in his right arm and speech difficulties. He underwent dental scaling 1 month earlier. He notes recent intermittent fevers and weight loss. On cardiac examination, his regurgitation murmur appears to be unchanged. A transthoracic echocardiogram shows a mobile, 12-mm mitral-valve vegetation and grade 2 (mild) regurgitation. Magnetic resonance imaging of the brain reveals recent ischemic lesions. How should the patient be further evaluated and treated?

THE CLINICAL PROBLEM

Infective endocarditis has an estimated annual incidence of 3 to 9 cases per 100,000 persons in industrialized countries.¹⁻⁷ The male:female case ratio is more than 2:1. The highest rates are observed among patients with prosthetic valves, intracardiac devices, unrepaired cyanotic congenital heart diseases, or a history of infective endocarditis, although 50% of cases of infective endocarditis develop in patients with no known history of valve disease. Other risk factors include chronic rheumatic heart disease (which now accounts for <10% of cases in industrialized countries), age-related degenerative valvular lesions,^{1,2,5} hemodialysis, and coexisting conditions such as diabetes, human immunodeficiency virus infection, and intravenous drug use. More than one third of the cases of infective endocarditis in the United States in recent years were reported to be health care–associated (nosocomial or non-nosocomial).⁸ The clustering of several of these predisposing factors with age probably explains the increased incidence of infective endocarditis among persons 65 years of age or older (Fig. 1).⁷

MICROBIOLOGY

Streptococci and staphylococci account for 80% of cases of infective endocarditis, with proportions varying according to valve (native vs. prosthetic), source of infection, patient age, and coexisting conditions. Staphylococci are now the most frequently identified microorganisms in several types of infective endocarditis (Fig. 1; and Table 1 in the Supplementary Appendix, available with the full text of this article at NEJM.org),^{2,7,9} which results from the increased proportion of health care–associated cases of infective endocarditis. In parallel, the incidence of cases attributable to oral streptococci has decreased in industrialized countries.²

Cases of infective endocarditis in which a blood culture is negative (10% of cases) may reflect one of two situations: infective endocarditis in patients exposed to antibiotic agents before the diagnosis of infective endocarditis or infective endocarditis caused by fastidious microorganisms. In the latter case, serologic testing, valve or blood polymerase-chain-reaction (PCR) assay, and highly specialized microbiologic techniques lead to the identification of the pathogen in 60% of cases,¹⁰ with the most frequent microorganisms being bartonella species, brucella species,

From Service de Maladies Infectieuses et Tropicales, Centre Hospitalier Régional Universitaire, and Unité Mixte de Recherche 6249 Chrono-environnement, Centre National de la Recherche Scientifique, Université de Franche-Comté, Besançon (B.H.); Association pour l'Etude et la Prévention de l'Endocardite Infectieuse, Paris (B.H., X.D.); and INSERM Centre d'Investigation Clinique 007, Assistance Publique–Hôpitaux de Paris, Hôpital Universitaire Bichat, and INSERM Unité 738, Université Paris Diderot, Paris 7, Unité de Formation et de Recherche de Médecine–Bichat, Bichat (X.D.) — all in France. Address reprint requests to Dr. Hoen at Service de Maladies Infectieuses et Tropicales, CHRU de Besançon, 25030 Besançon CEDEX, France, or at bruno.hoen@univ-fcomte.fr.

Drs. Hoen and Duval contributed equally to this article.

N Engl J Med 2013;368:1425-33.

DOI: 10.1056/NEJMc1206782

Copyright © 2013 Massachusetts Medical Society.



An audio version of this article is available at NEJM.org

KEY CLINICAL POINTS

INFECTIVE ENDOCARDITIS

- Staphylococci and streptococci account for 80% of cases of infective endocarditis, with staphylococci currently the most common pathogens.
- Cerebral complications are the most frequent and most severe extracardiac complications. Vegetations that are large, mobile, or in the mitral position and infective endocarditis due to *Staphylococcus aureus* are associated with an increased risk of symptomatic embolism.
- Identifying the causative microorganism is central to diagnosis and appropriate treatment; two or three blood cultures should routinely be drawn before antibiotic therapy is initiated.
- When infective endocarditis is suspected, echocardiography should be performed as soon as possible.
- Indications for surgery include heart failure, uncontrolled infection, and prevention of embolic events.
- Treatment should involve a multidisciplinary team with expertise in cardiology, cardiac surgery, and infectious disease.
- Indications for antibiotic prophylaxis have been restricted to invasive dental procedures in patients with a prosthetic valve, a history of infective endocarditis, or unrepaired cyanotic congenital heart disease.

Coxiella burnetii (the agent causing Q fever), bacteria in the HACEK group (haemophilus species, *Aggregatibacter* [formerly *Actinobacillus*] *actinomycetemcomitans*, *Cardiobacterium hominis*, *Eikenella corrodens*, and *Kingella kingae*), and *Tropheryma whippelii*.^{6,10,11}

PATHOGENESIS

Normal valvular endothelium is naturally resistant to colonization by bacteria. In the conventional model of native-valve infectious endocarditis, infection results from the colonization of damaged valvular endothelium by circulating bacteria with specific adherence properties. Endothelial damage may result from so-called jet lesions due to turbulent blood flow or may be provoked by electrodes or catheters or by repeated intravenous injections of solid particles in intravenous-drug users. Chronic inflammation, as in chronic rheumatic heart disease and degenerative valvular lesions,¹² may also promote infective endocarditis. However, the conventional model may not accurately explain the pathogenesis of infective endocarditis due to intracellular microorganisms, such as *C. burnetii*, bartonella species, or *T. whippelii*, in which the exposure and immune response of the host may play a prominent role.¹³

CLASSIFICATION

Whereas infective endocarditis was previously classified according to its mode of presentation (acute, subacute, or chronic), it is now categorized according to underlying cardiac conditions, location, the presence of intracardiac devices, or the mode of acquisition. These classifications overlap, with some cases of infective endocarditis belonging to

more than one group. Table 1 in the Supplementary Appendix shows the distribution of cases among these categories and the corresponding microorganisms.

OUTCOMES

In contemporary population-based studies of infective endocarditis in industrialized countries, in-hospital mortality ranges from 15 to 22%,^{5,7} and 5-year mortality is approximately 40%.¹⁴ However, rates vary widely across subgroups of patients. For instance, in-hospital mortality is less than 10% among patients with right-sided lesions or oral streptococcal, left-sided, native-valve lesions, whereas it is 40% or more among patients with prosthetic-valve infective endocarditis due to *Staphylococcus aureus*. In a multivariate analysis assessing risk factors for death among patients with infective endocarditis, independent predictors included higher age, *S. aureus* infection, heart failure, cerebrovascular and embolic events, and health care-associated infective endocarditis.^{5,7}

STRATEGIES AND EVIDENCE

PRESENTATION AND DIAGNOSIS

The diagnosis of infective endocarditis is generally based on clinical, microbiologic, and echocardiographic findings. The Duke criteria (Table 1) have sensitivity and specificity of more than 80% and are the reference criteria for diagnosis.¹⁵ However, they should not replace clinical judgment for diagnosis in the individual patient, especially in the first stage of care.

Fever is common, occurring in 80% of cases.^{6,7} In large, contemporary case series, recognition of

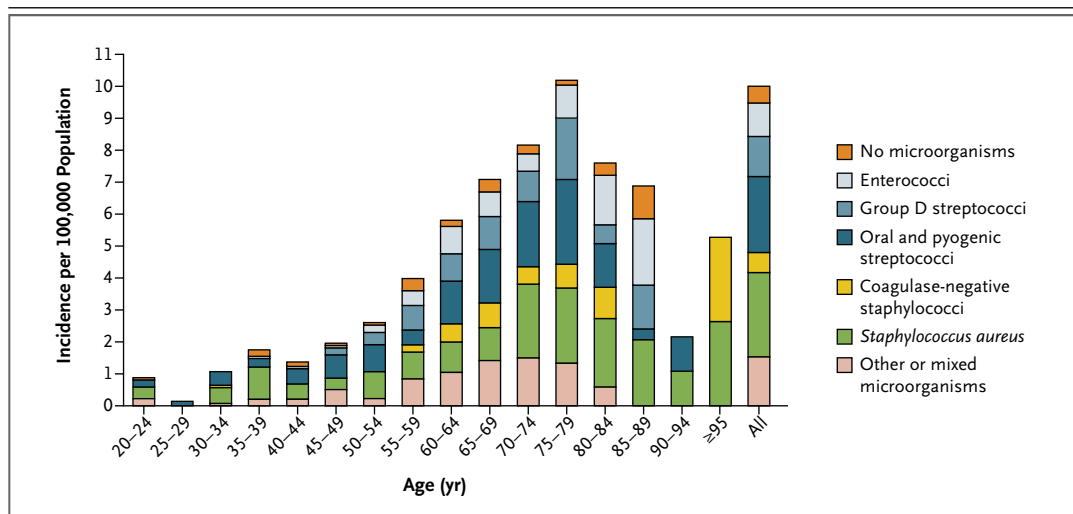


Figure 1. Incidence of Definite Infective Endocarditis, According to Age and Microorganism.

Streptococci and staphylococci account for 80% of cases of infective endocarditis, with proportions varying according to valve (native vs. prosthetic), source of infection, patient age, and coexisting conditions. The clustering of various predisposing factors with age probably explains the higher incidence of infective endocarditis in persons 65 years of age or older. Adapted from Selton-Suty et al.⁷

a new murmur and worsening of a known murmur are reported in 48% and 20% of cases, respectively. Other signs are less common: hematuria in 25% of cases, splenomegaly in 11%, splinter hemorrhages in 8%, Janeway's lesions in 5%, Roth's spots in 5%, and conjunctival hemorrhage in 5%. Sepsis, meningitis, unexplained heart failure, septic pulmonary emboli, stroke, acute peripheral arterial occlusion, and renal failure may also be presenting manifestations.¹⁶ Elevated inflammatory markers (erythrocyte sedimentation rate and C-reactive protein level) are observed in two thirds of cases, and leukocytosis and anemia in about half the cases.^{6,17}

Cerebral complications are the most severe extracardiac complications of infective endocarditis, as well as the most frequent (occurring in 15 to 20% of patients).^{18,19} They include ischemic and hemorrhagic stroke (preceding the diagnosis of infective endocarditis in 60% of patients^{20,21}), transient ischemic attack, silent cerebral embolism, mycotic aneurysm, brain abscess, and meningitis. Specific characteristics of vegetations (those that are large, mobile, and located in the mitral valve)²¹ and *S. aureus* infection^{21,22} have been associated with an increased risk of symptomatic embolic events. Systematic magnetic resonance imaging (MRI) of the brain may reveal cerebral abnormalities in up to 80% of patients, including embolic events (mostly asymptomatic) in 50%.²³

Mycotic aneurysms result from septic arterial embolism to the intraluminal space or vasa vasorum and spread of infection through the vessel wall. These aneurysms were reported in 5% of cases in older case series,²⁴ but they are now detected more frequently because of the wider use of imaging. Magnetic resonance angiography is the best confirmation test.²⁵

MICROBIOLOGIC DIAGNOSIS

Identifying the causative microorganism is central to making the diagnosis of infective endocarditis and guiding antimicrobial treatment. Blood cultures should be performed routinely before the administration of antibiotics. When three sets of blood cultures are performed, the pathogen is identified in about 90% of cases. Serologic tests for bartonella, *C. burnetii*, and brucella should be performed in patients with negative blood cultures who have risk factors for these infections. If the causative pathogen has not been identified by means of blood cultures and the patient requires valve surgery, gene amplification in cardiac-valve specimens, as well as immunostaining techniques, if available, may yield a microbiologic diagnosis.^{10,26,27}

DIAGNOSIS OF VALVULAR LESIONS

Transthoracic echocardiography is performed first and is better than transesophageal echocardiog-

Table 1. Duke Criteria for the Diagnosis of Infective Endocarditis.***Definite diagnosis**

Pathological criteria: microorganisms identified by culture or histologic examination of a vegetation, a vegetation that has embolized, or an intracardiac abscess specimen; or active endocarditis confirmed by histologic examination of vegetation or intracardiac abscess

Clinical criteria: two major, one major and three minor, or five minor criteria

Major clinical criteria

Blood culture positive for infective endocarditis

Microorganisms typically associated with infective endocarditis identified from two separate blood cultures: viridans streptococci, *Streptococcus bovis*, bacteria in the HACEK group, or *Staphylococcus aureus*; or community-acquired enterococci in the absence of a primary focus

Microorganisms consistent with infective endocarditis identified from persistently positive blood cultures: at least two positive cultures of blood samples drawn >12 hr apart, or positive results of all of three or a majority of four or more separate blood cultures (with first and last samples drawn at least 1 hr apart)

Single positive blood culture for *Coxiella burnetii* or IgG antibody titer for Q fever phase 1 antigen >1:800

Evidence of endocardial involvement

Echocardiogram positive for infective endocarditis: pendulum-like intracardiac mass on valve or supporting structures, in the path of regurgitant jets, or on implanted material in the absence of an alternative anatomical explanation; abscess; or new partial dehiscence of prosthetic valve†

New valvular regurgitation (worsening or changing of preexisting murmur not a sufficient criterion)

Minor clinical criteria

Predisposition to infective endocarditis, such as a predisposing heart condition, or intravenous drug use

Fever, defined as a temperature >38°C

Vascular phenomena, such as major arterial emboli, septic pulmonary infarcts, mycotic aneurysm, intracranial hemorrhage, conjunctival hemorrhage, and Janeway's lesions

Immunologic phenomena, such as glomerulonephritis, Osler's nodes, Roth's spots, and rheumatoid factor

Microbiologic evidence: positive blood culture but with no major clinical criterion met or serologic evidence of active infection with an organism consistent with infective endocarditis

Possible diagnosis

Clinical criteria (see above): one major criterion and one minor criterion or three minor criteria

Rejected diagnosis

Firmly established alternative diagnosis; resolution of infective endocarditis–like syndrome with antibiotic therapy for ≤4 days; no pathological evidence of infective endocarditis at surgery or autopsy, with antibiotic therapy for ≤4 days; or criteria for possible infective endocarditis not met

* Adapted from Li et al.¹⁵ HACEK denotes haemophilus species, *Aggregatibacter* (formerly *Actinobacillus*) *actinomycetem-comitans*, *Cardiobacterium hominis*, *Eikenella corrodens*, and *Kingella kingae*.

† Transesophageal echocardiography is recommended in patients with prosthetic valves and possible infective endocarditis according to clinical criteria or infective endocarditis complicated by paravalvular abscess; transthoracic echocardiography is recommended as the first test in other patients.

raphy for detecting abscesses in the anterior aortic valve in a patient with a prosthetic valve and for assessing the hemodynamic consequences of valvular dysfunction. Transesophageal echocardiography has higher sensitivity and specificity overall and is recommended when the results of transthoracic echocardiography are negative and there is a high clinical suspicion, poor imaging quality, and the presence of prosthetic valves or an intracardiac device, as well as in cases in which the transthoracic echocardiographic findings are suggestive of infective endocarditis but not definitive.

Combined transthoracic and transesophageal echocardiography shows vegetations (Fig. 2) in 90% of cases, valve regurgitation in 60%, paravalvular abscess in 20%,^{6,7} and infrequently, dehiscence of the prosthesis, pseudoaneurysms, and fistulas. In cases with initially negative findings on echocardiography, repeat examination should be performed if infective endocarditis continues to be suspected. Repeat transthoracic or transesophageal echocardiography is recommended if a new complication is suspected and when therapy has been completed.

TREATMENT

The treatment of patients with suspected or confirmed infective endocarditis should be provided by a multidisciplinary team with expertise in cardiology, cardiac surgery, and infectious disease.²⁸ Successful treatment is dependent on eradication of the causative agent, which requires prolonged bactericidal antibiotic treatment. Surgery may contribute to this goal by removing infected material and draining abscesses.

Antibiotic Treatment

Guidelines for appropriate antibiotic treatment of infective endocarditis are published by professional societies and updated regularly.²⁹⁻³¹ Table 2 in the Supplementary Appendix is adapted from the European Society of Cardiology guidelines and reviews antibiotic regimens recommended before an organism is identified and for most common causative bacteria.³⁰

For native-valve infective endocarditis due to common microorganisms, the duration of antibiotic treatment ranges from 2 weeks (for uncomplicated infective endocarditis due to fully penicillin-susceptible streptococci treated with a beta-lactam antibiotic combined with an aminoglycoside) to 6 weeks (for enterococcal infective endocarditis). For infective endocarditis involving a prosthetic valve, the duration of antibiotic therapy is usually 6 weeks, and regimens are basically the same as those for native-valve infective endocarditis, with the notable exception of staphylococcal prosthetic-valve infective endocarditis, for which the regimen should include both rifampin, whenever the strain is susceptible to this antibiotic, and gentamicin.

When valve replacement is performed during antibiotic treatment of native-valve infective endocarditis, the duration of antibiotic therapy should remain the same as the duration recommended for native-valve infective endocarditis and should not be switched to that recommended for prosthetic-valve infective endocarditis. In both native-valve and prosthetic-valve infective endocarditis, the duration of treatment should be calculated from the first day of appropriate antibiotic therapy, not from the day of surgery. After surgery, a new full course of treatment should be started only if valve cultures are positive.³²

Among aminoglycosides, only gentamicin has been fully evaluated for the treatment of infective endocarditis and should be used when the disease is caused by gram-positive cocci. Clinical

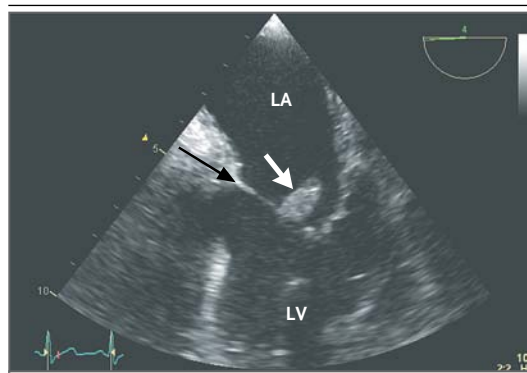


Figure 2. Transesophageal Echocardiogram Showing a Large Vegetation on a Native Aortic Valve.

A large vegetation (white arrow) can be seen near the mitral valve (black arrow). LA denotes left atrium, and LV left ventricle.

trials have shown that a 14-day course of gentamicin, given once daily instead of twice daily, in combination with ceftriaxone is effective for the treatment of uncomplicated cases of streptococcal infective endocarditis involving a native valve.^{33,34} Combination therapy with a beta-lactam antibiotic and an aminoglycoside should be used for prosthetic-valve infective endocarditis (Table 2 in the Supplementary Appendix).

In cases of enterococcal infective endocarditis, whenever the strain does not exhibit high-level resistance to gentamicin, that drug should be used in combination with an antibiotic agent that is active against the bacterial cell wall. Gentamicin is generally given for the full 6-week course of antibiotic treatment; however, in an observational study, the cure rate of enterococcal infective endocarditis was as high as 81%, with a median duration of aminoglycoside administration of 15 days. This suggests that shorter courses of aminoglycosides (2 to 3 weeks), which minimize the risk of renal toxicity, may be effective.³⁵ The question of whether gentamicin should be administered in divided daily doses continues to be debated; clinical data are lacking, and experimental data are conflicting. The combination of ampicillin (at a dose of 12 g per 24 hours) with ceftriaxone (at a dose of 2 g twice daily) may be effective in infective endocarditis due to *Enterococcus faecalis*, regardless of whether the strain is highly resistant to gentamicin³⁶ or not highly resistant.³⁷

Gentamicin is no longer recommended for staphylococcal infective endocarditis involving a native valve, because there is no documented clinical benefit and there is a risk of nephrotox-

icity.³⁸ In cases involving a prosthetic valve, however, a regimen that includes gentamicin for the first 2 weeks is recommended, especially in cases of methicillin-resistant *S. aureus* (MRSA) infection, to mitigate the risk of selection of rifampin-resistant escape mutants.

Daptomycin (at a dose of 6 mg per kilogram of body weight per day, given once daily) was approved by the Food and Drug Administration for adults with *S. aureus* bacteremia and right-sided infective endocarditis, on the basis of a randomized trial showing its noninferiority to standard therapy (vancomycin or an antistaphylococcal penicillin).³⁹ Observational studies have also shown the efficacy of daptomycin in patients with left-sided infective endocarditis⁴⁰ and in patients with infective endocarditis involving an implanted intracardiac device (with daptomycin used at a dose of 8 to 10 mg per kilogram per day).⁴¹ Daptomycin has been recommended as an alternative to vancomycin for the treatment of adults with infective endocarditis due to MRSA.⁴²

Surgical Treatment

The rate of early valve replacement or repair (i.e., surgery performed during the course of antibiotic treatment for infective endocarditis) has increased over the past three decades to approximately 50%.^{6,7} The main indications for early valve surgery are heart failure, uncontrolled infection, and prevention of embolic events (Table 2).³⁰ Observational studies assessing associations between the timing of surgery and outcomes have yielded inconsistent results.¹⁴

In a recent randomized trial involving 76 patients with severe left-sided infective endocarditis and a large vegetation but no indications for emergency surgery at the time of randomization, the incidence of the composite end point of in-hospital death or embolic events within the first 6 weeks after randomization was significantly lower among patients assigned to surgery within 48 hours after randomization than among those assigned to usual care (3% vs. 23%); the benefit was driven by the reduction in embolic events.⁴³ However, it is unclear whether these results should be generalized to support the routine use of early valve surgery, because the patients enrolled in this study were young (mean age, 47 years), with a low frequency of coexisting conditions and very low mortality (<5%).

After a cerebral embolic event, most patients

still have an indication for valve surgery. The decision to proceed with surgery must take into account the risk of further embolism and the risks associated with surgery. The incidence of stroke among patients receiving appropriate antimicrobial therapy decreases from 4.8 cases per 1000 patient-days in the first week of therapy to 1.7 per 1000 patient-days in the second week, with further decreases thereafter.²⁰ A history of embolic stroke or transient ischemic attack is not in itself a contraindication to surgery. Postoperative neurologic deterioration is infrequent after a silent cerebral embolism or a transient ischemic attack. After an ischemic stroke, the risk associated with surgery depends on the neurologic condition of the patient¹⁹; generally, surgery is performed if the patient does not have severe neurologic damage, as long as cerebral hemorrhage has been ruled out by means of cerebral imaging.³⁰

Anticoagulant and Antiplatelet Therapies

Observational data have suggested an increased risk of death from cerebral hemorrhage, with no reduction in the risk of embolic events, in patients with prosthetic-valve infective endocarditis due to *S. aureus* who were receiving treatment with oral anticoagulant agents.⁴⁴ European Society of Cardiology guidelines currently recommend that in patients already receiving oral anticoagulant therapy in whom infective endocarditis develops and is complicated by ischemic and nonhemorrhagic stroke, the oral anticoagulant agent be replaced with heparin for 2 weeks; however, the guidelines acknowledge the low level of evidence supporting this recommendation.³⁰

Antiplatelet agents are not recommended for patients with infective endocarditis. In a double-blind, placebo-controlled trial, patients with infective endocarditis who were randomly assigned to receive aspirin at a dose of 325 mg per day for 4 weeks had no significant decrease in the incidence of embolic events and had a nonsignificant increase in the rate of cerebral bleeding episodes.⁴⁵ Observational studies have yielded conflicting findings with respect to the associations of aspirin use before infective endocarditis with risks of death and embolic events.⁴⁶⁻⁴⁹ In the absence of bleeding, aspirin taken for other indications may not need to be discontinued.

Prophylaxis

In the past decade, on the basis of expert opinion, indications for antibiotic prophylaxis against infec-

Table 2. Indications for and Timing of Surgery in Patients with Left-Sided, Native-Valve Infective Endocarditis.*

Indication	Timing of Surgery†
Heart failure	
Aortic or mitral-valve infective endocarditis with severe acute regurgitation or obstruction causing refractory pulmonary edema or cardiogenic shock	Emergency
Aortic or mitral-valve infective endocarditis with fistula into a cardiac chamber or pericardium causing refractory pulmonary edema or cardiogenic shock	Emergency
Aortic or mitral-valve infective endocarditis with severe acute regurgitation or obstruction and persistent heart failure or signs of poor hemodynamic tolerance (early mitral-valve closure or pulmonary hypertension)	Urgent
Aortic or mitral-valve infective endocarditis with severe regurgitation and heart failure easily controlled with medical treatment	Elective
Uncontrolled infection	
Locally uncontrolled infection (abscess, false aneurysm, fistula, enlarging vegetation, or dehiscence of prosthetic valve)	Urgent
Persistent fever and positive blood cultures for >5–7 days	Urgent
Infection caused by fungi or multidrug-resistant organisms, such as <i>Pseudomonas aeruginosa</i> and other gram-negative bacilli	Elective
Prevention of embolism	
Aortic or mitral-valve infective endocarditis with large vegetations (>10 mm in length) after one or more embolic episodes, despite appropriate antibiotic therapy, especially during the first 2 weeks of therapy	Urgent
Aortic or mitral-valve infective endocarditis with large vegetations (>10 mm) and other predictors of complicated course (heart failure, persistent infection, or abscess)	Urgent
Isolated, very large vegetations (>15 mm); surgery may be preferred if a procedure preserving the native valve is feasible	Urgent

* Adapted from Habib et al.³⁰

† Emergency surgery was defined as surgery performed within 24 hours after the condition was identified, urgent surgery as that performed within a few days after the condition was identified, and elective surgery as that performed after at least 1 or 2 weeks of antibiotic therapy.

tive endocarditis have been restricted to patients who have a prosthetic valve, a history of infective endocarditis, or unrepaired cyanotic congenital heart disease and who are planning to undergo an invasive dental procedure; the recommended regimens are summarized in Table 3 in the Supplementary Appendix.^{30,50} In the United Kingdom, antibiotic prophylaxis against infective endocarditis is no longer recommended in any circumstances.⁵¹ To date, reports indicate no appreciable increase in the incidence of infective endocarditis due to viridans group streptococci since the guidelines were revised to recommend a restricted use of antibiotic prophylaxis.^{52,53} Good oral, dental, and skin hygiene are recommended to reduce risks.

AREAS OF UNCERTAINTY

The appropriate duration of antibiotic therapy, especially aminoglycosides, remains uncertain. Although a combination of oral ciprofloxacin and

rifampin was reported to be effective for *S. aureus* infective endocarditis in a study of intravenous-drug users,⁵⁴ oral therapy cannot currently be recommended for infective endocarditis.

Despite the recent randomized trial suggesting a benefit of early surgery,⁴³ the appropriate timing of surgery remains controversial. When surgery is performed within the first week of antibiotic treatment, there may be increased risks of relapse and prosthetic-valve dysfunction.⁵⁵

The usefulness of systematic brain imaging and the preferred treatment of patients with infective endocarditis and cerebral mycotic aneurysms are also uncertain. Because unruptured aneurysms may resolve with antibiotic therapy alone,²⁴ such patients should receive antibiotics, with serial angiography performed to document the resolution of the aneurysm. Endovascular treatment should be pursued only if the aneurysm is very large (e.g., >10 mm) or if it is not resolving or is enlarging despite treatment with antibiotics.²⁵

GUIDELINES

Guidelines addressing the prophylaxis and management of infective endocarditis have been published by professional societies in the United States and Europe.²⁹⁻³¹ The recommendations presented here are largely consistent with these guidelines.

CONCLUSIONS
AND RECOMMENDATIONS

The patient in the vignette has evidence of native mitral-valve infective endocarditis complicated by cerebral emboli. Antibiotic treatment should be started immediately after two to three blood cultures have been drawn. Pending culture results, an aminopenicillin with beta-lactam inhibitor (either ampicillin with sulbactam or amoxicillin with clavulanate potassium)^{29,30} should be given in combination with gentamicin. The recent cerebral embolic events and the large, mobile mitral-

valve vegetation seen on the echocardiogram are indications for urgent mitral-valve surgery, in the absence of contraindications. If blood cultures are still negative at the time of surgery, a sample of valve tissue should be obtained for culture, and a broad-range PCR assay should be performed to help identify the causative microorganism, with adaptation of the antibiotic regimen to the identified microorganism. The patient should be counseled concerning the prevention of recurrent infective endocarditis (oral and overall hygiene and appropriate use of antibiotic prophylaxis, given that he will now have both a history of infective endocarditis and a prosthetic valve).

Dr. Duval reports receiving grant support through his institution from Pfizer and travel expenses from Roche. No other potential conflict of interest relevant to this article was reported.

Disclosure forms provided by the authors are available with the full text of this article at NEJM.org.

We thank Dr. L. Kritharides and Dr. R.W. Sy for sharing data from the Australian population-based study on infective endocarditis.

REFERENCES

- Correa de Sa DD, Tleyjeh IM, Anavekar NS, et al. Epidemiological trends of infective endocarditis: a population-based study in Olmsted County, Minnesota. *Mayo Clin Proc* 2010;85:422-6. [Erratum, *Mayo Clin Proc* 2010;85:772.]
- Duval X, Delahaye F, Alla F, et al. Temporal trends in infective endocarditis in the context of prophylaxis guideline modifications: three successive population-based surveys. *J Am Coll Cardiol* 2012;59:1968-76.
- Fedeli U, Schievano E, Buonfrate D, Pellizzer G, Spolaore P. Increasing incidence and mortality of infective endocarditis: a population-based study through a record-linkage system. *BMC Infect Dis* 2011;11:48.
- Federspiel JJ, Stearns SC, Peppercorn AF, Chu VH, Fowler VG Jr. Increasing US rates of endocarditis with *Staphylococcus aureus*: 1999-2008. *Arch Intern Med* 2012;172:363-5.
- Sy RW, Kritharides L. Health care exposure and age in infective endocarditis: results of a contemporary population-based profile of 1536 patients in Australia. *Eur Heart J* 2010;31:1890-7.
- Murdoch DR, Corey GR, Hoen B, et al. Clinical presentation, etiology, and outcome of infective endocarditis in the 21st century: the International Collaboration on Endocarditis-Prospective Cohort Study. *Arch Intern Med* 2009;169:463-73.
- Selton-Suty C, Célard M, Le Moing V, et al. Preeminence of *Staphylococcus aureus* in infective endocarditis: a 1-year population-based survey. *Clin Infect Dis* 2012;54:1230-9.
- Benito N, Miró JM, de Lazzari E, et al. Health care-associated native valve endocarditis: importance of non-nosocomial acquisition. *Ann Intern Med* 2009;150:586-94.
- Tleyjeh IM, Abdel-Latif A, Rahbi H, et al. A systematic review of population-based studies of infective endocarditis. *Chest* 2007;132:1025-35.
- Fournier PE, Thuny F, Richet H, et al. Comprehensive diagnostic strategy for blood culture-negative endocarditis: a prospective study of 819 new cases. *Clin Infect Dis* 2010;51:131-40.
- Houpikian P, Raoult D. Blood culture-negative endocarditis in a reference center: etiologic diagnosis of 348 cases. *Medicine (Baltimore)* 2005;84:162-73.
- Stehbens WE, Delahunf B, Zuccollo JM. The histopathology of endocardial sclerosis. *Cardiovasc Pathol* 2000;9:161-73.
- Brouqui P, Raoult D. Endocarditis due to rare and fastidious bacteria. *Clin Microbiol Rev* 2001;14:177-207.
- Bannay A, Hoen B, Duval X, et al. The impact of valve surgery on short- and long-term mortality in left-sided infective endocarditis: do differences in methodological approaches explain previous conflicting results? *Eur Heart J* 2011;32:2003-15.
- Li JS, Sexton DJ, Mick N, et al. Proposed modifications to the Duke criteria for the diagnosis of infective endocarditis. *Clin Infect Dis* 2000;30:633-8.
- Richet H, Casalta JP, Thuny F, et al. Development and assessment of a new early scoring system using non-specific clinical signs and biological results to identify children and adult patients with a high probability of infective endocarditis on admission. *J Antimicrob Chemother* 2008;62:1434-40.
- Crawford MH, Durack DT. Clinical presentation of infective endocarditis. *Cardiol Clin* 2003;21:159-66.
- Thuny F, Avierinos JF, Tribouilloy C, et al. Impact of cerebrovascular complications on mortality and neurologic outcome during infective endocarditis: a prospective multicentre study. *Eur Heart J* 2007;28:1155-61.
- Sonneville R, Mirabel M, Hajage D, et al. Neurologic complications and outcomes of infective endocarditis in critically ill patients: the ENDOcardite en REAnimation prospective multicenter study. *Crit Care Med* 2011;39:1474-81.
- Dickerman SA, Abrutyn E, Barsic B, et al. The relationship between the initiation of antimicrobial therapy and the incidence of stroke in infective endocarditis: an analysis from the ICE Prospective Cohort Study (ICE-PCS). *Am Heart J* 2007;154:1086-94.
- Thuny F, Di Salvo G, Belliard O, et al. Risk of embolism and death in infective endocarditis: prognostic value of echocardiography: a prospective multicenter study. *Circulation* 2005;112(9):e125. [Erratum, *Circulation* 2005;112(9):e125.]
- Di Salvo G, Habib G, Pergola V, et al. Echocardiography predicts embolic events

- in infective endocarditis. *J Am Coll Cardiol* 2001;37:1069-76.
23. Duval X, Lung B, Klein I, et al. Effect of early cerebral magnetic resonance imaging on clinical decisions in infective endocarditis: a prospective study. *Ann Intern Med* 2010;152:497-504.
 24. Corr P, Wright M, Handler LC. Endocarditis-related cerebral aneurysms: radiologic changes with treatment. *AJNR Am J Neuroradiol* 1995;16:745-8.
 25. Peters PJ, Harrison T, Lennox JL. A dangerous dilemma: management of infectious intracranial aneurysms complicating endocarditis. *Lancet Infect Dis* 2006;6:742-8.
 26. Greub G, Lepidi H, Rovey C, et al. Diagnosis of infectious endocarditis in patients undergoing valve surgery. *Am J Med* 2005;118:230-8.
 27. Lepidi H, Coulibaly B, Casalta JP, Raoult D. Autoimmunohistochemistry: a new method for the histologic diagnosis of infective endocarditis. *J Infect Dis* 2006;193:1711-7.
 28. Botelho-Nevers E, Thuny F, Casalta JP, et al. Dramatic reduction in infective endocarditis-related mortality with a management-based approach. *Arch Intern Med* 2009;169:1290-8.
 29. Baddour LM, Wilson WR, Bayer AS, et al. Infective endocarditis: diagnosis, antimicrobial therapy, and management of complications: a statement for healthcare professionals from the Committee on Rheumatic Fever, Endocarditis, and Kawasaki Disease, Council on Cardiovascular Disease in the Young, and the Councils on Clinical Cardiology, Stroke, and Cardiovascular Surgery and Anesthesia, American Heart Association: endorsed by the Infectious Diseases Society of America. *Circulation* 2005;111(23):e394-e434. [Errata, *Circulation* 2005;112:2373, 2007;115(15):e408, 116(21):e547, 2008; 118(12):e497.]
 30. Habib G, Hoen B, Tornos P, et al. Guidelines on the prevention, diagnosis, and treatment of infective endocarditis (new version 2009): the Task Force on the Prevention, Diagnosis, and Treatment of Infective Endocarditis of the European Society of Cardiology (ESC): endorsed by the European Society of Clinical Microbiology and Infectious Diseases (ESCMID) and the International Society of Chemotherapy (ISC) for Infection and Cancer. *Eur Heart J* 2009;30:2369-413.
 31. Gould FK, Denning DW, Elliott TS, et al. Guidelines for the diagnosis and antibiotic treatment of endocarditis in adults: a report of the Working Party of the British Society for Antimicrobial Chemotherapy. *J Antimicrob Chemother* 2012;67:269-89. [Erratum, *J Antimicrob Chemother* 2012;67:1304.]
 32. Morris AJ, Drinković D, Pottumarthy S, MacCulloch D, Kerr AR, West T. Bacteriological outcome after valve surgery for active infective endocarditis: implications for duration of treatment after surgery. *Clin Infect Dis* 2005;41:187-94.
 33. Francioli P, Ruch W, Stambouliau D. Treatment of streptococcal endocarditis with a single daily dose of ceftriaxone and netilmicin for 14 days: a prospective multicenter study. *Clin Infect Dis* 1995;21:1406-10.
 34. Sexton DJ, Tenenbaum MJ, Wilson WR, et al. Ceftriaxone once daily for four weeks compared with ceftriaxone plus gentamicin once daily for two weeks for treatment of endocarditis due to penicillin-susceptible streptococci. *Clin Infect Dis* 1998;27:1470-4.
 35. Olaison L, Schadewitz K. Enterococcal endocarditis in Sweden, 1995-1999: can shorter therapy with aminoglycosides be used? *Clin Infect Dis* 2002;34:159-66.
 36. Gavaldà J, Len O, Miró JM, et al. Treatment of *Enterococcus faecalis* endocarditis with ampicillin plus ceftriaxone. *Ann Intern Med* 2007;146:574-9.
 37. Fernández-Hidalgo N, Almirante B, Gavaldà J, et al. Ampicillin plus ceftriaxone is as effective as ampicillin plus gentamicin for treating *Enterococcus faecalis* infective endocarditis. *Clin Infect Dis* 2013 February 25 (Epub ahead of print).
 38. Cosgrove SE, Vigliani GA, Fowler VG Jr, et al. Initial low-dose gentamicin for *Staphylococcus aureus* bacteremia and endocarditis is nephrotoxic. *Clin Infect Dis* 2009;48:713-21.
 39. Fowler VG Jr, Boucher HW, Corey GR, et al. Daptomycin versus standard therapy for bacteremia and endocarditis caused by *Staphylococcus aureus*. *N Engl J Med* 2006;355:653-65.
 40. Das I, Saluja T, Steeds R. Use of daptomycin in complicated cases of infective endocarditis. *Eur J Clin Microbiol Infect Dis* 2011;30:807-12.
 41. Durante-Mangoni E, Casillo R, Bernardo M, et al. High-dose daptomycin for cardiac implantable electronic device-related infective endocarditis. *Clin Infect Dis* 2012;54:347-54.
 42. Liu C, Bayer A, Cosgrove SE, et al. Clinical practice guidelines by the Infectious Diseases Society of America for the treatment of methicillin-resistant *Staphylococcus aureus* infections in adults and children: executive summary. *Clin Infect Dis* 2011;52:285-92.
 43. Kang D-H, Kim Y-J, Kim S-H, et al. Early surgery versus conventional treatment for infective endocarditis. *N Engl J Med* 2012;366:2466-73.
 44. Tornos P, Almirante B, Mirabet S, Permanyer G, Pahissa A, Soler-Soler J. Infective endocarditis due to *Staphylococcus aureus*: deleterious effect of anticoagulant therapy. *Arch Intern Med* 1999;159:473-5.
 45. Chan KL, Dumesnil JG, Cujec B, et al. A randomized trial of aspirin on the risk of embolic events in patients with infective endocarditis. *J Am Coll Cardiol* 2003;42:775-80.
 46. Chan KL, Tam J, Dumesnil JG, et al. Effect of long-term aspirin use on embolic events in infective endocarditis. *Clin Infect Dis* 2008;46:37-41.
 47. Pepin J, Tremblay V, Bechar D, et al. Chronic antiplatelet therapy and mortality among patients with infective endocarditis. *Clin Microbiol Infect* 2009;15:193-9.
 48. Snygg-Martín U, Rasmussen RV, Hasager C, Bruun NE, Andersson R, Olaison L. The relationship between cerebrovascular complications and previously established use of antiplatelet therapy in left-sided infective endocarditis. *Scand J Infect Dis* 2011;43:899-904.
 49. Anavekar NS, Tleyjeh IM, Anavekar NS, et al. Impact of prior antiplatelet therapy on risk of embolism in infective endocarditis. *Clin Infect Dis* 2007;44:1180-6. [Erratum, *Clin Infect Dis* 2007;44:1398.]
 50. Wilson W, Taubert KA, Gewitz M, et al. Prevention of infective endocarditis: guidelines from the American Heart Association: a guideline from the American Heart Association Rheumatic Fever, Endocarditis, and Kawasaki Disease Committee, Council on Cardiovascular Disease in the Young, and the Council on Clinical Cardiology, Council on Cardiovascular Surgery and Anesthesia, and the Quality of Care and Outcomes Research Interdisciplinary Working Group. *Circulation* 2007;116(15):e376-e377. [Erratum, *Circulation* 2007;116(15):e376-e377.]
 51. Richey R, Wray D, Stokes T. Prophylaxis against infective endocarditis: summary of NICE guidance. *BMJ* 2008;336:770-1.
 52. Thornhill MH, Dayer MJ, Forde JM, et al. Impact of the NICE guideline recommending cessation of antibiotic prophylaxis for prevention of infective endocarditis: before and after study. *BMJ* 2011;342:d2392.
 53. Desimone DC, Tleyjeh IM, Correa de Sa DD, et al. Incidence of infective endocarditis caused by viridans group streptococci before and after publication of the 2007 American Heart Association's endocarditis prevention guidelines. *Circulation* 2012;126:60-4.
 54. Heldman AW, Hartert TV, Ray SC, et al. Oral antibiotic treatment of right-sided staphylococcal endocarditis in injection drug users: prospective randomized comparison with parenteral therapy. *Am J Med* 1996;101:68-76.
 55. Thuny F, Beurtheret S, Mancini J, et al. The timing of surgery influences mortality and morbidity in adults with severe complicated infective endocarditis: a propensity analysis. *Eur Heart J* 2011;32:2027-33.

Copyright © 2013 Massachusetts Medical Society.