

[DONATE](#) [HELP](#) [CONTACT AHA](#) [SIGN IN](#) [HOME](#)



# Circulation

Search:

Go

[Advanced Search](#)

[Circulation Home](#) ▪ [Subscriptions](#) ▪ [Archives](#) ▪ [Feedback](#) ▪ [Authors](#) ▪ [Help](#) ▪ [AHA Journals Home](#)

**Circulation.**      « [Previous Article](#) | [Table of Contents](#) | [Next Article](#) »  
**1996;94:2662-2666**

(*Circulation*. 1996;94:2662-2666.)  
 © 1996 American Heart Association, Inc.

## Articles

# How Big Are Coronary Atherosclerotic Plaques That Rupture?

Michael C. Fishbein, MD; Robert J. Siegel, MD

the Department of Pathology and Laboratory Medicine (M.C.F.) and Division of Cardiology (R.J.S.), Cedars-Sinai Medical Center/University of California, Los Angeles, School of Medicine.

**Key Words:** atherosclerosis • plaque • arteries • thrombosis

### This Article

- ▶ [Extract](#) **FREE**
- ▶ [Alert me when this article is cited](#)
- ▶ [Alert me if a correction is posted](#)
- ▶ [Citation Map](#)

### Services

- ▶ [Email this article to a friend](#)
- ▶ [Similar articles in this journal](#)
- ▶ [Similar articles in PubMed](#)
- ▶ [Alert me to new issues of the journal](#)
- ▶ [Download to citation manager](#)
- ▶ [Request Permissions](#)

### Citing Articles

- ▶ [Citing Articles via HighWire](#)
- ▶ [Citing Articles via Google Scholar](#)

### Google Scholar

- ▶ [Articles by Fishbein, M. C.](#)
- ▶ [Articles by Siegel, R. J.](#)
- ▶ [Search for Related Content](#)

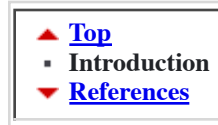### PubMed

- ▶ [PubMed Citation](#)
- ▶ [Articles by Fishbein, M. C.](#)
- ▶ [Articles by Siegel, R. J.](#)
- ▶ [PubMed/NCBI databases](#)  
**Medline Plus Health Information**

## ▶ Introduction

▪ [Coronary Artery Disease](#)

Plaque erosions (superficial intimal injury) and fissures (tears of variable depth) with overlying microscopic mural thrombosis are



common abnormalities of the intimal surface of coronary atherosclerotic plaques. Davies et al<sup>1</sup> found small plaque fissures in as many as 17% of patients who died of noncardiac causes. If no overlying obstructive luminal thrombus develops, these small plaque defects will cause no clinical events. Conversely, plaque rupture (disruption of the fibrous cap) that is complicated by occlusive thrombosis is clinically significant and is the underlying lesion in the majority of acute fatal coronary events: acute myocardial infarction and sudden death.<sup>2 3 4 5 6</sup>

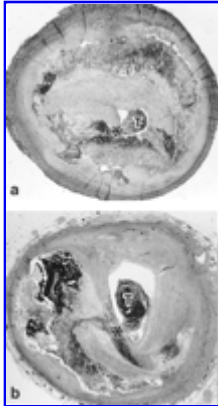Angiographic studies of coronary arteries before and after nonfatal myocardial infarction have frequently shown that at the site of the complete occlusion, the preexisting, underlying culprit lesion does not usually cause hemodynamically significant stenosis<sup>7 8 9 10 11 12 13 14</sup> (Table 1<sup>+</sup>). Several published studies have reported that nearly 50% of these lesions are at sites with <50% luminal diameter narrowing. Fewer than 20% of acute complete occlusions occur in lesions with antecedent angiographic diameter narrowing of >75%. Thus, it has recently become generally accepted that most plaque ruptures resulting in myocardial infarction occur in plaques that narrow the lumen diameter by <50%. This consensus has been expanded into the notion that nonstenotic, hemodynamically insignificant plaques may rupture, precipitating occlusive thrombosis, myocardial infarction, and/or death. This is a disheartening concept. It suggests that virtually all of the mature men and women of the industrialized world have a constant and unpredictable risk of a catastrophic coronary event.

**View this table:** [Table 1. Severity of Coronary Angiographic Lesions Before Myocardial Infarction](#)  
[\[in this window\]](#)  
[\[in a new window\]](#)

Conversely, histopathological studies from patients with fatal coronary events have consistently shown that at the sites of plaque rupture with superimposed occlusive thrombosis, the underlying lesion is "severe" (Table 2<sup>+</sup>, Fig 1<sup>+</sup>). Studies in which planimetry was used to measure the plaque determined that the plaque occupied, on average, ≈90% of the cross-sectional area (68% diameter reduction).<sup>2 3 4 5</sup> These studies did not use pressure fixation of the coronary arteries.

**View this table:** [Table 2. Severity of Underlying Stenosis by Atherosclerotic Plaque at Sites](#)

[\[in this window\]](#) of Occlusive Thrombosis\* (Cross-sectional Area Narrowing)  
[\[in a new window\]](#)



**Figure 1.** Two typical examples of acute coronary occlusions in fatal ischemic events. Note that with respect to cross-sectional area measurement of stenosis (a, 97%; b, 90%), there is severe underlying atherosclerosis at the site of plaque rupture and thrombosis (asterisk indicates rupture site; T, thrombus) (hematoxylin-eosin; magnification x17).

**View larger version**  
 (108K):  
[\[in this window\]](#)  
[\[in a new window\]](#)

How does one reconcile two sets of consistent, reliable data that appear to be so different? Usually, when there is such consistent difference in opinion, it means that either everyone is wrong or everyone is partially correct. In this case, comparing angiography and pathology, the divergence arises because the two techniques are not measuring the same thing: the proverbial apples and oranges.

Both angiographic (Table 3<sup>☒</sup>) and pathological (Table 4<sup>☒</sup>) examinations are subject to limitations that can result in erroneous results that can lead to either overestimation or underestimation of the degree of luminal narrowing by plaque.<sup>15 16 17 18 19 20 21 22 23 24 25</sup> Although these are important, it is our opinion that the most important factors responsible for the long-standing discordance between angiographic and pathological studies do not relate to poor technique or inaccurate interpretation but rather to two biological variables that make it illogical to even attempt to compare these two techniques.

**View this table:** **Table 3.** Factors Contributing to Coronary Arteriographic Lesion  
[\[in this window\]](#) Underestimation and Overestimation  
[\[in a new window\]](#)

**View this table:** **Table 4.** Factors Contributing to Inaccurate Pathological Quantification of [\[in this window\]](#) Coronary Atherosclerosis [\[in a new window\]](#)

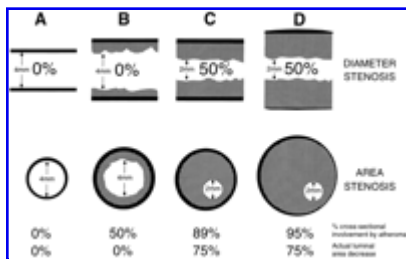
The two factors most important in understanding angiographic/pathological discordance are (1) the diffuseness of coronary atherosclerosis and (2) vascular remodeling associated with the progression of atherosclerosis.

The diffuse nature of coronary atherosclerosis is well known to pathologists,<sup>26 27 28 29 30</sup> angiographers,<sup>31</sup> and more recently, coronary ultrasonographers,<sup>32 33</sup> yet it seems to be ignored during standard evaluation of angiograms. In individuals with atherosclerotic coronary artery disease, it is virtually impossible to find a segment of the proximal coronary tree that is free of involvement by some degree of atherosclerosis. Thus, the concept of a focal stenosis due to a "plaque" is misleading. The observed plaque is not a discrete lesion but rather just a more severely involved region of a diffuse, widespread process.

The importance of vascular remodeling, elucidated primarily by the work of Glagov and associates<sup>34</sup> and others,<sup>35 36 37</sup> has only recently begun to be appreciated. This occurrence, now often called the Glagov phenomenon, consists of a progressive, compensatory increase in arterial cross-sectional area as atherosclerotic plaques enlarge. In effect, as the plaque grows, the lumen size remains the same. Thus, lumen size may remain normal despite occupation of  $\approx 40\%$  of the new arterial cross section by plaques. According to the Glagov concept, it is only when plaques enlarge further that the lumen size becomes compromised.

How then do the diffuseness of coronary atherosclerosis and vascular remodeling affect the angiographic and pathological quantification of coronary atherosclerosis? As shown in Fig 2<sup>+</sup>, the degree of stenosis determined angiographically depends on a comparison of lumen diameter at the site of a stenosis with an adjacent site thought to be normal. Because there are no normal sites adjacent to stenotic regions in atherosclerotic coronary arteries, angiography will actually be comparing a severe stenosis with a mild or moderate stenosis and thus will underestimate the volume of disease at the site of stenosis, as shown recently by Mann and Davies.<sup>38</sup> Because of compensatory enlargement, a segment of vessel with  $\leq 40\%$  involvement of the cross-sectional area by plaque may still have a lumen of normal size and shape. Therefore, by the time angiography detects a lesion,  $>40\%$  of the arterial cross section may be involved by plaque. Thus, angiography may be fairly

accurate in determining lumen size, but it will not detect the "volume" of atherosclerosis present. If the adjacent segment has some mild luminal narrowing, the amount of arterial luminal narrowing compared with a totally normal artery will also be underestimated.



**View larger version** (41K):

[\[in this window\]](#)

[\[in a new window\]](#)

**Figure 2.** Top row, Angiographic views. Bottom row, Pathological views. Column A, Normal artery. Column B, Artery with "moderate" atherosclerosis. Because of remodeling, with enlargement of the vessel, the angiographer sees a normal lumen. A pathologist viewing the same artery would see the same lumen, but 50% of the cross-sectional area would be occupied by plaque. Since the pathologist has no way of knowing that this lumen is still of normal size, he or she would conclude that this artery has a 50% cross-sectional area narrowing. Column C, More involved artery. The angiographer sees that the lumen is 50% less in diameter than the adjacent "normal" (B) segment. This would translate into a 75% cross-sectional area narrowing, but the angiographer might conclude that this is mild or moderate disease. The pathologist sees the 2-mm lumen but a larger plaque and measures the stenosis as an 89% narrowing. Column D, Same situation but with even more remodeling present. The angiographer still sees a 50% diameter narrowing, even though the plaque is much larger than in column C, and would still conclude that this is not severe disease. Because of the greater enlargement of the artery, the pathologist now measures the stenosis as a 95% cross-sectional narrowing, even though the lumen size is actually the same as in column C. The pathologist is left with no other explanation than that the angiographer has grossly underestimated the degree of stenosis in this patient's coronary artery.

Conversely, pathological evaluation, as shown in Fig 2<sup>+</sup>, will correctly identify the percentage of cross-sectional area occupied by plaque. The pathologist may see a plaque that constitutes, for example, 50% of the cross-sectional area. However, because of the Glagov phenomenon, the artery may have enlarged 50% in cross-sectional area. Thus, the lumen observed may actually still be the same size as the original, normal lumen. Since the pathologist does not know the original cross-sectional area of the artery or the amount of compensatory enlargement of the artery from evaluation of a single cross section of the artery at a site of stenosis, the degree of luminal narrowing of that segment cannot be determined. Because the pathologist determines the degree of stenosis by dividing

the lumen area by the total area, the degree of stenosis will be overestimated.

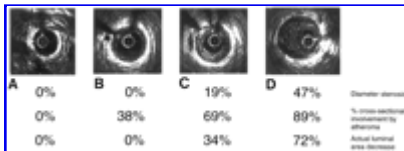
Thus, the angiographer determines the degree of stenosis by comparing lumens, assuming that one is normal, whereas the pathologist determines the degree of stenosis by comparing lumen to total plaque area. The angiographer uses a denominator that is too small, thereby underestimating the degree of stenosis. The pathologist uses a denominator that is too large, thereby overestimating the degree of stenosis. The latter sees the altered donut and the former sees only the hole, and both are attempting to relate their findings to the unseen pristine ring-shaped cake.

Furthermore, in studies reporting progression of insignificant lesions to total thrombotic occlusions, the mean interval between angiography and acute myocardial infarction is 2.5 years, with the interval as long as 12 or 18 years in some studies.<sup>7 8 9 10 11 12 13 14</sup> These considerable time intervals could allow for growth of "small" lesions before acute occlusion. Studies such as those by Moise et al<sup>14</sup> and Ellis et al<sup>39</sup> have shown that the relative risk of developing an acute myocardial infarction in the territory supplied by an artery with a <50% angiographic stenosis is actually quite low. The reported high frequency of acute occlusions in such regions may be at least in part related to the fact that the vast majority of the coronary luminal surface area contains lesions that are relatively mild and only a small percentage of the arterial tree is involved by more severe lesions. Thus, on a statistical basis, even if a region were at low risk for an acute event, if the majority of the arterial tree were composed of such regions, they might appear to be overrepresented in terms of degree of risk of occlusion.

Wherein lies the truth? An accurate determination of the degree of atherosclerosis depends on knowledge of the lumen and plaque area at the site of stenosis and the lumen area at an adjacent normal site. Then, one could determine the degree of luminal narrowing and also the amount of plaque present at any given segment.

Intravascular ultrasound (IVUS) has the potential to provide all of this information (Fig 3<sup>40</sup>). IVUS allows quantitative in vivo assessment of the arterial lumen and wall size and shape. It permits delineation of the intima, media, and adventitia and the presence of calcification, lipid pools, and fibrous regions. We used IVUS to study remodeling in coronary arteries with an angiographic diameter stenosis of >70%.<sup>40</sup> We compared the stenosis site with a proximal reference site that had <25% diameter narrowing by angiography and <50% cross-sectional area stenosis by IVUS. Compensatory enlargement was defined as being present when the total coronary arterial cross-sectional area at the stenotic site was greater than that at the proximal nonstenotic site. We documented that the majority of stenotic lesions had compensatory enlargement and thus exhibited remodeling. Note, however, that in 26% of arteries there was "inadequate" remodeling in that the total cross-sectional area at the stenotic site was less than that in both the proximal and distal reference sites. Fig 3<sup>40</sup> shows IVUS images that provide in vivo verification of the remodeling phenomenon

depicted in Fig 2<sup>4</sup>. Unfortunately, vascular remodeling is variable and inconsistent. This is not a trivial finding, because it indicates that clinically significant coronary arterial narrowing by atherosclerosis may be a function of not only the amount of atherosclerosis but also the degree of remodeling present.<sup>41</sup>



View larger version (34K):

[\[in this window\]](#)

[\[in a new window\]](#)

**Figure 3.** Intravascular ultrasound demonstration of coronary remodeling with atherosclerosis. A, Cross-sectional image of a normal proximal segment. B, Mild concentric lesion with 38% of the area bounded by the media involved by plaque. The lumen is actually larger than the normal segment shown in A. C, Concentric plaque. Because of remodeling, compared with the normal segment shown in A, for example, there is only a 34% reduction in luminal area despite a lesion occupying 69% of the cross-sectional area bounded by the media. D, Larger, eccentric plaque with even greater cross-sectional area involvement by atherosclerosis (89%). Because the entire vessel is larger, the actual decrease in luminal area is only 68%. Note that despite the considerable plaque present, diameter stenosis as would be determined angiographically would be considered mild: 19% in C and 47% in D (all percentages determined by manual planimetry).

What do the concepts discussed here indicate regarding the size of plaques that rupture with superimposed occlusive thrombus? Fig 1<sup>4</sup> shows typical examples of two such plaques. According to angiographic studies, we are to assume that in life, before rupture, these plaques were at sites with  $\approx$  50% diameter (75% area) stenoses. By planimetry, the cross-sectional area narrowings are 97% and 90%. These are typical findings at sites of plaque rupture.<sup>5</sup> We are aware that the current consensus is that the propensity for plaques to rupture is independent of plaque size; however, in our opinion, the hypothesis that small atherosclerotic plaques are the most likely to rupture, with resulting occlusive thrombosis, is unproven. Furthermore, if this occurs at all, it is a rare event. It is not small but rather large plaques, which may not be producing significant stenosis, that undergo rupture with acute occlusive thrombosis, resulting in myocardial infarction and other ischemic events. Understanding of the angiographic, pathological, and ultrasonic images of atherosclerotic coronary arteries and awareness of their limitations should lead to a better understanding of the biology of coronary atherosclerosis and plaque rupture.

## ► Footnotes

Reprint requests to Michael C. Fishbein, MD, Department of Pathology and Laboratory Medicine, Room 8732, Cedars-Sinai Medical Center, 8700 Beverly Blvd, Los Angeles, CA 90048. E-mail fishbein@csmc.edu.

## ▶ **References**

1. Davies MJ, Bland MJ, Hangartner WR, Angelini A, Thomas AC. Factors influencing the presence or absence of acute coronary thrombi in sudden ischemic death. *Eur Heart J*. 1989;10:203-208. [[Abstract/Free Full Text](#)]
2. Horie T, Sekiguchi M, Hirokawa K. Coronary thrombosis in pathogenesis of acute myocardial infarction: histopathologic study of coronary arteries in 108 necropsied cases using serial section. *Br Heart J*. 1978;40:153-161. [[Abstract/Free Full Text](#)]
3. Falk E. Plaque rupture with severe pre-existing stenosis precipitating coronary thrombosis: characteristics of coronary atherosclerotic plaques underlying fatal occlusive thrombi. *Br Heart J*. 1983;50:127-134. [[Abstract/Free Full Text](#)]
4. Davies MJ, Thomas A. Thrombosis and acute coronary artery lesions in sudden cardiac ischemic death. *N Engl J Med*. 1984;310:1137-1140. [[Abstract](#)]
5. Qiao J-H, Fishbein MC. The severity of coronary atherosclerosis at sites of plaque rupture with occlusive thrombosis. *J Am Coll Cardiol*. 1991;17:1138-1142. [[Abstract](#)]
6. Richardson PD, Davies MJ, Born GVR. Influence of plaque configuration and stress distribution on fissuring of coronary atherosclerotic plaques. *Lancet*. 1989;2:941-944. [[Medline](#)] [[Order article via Infotrieve](#)]
7. Ambrose JA, Winters SL, Arora R, Eng A, Riccio A, Gorlin R, Fuster V. Angiographic evolution of coronary artery morphology in unstable angina. *J Am Coll Cardiol*. 1986;7:472-478. [[Abstract](#)]
8. Ambrose JA, Tannenbaum MA, Alexopoulos D, Hjerndahl-Monsen CE, Leavy J, Weiss M, Borricco S, Gorlin R, Fuster V. Angiographic progression of coronary artery disease and the development of myocardial infarction. *J Am Coll Cardiol*. 1988;12:56-62. [[Abstract](#)]
9. Hackett D, Verwilghen J, Davies G, Maseri A. Coronary stenoses before and after myocardial infarction. *Am J Cardiol*. 1989;63:1517-1518. [[Medline](#)] [[Order article via Infotrieve](#)]
10. Little WC, Constantinescu M, Applegate RJ, Kutcher MA, Burrows MT, Kahl FR, Santamore WP. Can coronary angiography predict the site of a subsequent myocardial infarction in patients with mild to moderate coronary artery disease? *Circulation*. 1988;78:1157-1166. [[Abstract/Free Full Text](#)]
11. Little WC, Downes TR, Applegate RJ. The underlying coronary lesion in myocardial infarction: implications for coronary angiography. *Clin Cardiol*. 1991;14:868-874. [[Medline](#)] [[Order article via](#)

<a href="#">▲ Top</a>
<a href="#">▲ Introduction</a>
▪ <a href="#">References</a>



[Infotrieve](#)

12. Giroud D, Li JM, Urban P, Meier B, Rutishauser W. Relation of the site of acute myocardial infarction to the most severe coronary arterial stenosis at prior angiography. *Am J Cardiol.* 1992;69:729-732. [\[Medline\]](#) [\[Order article via Infotrieve\]](#)
13. Webster MWI, Chesebro JH, Smith HC, Frye RL, Holmes DR, Reeder GS, Bresnahan DR, Nishimura RA, Clements IP, Bardsley WT, Grill DE, Bailey KR, Fuster V. Myocardial infarction and coronary artery occlusion: a prospective 5-year angiographic study. *J Am Coll Cardiol.* 1990;15:218A. Abstract.
14. Moise A, Lesperance J, Theroux P, Taeymans Y, Goulet C, Bourassa MG. Clinical and angiographic predictors of new total coronary occlusion in coronary artery disease: analysis of 313 nonoperated patients. *Am J Cardiol.* 1984;54:1176-1181. [\[Medline\]](#) [\[Order article via Infotrieve\]](#)
15. Levin DC, Baltaxe HA, Lee JG, Sos TA. Potential sources of error in coronary arteriography, I: in performance of the study. *Am J Roentgenol Radiat Ther Nucl Med.* 1975;124:378-385. [\[Abstract\]](#)
16. Levin DC, Baltaxe HA, Sos TA. Potential sources of error in coronary arteriography, II: interpretation of the study. *Am J Roentgenol Radiat Ther Nucl Med.* 1975;124:386-393. [\[Abstract\]](#)
17. Blankenhorn DH, Curry PJ. The accuracy of arteriography and ultrasound imaging for atherosclerosis measurement: a review. *Arch Pathol Lab Med.* 1982;106:483-489. [\[Medline\]](#) [\[Order article via Infotrieve\]](#)
18. Trask N, Califf RM, Conley MJ, Kong Y, Peter R, Lee KL, Hackel DB, Wagner GS. Accuracy and interobserver variability of coronary cineangiography: a comparison with postmortem evaluation. *J Am Coll Cardiol.* 1984;3:1145-1154. [\[Abstract\]](#)
19. Grodin CM, Dyrda I, Pasternac A, Campeau L, Bourassa MG, Lesperance J. Discrepancies between cineangiographic and post mortem findings in patients with coronary disease and recent myocardial revascularization. *Circulation.* 1974;49:703-708. [\[Abstract/Free Full Text\]](#)
20. Vlodaver Z, Frech R, Van Tassel RA, Edwards JE. Correlation of the antemortem coronary arteriogram and the postmortem specimen. *Circulation.* 1973;47:162-169. [\[Abstract/Free Full Text\]](#)
21. Schwartz JW, Kong Y, Hackel DB, Bartel AG. Comparison of angiographic and postmortem findings in patients with coronary artery disease. *Am J Cardiol.* 1975;36:174-178. [\[Medline\]](#) [\[Order article via Infotrieve\]](#)
22. Isner JM, Kishel J, Kent KM, Ronan JA, Ross AM, Roberts WC. Accuracy of angiographic determination of left main coronary arterial narrowing: angiographic-histologic correlative analysis in 28 patients. *Circulation.* 1981;63:1056-1064. [\[Abstract/Free Full Text\]](#)
23. Marcus ML, Armstrong ML, Heistad DD, Mark AL. Comparison of three methods of evaluating coronary obstructive lesions: postmortem arteriography, pathologic examination and measurement of regional myocardial perfusion during maximal vasodilation. *Am J Cardiol.* 1982;49:1699-1706.

[\[Medline\]](#) [\[Order article via Infotrieve\]](#)

24. White CW, Wright CB, Doty DB, Hiratza LF, Eastham CL, Harrison DG, Marcus ML. Does visual interpretation of the coronary arteriogram predict the physiologic importance of a coronary stenosis? *N Engl J Med*. 1984;310:819-824. [\[Abstract\]](#)
25. Siegel RJ, Swan K, Edwards G, Fishbein MC. Limitations of postmortem assessment of human coronary artery size and luminal narrowing: differential effects of tissue fixation and processing on vessels with different degrees of atherosclerosis. *J Am Coll Cardiol*. 1985;5:342-346. [\[Abstract\]](#)
26. Zarins CK, Zatina MA, Glagov S. Correlation of postmortem angiography with pathologic anatomy: quantitation of atherosclerotic lesions. In: Bond MG, Insull W Jr, Glagov S, Chandler AB, Cornhill JF, eds. *Clinical Diagnosis of Atherosclerosis: Quantitative Methods of Evaluation*. New York, NY: Springer-Verlag; 1983:283-303.
27. Dietz WA, Tobis JM, Isner JM. Failure of angiography to accurately depict the extent of coronary artery narrowing in three fatal cases of percutaneous transluminal coronary angioplasty. *J Am Coll Cardiol*. 1992;19:1261-1270. [\[Abstract\]](#)
28. Warnes CA, Roberts WC. Sudden coronary death: relation of amount and distribution of coronary narrowing at necropsy to previous symptoms of myocardial ischemia, left ventricular scarring and heart weight. *Am J Cardiol*. 1984;54:65-73. [\[Medline\]](#) [\[Order article via Infotrieve\]](#)
29. Roberts WC. The coronary arteries and left ventricle in clinically isolated angina pectoris. *Circulation*. 1976;54:388-390. [\[Abstract/Free Full Text\]](#)
30. Bulkley BH, Roberts WC. Atherosclerotic narrowing of the left main coronary artery: a necropsy analysis of 152 patients with fatal coronary heart disease and varying degrees of left main narrowing. *Circulation*. 1976;53:823-828. [\[Abstract/Free Full Text\]](#)
31. Leung W-H, Alderman EL, Lee TC, Stadius ML. Quantitative arteriography of apparently normal coronary segments with nearby or distant disease suggests presence of occult, nonvisualized atherosclerosis. *J Am Coll Cardiol*. 1995;25:311-317. [\[Abstract\]](#)
32. Coy KM, Maurer G, Siegel RJ. Intravascular ultrasound imaging: a current perspective. *J Am Coll Cardiol*. 1991;18:1811-1823. [\[Abstract\]](#)
33. Mintz GS, Painter JA, Pichard AD, Kent KM, Satler LF, Popma JJ, Chuang YC, Bucher TA, Sokolowicz LE, Leon MB. Atherosclerosis in angiographically 'normal' coronary artery reference segments: an intravascular ultrasound study with clinical correlations. *J Am Coll Cardiol*. 1995;25:1479-1485. [\[Abstract\]](#)
34. Glagov S, Weisenberg E, Zarins CK, Stankunavicius R, Kolettis GJ. Compensatory enlargement of human atherosclerotic coronary arteries. *N Engl J Med*. 1987;316:1371-1375. [\[Abstract\]](#)
35. Stiel GM, Stiel LSG, Schofer J, Donath K, Mathey DG. Impact of compensatory enlargement of atherosclerotic coronary arteries on angiographic assessment of coronary artery disease. *Circulation*.

1989;80:1603-1609. [\[Abstract/Free Full Text\]](#)

36. Clarkson TB, Prichard RW, Morgan TM, Petrick GS, Klein KP. Remodeling of coronary arteries in human and nonhuman primates. *JAMA*. 1994;271:289-294. [\[Abstract/Free Full Text\]](#)

37. Losordo DW, Rosenfield K, Kaufman J, Pieczek A, Isner JM. Focal compensatory enlargement of human arteries in response to progressive atherosclerosis: in vivo documentation using intravascular ultrasound. *Circulation*. 1994;89:2570-2577. [\[Abstract/Free Full Text\]](#)

38. Mann JM, Davies MJ. Assessment of the severity of coronary disease at postmortem examination: are the measurements clinically valid? *Br Heart J*. 1995;74:528-530. [\[Abstract/Free Full Text\]](#)

39. Ellis S, Alderman E, Cain K, Fisher L, Sanders W, Bourassa M, for the CASS Investigators. Prediction of risk of anterior myocardial infarction by lesion severity and measurement method of stenoses in the left anterior descending coronary distribution: a CASS Registry study. *J Am Coll Cardiol*. 1988;11:908-916. [\[Abstract\]](#)

40. Nishioka T, Luo H, Eigler NL, Berglund H, Kim CJ, Siegel RJ. Contribution of inadequate compensatory enlargement to the development of human coronary artery stenosis: an in vivo intravascular ultrasound study. *J Am Coll Cardiol*. 1996;27:1571-1576. [\[Abstract\]](#)

41. Zarins CK, Weisenberg E, Kolettis G, Stankunavicius R, Glagov S. Differential enlargement of artery segments in response to enlarging atherosclerotic plaques. *J Vasc Surg*. 1988;7:386-394. [\[Medline\]](#) [\[Order article via Infotrieve\]](#)

## This article has been cited by other articles:



Journal of the American College of Cardiology

[HOME](#)

G. A. Rodriguez-Granillo, H. M. Garcia-Garcia, E. P. Mc Fadden, M. Valgimigli, J. Aoki, P. de Feyter, and P. W. Serruys

**In Vivo Intravascular Ultrasound-Derived Thin-Cap Fibroatheroma Detection Using Ultrasound Radiofrequency Data Analysis**

*J. Am. Coll. Cardiol.*, December 6, 2005; 46(11): 2038 - 2042.

[\[Abstract\]](#) [\[Full Text\]](#) [\[PDF\]](#)



Stroke

[HOME](#)

B. A. Wasserman, R. J. Wityk, H. H. Trout III, and R. Virmani

**Low-Grade Carotid Stenosis: Looking Beyond the Lumen With MRI**

*Stroke*, November 1, 2005; 36(11): 2504 - 2513.

[\[Abstract\]](#) [\[Full Text\]](#) [\[PDF\]](#)

**Journal of the American College of Cardiology**[▶ HOME](#)

M. Takano, S. Inami, F. Ishibashi, K. Okamoto, K. Seimiya, T. Ohba, S. Sakai, and K. Mizuno

**Angioscopic follow-up study of coronary ruptured plaques in nonculprit lesions**

J. Am. Coll. Cardiol., March 1, 2005; 45(5): 652 - 658.

[\[Abstract\]](#) [\[Full Text\]](#) [\[PDF\]](#)

**Circulation**[▶ HOME](#)

K. Fujii, Y. Kobayashi, G. S. Mintz, H. Takebayashi, G. Dangas, I. Moussa, R. Mehran, A. J. Lansky, E. Kreps, M. Collins, *et al.*

**Intravascular Ultrasound Assessment of Ulcerated Ruptured Plaques: A Comparison of Culprit and Nonculprit Lesions of Patients With Acute Coronary Syndromes and Lesions in Patients Without Acute Coronary Syndromes**

Circulation, November 18, 2003; 108(20): 2473 - 2478.

[\[Abstract\]](#) [\[Full Text\]](#) [\[PDF\]](#)

**Circulation**[▶ HOME](#)

J.H.F. Rudd, E.A. Warburton, T.D. Fryer, H.A. Jones, J.C. Clark, N. Antoun, P. Johnstrom, A.P. Davenport, P.J. Kirkpatrick, B.N. Arch, *et al.*

**Imaging Atherosclerotic Plaque Inflammation With [18F]-Fluorodeoxyglucose Positron Emission Tomography**

Circulation, June 11, 2002; 105(23): 2708 - 2711.

[\[Abstract\]](#) [\[Full Text\]](#) [\[PDF\]](#)

**Circulation**[▶ HOME](#)

E. Ivan, J. J. Khatri, C. Johnson, R. Magid, D. Godin, S. Nandi, S. Lessner, and Z. S. Galis

**Expansive Arterial Remodeling Is Associated With Increased Neointimal Macrophage Foam Cell Content: The Murine Model of Macrophage-Rich Carotid Artery Lesions**

Circulation, June 4, 2002; 105(22): 2686 - 2691.

[\[Abstract\]](#) [\[Full Text\]](#) [\[PDF\]](#)

**European Heart Journal**[▶ HOME](#)

C. Di Mario

**Vulnerable plaques: let's stop sinking on submerged icebergs?**

Eur. Heart J., March 1, 2002; 23(5): 349 - 351.

[\[Full Text\]](#) [\[PDF\]](#)


**European Heart Journal**
[▶ HOME](#)

C.L. de Korte, S.G. Carlier, F. Mastik, M.M. Doyley, A.F.W. van der Steen, P.W. Serruys, and N. Bom

**Morphological and mechanical information of coronary arteries obtained with intravascular elastography. Feasibility study in vivo**

Eur. Heart J., March 1, 2002; 23(5): 405 - 413.

[\[Abstract\]](#) [\[Full Text\]](#) [\[PDF\]](#)


**Circulation**
[▶ HOME](#)

P. K. Shah and Z. S. Galis

**Matrix Metalloproteinase Hypothesis of Plaque Rupture: Players Keep Piling Up But Questions Remain**

Circulation, October 16, 2001; 104(16): 1878 - 1880.

[\[Full Text\]](#) [\[PDF\]](#)


**Seminars in Cardiothoracic and Vascular Anesthesia**
[▶ HOME](#)

D. A. Zvara

**Treatment of Perioperative Myocardial Ischemia**

Seminars in Cardiothoracic and Vascular Anesthesia, July 1, 2001; 5(2): 166 - 183.

[\[Abstract\]](#) [\[PDF\]](#)


**Journal of the American College of Cardiology**
[▶ HOME](#)

C. von Birgelen, W. Klinkhart, G. S. Mintz, A. Papatheodorou, J.o. Herrmann, D. Baumgart, M. Haude, H. Wieneke, J. Ge, and R. Erbel

**Plaque distribution and vascular remodeling of ruptured and nonruptured coronary plaques in the same vessel: an intravascular ultrasound study in vivo**

J. Am. Coll. Cardiol., June 1, 2001; 37(7): 1864 - 1870.

[\[Abstract\]](#) [\[Full Text\]](#) [\[PDF\]](#)


**HEART ONLINE and EDUCATION IN HEART**
[▶ HOME](#)

C von Birgelen, W Klinkhart, G S Mintz, H Wieneke, D Baumgart, M Haude, T Bartel, S Sack, J Ge, and R Erbel

**Size of emptied plaque cavity following spontaneous rupture is related to coronary dimensions, not to the degree of lumen narrowing. A study with intravascular ultrasound in vivo**

Heart, November 1, 2000; 84(5): 483 - 488.

[\[Abstract\]](#) [\[Full Text\]](#)


**Journal of the American College of Cardiology**
[▶ HOME](#)

Y. Arad, L. A. Spadaro, K. Goodman, D. Newstein, and A. D. Guerci  
**Prediction of coronary events with electron beam computed tomography**

J. Am. Coll. Cardiol., October 1, 2000; 36(4): 1253 - 1260.

[\[Abstract\]](#) [\[Full Text\]](#) [\[PDF\]](#)


**Journal of the American College of Cardiology**
[▶ HOME](#)

G. Pasterkamp, E. Falk, H. Woutman, and C. Borst  
**Techniques characterizing the coronary atherosclerotic plaque: influence on clinical decision making?**

J. Am. Coll. Cardiol., July 1, 2000; 36(1): 13 - 21.

[\[Abstract\]](#) [\[Full Text\]](#) [\[PDF\]](#)


**Arteriosclerosis, Thrombosis, and Vascular Biology**
[▶ HOME](#)

R. Virmani, F. D. Kolodgie, A. P. Burke, A. Farb, and S. M. Schwartz  
**Lessons From Sudden Coronary Death : A Comprehensive Morphological Classification Scheme for Atherosclerotic Lesions**

Arterioscler Thromb Vasc Biol, May 1, 2000; 20(5): 1262 - 1275.

[\[Full Text\]](#) [\[PDF\]](#)


**Arteriosclerosis, Thrombosis, and Vascular Biology**
[▶ HOME](#)

S. Tsimikas, B. P. Shortal, J. L. Witztum, and W. Palinski  
**In Vivo Uptake of Radiolabeled MDA2, an Oxidation-Specific Monoclonal Antibody, Provides an Accurate Measure of Atherosclerotic Lesions Rich in Oxidized LDL and Is Highly Sensitive to Their Regression**

Arterioscler Thromb Vasc Biol, March 1, 2000; 20(3): 689 - 697.

[\[Abstract\]](#) [\[Full Text\]](#) [\[PDF\]](#)


**Cardiovascular Research**
[▶ HOME](#)

G. Pasterkamp, D. P.V de Kleijn, and C. Borst  
**Arterial remodeling in atherosclerosis, restenosis and after alteration of blood flow: potential mechanisms and clinical implications**

Cardiovasc Res, March 1, 2000; 45(4): 843 - 852.

[\[Abstract\]](#) [\[Full Text\]](#) [\[PDF\]](#)


**The NEW ENGLAND JOURNAL of MEDICINE**
[▶ HOME](#)

Y. Yeghiazarians, J. B. Braunstein, A. Askari, and P. H. Stone  
**Unstable Angina Pectoris**

N. Engl. J. Med., January 13, 2000; 342(2): 101 - 114.

[\[Full Text\]](#) [\[PDF\]](#)**Angiology**[▶ HOME](#)

I. Herz, A. Assali, A. Solodky, N. Shor, T. Ben-Gal, Y. Adler, and Y. Birnbaum  
**Coronary Stent Deployment Without Predilation in Acute Myocardial Infarction: A Feasible, Safe, and Effective Technique**

Angiology, November 1, 1999; 50(11): 901 - 908.

[\[Abstract\]](#) [\[PDF\]](#)**HEART ONLINE and EDUCATION IN HEART**[▶ HOME](#)

P C Smits, G Pasterkamp, M A Q. van Ufford, F D Eefting, P R Stella, P P T de Jaegere, and C Borst

**Coronary artery disease: arterial remodelling and clinical presentation**

Heart, October 1, 1999; 82(4): 461 - 464.

[\[Abstract\]](#) [\[Full Text\]](#) [\[PDF\]](#)**The NEW ENGLAND JOURNAL of MEDICINE**[▶ HOME](#)

D. S. Celermajer

**Noninvasive Detection of Atherosclerosis**

N. Engl. J. Med., December 31, 1998; 339(27): 2014 - 2015.

[\[Full Text\]](#)**Journal of the American College of Cardiology**[▶ HOME](#)

G. Pasterkamp, A. H. Schoneveld, A. C. van der Wal, C. C. Haudenschild, R. J. G. Clarijs, A. E. Becker, B. Hillen, and C. Borst

**Relation of arterial geometry to luminal narrowing and histologic markers for plaque vulnerability: the remodeling paradox**

J. Am. Coll. Cardiol., September 1, 1998; 32(3): 655 - 662.

[\[Abstract\]](#) [\[Full Text\]](#) [\[PDF\]](#)**Stroke**[▶ HOME](#)

P. T. Akins, T. K. Pilgram, D. T. Cross III, and C. J. Moran

**Natural History of Stenosis From Intracranial Atherosclerosis by Serial Angiography**

Stroke, February 1, 1998; 29(2): 433 - 438.

[\[Abstract\]](#) [\[Full Text\]](#) [\[PDF\]](#)*This Article*

[Circulation Home](#) | [Subscriptions](#) | [Archives](#) | [Feedback](#) | [Authors](#) | [Help](#) | [AHA Journals Home](#) | [Search](#)

Copyright © 1996 American Heart Association, Inc. All rights reserved. Unauthorized use prohibited.

▶ **Extract FREE**

▶ [Alert me when this article is cited](#)

▶ [Alert me if a correction is posted](#)

▶ [Citation Map](#)

*Services*

▶ [Email this article to a friend](#)

▶ [Similar articles in this journal](#)

▶ [Similar articles in PubMed](#)

▶ [Alert me to new issues of the journal](#)

▶ [Download to citation manager](#)

▶ [Request Permissions](#)

*Citing Articles*

▶ [Citing Articles via HighWire](#)

▶ [Citing Articles via Google Scholar](#)

*Google Scholar*

▶ [Articles by Fishbein, M. C.](#)

▶ [Articles by Siegel, R. J.](#)

▶ [Search for Related Content](#)

*PubMed*

▶ [PubMed Citation](#)

▶ [Articles by Fishbein, M. C.](#)

▶ [Articles by Siegel, R. J.](#)

▶ **PubMed/NCBI databases**

**Medline Plus Health Information**

▪ [Coronary Artery Disease](#)