

varicose bronchiectasis, high-attenuation mucus impaction, and tree-in-bud opacities.<sup>3</sup> In contrast, the computed tomographic findings in this patient included lower-lobe consolidation and diffuse bilateral nondependent ground-glass opacities, with no evidence of airway inflammation; these findings make allergic bronchopulmonary aspergillosis unlikely. Therefore, although this patient did have dyspnea and fever, his history, laboratory test results, and findings on imaging studies are not consistent with allergic bronchopulmonary aspergillosis.

Kai Saukkonen, M.D.

Amita Sharma, M.D.

Massachusetts General Hospital  
Boston, MA

Since publication of their article, the authors report no further potential conflict of interest.

1. Denning DW, Pashley C, Hartl D, et al. Fungal allergy in asthma — state of the art and research needs. *Clin Transl Allergy* 2014;4:14.
2. Bains SN, Judson MA. Allergic bronchopulmonary aspergillosis. *Clin Chest Med* 2012;33:265-81.
3. Greene R. The radiological spectrum of pulmonary aspergillosis. *Med Mycol* 2005;43:Suppl 1:S147-54.

DOI: 10.1056/NEJMc1604864

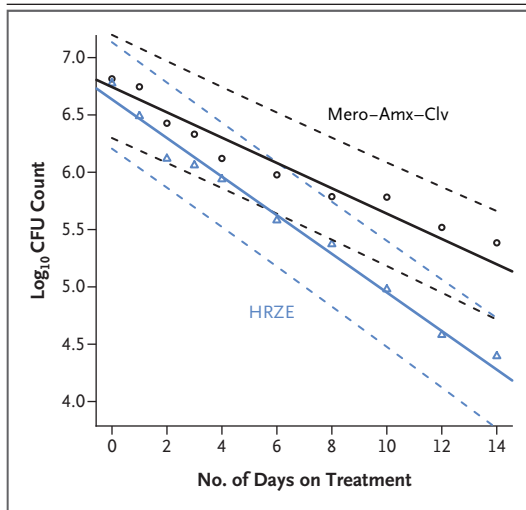
## **$\beta$ -Lactams against Tuberculosis — New Trick for an Old Dog?**

**TO THE EDITOR:** New treatments are needed to combat the worldwide increase in resistance to antituberculosis drugs.<sup>1</sup> The outlook for patients with tuberculosis who do not show a response to the key agents used in treatment — isoniazid, rifampin, fluoroquinolones, and aminoglycosides — is grim and reminiscent of the plight of patients with cancer in the era before chemotherapy.<sup>2</sup> New agents are emerging, but the obligatory evaluation of their safety and efficacy in combination with other antituberculosis and antiretroviral agents slows the pace of progress. Repurposing or combining commercially available products may offer a faster track to new antituberculosis regimens. For many decades, the hurdle of genetically encoded  $\beta$ -lactamase in *Mycobacterium tuberculosis* was considered insurmountable in clinical practice, a view that was supported by two unsuccessful clinical trials with amoxicillin–clavulanic acid, one conducted in the United States and Turkey<sup>3</sup> and one in South Africa.<sup>4</sup> The World Health Organization currently lists amoxicillin–clavulanic acid as a third-line (and last-line) agent with unclear efficacy.<sup>1</sup>

In vitro data showing that carbapenems are intrinsically poor substrates for *M. tuberculosis*  $\beta$ -lactamase have challenged this belief.<sup>5</sup> Meropenem combined with amoxicillin–clavulanic acid not only resisted hydrolysis well but also showed synergistic antituberculosis activity. In a prospective randomized trial (ClinicalTrials.gov number, NCT02349841) approved by ethics and regulatory authorities, we randomly allocated two groups of 15 patients each with smear-positive

tuberculosis to receive either 2 g of meropenem in a bolus infusion plus oral amoxicillin–clavulanic acid in doses of 500 mg and 125 mg, respectively, every 8 hours or daily treatment with isoniazid, rifampin, pyrazinamide, and ethambutol for 14 days. Written informed consent was obtained from each participant. We obtained serial counts of colony-forming units (CFUs) per milliliter of sputum from 16-hour overnight sputum collections for each patient. Using a linear mixed-effects model, we estimated the mean daily decline in CFUs with meropenem plus amoxicillin–clavulanic acid and with isoniazid, rifampin, pyrazinamide, and ethambutol as 0.11 (95% confidence interval [CI], 0.09 to 0.13) and 0.17 (95% CI, 0.15 to 0.19)  $\log_{10}$  CFUs, respectively ( $P < 0.001$  for both groups, as compared with no effect) (Fig. 1). The reduction of the sputum mycobacterial load by 1.5 orders of magnitude in the first 14 days of treatment is on par with that previously reported for the key agents rifampin and pyrazinamide. Adverse events among patients receiving meropenem plus amoxicillin–clavulanic acid were infrequent and mild.

It would be welcome news for clinicians who are treating patients with highly resistant tuberculosis that a commercially available  $\beta$ -lactam combination might be considered on the short list of options for a rescue regimen.  $\beta$ -Lactams have a long record of safety in a wide-ranging patient population, including children and patients infected with the human immunodeficiency virus. The finding of antimycobacterial activity early in treatment does not guarantee



**Figure 1. Estimated Mean Log<sub>10</sub> CFU Counts per Treatment over Time.**

The figure shows mean log<sub>10</sub> colony-forming unit (CFU) counts at each time point as symbols (triangles and circles) and superimposed treatment activities as lines, with 95% confidence intervals shown as dashed lines, as derived from a linear mixed-effects model. The estimated daily decline in log<sub>10</sub> CFUs for meropenem combined with amoxicillin–clavulanic acid (Mero–Amx–Clv) and isoniazid, rifampin, pyrazinamide, and ethambutol (HRZE) was 0.11 (95% confidence interval [CI], 0.09 to 0.13) and 0.17 (95% CI, 0.15 to 0.19), respectively, over 14 days ( $P < 0.001$  for both groups, as compared with no effect;  $P < 0.001$  for the comparison between groups).

relapse-free cure, and more research is needed to determine how  $\beta$ -lactams can contribute to the treatment of tuberculosis.

Andreas H. Diacon, M.D., Ph.D.

Stellenbosch University  
Cape Town, South Africa  
ahd@sun.ac.za

Lize van der Merwe, Ph.D.  
Marinus Barnard, Ph.D.  
Florian von Groote-Bidlingmaier, M.D.

Task Applied Science  
Cape Town, South Africa

Christoph Lange, M.D.

Research Center Borstel  
Borstel, Germany

Alberto L. García-Basteiro, M.D.

Barcelona Institute for Global Health  
Barcelona, Spain

Esperança Sevens, M.D., Ph.D.

Centro de Investigação em Saude de Manhica  
Maputo, Mozambique

Lluís Ballell, Ph.D.

David Barros-Aguirre, Ph.D.

GlaxoSmithKline  
Madrid, Spain

Supported by a grant from the European and Developing Countries Clinical Trials Partnership (SP.2011.41304.076).

Disclosure forms provided by the authors are available with the full text of this letter at NEJM.org.

This letter was published on July 13, 2016, at NEJM.org.

1. Global tuberculosis report 2013. Geneva: World Health Organization, 2013 ([http://apps.who.int/iris/bitstream/10665/91355/1/9789241564656\\_eng.pdf](http://apps.who.int/iris/bitstream/10665/91355/1/9789241564656_eng.pdf)).
2. Tiemersma EW, van der Werf MJ, Borgdorff MW, Williams BG, Nagelkerke NJ. Natural history of tuberculosis: duration and fatality of untreated pulmonary tuberculosis in HIV negative patients: a systematic review. *PLoS One* 2011;6(4):e17601.
3. Chambers HF, Kocagöz T, Sipit T, Turner J, Hopewell PC. Activity of amoxicillin/clavulanate in patients with tuberculosis. *Clin Infect Dis* 1998;26:874-9.
4. Donald PR, Siregel FA, Venter A, et al. Early bactericidal activity of amoxicillin in combination with clavulanic acid in patients with sputum smear-positive pulmonary tuberculosis. *Scand J Infect Dis* 2001;33:466-9.
5. Hugonnet JE, Tremblay LW, Boshoff HI, Barry CE III, Blanchard JS. Meropenem-clavulanate is effective against extensively drug-resistant *Mycobacterium tuberculosis*. *Science* 2009;323:1215-8.

DOI: 10.1056/NEJMc1513236

## Uveitis Associated with Zika Virus Infection

**TO THE EDITOR:** Zika virus (ZIKV) is an arthropod-borne virus transmitted by infected aedes mosquitoes.<sup>1</sup> Nonpurulent conjunctivitis has been described in association with ZIKV infection in adults.<sup>2</sup> We report on a man in his early 40s who had an unremarkable medical history and a 2-day history of a rash and bilateral ocular hyperemia. ZIKV infection was diagnosed by means of a positive real-time reverse-transcriptase–

polymerase-chain-reaction (RT-PCR) assay<sup>3</sup> of a serum specimen. A peripheral-blood sample was also positive for anti-ZIKV IgM antibodies detected by means of an in-house enzyme-linked immunosorbent assay and a plaque-reduction neutralization test<sup>4</sup> (titer, 1:5000).

Eight days after the onset of systemic symptoms, ophthalmic evaluation showed a visual acuity of 20/20 in the patient's right eye and